Google

This is a digital copy of a book that was preserved for generations on library shelves before it was carefully scanned by Google as part of a project to make the world's books discoverable online.

It has survived long enough for the copyright to expire and the book to enter the public domain. A public domain book is one that was never subject to copyright or whose legal copyright term has expired. Whether a book is in the public domain may vary country to country. Public domain books are our gateways to the past, representing a wealth of history, culture and knowledge that's often difficult to discover.

Marks, notations and other marginalia present in the original volume will appear in this file - a reminder of this book's long journey from the publisher to a library and finally to you.

Usage guidelines

Google is proud to partner with libraries to digitize public domain materials and make them widely accessible. Public domain books belong to the public and we are merely their custodians. Nevertheless, this work is expensive, so in order to keep providing this resource, we have taken steps to prevent abuse by commercial parties, including placing technical restrictions on automated querying.

We also ask that you:

+ *Make non-commercial use of the files* We designed Google Book Search for use by individuals, and we request that you use these files for personal, non-commercial purposes.

+ *Refrain from automated querying* Do not send automated queries of any sort to Google's system: If you are conducting research on machine translation, optical character recognition or other areas where access to a large amount of text is helpful, please contact us. We encourage the use of public domain materials for these purposes and may be able to help.

+ *Maintain attribution* The Google "watermark" you see on each file is essential for informing people about this project and helping them find additional materials through Google Book Search. Please do not remove it.

+ *Keep it legal* Whatever your use, remember that you are responsible for ensuring that what you are doing is legal. Do not assume that just because we believe a book is in the public domain for users in the United States, that the work is also in the public domain for users in other countries. Whether a book is still in copyright varies from country to country, and we can't offer guidance on whether any specific use of any specific book is allowed. Please do not assume that a book's appearance in Google Book Search means it can be used in any manner anywhere in the world. Copyright infringement liability can be quite severe.

About Google Book Search

Google's mission is to organize the world's information and to make it universally accessible and useful. Google Book Search helps readers discover the world's books while helping authors and publishers reach new audiences. You can search through the full text of this book on the web at http://books.google.com/

BOSTON
MEDICAL LIBRARY
8 THE FENWAY

TRANSACTIONS

of the

American Ophthalmological Society

Forty-fifth Annual Meeting

NEW LONDON, CONN., 1909

VOL. XII, PART 1

Philadelphia
American Ophthalmological Society
1909

BOSTON MEDICAL
[illegible] 1910
LIBRARY.

83 C6

CATALOGUED
JAN 18 1910
J. F. B.

PRESS OF WM. F. FELL CO.
PHILADELPHIA

12529

TABLE OF CONTENTS.

PAGE

List of Officers and Members 5

Necrology 11

Minutes of the Proceedings 21

A Classification of Eye Diseases: Dr. Alexander Duane 31

The Adverse Influence of Diabetes in Certain Operations on the Eye: Dr. Charles Stedman Bull 62

Summary of Results Obtained, and Features of Interest, in Two Hundred and Fifteen Consecutive Cataract Extractions: Dr. Samuel Theobald 76

The Choice of Operation for Iridotomy: Dr. McCluney Radcliffe 89

The Treatment of the Eye when the Globe is Infected, with the Object of Preventing Panophthalmitis: Dr. A. Edward Davis 103

Third Series of Cases of Injuries from Foreign Bodies Examined by the Roentgen Rays, with Results of Operation: Dr. William M. Sweet .. 117

Physical Economics: Dr. Erastus Eugene Holt 141

Spontaneous Rupture of the Eyeball. Report of a Case: Dr. James W. Ingalls 169

Adenocarcinoma of the Pituitary Body. Report of a Case Under Observation for Four and a Half Years. Pathological Examination: Dr. William T. Shoemaker 173

Report of a Case of Sarcoma and Bone Formation in an Atrophic Eye, with Presentation of Specimen: Dr. Dunbar Roy 188

Metastatic Carcinoma of the Orbit, with the Report of a Case: Dr. Edward A. Shumway 191

Orbital Fibroma, with Unusual Clinical Manifestations: Dr. G. Oram Ring 206

Symmetrical Lymphomata of the Lacrimal and Salivary Glands (Mikulicz's Disease): Dr. S. Lewis Ziegler 222

A Case of Complete Albinism; Observations on the Changes in the Diameters of the Lens as Seen through the Iris: Dr. George F. Libby 246

A Case of Bilateral Macular Coloboma: Dr. Howard F. Hansell 249

Hemorrhagic Central Chorioretinitis in Non-myopic Eyes: A Clinical Contribution: Dr. Charles J. Kipp 250

Angioid Streaks in the Retina, with the Report of a Case: Dr. W. Zentmayer 267

Concerning a Form of Retinal Disease with Extensive Exudation; Being a Clinical Contribution, with the Report of Two Cases: Dr. G. E. de Schweinitz 273

Neuroretinitis in Chlorosis, with Report of a Case: Dr. Wm. Campbell Posey 284

PAGE.

The Differentiation of the Diphtheria Bacillus from Organisms Morphologically Similar: Dr. Carl Fisher..... 297

Tropometers and Measurements of Arcs of Rotation: Dr. Lucien Howe.. 312

Improved Apparatus for Locating Foreign Bodies in the Eyeball by the Roentgen Rays: Dr. William M. Sweet..... 320

Improved Lantern for Testing the Color-Perception. Model of 1909. Dr. Charles H. Williams..... 330

American Ophthalmological Society.

1909-1910.

OFFICERS.

President,	Dr. S. THEOBALD,	Baltimore, Md.
Vice-President,	Dr. E. GRUENING,	New York City.
Secretary-Treasurer,	Dr. WM. M. SWEET,	Philadelphia, Pa.
Corresponding Secretary,	Dr. A. KNAPP,	New York City.

MEMBERS.

ACTIVE MEMBERS.

The (*) indicates *Associates.*

NAME.	RESIDENCE.	PLACE.
Dr. A. E. ADAMS,	44 Grand Street,	Newburg, N. Y.
Dr. J. L. ADAMS,	38 East 51st Street,	New York, N. Y.
Dr. L. A. W. ALLEMAN,	64 Montague Street,	Brooklyn, N. Y.
Dr. A. N. ALLING,	257 Church Street,	New Haven, Conn.
Dr. G. W. ALLYN,	Empire Building,	Pittsburg, Pa.
Dr. A. ALT,	Metropolitan Bldg.,	St. Louis, Mo.
†Dr. J. A. ANDREWS,	107 Madison Avenue,	New York, N. Y.
Dr. S. C. AYRES,	4 West 7th Street,	Cincinnati, Ohio.
*Dr. C. H. BEARD,	34 Washington Street,	Chicago, Ill.
*Dr. GEO. H. BELL,	12 West 46th Street,	New York, N. Y.
*Dr. JAS. H. BELL,	Moore Building,	San Antonio, Texas.
*Dr. JAMES BORDLEY, JR.,	330 N. Charles Street,	Baltimore, Md.
Dr. H. W. BRADFORD,		Wolfboro, N. H.
*Dr. E. V. L. BROWN,	100 State Street,	Chicago, Ill.
*Dr. GUSTAVE E. BRUÈRE,	413 Oregonian Building,	Portland, Oregon.
*Dr. WM. E. BRUNER,	New England Building,	Cleveland, Ohio.
*Dr. H. D. BRUNS,	211 Camp Street,	New Orleans, La.
Dr. CHARLES S. BULL,	47 West 36th Street,	New York, N. Y.
*Dr. G. H. BURNHAM,		Toronto, Can.
Dr. W. K. BUTLER,	1207 M St. N. W.,	Washington, D. C.
*Dr. W. GORDON M. BYERS,	346 Mountain Street,	Montreal, Canada.

† Temporarily residing at Santa Barbara, Cal.

Name.	Residence.	Place.
*Dr. L. W. Callan,	452 Fifth Avenue,	New York, N. Y.
Dr. Peter A. Callan,	452 Fifth Avenue,	New York, N. Y.
Dr. F. P. Capron,	118 Angell Street,	Providence, R. I.
Dr. W. H. Carmalt,	87 Elm Street,	New Haven, Conn.
Dr. John T. Carpenter, Jr.,	1624 Walnut Street,	Philadelphia, Pa.
Dr. Burton Chance,	235 So. 13th Street,	Philadelphia, Pa.
Dr. H. B. Chandler,	34½ Beacon Street,	Boston, Mass.
Dr. J. W. Charles,	509 Humboldt Building,	St. Louis, Mo.
Dr. Wm. Cheatham,	303 West Chestnut Street,	Louisville, Ky.
Dr. F. E. Cheney,	126 Commonwealth Ave.,	Boston, Mass.
Dr. J. H. Claiborne,	34 West 36th Street,	New York, N. Y.
Dr. C. F. Clark,	188 East State Street,	Columbus, Ohio.
Dr. David Coggin,	7 Chestnut Street,	Salem, Mass.
Dr. Wm. G. Craig,	15 Fuller Building,	Springfield, Mass.
Dr. C. M. Culver,	36 Eagle Street,	Albany, N. Y.
Dr. R. J. Curdy,	301 Keith & Perry Bldg.,	Kansas City, Mo.
Dr. Colman W. Cutler,	8 East 54th St.,	New York, N. Y.
*Dr. Jno. P. Davidson,	316 East Franklin Street,	Richmond, Va.
*Dr. A. E. Davis,	50 West 37th Street,	New York, N. Y.
Dr. W. S. Dennett,	8 East 49th Street,	New York, N. Y.
*Dr. George S. Derby,	7 Hereford St.,	Boston, Mass.
Dr. Hasket Derby,	182 Marlborough Street,	Boston, Mass.
Dr. Lewis S. Dixon,	232 Clarendon Street,	Boston, Mass.
Dr. Alexander Duane,	49 East 30th Street,	New York, N. Y.
*Dr. J. A. Duncan,	Arrott Bldg.,	Pittsburg, Pa.
Dr. J. B. Emerson,	20 East 30th Street,	New York, N. Y.
Dr. Arthur E. Ewing,	Metropolitan Bldg.,	St. Louis, Mo.
Dr. T. H. Fenton,	1319 Spruce Street,	Philadelphia, Pa.
Dr. George F. Fiske,	100 State Street,	Chicago, Ill.
*Dr. M. L. Foster,	616 Madison Ave.,	New York, N. Y.
Dr. W. H. Fox,	1826 Jefferson Place,	Washington, D. C.
Dr. Percy Fridenberg,	60 East 58th Street,	New York, N. Y.
Dr. H. Friedenwald,	1029 Madison Ave.,	Baltimore, Md.
Dr. B. E. Fryer,	520 East 9th St.,	Kansas City, Mo.
Dr. G. M. Gould,	The Sentinels, Cayuga Hts.,	Ithaca, N. Y.
Dr. H. Y. Grant,	Falls View,	Ontario, Canada.
*Dr. L. S. Greene,	1610 I Street, N. W.,	Washington, D. C.
Dr. Allen Greenwood,	101 Newbury Street,	Boston, Mass.
Dr. Emil Gruening,	36 East 57th Street,	New York, N. Y.
*Dr. C. W. Haddock,		Beverly, Mass.
Dr. G. W. Hale,	214 Wilcox Building,	Nashville, Tenn.
Dr. Wm. D. Hall,	416 Marlborough Street,	Boston, Mass.
Dr. H. F. Hansell,	1528 Walnut Street,	Philadelphia, Pa.
Dr. George C. Harlan,	1700 Walnut Street,	Philadelphia, Pa.

NAME.	RESIDENCE.	PLACE.
Dr. HERBERT HARLAN,	516 Cathedral Street,	Baltimore, Md.
Dr. DAVID HARROWER,	9 Elm Street,	Worcester, Mass.
Dr. N. D. HARVEY,	262 Benefit Street,	Providence, R. I.
Dr. H. H. HASKELL,	34 Commonwealth Ave.,	Boston, Mass.
Dr. NEIL J. HEPBURN,	317 West 23d Street,	New York, N. Y.
Dr. WARD HOLDEN,	43 West 48th Street,	New York, N. Y.
*Dr. T. B. HOLLOWAY,	1819 Chestnut St.,	Philadelphia, Pa.
*Dr. C. R. HOLMES,	8 East 8th Street,	Cincinnati, Ohio.
Dr. E. E. HOLT,	723 Congress Street,	Portland, Me.
Dr. LUCIEN HOWE,	87 West Huron Street,	Buffalo, N. Y.
Dr. A. A. HUBBELL,	212 Franklin Street,	Buffalo, N. Y.
Dr. D. W. HUNTER,	80 West 40th Street,	New York, N. Y.
Dr. J. W. INGALLS,	874 Lafayette Avenue,	Brooklyn, N. Y.
Dr. E. E. JACK,	215 Beacon Street,	Boston, Mass.
Dr. EDWARD JACKSON,	1434 Glenarm Street,	Denver, Col.
Dr. B. JOY JEFFRIES,	15 Chestnut St., Beacon Hill,	Boston, Mass.
Dr. W. B. JOHNSON,	170 Broadway,	Paterson, N. J.
*Dr. B. R. KENNON,	64 Granby Street,	Norfolk, Va.
Dr. H. W. KILBURN,	192 Marlborough Street,	Boston, Mass.
Dr. CHARLES J. KIPP,	560 Broad Street,	Newark, N. J.
Dr. ARNOLD KNAPP,	26 West 40th Street,	New York, N. Y.
Dr. H. KNAPP,	26 West 40th Street,	New York, N. Y.
Dr. CARL KOLLER,	681 Madison Avenue,	New York, N. Y.
Dr. CHAS. W. KOLLOCK,	Wentworth & Com'g Sts.,	Charleston, S. C.
Dr. W. E. LAMBERT,	47 West 38th Street,	New York, N. Y.
*Dr. W. B. LANCASTER,		Amherst, Mass.
*Dr. J. C. LESTER,	179 Schermerhorn Street,	Brooklyn, N. Y.
Dr. F. N. LEWIS,	616 Madison Ave.,	New York, N. Y.
*Dr. G. F. LIBBY,	1434 Glenarm Street,	Denver, Col.
Dr. J. A. LIPPINCOTT,	Arrott Building,	Pittsburg, Pa.
Dr. F. B. LORING,	1420 K Street,	Washington, D. C.
*Dr. R. G. LORING,	2 Arlington St.,	Boston, Mass.
Dr. D. B. LOVELL,	32 Pearl Street,	Worcester, Mass.
*Dr. J. B. LYNCH,	148 West 22d Street,	New York, N. Y.
Dr. F. W. MARLOW,	731 University Block,	Syracuse, N. Y.
Dr. W. V. MARMION,	1110 8th Street, N. W.,	Washington, D. C.
Dr. W. B. MARPLE,	46 W. 53d Street,	New York, N. Y.
Dr. ARTHUR MATHEWSON,	16th St. Extended,	Washington, D. C.
Dr. S. C. MAXSON,	225 Genesee Street,	Utica, N. Y.
*Dr. C. H. MAY,	698 Madison Avenue,	New York, N. Y.
Dr. CHAS. H. McILWAINE,	703 6th Ave.,	Asbury Park, N. J.
*Dr. JNO. R. McINTOSH,	40 Coburg Street,	St. John, N. B.
Dr. C. S. MERRILL,	21 Washington Avenue,	Albany, N. Y.
*Dr. H. S. MILES,	417 State Street,	Bridgeport, Conn.

Name.	Residence.	Place.
Dr. B. L. Millikin,	1110 Euclid Avenue,	Cleveland, Ohio.
Dr. J. Lancelot Minor,	Randolph Building,	Memphis, Tenn.
Dr. W. F. Mittendorf,	140 Madison Avenue,	New York, N. Y.
Dr. Charles A. Oliver,	1507 Locust Street,	Philadelphia, Pa.
Dr. H. S. Oppenheimer,	11 East 43d Street,	New York, N. Y.
*Dr. W. R. Parker,	912 Chamber of Commerce,	Detroit, Mich.
*Dr. S. McA. Payne,	542 Fifth Avenue,	New York, N. Y.
Dr. R. J. Phillips,	123 So. 39th Street,	Philadelphia, Pa.
Dr. Thomas R. Pooley,	109 Madison Avenue,	New York, N. Y.
Dr. Wm. Campbell Posey,	2049 Chestnut Street,	Philadelphia, Pa.
Dr. M. H. Post,	Metropolitan Bldg.,	St. Louis, Mo.
Dr. H. R. Price,	435 Clinton Avenue,	Brooklyn, N. Y.
Dr. J. S. Prout,	26 Schermerhorn Street,	Brooklyn, N. Y.
*Dr. Brown Pusey,	72 Madison Street,	Chicago, Ill.
Dr. Walter L. Pyle,	1931 Chestnut Street,	Philadelphia, Pa.
Dr. Alex. Quackenboss,	277 Dartmouth Street,	Boston, Mass.
*Dr. McCluney Radcliffe,	1812 Chestnut Street,	Philadelphia, Pa.
Dr. Alex'r Randall,	1717 Locust Street,	Philadelphia, Pa.
Dr. R. L. Randolph,	816 Park Avenue,	Baltimore, Md.
Dr. J. M. Ray,	Atherton Bldg.,	Louisville, Ky.
Dr. R. G. Reese,	147 W. 57th Street,	New York, N. Y.
Dr. R. A. Reeve,	48 Bloor Street East,	Toronto, Canada.
Dr. H. O. Reik,	412 Cathedral Street,	Baltimore, Md.
Dr. Stephen O. Richey,	732 17th Street,	Washington, D. C.
Dr. Wheelock Rider,	26 Gibbs Street,	Rochester, N. Y.
*Dr. G. O. Ring,	2014 Chestnut Street,	Philadelphia, Pa.
Dr. H. W. Ring,	187 Church Street,	New Haven, Conn.
*Dr. J. Norman Risley,	1728 Chestnut Street,	Philadelphia, Pa.
Dr. Samuel D. Risley,	1728 Chestnut Street,	Philadelphia, Pa.
Dr. Edmund C. Rivers,	1632 Welton Street,	Denver, Col.
Dr. Wm. K. Rogers,	188 East State Street,	Columbus, Ohio.
Dr. Dunbar Roy,	Grand Opera House Block,	Atlanta, Ga.
Dr. John D. Rushmore,	129 Montague Street,	Brooklyn, N. Y.
Dr. Robert Sattler,	30, The Groton,	Cincinnati, Ohio.
Dr. T. B. Schneideman,	1831 Chestnut Street,	Philadelphia, Pa.
Dr. G. E. de Schweinitz,	1705 Walnut Street,	Philadelphia, Pa.
Dr. P. N. K. Schwenk,	810 North 7th Street,	Philadelphia, Pa.
*Dr. N. M. Semple,	Humboldt Building,	St. Louis, Mo.
Dr. John R. Shannon,	25 W. 36th Street,	New York, N. Y.
Dr. Henry L. Shaw,	19 Commonwealth Ave.,	Boston, Mass.
*Dr. H. G. Sherman,	736 Rose Building,	Cleveland, Ohio.
Dr. Wm. A. Shoemaker,	1006 Carlton Building,	St. Louis, Mo.
Dr. Wm. T. Shoemaker,	2031 Chestnut Street,	Philadelphia, Pa.
Dr. E. A. Shumway,	2007 Chestnut Street,	Philadelphia, Pa.

NAME.	RESIDENCE.	PLACE.
Dr. F. D. SKEEL,	147 West 57th St.,	New York, N. Y.
*Dr. F. M. SPALDING,	390 Commonwealth Ave.,	Boston, Mass.
Dr. J. A. SPALDING,	627 Congress Street,	Portland, Me.
Dr. MYLES STANDISH,	6 St. James Avenue,	Boston, Mass.
*Dr. E. W. STEVENS,	421 McPhee Building,	Denver, Col.
Dr. GEORGE T. STEVENS,	22 East 46th Street,	New York, N. Y.
Dr. EDW. STIEREN,	3603 Fifth Avenue,	Pittsburg, Pa.
Dr. SAMUEL B. ST. JOHN,	68 Pratt Street,	Hartford, Conn.
Dr. GEO. STRAWBRIDGE,	202 So. 15th Street,	Philadelphia, Pa.
Dr. T. Y. SUTPHEN,	999 Broad Street,	Newark, N. J.
Dr. WM. M. SWEET,	1205 Spruce Street,	Philadelphia, Pa.
Dr. LEWIS H. TAYLOR,	83 South Franklin Street,	Wilkes-Barre, Pa.
Dr. SAMUEL THEOBALD,	Cathedral & Howard Sts.,	Baltimore, Md.
Dr. CH. HERMON THOMAS,	3634 Chestnut Street,	Philadelphia, Pa.
Dr. A. G. THOMSON,	1426 Walnut Street,	Philadelphia, Pa.
Dr. EDGAR S. THOMSON,	19 E. 44th Street,	New York, N. Y.
Dr. JAS. THORINGTON,	120 South 18th Street,	Philadelphia, Pa.
*Dr. ANDREW TIMBERMAN,	112 East Broad Street,	Columbus, Ohio.
Dr. H. H. TYSON,	47 West 51st Street,	New York, N. Y.
Dr. JOHN VAN DUYN,	318 James Street,	Syracuse, N. Y.
Dr. C. A. VEASEY,	Traders Bank Bldg.,	Spokane, Wash.
Dr. F. H. VERHOEFF,	95 Mountfort St.,	Boston, Mass.
Dr. O. F. WADSWORTH,	526 Beacon Street,	Boston, Mass.
Dr. F. L. WAITE,	68 Pratt Street,	Hartford, Conn.
Dr. DAVID WEBSTER,	308 Madison Avenue,	New York, N. Y.
Dr. J. E. WEEKS,	46 East 57th Street,	New York, N. Y.
*Dr. CASSIUS D. WESTCOTT,	31 Washington Street,	Chicago, Ill.
Dr. J. A. WHITE,	200 E. Franklin Street,	Richmond, Va.
Dr. W. H. WILDER,	103 State Street,	Chicago, Ill.
Dr. CHAS. H. WILLIAMS,	1069 Boylston Street,	Boston, Mass.
Dr. WM. H. WILMER,	1610 I Street, N. W.,	Washington, D. C.
Dr. F. M. WILSON,	834 Myrtle Avenue,	Bridgeport, Conn.
*Dr. J. SCOTT WOOD,	172 Sixth Avenue,	Brooklyn, N. Y.
*Dr. WILLIAM L. WOOD,	412 Oregonian Building,	Portland, Oregon.
Dr. HIRAM WOODS,	842 Park Ave.,	Baltimore, Md.
Dr. J. P. WORRELL,	20 South 7th Street,	Terre Haute, Ind.
Dr. WM. ZENTMAYER,	1819 Spruce Street,	Philadelphia, Pa.
Dr. S. LEWIS ZIEGLER,	1625 Walnut Street,	Philadelphia, Pa.
Total		192

HONORARY MEMBERS.

Dr. JNO. GREEN,	Metropolitan Bldg.,	St. Louis, Mo.
Dr. F. P. SPRAGUE,	229 Commonwealth Ave.,	Boston, Mass.
Whole number		194

Dr. Gustavus Hay

CAT.

NECROLOGY.

DR. GUSTAVUS HAY.

CHAS. H. WILLIAMS, M.D.,

Boston, Mass.

A modest and conscientious physician, beloved by his patients, respected by all who knew him, Gustavus Hay died at his home in Jamaica Plain, April 26, 1908, at the age of seventy-eight. He was prepared for college at the Boston Latin School, entered college when he was fifteen, and after completing the four years' course he petitioned the faculty to be allowed to remain another year, and so graduated with the class of 1850. He then entered the Lawrence Scientific School, graduating with honor in 1853, and for a year was connected with the work of the United States Coast Survey in the south. After this unusual academic preparation he decided to study medicine, and graduated from the Harvard Medical School in 1857. He was soon appointed one of the visiting physicians of the Boston Dispensary, and his attention was first drawn to ophthalmology by being asked to serve as an assistant at the Massachusetts Charitable Eye and Ear Infirmary. In order to thoroughly fit himself for his work he went to Vienna and studied under Arlt, Jaeger and others, and brought home one of the first of the Jaeger ophthalmoscopes to be used in Boston. In Vienna his pleasant and social nature made him a warm friend of other Bostonians studying there, and led to the formation of the Vienna Club in Boston, which has had a continuous existence for forty years, the death of Dr. Hay being the first break in the membership.

The favorite study of Dr. Hay was mathematics; the titles of his contributions to this Society show his liking for this difficult part of ophthalmology, and he was never so happy as when working out some problem or when explaining some difficult

proposition in optics or the higher mathematics, and his natural inclination would have led him to become a teacher of this science. He was one of the most earnest pupils of the late Professor Benj. Pierce, whose instruction gave Dr. Hay such a love for mathematics that it remained a solace and pleasure to him during his whole life.

In 1861 he was appointed to the staff of the Massachusetts Charitable Eye and Ear Infirmary, where he served through 1873, but the hurry and stress of hospital work were not congenial to him, and at his request he was relieved, to be appointed to the consulting staff, where he remained through 1900.

The work of Donders especially interested him, and for some seven years he spent an hour or two nearly every afternoon with one of his Vienna friends in going over the work of the Utrecht professor, and others. In a later trip to Europe he devoted the larger part of his time to operation courses in Paris, to acquire a skill in operative technique. Both his patients and his confrères knew that his work was painstaking and conscientious, and they trusted him. He was very fond of music, and enjoyed the opportunities which his stay in Vienna gave him to cultivate this taste.

In 1863 he married Maria Crehore, who died some twelve years later, and in 1881, Miriam Parsons, who, with one son, survives him. During the last few years of his life he had retired from active practice, and during the last year ill health disabled him, but he retained to the last his interest in ophthalmology and mathematics.

He was a member of the American Academy of Arts and Sciences, and a contribution to its proceedings of a paper entitled, "On a Postulate Respecting a Certain Form of Deviation from a Straight Line in a Plane," shows the choice of his favorite subject. He was also a member of the American Mathematical Society, the Massachusetts Medical Society, the Boston Society for Medical Sciences, and the New England Ophthalmological Society. He was one of the oldest members of the

American Ophthalmological Society, and its vice-president from 1873 to 1878, and at the meetings of the Society we shall miss the presence of this kindly, genial, and scholarly man.

PAPERS BY GUSTAVUS HAY, M.D.

Transactions of the American Ophthalmological Society:

- Refraction of a small oblique pencil of diverging rays by a glass plate with plane parallel surfaces, vol. l, 1866.
- Report on the Progress of Ophthalmology for 1867, vol. i, 1868.
- A Cystotome for the modified linear extraction, vol. i, 1868.
- Inclination of the vertical meridian of the eyeball for the direction of vision upward and outward, vol. i, 1868.
- Apparent movements of muscæ, vol. i, 1869.
- Apparent form of inverted ophthalmoscopic image of optic disc in Astigmatism, vol. i, 1870.
- Variety of forms of small pencils of astigmatic rays, vol. i, 1871.
- Instrument for facilitating section of the optic nerve, vol. ii, 1874.
- On the increase of refractive power of a plano-cylindrical lens when rotated about its axis, vol. ii, 1875.
- On the refraction by a glass plate of an obliquely incident plane pencil whose axis is perpendicular to the intersection of the plane pencil with the first surface of the plate, vol. ii, 1875.
- A case of extensive hemorrhage between choroid and sclerotic, vol. iii, 1882.
- Some additional remarks on the theory of the astigmatic pencil, vol. iii, 1883.
- Two cases in which Rahlmann's hyperbolic lenses improved vision, vol. iii, 1884.
- On the combination of two cylindrical lenses, vol. iv, 1886.
- On the positión of the eyeball during the Listing rotation and the apparent inconsistency between the Donders inclination and the Helmholtz rotation, vol. viii, 1898.

Journal of the Boston Society of Medical Sciences:

- The inclination of the vertical meridian outward, for the right eye looking up and out, not inconsistent with Helmholtz's rotation to the left for the same direction of vision, vol. ii, 1898.
- A curious relation between the positions as given by Weiland, of two linear after-images, studied in connection with the law of Listing, and the corresponding angles of two pairs of great-circle planes, as given by Helmholtz, vol. iv, 1899.

Boston Medical and Surgical Journal:

- A case of chronic glaucoma; iridectomy, vol. lxxi, 1864.
- Some cases of extraction of cataract preceded by iridectomy, vol. lxxi, 1864.
- Extraction of hard cataract, vol. lxxiii, 1865.
- A case of astigmatism, vol. lxxv, 1867.
- Two cases in ophthalmic practice, vol. lxxx, 1869.
- Defects of ocular refraction, accommodation and convergence, and their treatment by spectacles and otherwise, vol. lxxxiii, 1870.
- Cases of chronic entropion and trichiasis of the upper lid, resulting from granular ophthalmia, vol. xc, 1874.
- The combination of cylinder lenses, vol. cxv, 1886.
- Removal of foreign body from the anterior chamber of the eye, vol. cxxx, 1894.

Archives of Ophthalmology:

Special application to the case of the eye of Knapp's general formulæ for astigmatic rays, vol. ii, 1871.

On the analytical conditions of that form of astigmatic pencil in which the two focal lines are perpendicular each to the axis of the pencil and also to each other, and on the correction of such pencil by a plano-cylindrical lens, vol. v, 1876.

DR. DANIEL BENNETT ST. JOHN ROOSA.

J. B. EMERSON, M.D.,

New York.

In the death of Dr. Daniel Bennett St. John Roosa, which occurred on March 8, 1908, at his home, 20 East 30th Street, New York city, the American Ophthalmological Society has lost one of its oldest and most valued members, one who always had the best interests of the Society at heart. The most appropriate memorial which can be given is a review of his life's work, which space compels to be incomplete.

Dr. Roosa was a native of New York State. He was born on April 4, 1838, descendant of a long line of Colonial ancestors, all of his great-grandfathers being officers in the Continental army. At the age of eighteen he entered Yale, but was obliged to leave on account of ill health. A year later he entered the Medical Department of the University of New York, from which institution he received his degree of M.D. in 1860. He then became assistant to the house surgeon at the New York Hospital. In 1861 he served three months as assistant surgeon to the Fifth Regiment N. G. S. N. Y., and at the termination of his enlistment he returned to the New York Hospital and completed his term of service as house surgeon. He then spent a year in Europe, studying in the clinics of Berlin and Vienna. In 1863 he again volunteered with the 12th Regiment N. G. S. N. Y., and when he had completed his term of service he engaged in private practice in New York city, devoting his attention exclusively to ophthalmology and otology. For eighteen

Dr. Daniel Bennett St. John Rocha.

years he was professor in these branches in the University of New York. For five years he held a similar position in the University of Vermont. From 1883 till his death he taught ophthalmology and otology in the New York Post-Graduate Medical School and Hospital, making nearly forty-four years of continuous teaching. During his lifetime he held the following offices: President of New York State Medical Society, American Otological Society, International Otological Society, Academy of Medicine, and twice president of the New York Ophthalmological Society. He was one of the founders of, and surgeons in, the Manhattan Eye and Ear Hospital of New York, and the Brooklyn Eye and Ear Hospital, Brooklyn.

Dr. Roosa was an enthusiastic believer in the necessity of post-graduate medical instruction, and in 1883 he and his associates founded the New York Post-Graduate Medical School and Hospital, of which institution he was president up to the time of his death. Dr. Roosa had two honorary degrees conferred upon him, that of M.A. by Yale and LL.D. by the University of Vermont. He was the author of a number of text-books on ophthalmology and otology, and, in addition, a translator of several works from the German and a frequent contributor to the medical journals. He took a keen interest in public affairs and always used his best endeavors toward advancing the cause of humanity and in elevating the standard of medicine. His death was sudden and painless. As he had so often expressed the desire, he died at his post, without one faculty being impaired.

DR. WILLIAM THOMSON.

GEORGE C. HARLAN, M.D.,

Philadelphia.

The Society has lost a prominent and influential member in the death of Dr. William Thomson. He became a member of the Society in 1870, always felt an enthusiastic interest in it, and has made original and valuable contributions to its transactions.

Dr. Thomson was of Scotch-Irish descent and was born in Chambersburg, Pa., January 28, 1833. He attended school in his native town, was graduated in medicine at Jefferson College in 1855, and entered into general practice in Merion, a suburb of Philadelphia. He was married to Miss Rebecca George, of Merion, Pa., in 1857.

When the Civil War broke out, he entered the United States regular army as assistant surgeon, and in 1862 served as chief of staff to Dr. Letterman, General McClellan's medical director, on the Peninsula and at Antietam. After the battle of South Mountain he organized division hospitals on a plan that was afterward generally adopted throughout the army. In 1863 he was in charge of the Douglass Hospital, in Washington, which became known as a model one, and in 1864 he was appointed inspector of the Washington hospitals.

After passing his second examination, in 1866, he was promoted to the rank of captain, and was subsequently breveted major for faithful and meritorious service. In the meantime he kept up an active interest in the scientific side of his profession, made many contributions to the Army Medical Museum, and, with Dr. William F. Norris, spent much time in the development of photography as a means of recording the appearances of wounds and pathological conditions, and in experiments in microscopic photography.

These studies in optics were the beginning of his interest in

Dr. William Thomson

that special work to which his subsequent life was devoted with so much success. His first practical observation in refraction was the discovery that, on account of his high hyperopia (+5), he could read with much less discomfort by contracting his pupils with a candle flame held between his eyes and the book, which he did habitually until he learned enough to properly correct his refraction with a glass.

When he resigned from the army, in 1868, he settled in Philadelphia, and soon afterward took up the study and practice of ophthalmology, rapidly acquiring a large and lucrative practice.

His first important publication was a paper in the "American Journal of Medical Sciences," January, 1878, on the Scheiner experiment with the perforated disc, with the description of an instrument for utilizing it as a practical test in refraction. Later he invented an instrument for testing refraction by means of circles of diffusion. Both of these instruments are fully described by Landolt in his work on the "Refraction and Accommodation of the Eye" (1886, p. 246). They are scientific and ingenious, and may still be sometimes found practically useful even in these days of skiascopy, ophthalmometry, etc.

He was associated with Mitchell in his epoch-making publications calling attention to the effect of eyestrain as a cause of headache and other nervous disturbances. Though these papers may seem trite to-day, now that the subject has been exploited almost *ad nauseam*, when we remember that they were published thirty-five years ago their originality and importance are evident enough.

Dr. Thomson was a strong advocate of the use of mydriatics in refraction and of full correction. He had advanced views on the subject of full correction, and was one of the first to recommend it in myopia. His patience, perseverance, and skill in refraction were shown by his success in the correction of cases of conical cornea by sphero-cylinders and his opinion was that many of such cases may be better managed in this way than by operation. He was a pioneer in refraction, and the reputation for

careful and accurate work in this field enjoyed by the "Philadelphia school" in the early days of modern ophthalmology was largely due to his influence upon the ophthalmic surgeons and opticians of that city.

The most important of Dr. Thomson's other work was in connection with the detection of color blindness. His "color-stick" for worsteds and his color test lantern are well known to ophthalmic surgeons and railroad men. The former is in use by a large number of roads in this country, controlling more than 100,000 miles of track, and has also been used by several English roads.

Dr. Thomson held at various times the official positions of Assistant Surgeon, U. S. A., Attending Physician to the Protestant Episcopal Hospital, Attending Surgeon to the Wills Eye Hospital, lecturer, honorary professor, professor, and emeritus professor of ophthalmology in Jefferson Medical College, and Ophthalmic Surgeon to the Pennsylvania Railroad. He was a member of the American Ophthalmological Society, the Philadelphia College of Physicians, the American Philosophical Society, the Academy of Natural Sciences, the New York Neurological Society, and the Loyal Legion. He had a prominent, useful, and successful career. His scientific work and his comradeship will be missed in the Society. He had an attractive personality, a keen sense of humor, and an original way of putting things that made him an entertaining and instructive companion.

The following bibliography of Dr. Thomson's principal contributions to ophthalmology is from the memorial of Drs. Mitchell and de Schweinitz, read at a recent meeting of the Philadelphia College of Physicians, to which I am also indebted for some other data of his career.

Chapter on Diseases of the Eye in Gross' "Surgery" (fifth edition).
Test for diagnoses of ametropia, with instrument.
Ophthalmoscope in diagnosis of intracranial lesions.
History of first case of tumor of brain diagnosticated with the Ophthalmoscope in Philadelphia.

Dr Richard Henry Derby

CAL

Astigmatism as a cause of persistent headache (with Mitchell).
Connection between posterior staphyloma and astigmatism.
Correction of conical cornea by sphero-cylindrical glasses.
Rapid diagnoses of refraction with a new instrument.
System adopted by the Pennsylvania Railroad in 1880 for examination of employees for color-blindness, vision and hearing, with instruments, color-stick, etc.
Supplement to Nettleship on Diseases of the Eye.
Edition of ophthalmological part of Annual of Medical Sciences (1889).
New wool test for detecting color-blindness.
Normal color sense and detection of color-blindness in Norris and Oliver's System.
Chapter on diseases of eye in "American Text-Book of Surgery."
Relation of ophthalmology to practical medicine.
Use of circles of diffusion for correcting ametropia, with an instrument.

DR. RICHARD HENRY DERBY.

WALTER E. LAMBERT, M.D.,

New York

Dr. Richard Henry Derby, whose death occurred on July 4, 1907, was born in Boston in 1844. He was graduated from Harvard in 1864 and from the Harvard Medical School in 1867. He served as house surgeon in the Massachusetts General Hospital, and subsequently went to Germany to further his studies. He was a pupil of the distinguished German ophthalmologist, Prof. Von Graefe, and acted as his assistant during his stay abroad.

In 1870 he returned to America and started the practice of medicine in New York city. He was appointed clinical assistant in the New York Eye and Ear Infirmary in 1871, assistant surgeon in 1873, and surgeon in 1874. At the time of his death he was the executive surgeon of that institution, and also a member of the Board of Directors.

Dr. Derby has been a member of the American Ophthalmological Society since 1871. He was a member of the New York Academy of Medicine and New York Ophthalmological Society, consulting ophthalmologist of the Orthopedic Hospital and Trinity Hospital, one of the consulting physicians in

the Hospital for Scarlet Fever and Diphtheria, and a trustee of the New York Institution for the Blind.

He was a man of great public spirit and prominent in many of the civic movements of the times. He was a member of the counsel of the Charity Organization Society and State Charities Aid Association, and consulting ophthalmologist of the Health Department. He was also a member of the Committee of Twenty-one in 1881, which met to reform the street-cleaning system, and a member of the Committee of Seventy in 1894. He was also a vestryman in Trinity Church, New York city.

Dr. Derby's wide experience as an ophthalmologist, his genial manner, as well as his staunch integrity, gained for him the respect and esteem of all with whom he came into contact, whether professionally or socially, and his loss is and will continue to be deeply felt.

MINUTES OF THE PROCEEDINGS.

FORTY-FIFTH ANNUAL MEETING.

THE GRISWOLD,

New London, Conn., July 14, 1909.

The Forty-fifth Annual Meeting of the Society was called to order at 10 A. M. by President Dr. S. B. St. John, and the following Committees were announced:

On Membership—Drs. MYLES STANDISH, D. HARROWER, D. W. HUNTER, E. GRUENING, and G. E. DE SCHWEINITZ.

Auditing Committee—Dr. W. E. LAMBERT.

The question was raised whether the papers appearing in the presessional volume, whose authors were not at the meeting to present them, should be considered as before the Society for discussion, or if they should be ignored. On motion of Dr. Randolph, it was voted that they should be ignored and not published in the Transactions.

The following papers were read and discussed:

1. "A classification of eye diseases," Dr. Alexander Duane.

2. "The adverse influence of diabetes in certain operations on the eye," Dr. Charles Stedman Bull.

Discussed by Drs. Thorington, Hansell, Ziegler, de Schweinitz, Callan, Howe, Kipp, Randolph, Theobald, Carmalt, and Bull.

3. "Summary of results obtained, and features of interest, in two hundred and fifteen consecutive cataract extractions," Dr. Samuel Theobald.

Discussed by Drs. Webster, Sutphen, Woods, Kipp, Greenwood, Rider, Callan, Reik, Prout, and Theobald.

4. "The choice of operation for iridotomy," Dr. McCluney Radcliffe.

Discussed by Drs. Callan, Schwenk, de Schweinitz, Hansell. Ziegler, Howe, Kipp, Webster, St. John, Johnson, Theobald, and Radcliffe.

5. "The treatment of the eye when the globe is infected, with the object of preventing panophthalmitis," Dr. A. E. Davis.

Discussed by Drs. Duane, Ziegler, and Davis.

6. "Third series of cases of injuries from foreign bodies examined by the Roentgen rays, with results of operation," Dr. Wm. M. Sweet.

Discussed by Drs. Bull, Kipp, Callan, H. W. Ring, Johnson, Radcliffe, Theobald, Ziegler, and Sweet.

Drs. Carl Fisher, A. H. Little, and Oscar Diem were invited to sit as guests of the Society and take part in the discussions.

Afternoon Session.

The first part of the session was devoted to the exhibition of instruments.

Dr. Charles H. Williams exhibited a new lantern for testing the color sense.

Dr. Alexander Duane showed a disc for measuring the near point and the range of the accommodation.

Dr. Lucien Howe presented a new model of perimeter.

Dr. Wm. M. Sweet exhibited a new apparatus for the *x*-ray localization of foreign bodies in the eye.

Dr. A. E. Ewing presented an instrument for everting the eyelid and holding it in position for incision; also a guarded knife.

Dr. M. H. Post exhibited a knife for cutting secondary membranes.

The reading of papers was resumed.

7. "Physical economics," Dr. E. E. Holt.

8. "Spontaneous rupture of the eyeball, report of a case," Dr. Jas. W. Ingalls.

Discussed by Drs. Libby, Verhoeff, Butler, Sweet, and Woods.

9. "Adenocarcinoma of the pituitary body, report of a case under observation for four and a half years, pathological examination," Dr. Wm. T. Shoemaker.

Discussed by Drs. Duane, Zentmayer, Cutler, Post, and Shoemaker.

10. "Report of a case of sarcoma and bone formation in an atrophic eye, with presentation of specimen," Dr. Dunbar Roy.

11. Metastatic carcinoma of the orbit, with report of a case," Dr. Edw. A. Shumway.

Discussed by Drs. Kipp and Howe.

12. "Orbital fibroma, with unusual clinical manifestations," Dr. G. Oram Ring.

Discussed by Drs. Posey, de Schweinitz, Cutler, and Ring.

13. "Symmetrical lymphomata of the lachrymal and salivary glands (Mikulicz's disease)," Dr. S. Lewis Ziegler.

Discussed by Drs. Cutler, Posey, and Ziegler.

14. "A case of complete albinism; observations on the changes in the diameters of the lens as seen through the iris," Dr. Geo. F. Libby.

Discussed by Drs. Theobald and Libby.

15. "A case of bilateral macular coloboma," Dr. H. F. Hansell.

Morning Session, July 15th.

16. "Hemorrhagic central chorioretinitis in non-myopic eyes, clinical contribution," Dr. Charles J. Kipp.

Discussed by Drs. Ring and Kipp.

17. "Angioid streaks in the retina, with the report of a case," Dr. W. Zentmayer.

18. "Concerning a form of retinal disease with extensive

exudation; being a clinical contribution, with the report of two cases," Dr. Geo. E. de Schweinitz.

Discussed by Drs. Duane and Verhoeff.

19. "Neuroretinitis in chlorosis, with report of a case," Dr. Wm. Campbell Posey.

Discussed by Drs. Verhoeff, de Schweinitz, and Greenwood.

20. "The differentiation of the diphtheria bacillus from organisms morphologically similar," Dr. Carl Fisher.

Discussed by Drs. Verhoeff and Fisher.

21. "Tropometers and measurements of Arcs of Rotation," Dr. Lucien Howe.

Discussed by Drs. Stevens and Howe.

22. "Improved apparatus for locating foreign bodies in the eyeball by the Roentgen rays," Dr. Wm. M. Sweet.

Discussed by Dr. E. E. Holt.

Executive Session, Wednesday Evening, July 14th.

The President, Dr. S. B. St. John, presiding.

The President announced the death, during the year, of Dr. C. E. Rider.

The Report of the Committee on Memorials was called for, and on motion of Dr. Carmalt the Committee was given leave to print the memorials prepared in the Transactions for this year. Dr. Carmalt further moved that photographs of the deceased members, if obtainable, be also put in with the memorials, which motion was carried.

The Treasurer's report was read, and the Auditing Committee having certified it, Dr. Carmalt moved that it be accepted and placed on file, which was voted upon in the affirmative.

On motion of the Secretary it was voted that the assessment for next year be five dollars.

The Committee on Membership recommended the following candidates for admission to the Society:

Dr. L. W. Callan, New York City.

Dr. G. H. Burnham, Toronto, Canada.

Dr. M. L. Foster, New York City.
Dr. R. G. Loring, Boston.
Dr. T. B. Holloway, Philadelphia.
Dr. N. M. Semple, St. Louis.
Dr. F. M. Spalding, Boston.
Dr. Geo. S. Derby, Boston.
Dr. Jas. Bordley, Jr., Baltimore.

On motion of Dr. Carmalt the candidates recommended by the Committee were declared elected as Associate Members.

The Committee also referred the names of a number of candidates to the Committee for 1910.

The Executive Committee reported the following nominations for officers of the Society:

President—Dr. Samuel Theobald, Baltimore.
Vice-President—Dr. Emil Gruening, New York City.
Secretary and Treasurer—Dr. Wm. M. Sweet, Philadelphia.
Corresponding Secretary—Dr. Arnold Knapp, New York City.
Publication Committee: Dr. W. S. Dennett, Dr. D. W. Hunter, Dr. Wm. M. Sweet.

Dr. Carmalt moved that the Secretary be empowered to cast the ballot for the nominees, which motion was carried, and the officers declared duly elected.

The Secretary read the names of candidates for membership, and they were referred to the Membership Committee for 1910.

The Report of the Committee on Nomenclature was called for, and Dr. Alexander Duane, Chairman, reported that no meeting of the Committee had been held, but that as a member of the Committee he had done individual work, the result of which was presented in his paper.

Dr. Carmalt moved that the Committee be continued to take up the work, if it should come into their hands through official channels, which motion was carried.

Dr. Lucien Howe, Buffalo, moved that the last clause of Sec. 5, of the By-Laws, which reads as follows, "any member or associate being absent from regular meetings for three consecu-

tive years and without valid excuse, shall be dropped from the roll, honorary members being excepted; this By-Law shall be printed in every call for the annual meeting," be modified by the insertion of the following after the word "excepted":

"The term 'valid excuse' shall count in illness of the member, or of some of his immediate family, or of the absence of the member from the country. This part of the By-Laws shall be printed in every call for the annual meeting."

Dr. Howe also offered the following modification of the clause in the Transactions of May 9, 1907, which exempts all members of twenty years' standing from the Section of the By-Laws regarding attendance:

"Any member of twenty years' standing may, if he is desirous, claim exemption from attendance, from presentation of papers, or from any penalty mentioned in the By-Laws, except the payment of his annual dues. If he does claim such exemption, however, he shall be classed as a 'senior' or 'emeritus' member, and another active member may be elected in his place."

Dr. Geo. E. de Schweinitz, Philadelphia, moved the reconsideration of the action of the Society last year in appointing a Business Committee to prepare a presessional volume, etc., which motion was carried.

Dr. Wm. M. Sweet, Philadelphia, offered the following substitute for No. III of Standing Rules:

"The Secretary shall, two months before the date of meeting, send a request to each member to forward within four weeks the title of such papers as he desires to present at the next meeting of the Society, with a brief abstract of the same. Such titles shall be incorporated by the Secretary in the printed call for the meeting. No paper shall be eligible for presentation at the meeting of the Society unless the title and an abstract of the paper be printed in the call for the meeting. This rule shall not apply to the exhibition by any member of new instruments or apparatus."

This motion was seconded by Dr. de Schweinitz, and adopted.

The Secretary read a letter from Dr. Sidney Yankhauer, New York, calling attention to the twenty-fifth anniversary of the introduction of cocain by Dr. Carl Koller.

Dr. Howe moved that the letter be referred to a committee of three to report later, of which committee the President of the Society should be chairman. The motion prevailed and the President announced that he would appoint the committee later.

The Secretary read a letter from the Secretary of the Congress of American Physicians and Surgeons regarding the program for the meeting to be held in Washington, D. C., May 3 and 4, 1910, which, on motion, was referred to the incoming President.

The Executive Session then adjourned.

Executive Session, Thursday Morning, July 15th.

The President, Dr. S. B. St. John, presiding.

Dr. Lucien Howe, Buffalo, presented the report of the committee appointed to consider the matter of the twenty-fifth anniversary of the discovery of cocain by Dr. Carl Koller, offering the following resolution:

"*Whereas*, it is now a quarter of a century since the discovery of the anesthetic properties of cocain, and, *Whereas*, during these years its value has been proved by the relief from pain given to thousands of persons in all parts of the world, especially those suffering from diseases of the eye, and, *Whereas*, the operative methods of all ophthalmic and other surgeons have thus been much facilitated and their results rendered far more satisfactory;

"*Therefore*, as a Society, we desire to place on record our appreciation of the great value of this agent, and our indebtedness to its discoverer, Dr. Carl Koller, of New York, and we hereby empower our Secretary to join with the Secretaries of other similar National Societies in transmitting to Dr. Koller our thanks for this boon conferred on mankind and for the advance thus made in the science of ophthalmology."

On motion of Dr. Walter B. Johnson, the report was accepted and adopted.

Dr. Howe presented his amendment offered at the previous Executive meeting to change Sec. 5 of the By-Laws.

On motion of Dr. Walter B. Johnson it was laid upon the table.

The Executive Session then adjourned.

At the close of Thursday morning's session Dr. Carmalt moved that the Society go into Executive Session, which was accordingly done.

Dr. Carmalt moved that the Secretary be authorized to have printed a new copy of the Constitution and By-Laws, incorporating all the new regulations up to the present time.

Dr. Howe amended the motion to further instruct the Secretary to change the numbering of the Sections, which was accepted, and the amended motion carried.

In regard to the illustrations made to accompany papers not read at the meeting, Dr. Posey moved that the authors of the papers pay the cost of type-setting and the making of the cuts, and that reprints of the articles be furnished them, if desired, at the usual rates, which motion was carried.

The Session then adjourned.

Members present at the Forty-fifth Annual Meeting:

ADAMS, A. E.
BELL, G. H.
BULL, CHARLES S.,
BUTLER, W. K.
CALLAN, P. A.
CARMALT, W. H.
CHENEY, F. E.
COGGIN, DAVID
CRAIG, W. G.
CURDY, R. J.
CUTLER, C. W.
DAVIDSON, J. P.
DAVIS, A. E.
DUANE, ALEXANDER
DUNCAN, J. A.
EWING, A. E.
FOX, W. H.
FRIDENBERG, PERCY
GREENWOOD, ALLEN
HALE, G. W.
HANSELL, H. F.
HARROWER, DAVID
HOLDEN, WARD
HOLT, E. E.
HOWE, LUCIEN
HUNTER, D. W.
INGALLS, J. W.
JOHNSON, W. B.
KENNON, B. R.
KILBURN, H. W.
KIPP, CHARLES J.
LAMBERT, W. E.
LANCASTER, W. B.
LIBBY, G. F.
MCILWAINE, C. H.
MAY, C. H.
MILES, H. S.
PAYNE, S. MCA.
PHILLIPS, R. J.
POSEY, WM. CAMPBELL
POST, M. H.
PRICE, H. R.
PROUT, J. S.
RADCLIFFE, MCCLUNEY
RANDOLPH, R. L.
REIK, H. O.
RIDER, WHEELOCK
RING, G. ORAM
RING, H. W.
ROY, DUNBAR
SCHNEIDEMANN, T. B.
DE SCHWEINITZ, G. E.
SCHWENCK, P. N. K.
SHANNON, J. R.
SHOEMAKER, WM. T.
SHUMWAY, E. A.
STANDISH, MYLES
STEVENS, G. T.
ST. JOHN, S. B.
SUTPHEN, T. Y.
SWEET, WM. M.
THEOBALD, SAMUEL
THORINGTON, JAMES
TIMBERMAN, ANDREW
TYSON, H. H.
VERHOEFF, F. H.
WAITE, F. L.
WILLIAMS, C. H.
WILSON, F. M.
WOODS, HIRAM
ZENTMAYER, W.
ZIEGLER, S. LEWIS

A CLASSIFICATION OF EYE DISEASES.

WITH THE OUTLINE OF A UNIVERSAL MORBIDITY LIST BASED ON THE NOMENCLATURE OF DISEASES OF THE ROYAL COLLEGE OF PHYSICIANS, OF LONDON.*

ALEXANDER DUANE, M.D.,

New York.

From many points of view it is of great importance to have a correct and uniform arrangement, classification, and nomenclature of diseases. If the arrangement and classification are not uniform, the tables compiled by hospital statisticians and health officers cannot be compared with each other. And if the nomenclature is not uniform, so that different men use different terms to denote the same morbid condition, or the classification is not uniform, so that some include under one term conditions which by others are separately enumerated, then not only is the compilation of correct statistics made difficult or impossible, but a considerable difficulty is thrown in the way of the student of medical literature, who can never be certain that the condition which an author is describing is that which he knows under the same name.

To make a classification that shall be universally acceptable is a difficult, perhaps an insurmountable, task. A classification which is suitable for the purposes of the health officer is not usually the best for hospital returns. A health officer, for instance, finds it important to separate injuries due to accident from those inflicted with homicidal or suicidal intent. To a hospital statistician such a distinction is not only needless but confusing. Again, a classification concerned with mortality

* The variations in the customary spelling of a number of the medical terms which occur in this paper are those suggested by the Committee on Nomenclature of the American Medical Association, and are permitted to remain unaltered at the request of the author.

statistics is necessarily very different in scope and character from one devoted to morbidity returns. Lastly, a classification suitable for a general hospital is usually insufficient for the needs of the specialist.

What we demand of a classification is that it shall be comprehensive—including all known morbid conditions; that it shall admit of expansion, so that additions can be made at any time without deranging it; that it shall also admit of contraction, so as to be abbreviated to any desired extent without essentially changing its character; and, finally, that it shall adhere throughout to a consistent plan.

Of a nomenclature we demand that the terms shall be such as are universally recognized, properly formed, and definite in meaning. Obsolete and, more particularly, ill-defined terms should be dropped. Indeed, any nomenclature should comprise as one of its most valuable parts an "index expurgatorius," showing what terms not to use.

For mortality statistics the "International Classification" is fast superseding all others. It is not, however, very suitable for morbidity statistics. For these perhaps the best system is that offered by the "Nomenclature of Diseases" prepared by the College of Physicians of London. This is a universal list comprising 1244 titles. It is arranged with great care and elaboration, and in most regards is admirably suited to its purpose. Its main defects are, first, that it is not altogether consistent in its arrangement, so that the reader is sometimes left in doubt as to how he should enter certain terms.* Again, it is not flexible, in that no provision is made for expansion. Not a single term, in fact, could be added to it without deranging the whole classification.

The present author has endeavored to frame the skeleton of a "Universal Morbidity List," which, based on the London "Nomenclature," shall be free from these defects of the latter. And he has also made, as an excerpt from this "Universal List,"

* For example, "trichiniasis."

a classification of eye diseases, which is here subjoined. This latter will be better understood if the principles governing the formation of the "Universal List" are fully explained.

The author may add that both lists were formulated as part of his work in connection with the Committee on Nomenclature of the American Medical Association. The chairman of this committee, Dr. Frank P. Foster, has described the general principles of the classification in his report, and has appended to the latter as an exhibit the classification of eye diseases here given.

The "Universal List" comprises 21 sections, as follows:

I. GENERAL DISEASES.

II–XXI. LOCAL DISEASES.

II. *Diseases of the Nervous System.*

1. Diseases of the nerves.
2. " " " spinal meninges.
3. " " " spinal cord.
4. " " " meninges of the brain.
5. " " " brain.
6. Miscellaneous and unclassed nervous diseases.
7. Psychoses.

III. *Diseases of the Eye.*

10. Diseases of the conjunctiva.
11. " " " cornea.
12. " " " sclera.
13. " " " iris and ciliary body
14. " " " chorioid.
15. " " " retina.
16. " " " optic nerve.
17. " " " lens.
18. " " " vitreous.
19. " " " eyeball as a whole.
20. " " " lids.
21. " " " lacrymal apparatus.
22. " " " eye muscles.
23. " " " orbit.

IV. *Diseases of the Ear.*

25. Diseases of the auricle and external meatus.
26. " " " middle ear and mastoid cells.
27. " " " internal ear and auditory nerve.

V. *Diseases of the Nose.*

30. Diseases of the nose.
31. " " " accessory sinuses.
32. " " " naso-pharynx.

VI. *Diseases of the Circulatory System.*

35. Diseases of the pericardium.
36. " " " endocardium.
37. " " " myocardium.
38. " " " arteries.
39. " " " veins.
40. " " " capillaries.

VII. *Diseases of the Respiratory System.*

45. Diseases not strictly local.
46. " of the larynx.
47. " " " trachea and bronchi.
48. " " " lungs.
49. " " " pleura.

VIII. *Diseases of the Digestive System.*

55. Diseases of the lips.
56. " " " mouth.
57. " " " jaws.
58. " " " teeth.
59. " " " periosteum, gums, and alveoli.
60. " " " tongue.
61. " " " palate and fauces.
62. " " " salivary glands.
63. " " " pharynx and œsophagus.
64. " " " stomach.
65. " " " intestines.
66. " " " rectum and anus.
67. " " " pancreas.
68. " " " liver.
69. " " " gall-bladder and ducts.
70. " " " peritonæum.

IX. *Diseases of the Lymphatic System.*

75. Diseases of the spleen.
76. " " " lymph-glands.
77. " " " lymphatic vessels.

X. *Diseases of the Ductless Glands.*

80. Diseases of the thymus.
81. " " " thyreoid gland and parathyreoids.
82. " " " suprarenals.
83. " " " pituitary body.

XI. *Diseases of the Urinary System.*

85. Diseases of the kidney.
86. " " " ureters.
87. " " " bladder.
88. Urinary disorders.

XII. *Diseases of the Male Genitals.*

90. Diseases of the urethra.
91. " " " prostate.
92. " " " seminal vesicles.
93. " " " prepuce.
94. " " " penis.
95. " " " scrotum.
96. " " " spermatic cord.
97. " " " tunica vaginalis.
98. " " " testicle.

XIII. *Diseases of the Female Genitals.*

100. Diseases of the ovary.
101. " " " fallopian tube.
102. " " " uterine ligaments and adjacent structures.
103. " " " uterus.
104. " " " vagina.
105. " " " vulva.
106. Miscellaneous and unclassed symptomatic disorders.

XIV. *Affections Connected with Pregnancy.*

110. Accidents and complications of pregnancy.
111. Ectopic gestation.

XV. *Affections Connected with Parturition.*

115. Affections of the uterus.
116. " " " vagina.
117. " " " vulva.
118. " " " urinary bladder.
119. " " " perinæum.
120. Abnormities of placenta.
121. Other affections.

XVI. *Affections Consequent on Parturition.*

125. Puerperal affections of uterus.
126. " " " pelvis.
127. " " " vagina.
128. " " " perinæum.
129. " " " bladder.
130. " " " rectum.
131. " " " breast.
132. " " " nervous system
133. " " " producing general disorders (pyæmia, septicæmia).
134. Other puerperal affections.

XVII. *Diseases of the Female Breast.*

140. Diseases of the nipple and areola.
141. " " " mammary gland.

XVIII. *Diseases of the Male Breast.*

144. Diseases of the male breast.

XIX. *Diseases of the Organs of Locomotion.*

145. Diseases of bone.
146. " " joints.
147. " " the spine.
148. " " muscles.
149. " " fasciæ.
150. " " tendons.
151. " " sheaths of tendons.
152. " " bursæ.

XX. *Diseases of Connective Tissue.*

160. Diseases of connective tissue.

XXI. *Diseases of the Skin.*

165. Diseases of skin proper.
166. " " sebaceous glands.
167. " " sweat coils and ducts.
168. " " hair and hair follicles.
169. " " the nails.

All titles denoting a morbid condition bear a *title letter* indicating the general nature of the morbid condition, as follows:

I. GENERAL DISEASES.

(To be reported under Section I.)

A. Infectious conditions (due, in general, to protozoa, bacteria, or fungi).
B. Zoöparasitic affections.
C. Diathetic diseases (disorders of nutrition or metabolism).
D. Chronic intoxications.
E. Injuries.
F. Tumors.
G. Congenital anomalies.

II. LOCAL DISEASES.

(To be reported under the names of the organs affected, Nos. 1–169, Sections II–XXI, above.)

H. Circulatory disturbances.
   1. Anæmia.
   2. Hyperæmia.
   3. Œdema.
   4. Hæmorrhage.
   5. Embolism and thrombosis.
   6. Angiosclerosis.
   7. Disturbances of lymph circulation.
   8. Other disorders of this class.

I. Inflammation (classed as catarrhal, purulent, serous, fibrinous, membranous, parenchymatous, interstitial or fibrous, etc., according to the character of the part affected).

Note.—Specific inflammations (erysipelatous, syphilitic, tuberculous, gonorrhœal, and diphtherial) are not to be listed under the local affections but under the corresponding general diseases (A).

J. Atrophy, hypertrophy, and degeneration.
The degenerations comprise:
a. Cloudy swelling. Syn.: Granular degeneration.
b. Fatty degeneration.
c. Calcareous degeneration.
d. Fibrous degeneration.
e. Mucous or myxoid degeneration.
f. Colloid degeneration.
g. Hyaline degeneration.
h. Amyloid (Waxy, Lardaceous) degeneration.
i. Pigmentary degeneration.
j. Other forms of degeneration.

K. Local death. Necrosis and mortification.

L. Mechanical lesions (acquired malformations not directly due to injury). Such are:
a. Absence of parts.
b. Dislocation or malposition.
c. Abnormal connection with adjacent parts (adhesion).
d. Abnormal separation from adjacent parts or abnormal division (laceration, rupture).
e. Diminution in size (especially, contraction of a hollow organ), stricture of a tube or occlusion by concretions.
f. Increase in size (especially, dilatation of a hollow organ).
g. Change in shape.
h. Other conditions of this sort.

M. Disorders of functions, comprising:
a. Excess of action (hypertony of a muscular organ, excess of secretion in a secreting part, excess of sensation in a sensory organ).
b. Deficiency of action (hypotony, undersecretion, hypæsthesia).
c. Absence of action.
d. Perversion of normal action.

N. Disorders unclassed or of uncertain nature.

The special nature of the morbid process is denoted by a *species number* following the title letter. Thus A being the title letter for an infectious disease in general, the special infectious disease syphilis is denoted by A 380. So the special diathetic affection diabetes is denoted by C 30; chronic alcoholism by D 5; etc.

In the case of local diseases the proper *title number* (1 to 169) is prefixed to the title letter (H to N) and serves to show the part affected. Thus 10, H means a circulatory disorder of the conjunctiva and 10, H 2 hyperæmia of the conjunctiva; 10, I means conjunctivitis; 11, J degeneration of the cornea, etc. The presence of this title number, then, indicates that the condition in question is local and is to be listed under the name of the part affected.

In the case of general diseases the title letter (A to G) is not preceded by a title number—the absence of the latter indicating that the affection is not local, and is not to be listed as such even if confined to a single organ. Thus tuberculosis of the conjunctiva is to be listed under tuberculosis (A 450), not under 10 (Diseases of the Conjunctiva), the entry reading A 450 Tuberculosis of the Conjunctiva.

So also an injury of the conjunctiva is not entered under 10, but under the general head E ("Injuries").

Such titles indicating a general affection of a special part may for the sake of convenience be recapitulated under the name of the part affected, but always with the statement that they do not belong here and are to be referred to the proper portion of the general list.*

The title letters, title numbers, and species numbers serve to identify the morbid condition, indicating its nature and showing

* If for some special reason it seems desirable to group all the diseases of the conjunctiva together, then under 10 ("Diseases of the Conjunctiva") a series of heads are made as follows:

10, A. Infectious diseases of conjunctiva.
— 60 Diphtheria of conjunctiva.
—450 Tuberculosis of conjunctiva, etc.
10, B. Zoöparasitic diseases of conjunctiva.
— 10 Cysticercosis of conjunctiva.
— 20 Ecchinococcosis of conjunctiva.
— 25 Filariasis of conjunctiva, etc.
10, C. Diathetic affections of conjunctiva, etc.
10, D. Toxic conditions of conjunctiva.
10, E. Injuries of conjunctiva.
10, F. Tumors of conjunctiva.
10, G. Congenital anomalies of conjunctiva.

And similar heads are made for the sclera (11), cornea (12), etc.

its precise place in the classification. They remain invariable* no matter how much the classification itself may, for special purposes, be expanded or contracted. Thus, in the accompanying list, which is designed to comprise only diseases of the eyes, the list numbers and letters are the same as in the Universal List. In this special list Part I corresponds to Section I of the Universal List, greatly abbreviated; Part II to Section III of the Universal List; while such few excerpts from the remaining sections of the latter as would be used in the reports of an eye hospital are grouped under Parts III and IV. Reference from one part of the list to another is made by enclosing the proper title letter and number in parenthesis. Thus (A 450) following a title means that that title is to be entered under Tuberculosis (in general list A). In the accompanying list all such parenthetic entries containing title letters A to G (without a title number) refer to Part I; all containing title numbers 10 to 23 refer to Part II; and all containing title numbers 1 to 7 and 25 to 169 refer to Part III.

The list as presented may seem to many much too elaborate and detailed. Yet for many purposes great elaboration and extreme minuteness of detail are an advantage, and in some cases they are really essential. And those who demand a more compendious classification can condense the list to any desired extent—the reference letters and numbers being retained unchanged. An example of such an abridged classification, comprising diseases of the conjunctiva and cornea, is appended.

10. *Diseases of the Conjunctiva.*

10, I. Conjunctivitis.
- 1*a*. Acute catarrhal (not exanthematous, traumatic, or toxic).
- 1*b*. Chronic catarrhal.
- 2. Purulent (non-gonorrhœal).
  - *a*. Of the newborn.
  - *b*. Of others.

* To better effect this, and make room for additions and subdivisions, the numbering of the title numbers and species numbers in the Universal List is made non-consecutive—title number 7, for example, being followed by title number 10.

4. Trachoma.
5. Phlyctænular conjunctivitis.
Other forms.

10, L. Acquired Malformations.
1. Pterygium.
5. Symblepharon (not traumatic nor trachomatous).
Other conditions of this class.
Other affections of the conjunctiva.

11. *Diseases of the Cornea.*

11, I. Keratitis.
1*a*. Ulcer of the cornea.
b. Ulcus serpens.
Other forms of suppurative keratitis.
2*g*. Parenchymatous keratitis (not syphilitic nor tuberculous).
Other forms of non-suppurative keratitis.

11, L. Acquired Malformations.
1. Opacity (not due to keratitis or injury).
7. Staphyloma.
8. Keratoconus.
Other malformations.
Other diseases of the cornea.

Such a classification might be condensed still further if required.

A classification of this sort, if properly made and if generally adopted, would be of service:

(*a*) In the compilation of dispensary and hospital reports. Reports so compiled would be prepared on a uniform and definite plan and could be compared with one another, even though some of the statistics were derived from general and some from special hospitals, and some were very brief while others were set forth in great detail.

(*b*) In making mortality* and morbidity returns to health officials and statisticians.

* Mortality returns will in general be made according to the International Classification. Dr. W. A. Coleman has very properly suggested that, to facilitate the making of such returns, there be appended to each title in any morbidity list the corresponding number of the International Classification. In the case of the present list this will be done as soon as the revision of the International Classification, now in preparation, has been completed.

(*c*) In reporting cases in medical journals and books and in medical discussions. It is important that all physicians should use the same terms in the same sense, so that a designation used by one man to denote a morbid condition shall express to every other man just this condition and nothing else.

DISEASES OF THE EYE.

PART I.—AFFECTIONS REGARDED AS GENERAL.*

A.† INFECTIOUS DISEASES.

10. Aspergillosis.
25. Cerebrospinal fever.
30. Chancroid.
60. Diphtheria.
    Diphtherial conjunctivitis.
    Diphtherial paralysis.
85. Erysipelas.
140. Gonorrhœa.
    Gonorrhœal conjunctivitis of newborn.
    Gonorrhœal conjunctivitis of others.
    Gonorrhœal iritis.
160. Influenza.
    Influenzal paralysis.
185. Lepra.
200. Malaria.
205. Measles.
    Conjunctivitis of measles.
310. Rheumatism.
    Rheumatic iritis.
360. Smallpox.
    Variolous conjunctivitis and keratitis.
380. Syphilis.
    Chancre of conjunctiva and lids.
    Gumma of lids.

* In all cases specify part affected; thus, "Aspergillosis of cornea," "Sarcoma of chorioid," etc.

† The letters and numbers attached to the titles are those of the Universal Morbidity List, of which the present list is an excerpt.

Syphilitic keratitis.
Syphilitic iritis.
Syphilitic chorioiditis and retinitis.
Syphilitic optic neuritis.
Syphilitic disease of orbit.
Syphilitic paralyses.
450. Tuberculosis (including Lupus).
Of conjunctiva.
Of cornea.
Of chorioid.
Of other parts or other organs.
Other diseases of this class (specify kind).

B. ZOÖPARASITIC AFFECTIONS.

10. Cysticercosis.
20. Ecchinococcosis.
25. Filariasis.
40. Phtheiriasis.
Other diseases of this class.

C. DIATHETIC DISEASES.

3. Acromegaly.
30. Diabetes.
Diabetic cataract.
Diabetic retinitis.
50. Gout.
70. Leuchæmia.
Other diseases of this class.

D. CHRONIC INTOXICATION. CHRONIC POISONING BY:

5. Alcohol.
Alcoholic amblyopia.
Alcoholic paralyses.
70. Lead.
80. Mercury.
88. Naphthaline.
120. Silver.
Argyrosis of the conjunctiva.
130. Tobacco.
Nicotine amblyopia.
Other diseases of this class.

E. INJURIES.*

Wounds.

502. Lid.
  a. Uncomplicated.
  b. Complicated by symblepharon, etc.
503. Conjunctiva.
504. Cornea.
  a. Non-perforating.
    Special form: Recurrent traumatic erosion.
  b. Perforating.
    If complicated by prolapse of iris, iridodialysis, iritis, dislocation of lens, cataract, panophthalmitis, specify complication.
506. Sclera.
  a. Non-perforating.
  b. Perforating.
    If complicated by ciliary prolapse, escape of vitreous, dislocation of lens, detachment of retina, panophthalmitis, specify complication.
508. Orbit.
  Specify if complicated with injury to optic nerve or the muscles.
510. Lacrymal apparatus.

Gunshot wounds.

515. Eyeball.
517. Orbit.
  Specify if complicated with injury to optic nerve or the muscles.

Fracture.

525. Bones of orbit.
  Specify complications (injury to optic nerve, etc.).

Contusion and concussion.

530. Lids.
532. Globe.
  With rupture of cornea.
  " " " sclera.
  " keratitis profunda.
  " iridodialysis.
  " iridoplegia and cycloplegia.

* To replace Nos. 1110–1122 of the London List and include various additional titles given on pages 43–49 of the latter.

With dislocation of lens.
" traumatic cataract.
" rupture of the chorioid.
" concussion of the retina.
" detachment of the retina.
" laceration of optic nerve.
" dislocation of eyeball.

Foreign bodies.
550. Conjunctiva and cornea.
552. In eyeball.
554. In orbit.

Effects of heat and light.
558. Burns of conjunctiva, lids, or cornea from heat or caustics.
Uncomplicated.
Complicated (with symblepharon, pseudopterygium, ectropion, entropion). (Specify complications.)
562. Solar conjunctivitis (snow blindness).
563. Electric conjunctivitis.
565. Solar (and electric) retinitis.
567. Cataract from heat.
570. *x*-ray burns of eye.

Acute poisoning.*
575. Poisoning by corrosive substances.
585. Poisoning by substances ingested, inhaled, or absorbed, causing
Conjunctivitis.
Mydriasis (and cycloplegia).
Meiosis.
Cataract.
Amblyopia.
Quinine amblyopia.
Methyl-alcohol poisoning.

F. TUMORS.

I. Malignant Tumors.

Carcinoma.
Conjunctiva.
Cornea.
Chorioid.

* Specify poison.

Epithelioma.
    Conjunctiva.
    Lid.
Sarcoma.
    Conjunctiva.
    Iris and ciliary body.
    Chorioid.
    Optic nerve.
    Orbit.
Glioma.
    Retina.

2. *Benign Tumors.*

Fibroma.
    Optic nerve.
    Lid.
Lipoma.
    Conjunctiva.
Melanoma.
    Iris.
Angeioma.
    Lid.
    Orbit.
Cyst.
    Iris.
Other tumors.

G. CONGENITAL ANOMALIES.*

Tumors.
    Lipoma.
    Telangeiectasis (of orbit or lids).
    Cyst (of conjunctiva, iris, or lids).
    Dermoid (of conjunctiva or orbit).
Of cornea.
    Opacity.
    Pigmentation.
    Microcornea.
    Megalocornea.

* To replace London List of malformations so far as it relates to the eye, with other titles passim on pp. 51 et seq. of that list.

Of sclera.
- Scleral fissure (Protrusion of Ammon).

Of iris.
- Persistent pupillary membrane.
- Coloboma.
- Aniridia.
- Ectopia pupillæ.
- Polycoria.

Of chorioid.
- Coloboma.

Of retina and optic nerve.
- Coloboma.
- Absence of vessels or peculiarities in arrangement.
- Medullated nerve fibres.
- Fibrous tissue on the papilla.
- Pigmentation of papilla.
- Amblyopia (congenital).
- Color blindness.

Of lens.
- Cataract.
- Coloboma.
- Dislocation (Ectopia lentis).
- Lenticonus.

Of vitreous.
- Persistent hyaloid artery.

Of eyeball.
- Buphthalmus.
- Microphthalmus.
- Anophthalmus.
- Cyclopia.
- Albinism.

Of lids.
- Epicanthus.
- Ankyloblepharon.
- Cryptophthalmus.
- Coloboma.
- Microblepharia.
- Ablepharia.

Of lacrymal organs.
- Supernumerary puncta.
- Malposition of puncta.
- Fistula.

Of muscles.
Congenital absence or paralysis.
Var: Blepharoptosis.*

PART II.—LOCAL DISEASES OF THE EYE.

10†. DISEASES OF THE CONJUNCTIVA.‡

10, H. Circulatory Disorders.
2. Hyperæmia.
3. Œdema.§
Var.: Chemosis.
4. Hæmorrhage.§
7. Lymphangeiectasis.
10, I. Conjunctivitis.‖
1. Catarrhal.
a. Acute.
Do not include: Exanthematous conjunctivitis (due to measles, smallpox, etc.) (A 205, A 360); traumatic conjunctivitis (conjunctivitis from wounds, foreign bodies, irritants, light, electricity, and *x*-rays (E passim); toxic conjunctivitis (E 585); nor conjunctivitis from hay-fever (enter under Part III).
b. Chronic.
Var: Angular conjunctivitis.
Do not include: Lacrymal conjunctivitis (21, I).
c. Follicular.
2. Purulent.**
(*a*) Of the new born.
If gonorrhœal enter under A 140.
(*b*) Of older persons.
If gonorrhœal enter under A 140.

* Do not use term Ptosis.

† The numbers 10, etc., prefixed to the titles correspond to the numbers of the Universal Morbidity List, of which this list is an excerpt.

‡ For the general diseases affecting the conjunctiva, see Part I.

§ Entry to be made under this head only when no cause for the condition is known. Otherwise enter under the cause (E; 10, I, etc.).

‖ Give cause (microörganism, occupation, etc.) when known; also state whether epidemic or not. Note presence of serious complications (ulcer of cornea, pannus, xerophthalmus, trichiasis, ectropion, entropion, or symblepharon).

** Note presence or absence of discharge from genitals.

3. Membranous.
   If diphtherial enter under A 60; if due to chemical irritants under E 575.
4. Trachoma.
   Do not use terms "Granular conjunctivitis, Egyptian ophthalmia, granular lids."
5. Phlyctænular conjunctivitis.
6. Spring catarrh.
7. Parinaud's conjunctivitis.

Other forms.

10, J. Atrophy, Hypertrophy, and Degeneration.

1. Amyloid degeneration.
2. Hyaline degeneration.
3. Conjunctivitis petrificans.
4. Xerosis.*
5. Pigmentation.
   Do not include Argyrosis (enter under D 120).

10, L. Acquired Malformations.

1. Pterygium.
2. Pseudopterygium.*
3. Symblepharon.*
4. Lithiasis.

10, N. Conditions, Miscellaneous or Unclassed.
Affections of conjunctiva due to skin diseases. (See Part III.)

11. DISEASES OF THE CORNEA.

11, H. Circulatory Disorders.

3. Œdema.†
4. Blood staining (Hæmocornea).

11, I. Keratitis.

1. Suppurative keratitis.
   a. Ulcer of cornea.
      Special forms:
      (1) Mooren's ulcer. (Do not use term Rodent ulcer).
      (2) Superficial marginal keratitis.

* When cause is known make entry under this cause (E, 10, I, 4), specifying also the local condition.

† Enter under this only when cause of condition (glaucoma, etc.) is unknown; otherwise, enter under this cause.

Special types to be entered under other headings:
Phlyctænular keratitis (10, I 5).
Fascicular keratitis (10, I 5).
Catarrhal ulcer (10, I 1).
Gonorrhœal ulcer (A 140).
Diphtherial ulcer (A 60).
Traumatic ulcer (E).
Ulcer of herpes febrilis (see Part III, Skin Diseases).
Ulcer of zoster ophthalmicus (see Part III, Skin Diseases).
Ulcer of rosacea (see Part III, Skin Diseases).

b. Deep purulent keratitis.
(1) Ulcus serpens. Include the varieties known as hypopyon keratitis, reaper's keratitis, etc.
(2) Disciform keratitis.
(3) Annular abscess of the cornea.
Note: Enter Keratomycosis aspergillina under Aspergillosis (A 10).

c. Keratomalacia.

d. Keratitis e lagophthalmo.
When due to injury enter under E; when due to paralysis of facial nerve enter under Diseases of Nervous System (Part III).
Note: Enter Neuroparalytic keratitis under Diseases of the Nervous System (Part III).

2. Non-suppurative keratitis.
a. Pannus.*
b. Vesicular keratitis.
(1) Dendritic keratitis.
If due to malaria enter under A 200.
(2) Stellate keratitis.
(3) Recurrent erosion of the cornea (if due to injury, enter under E 504).
(4) Bullous keratitis.
Varieties to be entered under other heads:
Herpes febrilis corneæ (Part III, Skin Diseases).
Zoster of cornea (Part III, Skin Diseases).

c. Superficial punctate keratitis.
d. Filamentary keratitis.
e. Nodular keratitis. Syn.: Nodular opacity of cornea.

* Enter under cause (trachoma, etc.) when known.

CHICAGO MEDICAL LIBRARY

f. Reticulate keratitis. Syn.: Lattice-shaped opacity of cornea.
g. Parenchymatous keratitis. Syn.: Interstitial keratitis.
If due to syphilis enter under A 380; if due to tuberculosis under A 450.
h. Keratitis profunda.
If due to injury enter under E 532.
i. Posterior keratitis (due to lesion of Descemet's membrane).
j. Sclerosing keratitis.

11, J. Degeneration.
1. Zonular opacity.
Syn.: Ribbon-shaped keratitis.
Enter under cause (glaucoma, etc.) if known.

11, H. Necrosis.

11, L. Acquired Malformations.
1. Opacity.*
2. Microcornea.*
3. Flattening.*
4. Collapse.*
5. Wrinkling.*
Var.: Wrinkling of Descemet's membrane (Striped keratitis, Traumatic striate opacity).
6. Keratectasia.*
Var.: Keratocele.
7. Fistula of the cornea.*
8. Staphyloma of the cornea.*
9. Keratoconus.
Enter Keratoglobus under glaucoma (19, H 7).

12. DISEASES OF THE SCLERA.

12, I. Scleritis.
1. Episcleritis.
Var.: Episcleritis periodica fugax.
2. Deep scleritis.

12, L. Acquired Malformations.
1. Staphyloma.

* Enter under cause, as ulcer of cornea (11, I), injury (E), etc., if known, mentioning also the local condition.

13. DISEASES OF THE IRIS AND CILIARY BODY.

13, H. Circulatory Disorders.
2. Hyperæmia.*
4. Hæmorrhage.*

13, I. Iritis (including Cyclitis and Irido-Cyclitis).
1. Acute.
If due to syphilis, gonorrhœa, rheumatism, tuberculosis, enter under A; if due to diabetes, etc., enter under C; if due to traumatism enter under E.
2. Chronic.
a. Simple cyclitis.
Syn.: Serous iritis (Do not use this term).
b. Anterior uveitis.
3. Secondary (due to other diseases of the eye affected).
4. Sympathetic irido-cyclitis.

13, J. Degeneration.
1. Atrophy.
Enter under cause (iritis, glaucoma, etc.) when known.

13, L. Acquired Malformations.
1. Synechia.
a. Anterior.
Enter under cause (keratitis, etc.) when known.
b. Posterior.
Enter under cause (iritis, etc.) when known.
2. Mydriasis.†
3. Meiosis.†
4. Heterochromia iridis.

13, M. Functional Disorders.
a. Of iris.
Paralysis (Paralytic mydriasis and meiosis) and Spasm (Spastic mydriasis and miosis), see 13, L.
b. Of ciliary muscle.
Paralysis (Cycloplegia) and Spasm (spasm of accommodation). Enter all cases under head of cause as provided in note to 13, L.

* Enter under cause (E; 13 I) when known.

† If due to general disease, as syphilis, etc., enter under A; if due to traumatism under E; if due to acute poisoning under E 385; if due to iritis, under 13, I; to disease of the nervous system under such disease (see Part III).

14. DISEASES OF THE CHORIOID.

14, H. Circulatory Disorders.
Hæmorrhage.*

14, I. Chorioiditis.
1. Non-suppurative.
If due to syphilis, tuberculosis, etc., enter under A;. if traumatic under E.
2. Suppurative.
Var.: Metastatic.
If traumatic enter under E.

14, J. Degeneration and Atrophy.
a. Myopic.
b. Senile.
c. Colloid. Enter atrophy due to chorioiditis under 14, I.

14, L. Acquired Malformations.
Detachment.

15. DISEASES OF THE RETINA.

15, H. Circulatory Disorders.†
1. Anæmia.
2. Hyperæmia.
3. Œdema.
4. Hæmorrhage.
5. Embolism and Thrombosis of retinal vessels.
6. Angiosclerosis.

15, I. Retinitis.
If due to syphilis, malaria, tuberculosis, etc., enter under A; if due to diabetes, leuchæmia, etc., under C; if due to traumatism including effects of sunlight or electric light (Retinitis solaris, Retinitis electrica) enter under E 565; if due to nephritis (Nephritic retinitis) enter under nephritis (Part III, 85, I).

15, J. Degeneration.
1. Retinitis pigmentosa.
Note: Forms of degeneration secondary to retinitis should be entered according to the cause as noted in 15, I.

* Enter under causal condition when known.

† Make entry under casual condition (injury, retinitis, etc.) when known, specifying also the local condition.

15, L. Acquired Malformations.
1. Detachment.
If traumatic enter under E.

16. DISEASES OF THE OPTIC NERVE.

16, H. Circulatory Disorders.*
1. Anæmia.
2. Hyperæmia.

16, I. Optic Neuritis.
1. Papillitis.
If due to syphilis, etc., enter under A; if to brain tumor enter under F; if due to other forms of brain disease enter under Diseases of Nervous System (see Part III).
2. Retrobulbar neuritis.
If due to chronic poisoning enter under D.

16, J. Degeneration and Atrophy.
1. Atrophy.
If due to retinitis enter under 15, I; if due to optic neuritis under 16, I; if toxic under D; if due to nervous disease under latter (see Part III).
2. Colloid degeneration.

17. DISEASES OF THE LENS.

17, J. Cataract.
If due to diabetes enter under C 30; if due to toxic conditions under D; if due to traumatism under E; if congenital under G; if due to keratitis or other disease of the eye under causal lesion.

17, L. Acquired Malformations.
a. Aphakia.†
b. Dislocation.†
For Lenticonus see G.

18. DISEASES OF THE VITREOUS.

18, H. Circulatory Disorders.
4. Hæmorrhage.‡

18, I. Hyalitis.‡

* Enter under cause when known.
† Enter under E if traumatic, under G if congenital.
‡ Enter under cause when known.

18, L. Opacity.*
Var.: Synchysis scintillans.

19. AFFECTIONS OF THE EYEBALL.

H. Circulatory Disturbances.
4. Intraocular hæmorrhage.†
Var.: Expulsive hæmorrhage.
7. Glaucoma.
a. Primary.
(1) Acute congestive.
(2) Chronic congestive.
(3) Glaucoma simplex.
(4) Hydrophthalmus (Buphthalmus‡).
b. Secondary.
Enter under affection causing glaucoma.
19, I. Panophthalmitis.§
19, J. Atrophy and Degeneration.
a. Atrophy of eyeball.‖
b. Phthisis bulbi.‖
19, M. Functional Disorders.
1. Anæsthesia of eyeball.‖
2. Hyperæsthesia and neuralgia of eyeball.‖
3. Asthenopia.‖
5. Sympathetic irritation.
10. Perverted visual sensations.‖
a. Micropsia.
b. Macropsia.
c. Metamorphopsia.
d. Photopsia.
e. Chromatopsia.
f. Acquired color blindness.
12. Muscæ volitantes.‖
15. Diplopia.‖
a. Binocular.
b. Uniocular.

* Enter under cause when known.

† Enter under the cause if known; if confined to vitreous enter under 18, H.

‡ If congenital enter under G.

§ Enter under cause, as cerebrospinal fever (A 25), traumatism (E), irido-cyclitis (13, I), when known; the local lesion being also specified.

‖ Make no entry under these heads unless the cause of the condition is unknown.

20. Ametropia.*
    a. Myopia (simple).
    b. Hyperopia (simple).
    c. Astigmatism.
    d. Anisometropia.
    e. Presbyopia.†

20. DISEASES OF THE LIDS.

20, H. Circulatory Disturbances.
3. Œdema.
   If traumatic enter under E; if renal enter under Nephritis (see Part III); if angioneurotic enter under Skin Diseases (Part III).
4. Hæmorrhage.
   Enter under cause when known (E, etc.).

20, I. Inflammation.
1. Blepharitis.
   a. Simplex.
   b. Ulcerosa.
2. Hordeolus.
3. Abscess.
4. Tarsitis.
   If due to syphilis, etc., enter under A.
5. Chalazion.

20, L. Acquired Malformations.
1. Emphysema.
   When due to injury enter under E.
2. Trichiasis.
   Enter under cause when known.
3. Entropion.
   If spastic (due to blepharospasm) enter under Diseases of the Nervous System (Part III). If due to trachoma, injury, etc., enter under causal condition (10, I; E).
4. Ectropion.
   If spastic (due to blepharospasm) or paralytic (from

* Ametropia due to organic disease of the cornea or lens should be entered under this cause.

† Enter premature presbyopia under paralysis of accommodation. See 13, M.

lagophthalmus) enter under Diseases of the Nervous System (Part III). If due to trachoma, injury, etc., enter under causal condition (10, I; E).

5. Ankyloblepharon.
   Enter under cause when known (E, etc.).
6. Blepharophimosis.
   Enter under E if traumatic.
7. Lagophthalmus.
   When due to injury enter under E; when due to 7th nerve paralysis enter under Diseases of the Nervous System (Part III).
8. Blepharoptosis.
   When due to 3d nerve paralysis enter under Diseases of the Nervous System (Part III).
   Note: Do not use term Ptosis.
9. Blepharochalasis.

20, M. Functional Disorders.
   Blepharospasm.
   Enter under Diseases of the Nervous System (Part III).

21. DISEASES OF THE LACRYMAL APPARATUS.

21, I. Inflammation.
1. Dacryoadenitis.
2. Dacryocystitis.
   a. Acute.
   b. Chronic.

21, L. Acquired Malformations.
1. Distension of excretory ducts.
2. Fistula of excretory ducts.
3. Eversion of puncta.*
4. Stricture of puncta or canaliculi.*
5. Obstruction of duct.*
6. Fistula of sac.*
7. Dacryolithiasis.

21, M. Functional Disorders.
1. Epiphora.
   Make no entry under this unless cause is unknown.

* Enter under causal condition when known.

22. DISEASES OF THE OCULAR MUSCLES.

22, I. Myositis.
22, M. Functional Disorders.
1. Heterophoria.
a. Esophoria.
b. Exophoria.
c. Hyperphoria.
d. Mixed or unspecified conditions.
2. Strabismus.
a. Esotropia.
b. Exotropia.
c. Hypertropia and hypotropia.
d. Mixed and unspecified conditions.

Enter paralysis and spasm of the muscles (Paralytic and Spastic Strabismus), Nystagmus, and Conjugate Deviation under Diseases of the Nervous System (Part III).

23. DISEASES OF THE ORBIT.

23, H. Circulatory Disorders.
4. Hæmorrhage.

Enter under cause if known (E, etc.).

23, I. Inflammation.
1. Cellulitis.

Enter under cause if known.

2. Periostitis.

If due to syphilis enter under A; if due to traumatism under E.

23, K. Necrosis.
1. Caries of bone.
2. Necrosis of bone.

23, L. Acquired Malformations.
1. Exophthalmus.*

Var.: Pulsatile.

* Enter Exophthalmic Goitre under Diseases of the Ductless Glands (Part III); exophthalmus due to tumors under F.; exophthalmus due to disease of accessory sinuses under Affections of Nose (Part III); exophthalmus due to orbital cellulitis under 23, I.

PART III.—AFFECTIONS OF OTHER ORGANS CAUSING DISEASE OF THE EYE.*

Note: Enter affections due to syphilis, cerebrospinal fever, tuberculosis, etc., under A; those due to diabetes, etc., under C; those due to chronic alcoholism, etc., under D; those due to traumatism under E; those due to tumors under F; those due to congenital anomalies under G. Otherwise enter under the name of the causal disease, as follows:

AFFECTIONS OF THE NERVOUS SYSTEM.

1.† *Diseases of the Nerves.*
- I. Neuritis.

3. *Diseases of the Cord.*
- J. Tabes.
- Hereditary ataxia.
- Other diseases of this class.

4. *Diseases of the Meninges.*
- H. Meningeal hæmorrhage.
- Thrombosis of the cranial sinuses.

5. *Diseases of the Brain.*
- H. Hæmorrhage.
- I. Abscess.
- Softening.
- J. Multiple sclerosis.
- L. Hydrocephalus.
- Other diseases of this class.

6. *Miscellaneous and Unclassified Diseases.*
- Hysteria.
- Neurasthenia.
- Migraine.
- Other diseases of this class.

7. *Psychoses.*
- General paresis.
- Other psychoses.

* Parts III and IV represent simply a few excerpts from the Universal List, grouped together in a form convenient for those tabulating the statistics of eye hospitals. In other hospitals, in tabulating general statistics, and in making morbidity returns of all sorts, the full Universal List would be used.

† The numbers prefixed to the heads correspond to the numbers of the Universal Morbidity List.

In each case also the local condition produced should be specified* according to the following list:

Optic neuritis (of brain disease).
Optic-nerve atrophy (of brain and cord disease).
Hysterical disturbances of vision.
Neurasthenic disturbances of vision.
Scintillating scotoma.
Anæsthesia of eyeball and lid from fifth nerve paralysis.
Neuroparalytic keratitis.
Paralysis of exterior muscles of the eye.
a. Oculomotor paralysis, complete or partial.
Var.: Blepharoptosis.†
b. Trochlear paralysis.
c. Abducens paralysis.
d. Combined paralysis.
e. Facial paralysis (Paralytic Lagophthalmus).
Keratitis e lagophthalmo.
Paralysis of interior muscles (Ophthalmoplegia interior).
a. Iridoplegia (Paralytic mydriasis and meiosis).
Var.: Reflex iridoplegia.
b. Cycloplegia (Paralysis of accommodation).
c. Combined iridoplegia and cycloplegia.
Paralysis of ocular sympathetic.
Spasm of exterior muscles of eye.
Blepharospasm.
Spasm of interior muscles.
a. Spastic mydriasis and meiosis.
b. Spasm of accommodation.
Disorders of associated movements.
a. Conjugate deviation of the eyes.
b. Paralysis of convergence.
c. Spasm of convergence.
d. Nystagmus.
e. Other diseases of this class.

AFFECTIONS OF THE NOSE.

31. *Diseases of the Accessory Sinuses of the Nose.*
1. Sinuitis.

* *I. e.*, an entry would read thus: "Tabes; Ophthalmoplegia interior and Optic-nerve atrophy."

† The term Ptosis should be discarded as ambiguous.

Other conditions.
Specify also the resulting eye lesion, viz.,
Orbital cellulitis.
Optic neuritis.
Optic-nerve atrophy.
Exophthalmus.

AFFECTIONS OF THE RESPIRATORY TRACT.

45. *Affections not Strictly Local.*
Hay-fever (causing conjunctivitis).

AFFECTIONS OF THE DUCTLESS GLANDS.

81. *Diseases of the Thyreoid Gland.*
Exophthalmic goitre.

85. *Diseases of the Kidney.*
1. Nephritis; causing:
Nephritic retinitis.
Nephritic œdema of the lid.
Uræmic amaurosis.

AFFECTIONS OF THE SKIN.

165. *Diseases of the Skin Proper.*
Eczema of lids.
Urticaria œdematosa of lids (Angioneurotic œdema).
Herpes febrilis of cornea.
Zoster of lids and cornea (Zoster ophthalmicus).
Pemphigus of conjunctiva.
Other diseases of this class.

166. *Diseases of the Sebaceous Glands.*
Rosacea of conjunctiva and cornea.

PART IV.—DISEASES OF OTHER ORGANS UNRELATED TO EYE DISEASES.*

*** Enter according to title numbers as given in list on page 33. See Note * to page 59, Part III.**

THE ADVERSE INFLUENCE OF DIABETES IN CERTAIN OPERATIONS ON THE EYE.

CHARLES STEDMAN BULL, A.M., M.D.,

New York.

It is known to all ophthalmologists that, in certain cases of diabetes, disastrous results have followed operations upon the eye. For a number of years the author has been led to study the varying conditions of all diabetic patients in his private practice, before as well as after operating, with a view to determine, if possible, what class of diabetic patients, if any, are not fit subjects for operative interference. I have not succeeded in making any exact discrimination of such patients, and I am still very much in doubt when to operate, if at all, in the presence of undoubted diabetes. It is a recognized fact in general surgery that certain types of diabetics stand operations badly. The wounds do not heal, but become gangrenous along the edges, and no apparent attempt at repair occurs. On the other hand, many patients whose general condition cannot clinically be distinguished from the others do unusually well after operations, the wounds healing promptly. How are we to decide what cases can be safely operated, with a favorable prognosis as to results?

Diabetic patients are generally anemic; the hemoglobin percentage is reduced, and, as a result, there is a lowered power of resistance. It has been satisfactorily proved that diabetes interferes with the success of surgical operations because the sugar circulating in the blood is hygroscopic, and draws water from all the tissues of the body and makes them dry. This arrests or retards the process of repair by limiting the capacity of the leucocytes to furnish alexins to meet the toxins in the

blood, and by preventing the proper development of new repair cells.

Diabetes is a grave disease. Life often seems to hang by a thread, and this thread is often severed by a very trifling accident. We must consider the general condition of the patient and learn to properly appreciate how far our treatment is successful in reducing the amount of sugar in the system, and in maintaining the nutrition at a high standard. We must learn to understand the state of the circulation as indicated by the pulse pressure and the cardiac impulse, as this will help us to recognize the presence of possible complications. If we study our cases carefully, we will learn how frequently the diabetic condition is associated with general arteriosclerosis and with tuberculosis. These three diseases have more than an accidental interrelationship. In the case of arteriosclerosis, nutritional changes in the pancreas, due to sclerosis of the pancreatic arteries, have been suggested as the cause of diabetes. With regard to tuberculosis, about 50 per cent. of the cases of diabetes are tuberculous, or there is tuberculosis in the immediate family. Clinical and experimental evidence shows that the two diseases, when existing concurrently, do not necessarily influence each other for the worse; but it is possible that similar factors form the predisposing cause for each. It has been noted by more than one keen observer that an increase in the number of cases of diabetes is attended by a decrease in the number of cases of tuberculosis. Arteriosclerosis is frequently found associated with diabetes, and in many of these cases the glycosuria is the least important feature of the case and diminishes or disappears when the cardiac angina and other vascular symptoms yield to treatment.

Diabetes mellitus seems to be increasing in frequency, and the belief that a hereditary predisposition underlies most cases is gaining credence. It is a generally accepted statement that the later in life the disease manifests itself, the better the prognosis, but that a permanent cure is seldom, if ever, effected.

Almost all authors advise postponing any operation on a diabetic patient until repeated urinalyses show that the sugar has disappeared from the urine. But we now know that it is not the amount of sugar, or even its presence, which is of the greatest importance, but rather the amount of acetone, diacetic acid, and beta-oxybutyric acid present, which give us a more accurate idea of the existing condition of the patient. The urinalysis may show little or no sugar in the urine, and yet in these very patients the odor of acetone is very strong in the expired breath—an evidence of the abnormal product of decomposition of the glucose.

As is too well known, operations on the eyes of patients with advanced diabetes have been followed by fatal results, the patients dying in coma. During the coma the urine is usually free from sugar, even if it has been abundant prior to the attack. The coma may set in within twenty-four hours after operation, or it may be postponed for several days. In some of the cases which were followed by unfortunate complications the diabetes was accompanied by gastro-intestinal symptoms and by enlargement of the liver, but the latter gradually subsided. It is probable that the pancreas was also diseased in these cases, as chronic pancreatitis is of very frequent occurrence in chronic diabetes.

A prolonged and close observation of the cases under my care, which were followed by various complications, seemed to offer evidence of a greater deficiency of fermentative action than in other cases free from these complications. Whether psychic, nervous, or organic influences were originally at fault in these cases, it was evident that the prognosis for operation was more unfavorable, the more marked was the defective metabolism of the carbohydrates. Whether this failure of fermentative action in these cases occurs through the blood-current and tissues of the body, or in the digestive tract, we do not yet know.

It is not wise to introduce a strict anti-diabetic regimen in

a patient immediately before operating, especially if the patient has not been accustomed to it. On the other hand, such a regimen, to which a patient has for a considerable time become accustomed, should not be interrupted at the time of operation. In other words, any change from the general routine of nutrition should not be made in any patient immediately before the operation.

The complications which have occurred in my experience after operations on diabetics have been mainly either iritis, hemorrhages into the anterior chamber, or an infection of the wound as manifested by slow healing. In the cases of iritis there was a marked maceration of the pigment epithelium of the iris, a fact long since pointed out by Snellen. I have also noticed a rather marked tendency to infection by microörganisms after operations on diabetics, and it is known that this has been observed in other branches of surgery. In view of these facts it would seem wise to have tests made of the bactericidal power of the blood-serum in diabetes.

The relatively frequent coexistence of arteriosclerosis and diabetes needs further careful study, for this arteriosclerosis is probably the cause of the recurring intraocular hemorrhages which have been so often observed, especially if the peripheral arteries are involved in the process.

A careful analysis of the 115 cases, on which various operations were performed, has been made, and such conclusions as I have been able to draw are based on the results of such analysis. Of the 115 operations, 62 were cataract extractions; 40 were preliminary iridectomies; 9 were iridectomies for optical purposes owing to the presence of central corneal opacities; and 4 were iridectomies for chronic glaucoma.

Of the 62 cataract extractions, 40 were senile cataracts in diabetic patients, and all the patients were sixty-five years of age or over. These were all extractions with iridectomy, and all the patients recovered without any serious complications, though the wound healed slowly in 11 cases. There

were no hemorrhages and no sign of infection in any of the cases. Many of these patients came under my care before the period of careful observation of the heart and arteries, such as is now being made, and before we had the means of carefully estimating the intravascular tension. But of these 40 cases I have accurate records of the condition of the heart, arteries, and intravascular tension in 10 cases. These 10 cases showed slow healing of the wound, and all gave evidence of arterial degeneration and a high intravascular tension.

The remaining 22 cases were all pure diabetic cataracts; that is, they were all cortical cataracts, bluish-white in color, and somewhat swollen. The patients' ages varied from thirty-six to forty years. In each case before operation, care was taken to reduce the percentage of sugar to a minimum, and as far as possible to eliminate the abnormal products—acetone, diacetic acid, and oxybutyric acid. In 6 of the 22 cases there was a somewhat profuse hemorrhage into the anterior chamber, which recurred several times. In 2 cases there were retinal hemorrhages, which did not recur and were slowly absorbed. In 6 cases the operation was followed by iritis, without much exudation, which was obstinate in resisting treatment, and discission of the opaque capsules was necessitated in 2 cases. In the remaining 8 cases there were no complications either at the time of the operation or following it, and the wounds healed promptly, with excellent results as to vision. In 14 of the 22 cases there were signs of arteriosclerosis in the conjunctival vessels, and after the extraction of the cataracts the same condition was found in the retinal arteries. In the remaining 8 cases no signs of arterial degeneration were demonstrable.

In the second list of operations—40 cases of preliminary iridectomy in cataract patients—22 were senile cataracts in diabetic patients, whose ages varied between sixty and sixty-eight years; and 18 were true diabetic cataracts in patients under forty years of age. In the 22 cases of the senile cataracts no case of iritis occurred after the iridectomy, but in 3 cases there

was an annoying hemorrhage into the anterior chamber, and the external wound healed very slowly, and in these 3 cases the signs of general arteriosclerosis were present. In the 18 cases of true diabetic cataract iritis occurred in 4 cases, but owing to the prompt treatment no permanent synechiæ were formed. Two of these 4 cases were victims of pulmonary tuberculosis, but showed no evidence of arterial degeneration.

In the third list of operations there were 9 iridectomies for optical purposes, owing to central corneal opacities. There were no anterior or posterior synechiæ and no signs of intra-ocular irritation. They were all young diabetics, under forty years of age, and with one exception all did well, the wounds healing promptly. The one exception was a lady, aged twenty-two, in whom the operation was followed by severe iritis, with an abundant exudation, which blocked the pupil for a long period, and it was not until five months later that the pupil became free and useful vision was restored to the eye. In all of the 9 patients the fellow-eye was normal.

In the fourth and last list of operations there were 4 iridectomies for chronic glaucoma, performed before the field of vision was much contracted, and as soon as the diagnosis was positively made. In these cases great care was taken to choose the time for the operation when the percentage of sugar was either nil or very small, and when the urinalysis showed only a minute percentage of acetone and diacetic acid. All 4 cases did badly, and 1 case fell into collapse and nearly died. Three were men and one was a woman. Profuse hemorrhage into the anterior chamber occurred in all 4 cases, and recurred several times, but there were no retinal hemorrhages. In the fourth case, a lady aged fifty-nine, there was a profuse hemorrhage into the anterior chamber, which recurred on the two succeeding days. At the close of the third day the patient complained of great pain, and in a few hours became delirious. There was a distinct odor of acetone in her breath, and I looked for a speedy onset of diabetic coma and death. Fortunately, after

twenty hours of delirium, the mental excitement passed away without developing into coma and the patient temporarily recovered. The glaucomatous symptoms seemed to be arrested, the tension returned to the normal, and the vision was improved. Eight months later, however, the patient succumbed to an attack of diabetic coma.

An analysis of Uhthoff's paper on "Cataract Extraction in Diabetics," presented at the meeting of the Ophthalmological Society in Heidelberg in 1908, yields the following results: There were 115 cataract operations, and 68 per cent. recovered vision of 1 to $\frac{1}{3}$. Iritis occurred in 6 per cent. and glaucoma in 1 per cent. There were hemorrhages into the anterior chamber in 8.9 per cent., hemorrhages into the retina in 4.5 per cent., and hemorrhages into the vitreous in 1.8 per cent. Retinitis occurred in 2.6 per cent. No eye was lost, but two patients had only light perception. One patient died on the fifth day after the operation in diabetic coma.

In all the statistics published on the subject, iritis seems to have been the most frequent complication. This is probably because the tissues in diabetes are more prone to inflammatory processes, in consequence of diminished powers of resistance and the greater virulence of microörganisms in diabetic patients.

I believe that the retinal and vitreous hemorrhages are far more serious in their prognosis as to results than is usually appreciated. So far as it is possible to draw any conclusions from my own experience, I am induced to offer the following:

1. We must carefully differentiate those diseases which are directly due to diabetes as a cause from those which may occur independently of the disease.

2. The abnormal products of metabolism—acetone, diacetic acid, and oxybutyric acid—seriously complicate the prognosis, and must as far as possible be eliminated before any operation is undertaken.

3. Arteriosclerosis plays an important rôle in the etiology of the disease and its complications.

4. The prognosis does not depend on the percentage of glucose in the urine, but on the degree of acid intoxication.

5. The possible connection between diabetes and tuberculosis needs more searching investigation before any positive opinion can be formulated.

DISCUSSION.

DR. JAS. THORINGTON, Philadelphia: One clinical case that I have had under observation lately tends to corroborate the remarks of the writer. The right eye was operated upon and considerable vitreous lost; the second eye was operated upon and there was hemorrhage into the anterior chamber, followed by a slight iritis. The case was interesting from this point of view: that one year later—one year after the second eye had been operated upon—detachment of the retina occurred in the eye first operated upon, and then twenty-four hours later in the second eye, showing that the diabetic condition was most likely the cause of the detachment of the retina in each eye in such a short time.

DR. H. F. HANSELL, Philadelphia: This subject is one of very great interest to all operators, because many cases are presented to them in the course of a year in which it is necessary to decide the question of whether it is safe to operate. Dr. Bull's statement of the value of carefully analyzing the urine as to the quantity of these acids is especially interesting to me, because I have never made them. My plan has been to examine the urine in all cases of cataract, and, when sugar is found in any appreciable amount, to postpone the operation until the patient has been under observation and treatment for some time. In two cases under my care this winter the percentage of sugar was 8 per cent. and 10 per cent. on admission. Dr. Bull's advice that the patient shall be under treatment and the quantity of sugar reduced, and if possible eliminated, had been followed by me in these two cases. In them the sugar was reduced, in one to 2 per cent., and the operation performed with a good result; and in the second the glycosuria was cured and then a successful operation was done. I am quite sure that if the operations had been performed when the patients were first admitted, total loss of the eyes would possibly have ensued.

DR. S. LEWIS ZIEGLER, Philadelphia: Dr. Bull has so thoroughly covered the subject of the operative complications of diabetes that there remains but little to be said except in the field of general therapy. It has been my custom to prepare all diabetic patients for operation by administering for a longer or shorter period a comparatively unknown remedy, which has been designated in the shops as "Clemens' solution" of the arsenite of bromin. This is given in doses of from 3 to 5 drops in water after each meal. This treatment has proved efficient in relieving almost every case that has been placed upon it. While I have not been able to follow the treatment to a cure in all cases, I am fully convinced that its continued use will prove permanently effective. I have now in my employ an old colored servant who has practically been cured of diabetes by this treatment after suffering severely for a number of years. She claims that she noticed a marked improvement in her condition after the first week's treatment.

During the past twenty years I have operated on a number of cases of primary and secondary cataract, occurring in diabetic patients who had been placed on this course of treatment, without meeting with any post-operative complications. Only a few of these cases, however, have been cases of true diabetic cataract, of bluish-white character, as referred to by Dr. Bull.

I have had one unfortunate result in an accident case occurring in a diabetic subject, who had not been placed on this line of treatment. The accident was caused by a spawl of stone striking the cornea, causing sloughing keratitis, which was promptly followed by panophthalmitis. The eye was enucleated under ether anesthesia, the patient rapidly passed into diabetic coma, and died in less than a week. The lesson I have learned from this case is never to administer ether in confirmed diabetes. I would like to inquire if others have had a similar experience.

DR. G. E. DE SCHWEINITZ, Philadelphia: It would seem to me that a sharp distinction should be made between a diabetic cataract and a cataract that happens to occur in a patient who at the time has sugar in the urine, and, if I understood Dr. Bull correctly, this is one of the points which he desires to bring out in his paper. If we were to allow the presence of a little sugar in the urine of patients with cataract to deter us from operating, I fancy that our operative tables would not be as large as they are. I would like to refer to an interesting experience of my

own in this connection. Last year I removed four cataracts in two patients who had in spite of treatment a large quantity of sugar in their urine and other symptoms of diabetes mellitus. In all instances the operations were successful, and yet the visual results were not as satisfactory as they might have been owing to the presence of a widespread so-called diabetic retinitis, visible only too plainly after the removal of the lenses. It seems to me that considering the character of the lesions the operative results were very good, unattended, as they were, with any complications.

DR. P. A. CALLAN, New York: I am in full accord with Dr. Bull's paper, and at the same time I fully appreciate that there is nothing to guide us in determining what is going to be the outcome of an operation upon a diabetic patient. Up to this winter I felt more or less sure that if there was less than 3 per cent. of sugar it was perfectly safe to remove a cataract. I now think that is a mistake. I think where there is no sugar except occasionally we may have a disastrous result. Years ago I lost an eye in a diabetic case after extraction. This winter I operated on three, in one of which there was over 9 per cent. of sugar, and I refused to operate at first, but after three weeks of diet the sugar was reduced to 2 per cent. I operated on both eyes with a perfect result; not even a drop of hemorrhage followed excision of the iris. In the other patient, however, where there was no sugar at the time of operation, there was a large exudate in the vitreous afterwards which has not cleared up in months.

The acidosis is a guide, but not an accurate one. At the same time I never hesitate to operate if the patient will for some time previous adhere to the proper diet. I think it wise to do a preliminary iridectomy, and at the end of six weeks remove the cataract.

One statement in the paper which is new to me is that in regard to the connection between diabetes and tuberculosis. Though I am not in a position to be a judge of this, as I have not looked for it, I would at first sight be inclined to doubt this.

If the patient is otherwise in ordinary health, I have no hesitancy in operating. Of course, we may have these complications, especially hemorrhages in the anterior chamber. In this condition I give three grains suprarenalin capsules three times a day.

DR. LUCIEN HOWE, Buffalo: It strikes me that we are in danger of confusing two things which the writer of the paper has distinctly separated. The title is diabetes in ophthalmic operations, and the author says we now know that it is not the amount of sugar that is of importance, but the diacetic and beta-oxybutyric acid. That is the keynote of the situation.

When I asked myself what was meant by "autointoxication," it struck me that it would be a good plan to look up the more modern ideas of the chemistry of to-day, and I was surprised to find how little I knew about it, and yet how comparatively simple the matter was. It is no doubt familiar to most of you that a certain amount of alkalinity of the blood is an absolute necessity. We must have about the proportion of 180 mg. of the sodium and other alkaline compounds to 100 gm. of blood. When the alkalinity falls below that, we are apt to have an "autointoxication" of some kind. We get that in two different ways: First, by not enough acid being given off, in the form of carbonic acid, from the lungs, or uric acid from the kidneys, etc.; or, second, by the formation in the system of other acids. We are told by those who know that the first cause is comparatively rare, while the other condition, that in which the acids are manufactured, is comparatively common. What we call "diabetes" comes in as a part of that condition. Of special importance is what they call the ketone group, which includes diacetic acid or oxybutyric acid. Of course, this is only an outline of what the chemists know perfectly well.

The point is that if we are to practise as physicians we must study the advances constantly made in chemistry. Simply to keep on operating and saying that we do not know why we have this or that result is to acknowledge that we have not submitted these cases to men who do not now speak so much of "diabetes" as, in terms of more advanced chemical knowledge, of the condition of which the sugar is only one sign.

DR. C. J. KIPP, Newark: I have never hesitated to operate on a cataract in the diabetic subject, and my results, I think, have been as good as in other cases. The precaution that experience has taught me is to make an unusually large incision. Slight bruising is apt to be followed by serious complications. Many years ago, when I ripened cataracts, I had a case, a dia-

betic subject, in which the patient had only one eye, the other having been lost years before. In order to operate I intended to ripen the cataract and used cocain and rubbing of the cornea. In this case I had a severe ulcer following, which took a long time to heal, but after a while I was able to remove the cataract with a good result. In all these cases I am very careful to have a large opening and to use very little pressure in expelling the lens.

DR. ROBERT L. RANDOLPH, Baltimore: It seems to me that in speaking of the so-called diabetic cataract it is well to distinguish between those cataracts which are seen in elderly people who have sugar in their urine and those cataracts which occur in comparatively young people with diabetes, and which are clearly due to the latter disease. Some years ago I reported five cases of diabetic cataract successfully operated upon. One of these cases was a woman of over sixty who had sugar in her urine, but in thinking over this case afterward I concluded that the cataract was just as likely to have been senile as diabetic in character, especially so as the cataract in one eye was mature and in the other eye the lens was only vaguely clouded. True diabetic cataracts advance at an equal rate in both eyes and come to maturity rapidly. Sugar in the urine of elderly individuals is not such an infrequent occurrence, and I am told that it is not an insuperable obstacle to insurance. The other four cases were under forty; two, indeed, were under thirty, and one of these two (a young negro man) was twenty-four. In this latter case the lenses commenced to get cloudy early in September, and by the middle of October they presented the characteristic appearance of diabetic cataract. When the second eye was operated upon, he had a gangrenous sore on one of his feet. He died in the early spring, about six months after the operation. I cannot but regard the occurrence of cataract in the diabetes such as we see occasionally in rather young individuals as an indication that the disease will terminate fatally within a few months, and yet a study of the statistics of de Grandemont and others in this connection, coupled with my own, leads me to think that the presence of diabetes is no contraindication to the extraction of the cataract.

DR. SAMUEL THEOBALD, Baltimore: It may not be out of place to mention two cases of toxic amblyopia which have

come under my observation recently, and which interested me especially because in each sugar was present in the urine. In one the man was a diabetic subject, in the other there was simply glycosuria. In each case there was the history of excessive use of both alcohol and tobacco. That the general systemic condition was a factor in rendering them more susceptible to the toxic action of these agents seems more than probable. In the case in which glycosuria was probably a transient condition not only sugar, but albumin, was found in the urine. This patient abstained wholly from alcohol, almost entirely from tobacco, ate no sugar and fewer foods containing starch, and in twelve days—increasing doses of strychnin having been given meantime—both the sugar and the albumin had disappeared from the urine, and have not been found since.

DR. W. H. CARMALT, New Haven: I beg leave to speak of one of Dr. Bull's conclusions, which says that "the abnormal products of metabolism, acetone, diacetic acid, and oxybutyric acid, seriously complicate the prognosis, and must as far as possible be eliminated before any operation is undertaken." In the late seventies I assisted a gentleman at an operation for a cataract in a patient, a woman of some sixty years of age, who had been under his care for several years for diabetes. She developed a cataract, presumably as the result of the diabetes, but being desirous to have her in as good a condition as possible for the operation, he deferred the operation until every evidence, as understood at that time, had disappeared. It was before we knew about acetone, diacetic acid, etc., in the urine as evidences of diabetes; we judged simply by the presence and amount of sugar in the urine and clinical signs. The sugar had disappeared for several months,—a year, more or less,—there was no polyuria, and from having been greatly emaciated, she had taken on weight; she was regarded as cured of her diabetes.

At the operation immediately that the anterior chamber was opened into, the aqueous flowed out upon the cheek almost as black as ink, from the pigment washing off the iris. The eyeball collapsed, the cornea made no attempt whatever to repair, began to slough, and the patient succumbed completely to the operation, dying in the course of a week. I do not recollect whether ether was given or not, but my impression is that it

was not. Certainly, to all evidences that we then had the patient had been free from the disease for several months, and yet the result was most disastrous. Even taking the precautions mentioned by Dr. Bull, I cannot think we are justified in promising a recovery from an operation in this class of cases; we must at best give a guarded prognosis.

DR. CHARLES STEDMAN BULL, New York: It is not sufficient alone to examine the urine for these evidences of faulty metabolism: the intestinal contents must be as carefully examined. Very often the urine will show no evidence of a positive nature, while the intestinal contents will show acetone and diacetic acid.

There is an element in these patients, possibly of psychic character, which we do not as yet fully appreciate. It has been my misfortune in the last year to have had two cases, in one of which I was operator and the other consultant, of cataracts in diabetic patients. In both cases careful dietetic and medicinal treatment had caused entire disappearance of sugar from the urine, and no trace could be found, in either of the cases, of acetone or diacetic acid. In my own case I did a preliminary iridectomy, which was recovered from rapidly, the wound healing in twenty-four hours. I allowed four weeks to pass, and then extracted the cataract without any hemorrhage into the anterior chamber. The patient did well and the wound healed, but in the middle of the third day, less than seventy hours after operation, there was marked odor of acetone in the breath, the patient became rapidly worse, and died. In the case in which I was consultant the same care had been taken as to diet and medicinal treatment, and a preliminary iridectomy was done with perfect result. On the fourth day, the wound having healed, the odor of acetone appeared on the breath, the patient had a convulsion, and in twenty-four hours died of diabetic coma. There is an element, possibly of psychic nature, which we do not understand and cannot presuppose.

SUMMARY OF RESULTS OBTAINED, AND FEATURES OF INTEREST, IN TWO HUNDRED AND FIFTEEN CONSECUTIVE CATARACT EXTRACTIONS.

SAMUEL THEOBALD, M.D.,

Baltimore.

Of the cases included in this summary 100 have been reported in detail heretofore.* Like this first series, the 115 eyes since operated upon were in no sense "selected cases." Indeed, five of the cataracts were of traumatic origin, and three of these were complicated by the lodgment of a foreign body within the eye and one by laceration of the iris, while in one case pulmonary tuberculosis was present, in another diabetes, in another an iridectomy had been done previously for glaucoma, and in still another the cataract was hypermature and partially dislocated.

I have felt warranted in excluding six cases from this report. In three there was before operation no light perception, the lens having been removed in one to reduce tension, in one for cosmetic effect, and in one to lessen the irritability of the eye blind from iridochoroiditis. In another case there was doubtful light perception consequent upon an old choroidoretinitis, and, though recovery from the operation was smooth, vision was not improved. In another the cataract was secondary to extensive detachment of the retina, and in still another, which was of traumatic origin, due to penetrating wound of the ball, the eye was eventually enucleated because of severe and persistent iritis.

Combined extraction was done in ninety-four cases, extraction after preliminary iridectomy in seventeen cases, simple extraction (unintentional) in one case, extraction in capsule, without iridectomy (unintentional), in two cases, and suction extraction in one case of traumatic cataract.

In most of the cases in which a preliminary iridectomy was

* American Journal of Ophthalmology, vol. xvi, p. 353.

done the cataract was immature, and trituration of the lens was combined with it; in one instance the iridectomy was done for the control of glaucoma. In two of the preliminary iridectomy cases, owing to complications, the lens was extracted with the "loop."

In all of the operations the section was made throughout in the sclero-corneal juncture, and in nearly all of them a small conjunctival flap was secured. A small iridectomy was made with a single cut with the writer's reverse curved iris scissors (Fig. 1). The capsule was opened freely by a long vertical cut crossed by a shorter horizontal one. After extrusion of the lens the iris was carefully disentangled from the angles of the section. Both eyes were closed with sterile pads of gauze and cotton,

Fig. 1.—About three-fourths actual size.

the eye operated upon being further protected by Murdoch's shield. The fellow-eye was kept closed until the fourth day; the pad was not removed permanently from the eye operated upon until the seventh day. Strict antisepsis was practised, the instruments and all solutions used being sterilized by boiling. Beginning usually on the second day, a daily application of a 4-grain solution of atropin was made to the eye operated upon.

Accidents and Complications.—In the 115 cases not heretofore reported, loss of vitreous humor occurred nine times. In five this was due to strong contractions of the lids, four occurring in negroes. In one case there was difficulty in delivering the lens, in one the loop was used, and in two cases the cause

was not apparent. In the first 100 cases vitreous was lost six times.

In one case, after a smooth operation, the patient, in taking a dose of trional, had a spell of choking which brought on intraocular hemorrhage. Hernia of the vitreous followed, and, though suppuration was avoided, only light perception was retained.

In endeavoring to secure a small coloboma, it happened in several cases that the pupillary margin of the iris was not excised, a "buttonhole" iridectomy being the result. In no instance did this seem to interfere with the success of the operation. Several times, too, the iris protruding in front of the knife was cut during the completion of the corneal section, but this was in no case followed by serious consequences. In one instance, in which it was difficult to seize the iris, due probably to exceptionally wide mydriasis from the cocain, the iridectomy was done after delivery of the lens. It so happened that the best visual result of the series was obtained in this case.

There were fifteen cases in which discission of capsular opacity was performed, and in one of these a second discission was necessary. There were a number of cases of mild iritis, and three cases in which the iritis was so severe as to require a secondary iridectomy, the ultimate visual result in these cases being $\frac{20}{C}$, $\frac{20}{CXXV}$ and $\frac{20}{CC}$ respectively.

SUMMARY OF RESULTS.

Successes (V = $\frac{20}{CC}$ to $\frac{20}{XV}$)	95
Successes (V not recorded) *	8
Total successes	103
Partial successes (V = $\frac{6}{CC}$ to $\frac{18}{CC}$)	6
Partial successes (V not recorded)	1
Failures from suppuration	2
Failures from other causes	3
	115

* The history notes of these cases showed smooth recoveries, but for various reasons, chiefly because the patients did not report for adjustment of glasses, no record of vision was obtained.

The visual acuity obtained in the successful cases, omitting the eight cases in which it was not recorded, and taking the best vision in each, whether before or after discission of capsular opacity, was as follows:

$\frac{20}{XV}$	1
$\frac{20}{XX}$	2
$\frac{20}{XXV}$	3
$\frac{20}{XXX}$	15
$\frac{20}{XL}$	18
$\frac{20}{XLV}$	3
$\frac{20}{L}$	8
$\frac{20}{LX}$	1
$\frac{20}{LXX}$	5
$\frac{20}{LXXV}$	2
$\frac{20}{LXXX}$	4
$\frac{20}{XC}$	6
$\frac{20}{C}$	14
$\frac{20}{CXX}$	3
$\frac{20}{CXXV}$	2
$\frac{20}{CL}$	1
$\frac{20}{CC}$	7
Total	95

Of the cases designated in the above summary as "partial successes" the poor vision obtained was due in one to the patient (a negro) contracting the lids so strongly just before delivery of the lens as to cause a loss of about one-fourth of the vitreous humor ($V = \frac{10}{CC}$); in one (also a negro) through similar behavior

forcing out the lens and a considerable quantity of vitreous ($V=\frac{10}{CC}$); in one, in which there was a smooth recovery, to antecedent chorio-retinitis ($V=\frac{6}{CC}$); in one to antecedent syphilitic iridochoroiditis ($V=\frac{16}{CC}$); in one to an old uveitis, for which I had previously performed an iridectomy (V unrecorded); and in one case, in which $V=\frac{18}{CC}$ was obtained, the cataract was caused by a blow from a whip, and was complicated by laceration of the iris.

Of the five "failures," two, as indicated, were due to infection, with resulting purulent panophthalmitis. One of these occurred in a woman eighty years of age, in feeble health, an inmate of the Home for Incurables. The operation was performed at the Baltimore Eye, Ear, and Throat Hospital, and the usual antiseptic precautions were observed. The conjunctiva tore under the grasp of the fixation forceps, and for this reason the corneal section was made with difficulty, and was somewhat smaller than was intended. Counterpressure was required to effect the delivery of the lens, and when it rather suddenly slipped out there was a small loss of vitreous. A crater-like depression of the cornea followed, and this had not entirely disappeared when the permanent dressings were applied, after a delay of a quarter of an hour. More than the usual amount of pain followed the operation, and on the third day it was evident an infection had occurred. The eye was subsequently enucleated.

The other infection happened in a man about seventy-four years of age, in poor health, and of unsound mind. The cataract was fully mature and was very black, and, it seemed not improbable, was secondary to disease of the deeper eye tunics. I had operated upon the other eye four years before (No. 68 of previously published series), and this eye (otherwise diseased) was also lost by infection. It is worthy of note, therefore, that this one individual furnished just half of the four infections which occurred in the whole series of 215 operations.

Because of this previous experience, I had, as a precaution, performed a preliminary iridectomy upon the second eye. The

nucleus proved to be exceptionally large, and for this reason, though a good corneal section had been made, its delivery was a little difficult. However, no vitreous was lost, and the outlook seemed altogether promising. After the operation the patient complained continuously of pain, and three times tore off the dressings, twice during the second night. Within forty-eight hours a purulent panophthalmitis set in, and the eye, of course, was lost.

Of the three "failures" due to causes other than pyogenic infection one, resulting from post-operative hemorrhage, has already been described.

Another occurred in a man, eighty-six years of age, who was in fairly good health. A broad arcus senilis was present, and the iris was very light in color. Adrenalin (1 : 1000) was used in conjunction with the usual 4% cocain solution. The cornea collapsed after completion of the section, and it was impossible to see the light-colored iris. Probably owing to exceptionally wide mydriasis, it was equally impossible to seize the iris; so, after several ineffectual efforts to accomplish this, the capsule was opened and the lens delivered without the performance of an iridectomy. Collapse of the cornea followed, but the edges of the section being in good apposition, the dressings were applied. The cocain was not used oftener nor for a longer time in this case than usual, and it seemed altogether probable that the unfavorable conditions produced were due to the added effect of the adrenalin. At all events, I have never since ventured to use it in operating for cataract.

Undue inflammation, suggestive of non-pyogenic infection, followed, and involved the anterior portion of the vitreous body as well as the iris. During convalescence the patient fell and fractured the neck of his femur. On this account he was removed to a general hospital, where I saw him some weeks later. He was then able to see the hand by reflected light, and there seemed to be a chance of improving vision by a secondary operation. He was not, however, heard from again.

The third case of failure from causes other than pyogenic infection was to me of especial interest: A negro woman, who gave her age as fifty-six, but was probably older, had a somewhat hypermature cataract in the R. eye and a not fully mature cataract in the L. eye. A smooth operation (combined extraction) was done upon the R. eye. The result was entirely satisfactory, except that there was some entanglement of the iris in one extremity of the corneal section, and within five weeks she had in this eye $V = \frac{20}{XXX}$. She was anxious to have the other cataract removed before leaving the hospital, and, contrary to my usual practice, I operated upon the L. eye three weeks after the date of the first extraction. The operation was smooth, and when the eye was inspected on the second day its condition was most promising, there being very little cortex in the pupillary area. Some days later the R. eye became injected, and then the L. eye began to do badly, and before long a severe and obstinate iridocyclitis was established in each eye. Extensive adhesion of the iris to the vitreous body occurred in both eyes, the T of each fell below normal, and in each V was reduced to light perception, with no hope of improvement.

That a condition closely akin to sympathetic ophthalmitis was established in this case seems altogether probable, and I feel sure that two successful operations were spoiled because so brief an interval was allowed to elapse between their performance.

Several other cases presented features worthy of mention: A negro, sixty years of age, a truck-driver, with a hypermature cataract in one eye, eight days before reporting saw well enough with the other eye to drive his team. Within this brief period, and without signs of inflammation or the occurrence of any traumatism, the lens of the seeing eye clouded so rapidly that V was reduced to light perception, and the cataract, though presenting a mother-of-pearl appearance, was recorded as "nearly mature." I may add that I have encountered three other similar cases.

Mrs. S., a gentlewoman, sixty-five years old, after a successful

combined extraction upon one eye, the other eye having slight peripheral lens opacity, with a low grade of compound hypermetropic astigmatism and nearly normal vision, wore for several years with entire satisfaction bifocal glasses, which gave her comfortable binocular vision in both far and near. Such an experience, so far as my observation goes, is rare, and it is, perhaps, worth while to give the formula of her lenses:

R. eye + 11.s, with + 3.75s added for near.
L. eye + .62s ⊂ + .37c axis 85,° with + 3.50s added for near.

With these the V of the R. eye was $\frac{20}{XX}$; of the L. eye, $\frac{20}{XXV}$ (?); and of the two eyes, $\frac{20}{XX}$, missing one letter.

Mrs. H., about seventy years of age, had had a successful extraction operation performed upon the L. eye. A combined extraction was done upon the R. eye, with good result; but when an attempt was made to adjust glasses to the two eyes intolerable vertical diplopia resulted, and it was found that a downward squint had developed in the R. eye during the time that it was not in use. To overcome this diplopia a 5° prism, base up, before the R. eye was necessary, and this effect was obtained by decentering the lens. The point of interest is that in a little more than six weeks the hyperphoria had almost entirely disappeared, and the patient was actually more comfortable without the prismatic correction which so short a while before was urgently demanded.

In the one hundred extractions heretofore reported there were, as has been indicated, two eyes lost from suppuration, giving a total of four for the whole series of two-hundred and fifteen cases—slightly less than 2%. There were also two eyes in which V was not improved, though recovery from the operation was smooth, the negative result in one being due to preëxistent extensive retinal detachment; in the other to an old syphilitic iridochoroiditis. There were six partial successes and ninety successes.

Combining the results of the two series we have:

GENERAL SUMMARY.

Successes (V $\frac{20}{CC}$ to $\frac{20}{XIII}$)	178
" (V not recorded)	15
Total successes	193
Partial successes (V $\frac{6}{CC}$ to $\frac{18}{CC}$)	10
" " (V not recorded)	3
V not improved, though recovery from operation was smooth	2
Failures from suppuration	4
" " other causes	3
Total operations	215

The seven failures recorded represent a loss of slightly more than 3.25%. The visual acuity obtained in the successful cases, omitting the fifteen cases in which it was not recorded, was as follows:

$\frac{20}{XIII}$	1
$\frac{20}{XV}$	1
$\frac{20}{XX}$	4
$\frac{20}{XXV}$	3
$\frac{20}{XXX}$	31
$\frac{20}{XL}$	25
$\frac{20}{XLV}$	3
$\frac{20}{L}$	19
$\frac{20}{LX}$	10
$\frac{20}{LXX}$	16
$\frac{20}{LXXV}$	6
$\frac{20}{LXXX}$	7
$\frac{20}{XC}$	6
$\frac{20}{C}$	22
$\frac{20}{CXX}$	7
$\frac{20}{CXXV}$	2
$\frac{20}{CL}$	1
$\frac{20}{CC}$	14
Total	178

DISCUSSION.

DR. DAVID WEBSTER, New York: I just want to say a word about the use of adrenalin. The doctor speaks of having used it in one of his extractions with loss of the eye. Some years ago when we were first trying adrenalin I used it in a number of cases of cataract extraction, perhaps six or ten in succession. I used it long enough to learn that in all the cases in which I used adrenalin with cocain in order to promote anesthesia I had secondary hemorrhages. There was none at the time of operation, but when I came to open the eye thirty-six to forty-eight hours afterward, I would find the wound healed and the anterior chamber full of blood, and this always seemed to delay recovery. The anterior chamber would remain more or less full of blood, it would keep on oozing for some time, but in these cases, so far as I remember, the final result was good. I then abandoned its use and have not employed it since.

DR. T. Y. SUTPHEN, Newark, N. J.: Dr. Theobald refers to the use of the loop in two cases. Already this year I have found it necessary to resort to this means for the removal of the lens in three cases where the vitreous presented, and in all the result of the operation was perfectly satisfactory, the only untoward symptoms being the causation of striped keratitis, which quickly disappeared. It is my opinion that there is little to be feared when this is necessary.

He also mentions the fact that in one or two cases the excision of the iris for the iridectomy was insufficient, inasmuch as the sphincter was left. I have had the same thing occur, and have found that the narrow bridge of iris could be readily withdrawn with the cystotome, and, being snipped off, leave a clear and symmetrical coloboma.

DR. HIRAM WOODS, Baltimore: There is one point brought out in this discussion upon which I should like to hear further expression of opinion; that is, the use of adrenalin. I have used it, 1 : 1000, to promote anesthesia, and with, I think, very good effect. I have seen this hemorrhage in the anterior chamber occasionally when the wound was dressed, but I have seen it just as often, I think, where adrenalin had not been used. If it is the general experience, however, that adrenalin is not a good thing to use, I should like to have it brought out here to-day, as that idea does not correspond with my observation.

DR. CHARLES J. KIPP, Newark: I practised a good many years before adrenalin was introduced, and had these hemorrhages in the anterior chamber that have been referred to. Since its introduction I have used it without any more hemorrhage into the anterior chamber than occurred before. I use it in every case of extraction, only one drop of 1 : 1000 solution.

DR. ALLEN GREENWOOD, Boston: I have used adrenalin in all my extractions in the last few years. I never use it stronger than 1 : 10,000, and I have yet to see hemorrhage into the anterior chamber following its use.

I always, like Dr. Theobald, try to make a conjunctival flap, and think it helps a great deal. We should use a very weak solution of adrenalin, and I have not seen conjunctival hemorrhage of any amount following its use in that strength, and it certainly aids the operator when making the flap.

DR. WHEELOCK RIDER, Rochester, N. Y.: I would say that I think I have had more $\frac{20}{20}$ results than the writer reports, possibly from recording patients' vision after they have practised with their glasses. On the other hand, I think the general average of his results is higher than I have obtained; I have had more poor results.

The loop has been referred to. My first lens got away from me and I went after it with the cystotome and caught it, and with perfect results. I soon lost an eye, not having the good fortune to catch the lens. Since then I have always had the wire loop and have found it the most useful instrument in cataract extraction. I rely upon it whenever more than the most gentle manipulations would be required to deliver the lens, and for this reason I very seldom see vitreous.

I never use anything to restrain hemorrhage. I use a slightly dull knife that cuts the cornea easily, but cuts the conjunctiva with difficulty, so that this hangs back and makes a good flap.

I keep my patient in bed about twenty-four hours, as a rule. Have seen little trouble from allowing them much liberty after that.

DR. P. A. CALLAN, New York: As to adrenalin, I have used it and found that there have been occasional secondary hemorrhages. As a rule, I do not use it.

There are a few points with regard to cataract extractions that I would like to emphasize: The first is that we should not

keep the patient in bed more than twenty-four hours; that is to say, if I operate in the afternoon, the following morning when the house surgeon makes his rounds the patient is allowed out of bed. That is my invariable rule with combined extractions. The house surgeon removes the bandage without disturbing the eye. I never use the róller bandage—have not for ten years or more. I use cotton with a Ring mask.

For the last three years in every operation where I opened the eye I use immediately after a 25 per cent. solution, and in some a 50 per cent. solution of argyrol. The house surgeon is instructed to put in the next morning a 25 per cent. solution, and when I dress the eye in the afternoon I put in a 25 per cent. solution. I find that cases heal quicker and that the anterior chamber is restored sooner, and I have not had any cases of infection since using argyrol in this way.

The old patients are more comfortable when out of bed the following morning, and by doing away with the bandage the wound is less likely to be disturbed by the patient's restlessness and moving the head about. My original disuse of the bandage came from a patient with very prominent eyes, or one eye rather, the other having been lost previously, in which the wound spread open because of the patient's restlessness and the bandage being disturbed, which resulted in the loss of the eye.

DR. H. O. REIK, Baltimore: I should like to have the privilege of calling the Society's attention more emphatically to the practical utility of these concave iridectomy scissors which Dr. Theobald has devised. To me the performance of the iridectomy has always been the most difficult part of the cataract operation, and most of my complications have been due to faulty iridectomy. Since Dr. Theobald has furnished us with these scissors I have been able to do a much cleaner iridectomy, with no entanglement following, and have been much pleased with their use. At the Baltimore Eye, Ear and Throat Hospital, where all the surgeons and assistants use them, they have given universal satisfaction, and we find them much better than the ordinary iridectomy scissors. I would heartily commend them to the trial of those members who have not heretofore employed them.

DR. J. S. PROUT, Brooklyn: I would like to indorse Dr. Callan's idea of not bandaging the eyes.

As to the iridectomy, I like to do it as a preliminary step

a few weeks in advance. As a substitute for it recently in doing an extraction in the capsule à la Major Smith, when on account of arteriosclerosis I did not wish to cut vascular tissue, I displaced the iris into the wound by using a small probe. By making pressure as directed by Smith the lens escaped in the smoothest possible manner and the iris replaced itself with a perfectly central and round pupil. I am not aware that any one has previously used this method of getting the iris out of the way of the lens, but some years ago Valk suggested using a forceps for this purpose. It seems to me that the probe is safer and better.

DR. SAMUEL THEOBALD, Baltimore: In regard to the use of adrenalin, with which in cataract operations I have had but little experience, I should like to ask Dr. Kipp just how he uses it.

DR. KIPP: I instil one drop of a 1 : 1000 solution.

DR. THEOBALD: I have used it very freely in tenotomies, probing lachrymal ducts, slitting canaliculi, and opening chalazia, and there is no question that in these cases a more marked anesthesia results from its employment, while no ill effects have been observed. I have employed it in the strength of 1 : 1000, alternating with 4% cocain solution, about three applications of each. This is the way I used it in the cataract case referred to, and it may be that the unfavorable conditions produced were due to the too free use of the agent.

In regard to what Dr. Callan says as to the abandonment of the roller bandage, I have not used it for many years. As I state in my paper, I use a very light aluminum shield, devised by the late Dr. Russell Murdoch, of Baltimore, with a pad of gauze over the lids and enough cotton to fill out the concavity of the shield. I have not used the bandage after cataract operation for many years, and quite agree with Dr. Callan that it should not be employed.

THE CHOICE OF OPERATION FOR IRIDOTOMY.

McCLUNEY RADCLIFFE, A.M., M.D.,

Philadelphia.

Haab, in his book on "Operative Ophthalmology," states that: "It may be asserted with confidence and with entire honesty that an ophthalmic surgeon, be he ever so experienced, never is certain when he begins an uncomplicated operation for cataract how it will end." He might have added with equal truthfulness that no one can predict the after-results of a cataract operation, no matter how skilfully the operation is performed, or how carefully the after-treatment is carried out, for the unexpected will at times happen; and, instead of a resultant clear pupil, we find one occluded with a lymph membrane, or the iris so distorted as to completely obliterate the coloboma.

While such results are comparatively rare in proportion to the total number of cataract operations, they are still of sufficient number to warrant the adoption of a distinctive line of treatment—one that will at the same time combine the elements of safety, ease of execution, and yield the best visual results.

The end to be accomplished is, of course, the making of a central artificial pupil. In this we are limited, according to the experiences of the most conservative operators, to three operations, viz., Bowman's, De Wecker's, and the recently published operation of Ziegler—the V-shaped iridotomy with a knife-needle.

Bowman's operation has practically fallen into disuse, owing to the difficulty of its execution and the additional opportunity that two corneal incisions afford for the introduction of infection and the exit of fluid vitreous.

The De Wecker operation is the one that is most generally

used, and frequently with good results, although there are inherent elements of danger in it which cannot be eliminated. It necessitates a large corneal opening, thus affording an easy exit for fluid vitreous and a correspondingly easy entrance for infection, in addition to the extensive traumatism to the eye.

The knife-needle operation possesses all the elements of a perfect operation: ease of execution, safety, and the minimum of traumatism to the eye; and, as a consequence, the visual results are often superior to those of the older operations. It possesses all the advantages of the De Wecker operation without sharing its disadvantages.

Ziegler, in his exhaustive "History of Iridotomy," has well stated the chief advantages of iridotomy with the knife-needle as "ease of incision, the lack of traction on the ciliary body, freedom from post-operative inflammatory reaction, the avoidance of opening an eyeball which may contain fluid vitreous, the lessening of the tendency to iris hemorrhage from lowered tension, and the avoidance of the nebulous scar which often follows a large corneal incision in old inflammatory eyes."

The utility of the Ziegler operation can best be illustrated by brief histories and diagrams of a few cases, which, without such operative interference, would have been absolute failures.

REPORT OF CASES.

CASE I.—J. M., male, aged seventy-eight years. First seen on April 14, 1905. R. E., mature senile cataract. Light perception and projection field normal. I admitted him to St. Joseph's Hospital, and on May 29, 1905, did a combined extraction. There were no complications at the time of the operation; but a few days later a severe iridocyclitis developed, which resulted in almost complete occlusion of the pupil, a minute semilunar opening, about 2 mm., remaining at the upper margin of the coloboma (Fig. 1). I postponed further operative procedure until the late autumn.

On November 17, 1905, I did a V-shaped iridotomy, going well down into the iris tissue, and the membrane opened up into a pear-shaped pupil (Fig. 2), which has remained permanent.

The test for glasses on January 5, 1906, gave the following result: R. E., S + 7.50 ⊂ C + 3.50 ax. 15° = $\frac{20}{20}$, partly. Four months later the refraction had changed to R. E., S + 8 ⊂ C + 3 ax. 15° = $\frac{20}{16}$. With a S + 4 added, reads J. No. 1 fluently. Has worn this correction with comfort ever since.

This was a typical case, as the iris was well stretched and

CASE I.

Fig. 1.—Distorted iris, almost obliterating coloboma.



Fig. 2.—V-shaped iridotomy, with pyriform pupil.

consequently resilient, the pupil opening readily and the apex of the flap dropping down and the base rounding.

CASE II.—S. L., aged seventy years, carpenter. R. E., mature senile cataract. Admitted to the Wills Hospital February 14, 1908. On February 17, 1908, I did a combined extraction, which was smooth and uneventful. Iridocyclitis developed

CASE II.

Fig. 3.—Occlusion of pupil with displacement.

Fig. 4.—Iridotomy, showing shape of pupil immediately after incision.



Fig. 5.—Iridotomy, ultimate appearance of pupil.

on the fourth day. Extensive and dense adhesions formed between capsule and iris, resulting in a small, pear-shaped, and completely occluded pupil (Fig. 3). Vision reduced to light perception.

On April 3, 1908, a V-shaped incision was made in the iris, the pupil spreading out as shown in Fig. 4. Fig. 5 shows the

final shape of pupil. A test for glasses on June 9th gave the following result: R. E. S + 11 ⌓ C + 50 ax 30° = $\frac{20}{20}$ partly.

With a S + 3 added for working, could read the small divisions on carpenter's square, and with S + 4 read J. No. 1. The ultimate aphakic change nine months later gave the following result: R. E., S + 11.50 ⌓ C + .50 ax 180° = $\frac{20}{20}$ partly.

This patient has been able to follow his trade as a carpenter since his first glasses were ordered, April, 1908.

CASE III.—Wm. C., aged eighty years, farmer. Admitted to my clinic at the Wills Hospital on November 11, 1908, with mature senile cataract of right eye. On November 16, 1908, the senior house surgeon did a combined extraction. A violent iridocyclitis developed within three days, which subsided after vigorous antiphlogistic treatment, leaving the coloboma filled with thickened capsule and adherent iris, as shown in Fig. 6.

On January 27, 1909, I made a V-shaped incision of the iris, as shown in Fig. 7. There was considerable reaction following

CASE III.

Fig. 6.—Occluded and distorted pupil.



Fig. 7.—Iridotomy, with resultant pupil.

the iridotomy, which subsided under ice, atropin, and leeching. He was discharged on March 2, 1909, with the following temporary correction for distance: R. E., S + 9.50 ⌓ C + 3°. ax 180° = $.\frac{20}{70}$. He is to return later for final correction.

CASE IV.—T. M., aged eight. Admitted to Wills Hospital on February 24, 1909. Was struck on R. E. two days previously by a flying piece of wood, causing an irregular penetrating wound of the cornea, extending from the equator down and into the sclerocorneal margin. The contused iris was caught in the wound; pupil elliptical; small hypopyon; lens opaque.

On March 26, 1909, the soft lens cortical was removed. The eye did well, but owing to the attachment of the iris to the

cornea and the capsule of the lens, the pupil was gradually drawn down into a mere slit, filled with thickened capsule and lymph, as shown in Fig. 8.

On April 12, 1909, I made a V-shaped incision in the iris tissue, with the result shown in Fig. 9. Fig. 10 shows the

CASE IV.



Fig. 8.—Pupil occluded, and iris caught in wound of cornea.

Fig. 9.—Iridotomy, immediate result.

Fig. 10.—Iridotomy, final result.

ultimate shape of the pupil. Owing to the nebulous condition of the cornea, the correcting lens, S + 12, only gives $\frac{6}{200}$, but the enlarged pupil gives him protective vision to the right side.

CASE V.—W. C. C., aged fifty-four; carpenter. Admitted to the Wills Hospital November 24, 1908, for mature cataract of right eye. A combined extraction was done, with slight loss of vitreous owing to the straining of the patient at the close of the operation. Three days later he had a hemorrhage in the

CASE V.

Fig. 11.—Dense pupillary membrane and distortion of iris.



Fig. 12.—Iridotomy, showing shape of pupil after incision.

Fig. 13.—Iridotomy, ultimate result.

anterior chamber, probably the result of striking his eye during the the night. Iridocyclitis followed, which yielded to treatment, and he was discharged December 19, 1908, to return later for the secondary operation. He was readmitted on April 13, 1909, with a condition as shown in Fig. 11. Three days later I made

a V-shaped incision in the iris, as shown in Fig. 12. Fig. 13 illustrates the final appearance of the pupil. With S + 12.50 ⊂ C + 1.50 ax. 150° = $\frac{20}{60}$, partly. With S + 3.50 added, he reads J No. 3.

CASE VI.—Mrs. S. R., aged sixty-seven, admitted to my clinic at the Wills Hospital on March 24, 1909, for mature senile cataract. Light perception and projection field normal.

On March 26th I did a combined extraction, some cortical matter remaining. Four days later an iridocyclitis developed, which subsided under the usual treatment of atropin, ice, and leeching, but left the eye as shown in Fig. 14.

On April 28th I did a V-shaped iridotomy with the immediate

CASE VI.

Fig. 14.—Occluded pupil in a soft eyeball.

Fig. 15.—Iridotomy, immediate result.



Fig. 16.—Iridotomy, final result.

result as depicted in Fig. 15. The present appearance of pupil is shown in Fig. 16.

It is too early to give the visual result, as there was some inflammatory reaction following the operation, which is rapidly subsiding.

I have found the V-shaped incision equally applicable and satisfactory in operations on thickened capsules, as is well demonstrated by the following case and illustrations.

CASE VII.—C. K., aged thirty-eight, mechanic. Admitted to Wills Hospital January 3, 1908. Struck by piece of steel in L. E. three years previously. Lens cataractous. Vision, fingers at 3 feet; contracted visual field. R. E., vision failed during December, 1907; counted fingers at 3 feet. Projection field normal. No history of injury. Lens swollen and cloudy. No fundus details could be seen. Small mass suspiciously like foreign body imbedded in lens at the equator, near nasal margin. Radiographs showed foreign body in L. E., but none in R. E.

On January 8, 1908, I operated on right eye, and removed the soft lens cortical, and with it a small foreign body 1½ mm. by ¼ mm., and very thin. Two weeks later the eye presented the appearance as shown in Fig. 17, and I then made a V-shaped

CASE VII.



Fig. 17.—Thickened capsule.



Fig. 18.—V-shaped capsulotomy showing resultant pupil.

incision in the thickened opaque capsule, with the result as illustrated in Fig. 18. The visual test gave the following result: R. E., S + 14 ⌒ C + 1 ax 180° = $\frac{20}{16}$. With a S + 3.50 added, reads J No. 1 fluently.

REMARKS.

The requisites for the successful performance of this operation of V-shaped iridotomy are four:

1. A properly shaped and perfectly sharpened knife-needle. I have adopted Ziegler's modification of the Hays knife-needle (Fig. 19) as the one that best meets all requirements.

Fig. 19.—Ziegler's knife-needle.

2. All pressure must be absolutely avoided in making the incisions.

3. A gentle sawing motion. In this, and the avoidance of pressure, lies the real secret of success in the operation.

4. Perfect artificial illumination is an absolute necessity, and particularly so in capsulotomies, where the membranes are filmy or web-like in structure.

After a somewhat extensive experience in performing this operation during the past four years I unhesitatingly recommend it as the operation par excellence for iridotomy and capsulotomy, as the safest, easiest of execution, and, above all, as the one that yields the best visual results.

I am indebted to my chief assistant at the Wills Hospital, Dr. Geo. Robinson, Jr., for the excellent drawings which he has made of the cases here illustrated.

DISCUSSION.

DR. P. A CALLAN, New York: The writer says that, according to the experience of the most conservative operators, we are limited to three operations, namely, Bowman's, De Wecker's, and Ziegler's—the V-shaped iridotomy with the knife-needle. This latter operation, he says, possesses all the advantages of the De Wecker. Now, let us stop and think a moment [drawing on the board]. You introduce the knife-needle here, and you can cut this tough membrane without any traction; how is that supported? By the periphery of the iris and the vitreous, and no matter whether you use a sawing or other motion, the moment you make an opening, the vitreous comes in and you make traction. It is impossible to do otherwise. The first incision is easy, because you have a taut membrane; but the second is more difficult. Now that stiff membrane will turn down and give you an opening like this [illustrating]. I think the doctor has been extremely fortunate in his results.

On the other hand, the membrane to be cut is supported between the two blades of the scissors and there is no traction whatever, and you can get any shape you want. We are told that a large incision is necessary for the introduction of the scissors; now, the knife is 1½ mm. in width, and in New York we use the scissors which are 3 mm. It is true that is 1½ mm. more than the knife, but the scar is practically the same. It is exceptional that we lose vitreous, and I have not in twenty-five years seen any inflammatory reaction following the use of the scissors, but I have seen eyes lost by this same method which is so strongly advocated. You can take your choice.

The knife-needle is only applicable to a diaphanous membrane, in such cases as Knapp advocated its use. In one case you use pressure in order to cut, and that pressure is on the

vitreous and on the periphery of the iris. I was unfortunate, years ago, to lose one eye with the knife-needle, and others have lost them, and will continue to lose them if they follow this method.

DR. P. N. K. SCHWENK, Philadelphia: In order to add another operation to the list, permit me to show you a procedure that has proved quite successful in my hands in cases of iridocyclitis following lens extraction—where the pupil invariably is drawn up to line of incision. I take a Hays knife, make a puncture through the cornea at the outer third, a counter-puncture in the iris at the inner third, and then a vertical incision in the iris equal in size to the diameter of pupil desired. Withdrawing the knife until the cutting-edge is brought into the corneal puncture, this is enlarged vertically 3 mm. or more, until the opening will admit a blunt iris hook without any difficulty. A blunt iris hook is introduced on the flat into the corneal opening, the hook passed over the outer cut edge of the iris, the instrument rotated with the engaged edge of the iris so that its flat side will engage through the corneal incision, the iris drawn out, and the projecting part cut off. This can be done with but little traction on the iris, as the anterior chamber will have been emptied of most of its aqueous, and you will have a "D"-shaped pupil. This operation is applicable principally where iris has to be removed to make an artificial pupil. It is the simplest of all the operations I have employed.

DR. G. E. DE SCHWEINITZ, Philadelphia: In my earlier operative experience I was accustomed to use the De Wecker operation in the cases at present under consideration almost entirely, especially after a visit to the clinic of that distinguished operator, where I may say I never saw more skilfully performed operations or better results. At that time I had not had the pleasure of seeing Dr. Callan operate. Because, however, of certain dissatisfactions with the operation, I abandoned it and took up Dr. Knapp's method, to which reference has been made. When Dr. Ziegler first devised his operation, he permitted me to make the first reference to it in one of the editions of my text-book, and I am rather proud that he did, because, in spite of what Dr. Callan has said,—and no one has a higher regard for his skill and large experience than I have,—

in my judgment the Ziegler operation is far superior in its results to any other technical procedure with which I am acquainted under similar circumstances. I am quite aware that the second incision of the Ziegler operation is more difficult to make than the first one, and that there must be some traction, but I do not believe that this traction, when made with Ziegler's modification of the Hays knife-needle, is anything like as great as the amount of traumatism which is produced by the ordinary De Wecker operation. My results with the Ziegler procedure have been so good that I have no hesitation in recommending it, and I am thoroughly convinced that it is an operation which has come to stay.

DR. H. F. HANSELL, Philadelphia: I have used this knife only for the past year, and with absolute satisfaction. I have in each case been able to secure the desired pupil, of good size and clear, and allow the patient to leave the hospital in twenty-four hours. In all my cases there has been no such membrane as that described in the paper, but simply the usual thin capsular or after-cataract. I believe the operation is superior in these conditions also. The knife itself is perfectly easy to handle, and with its cutting-edge sharp, and the cutting done by alternately thrusting and drawing, traction is reduced to the minimum.

DR. S. LEWIS ZIEGLER, Philadelphia: I am afraid Dr. Callan has either used some other knife-needle, or else has not practised the operation sufficiently to acquire the proper technic, because you certainly cannot make an incision of this kind with this knife-needle if you make traction on the membrane. You must make the most delicate pressure in using the long sawing movement, and it is only in this way that you can accomplish the result.

As compared with the De Wecker method, I may say that I have seen De Wecker operate on many cases, and I have done a few De Wecker operations myself in the past twenty years, but only a few; on the other hand, I have used this knife-needle in hundreds of cases. I have probably had a few failures, but it has certainly been the most uniformly successful of any method that I have tried. I am perfectly willing to abandon it if any one can show me something better.

Dr. Radcliffe should be congratulated on the uniformly excellent results he has achieved. I have only seen him operate on one of these cases, but have seen several at the end of treatment, and can testify to the excellent character of the final results as illustrated in his paper. He uses, I believe, the long knife-needle which I have always employed, because it gives the long leverage so essential to the success of this operation. Many have said that they find this instrument too long for easy manipulation in the anterior chamber, and I have, therefore, asked the manufacturer to make the blade in three different sizes, 5 mm., 6 mm., and 7 mm.

Some have complained of the loss of aqueous, but that is impossible if the instrument has been properly made and if the correct technic has been acquired. They have probably used the long knife-needle and brought the blade out through the cornea a second time in making the incision. I am informed by some that they employ the knife-needle as a cystotome to make a V-shaped incision in the capsule, while others claim to perform this cystotomy through a corneal puncture before making the flap incision. I cannot see the desirability of such a procedure. I have usually confined the operation to three features, iridotomy, capsulotomy, and discission of soft cataract, in all of which I have had success.

DR. LUCIEN HOWE, Buffalo: It may be worth while to add one word, as evidence of what De Wecker thought of his operation for iridotomy. I was in his clinic many years ago, at the time when one of his volumes came out. Naturally I spoke of it as being a great contribution to ophthalmology, and I remember his reply. He said, "No, I think that small operation of iridotomy was as good as anything I have done for ophthalmology."

The president has shown me an instrument for iridotomy which is a recent one, made on the principle of a punch. Many years ago I also tried one like it. When it enters the anterior chamber it opens, and, inclosing a piece of the iris, punches it out. It was very beautiful as a theory and I had one made. You could cut paper with it nicely, but I found that it would not cut the iris at all.

Finally, in regard to introducing a hook to draw out the iris. I tried that only once. But only with the greatest difficulty

could I withdraw it, and I was glad, for both myself and the patient, when I got that hook out of the eye.

DR. P. A. CALLAN, New York: There are two iris punches on the market, Stevenson's, and DeLaPersonne's, of Paris. They work excellently, but you need a large corneal opening. I have used them in four cases and they do the work beautifully.

DR. CHARLES J. KIPP, Newark: As to the iris punch, I think Stevenson has priority. I have used it, but you have to make a very large incision.

DR. DAVID WEBSTER, New York: I must confess I have had very few cases of closure of the pupil occurring in my own practice. Of course, I have had many cases of membrane following a cataract extraction, and there has rarely been any difficulty in making an opening through these with Knapp's knife-needle. But I have had three or four closures, and in two of these I used the De Wecker scissors with good results and in the others Wilson's (of Bridgeport) little knife. It is a diminutive Graefe cataract knife.

DR. S. B. ST. JOHN, Hartford: I saw this instrument at Naples [exhibiting iridotomy instrument]. An instrument-maker of Heidelberg was showing it as something new. I found on showing it to the members that there is nothing new about it. It is an example of that kind of an instrument referred to as the iris punch.

I want to remind the older members of Dr. Agnew's method of dealing with these cases, in which he used to make two corneal incisions at the same time, using two iridectomy knives. He used to do it with these two knives working toward each other; then, withdrawing them, he had two small slits, and he put a hook in each and tore an opening in the membrane without dragging on the ciliary body.

DR. W. B. JOHNSON, Paterson: Dr. Agnew also used one little sharp iris hook, with one incision, introducing the hook and drawing the membrane out and cutting it off. I have seen him do that a number of times with perfect success.

DR. SAMUEL THEOBALD, Baltimore: I was very much inter-

ested in seeing these knife-needles of Dr. Ziegler's. When I looked at the illustration, I said, "Why, that is Dr. Hays' needle-knife," but when I saw the knives, I realized what the difference was.

I think Dr. Ziegler is very wise in following, in other respects than the length of the blade, Dr. Hays' model. I have a Hays needle-knife that belonged to my grandfather. They did not realize in those days the importance of making the shank of such size as to fill the corneal wound and prevent escape of aqueous, but that is the only fault in the Hays instrument. It is, in my opinion, the best instrument we have for operations for secondary cataract. The long blade which Dr. Ziegler has introduced doubtless makes it better for the special purpose he has spoken of. I should think, however, that it would be difficult, without going deeply into the vitreous humor, to keep the cutting-edge beyond the corneal wound, and if this were not done, the wound would necessarily be enlarged as a result of the sawing movement.

DR. MCCLUNEY RADCLIFFE, Philadelphia: In reply to Dr. Callan's criticism of the operation, I desire to call his attention to the fact that there is a minimum amount of traction in this operation. It is decidedly less than in the De Wecker operation. Of course, there must be some traction, but it is reduced to the minimum by the sawing motion, which is the most difficult part of the operation to learn. We have an illustration of this motion in the carpenter's use of the saw. He will tell you that if you put any pressure on the saw it will bind; it is the weight of the saw that cuts. Dr. Callan said he had formerly used a knife-needle, but I would call his attention to the fact that doubtless it was different from the knife-needle that Dr. Ziegler advocates, and which I have used; that would make a great difference.

He spoke of the fluid vitreous coming up after the first incision. That, of course, happens; but how much greater that would be if the anterior chamber were opened by an incision twice as large, and which is not filled, as in the knife-needle operation. The shank practically fills the opening, and there is no chance for the escape of aqueous and no opportunity for the escape of the vitreous.

With a stiff membrane there is, of course, some difficulty in

cutting it, and also some difficulty in the dropping down of the flap; and where that occurs, you have the alternative of opening the anterior chamber and pulling the flap down, and cutting it off with proper scissors.

As a surgical procedure, I think the operation is a perfectly rational one, even if you do not get perfect vision in all cases. The knife is introduced diagonally, and when you withdraw it, there is a flap which closes, and there is practically no means for the entrance of infection. I cannot recall any failures I have had with it. I do all my capsulotomies with this method and have better results than ever before.

I was glad to hear Dr. de Schweinitz speak of his success with this operation, for I think, as he said, it is the coming operation; and the more we use it, the more we shall be pleased with it.

THE TREATMENT OF THE EYE WHEN THE GLOBE IS INFECTED, WITH THE OBJECT OF PREVENTING PANOPHTHALMITIS.

A. EDWARD DAVIS, M.D.,

New York.

In a comparatively recent paper on the operative, post-operative, and traumatic infections of the eye, H. F. Hansell,[1] of Philadelphia, has reviewed the well-recognized forms of treatment in such cases; *e. g.*, (1) cauterants to the wound, as carbolic acid, galvanocautery; (2) subconjunctival injections of bichlorid or cyanid of mercury; (3) the introduction into the anterior chamber of iodoform rods; (4) the injection into the interior of the eye, preferably into the anterior chamber, of bichlorid of mercury solution (1 : 3000) by means of a hypodermic syringe. The author, in a case of his own,—infection after cataract extraction,—after cauterization of the wound had failed, injected 5 minims of 1 : 3000 bichlorid solution into the anterior chamber and saved the eye with useful vision.

The object of this paper is to give briefly å report of some clinical observations, made during the past winter, in the treatment of the eye when the globe was infected. It is with special reference to the use of argyrol in these cases and the method of its employment to which I wish to call attention. The number of cases observed—four in all, one following discission for secondary cataract, and three from truamatism—is very small indeed, but the results were so satisfactory, at least in warding off panophthalmitis in all of the cases, and in preserving useful vision in one (the discission case), that I venture to report them.

CASE I.—*Infection of the globe following discission for secondary cataract, three years after the extraction.* M. J. F., aged fifty-eight years, was operated upon by me, March 15, 1906, for senile cataract in the right eye. The patient made an uneventful recovery in ten days' time with vision $\frac{20}{40}$. There was a light membrane in the pupil, but the patient refused a discission at that time, as he had perfect vision in the left eye, $\frac{20}{20}$. On November 10, 1908, the patient returned on account of sudden loss of vision in the left eye. Examination showed in the left eye, partial detachment of the retina, far forward on the temporal side, with shelving edges, which aroused my suspicions as to a sarcoma underlying same. However, transillumination of the pupil was not interfered with on using the Würdemann transilluminator. By November 16, 1908,—six days after coming under observation,—the whole lower portion of the retina as well as the anterior temporal part was detached. The patient was sent to the hospital for observation and treatment of the left eye, which consisted of atropin, bandaging, and lying in bed on his back. I advised, while he was undergoing this treatment, a discission of the membrane in the right eye, which had thickened in the last three years, reducing the vision to $\frac{20}{70}$. Accordingly, under cocain anesthesia, the discission was made on November 17th, the instruments being sterilized by boiling and then dipping in 95% alcohol and later in sterile water. The patient's face and the outer surface of the lids were washed by bichlorid 1:3000, and the eyeball with a saturated solution of boric acid. The conjunctiva and lids were in perfect condition, no inflammation whatsoever being present. Wilson's knife-needle was used and a horizontal incision 3 mm. in length was made across the membrane. Bandage was applied. Extraordinary precautions were taken in antisepsis in this case, especially as the patient had detachment of the retina in the opposite eye, with a possibility even of sarcoma, and the eye might have to be sacrificed. The day after the discission the bandage was removed, the eye was quiet, and no dressings were reapplied. On November 19th, two days after the discission, right eye was slightly red; November 20th, patient had pain in the eye during the night. The eyeball was now red and the ocular conjunctiva slightly edematous, and the upper lid red and somewhat swollen. Atropin and hot fomentations were ordered for the eye, the bowels were opened thor-

oughly with calomel and soda, and calomel, $\frac{1}{10}$ grain, was ordered t. i. d. November 21st, all symptoms greatly aggravated and the anterior chamber half filled with pus, with grayish lines extending from the cornea into the pupil and vitreous. The cornea remained clear, however. A paracentesis of the cornea was made, pus evacuated, and three or four drops of a 2% solution of argyrol was injected into the anterior chamber. November 22d, the following day, the eye was better, less redness of the eyeball and the lids. Atropin and hot fomentations continued. November 23d, a small amount of pus in the anterior chamber again. A second paracentesis of the cornea was made, and again a 2% solution of argyrol injected. The wound, which was at the lower sclerocorneal margin, was reopened the next day by probing with an iris spatula, after which it was allowed to close. From this day, November 24th, no more pus formed, and, under the continued treatment of atropin, hot fomentations, and calomel, the patient made a good recovery with vision equaling $\frac{20}{70}$, the same as before the discission; tension normal. Incidentally, I may say that the detached retina in the left eye completely reattached, with restoration of the field, patient having been in bed about three weeks. This reattachment has remained four months, when patient was last heard from. In other words, the patient made a recovery from two diseases, either usually counted fatal to sight. No bacteriological examination of the pus from the eye was made in this case, I am sorry to say.

CASE II.—J. W., aged four years, admitted to my service at the Post-Graduate Hospital, December 6, 1908. Two weeks previous to admission the patient had stuck a fork into the globe of the right eye, wounding the cornea and iris. Patient had been treated as an outdoor patient at a dispensary in the meantime. When first seen by me, he had two perforations near the center of the cornea, the iris was hazy, pupil contracted and irregular, the anterior chamber about half full of pus, and redness and swelling of the conjunctiva. Under the usual plan of treatment, hot fomentations, atropin, calomel, etc., the condition of the eye became gradually worse until December 11th, when the anterior chamber was filled with pus completely hiding the iris. The conjunctiva was decidedly edematous, lids somewhat swollen, and panophthalmitis seemed imminent. The general condition of the patient at this time was not the best,

as there were symptoms of general infection, acceleration of the pulse, respiration and rise of temperature—about 101.° Under a surgical anesthesia, December 11th, five days after admission and about eighteen days after the injury, a paracentesis of the cornea was made and considerable pus evacuated from the anterior and posterior chambers by gentle expression and manipulation with spoons. After this 2 or 3 mm. of a 20% solution of argyrol was instilled directly into the anterior chamber by means of an eye-dropper, and a compress bandage applied. With the continuance of hot fomentations, atropin and also argyrol instillations into the conjunctival sac, there were no further evidences of pus formation in the eye, and in two weeks the eye was perfectly quiet, although no vision was preserved. In the meantime, however, the general condition of the patient did not improve correspondingly; in fact, at one time there was a sharp exacerbation in the temperature, which went up to 105°, but with doses of quinin and salicylic acid the temperature was reduced, and the patient was discharged December 27th with the eye entirely quiet, and it has remained so since and without sympathetic symptoms. No bacteriological examination was made.

CASE III.—A. C., a child of the same age, admitted to my service four weeks after the above case, presenting the exact clinical picture, the globe of the eye having been punctured by a fork, resulting in a pus formation, marked edema of the conjunctiva, with swelling of the lids. Under a similar line of treatment the eye was saved, but without vision. In this case also no bacteriological examination was made.

CASE IV.—Thomas D., aged two years, admitted to my service at the Post-Graduate Hospital, March 11, 1909. Two weeks previously the child fell with a knife in his hand and received an injury to the right eye and right upper eyelid. When seen by me, the upper lid was cut through to the extent of $\frac{1}{3}$ inch vertically and about $\frac{1}{4}$ inch from the inner canthus. The globe of the eye was punctured at the sclerocorneal margin on the temporal side. The anterior chamber was partially filled with pus; ocular conjunctiva injected and edematous; the eyelids swollen. Under surgical anesthesia the lid was sutured, and the wound at the sclerocorneal margin of the cornea, temporal side, was enlarged at its lower end, and a large mass of thick, tenacious pus was removed from the

anterior chamber with forceps. The vitreous was also infected, grayish lines of pus extending into it. In this case the pus reformed two or three times in the anterior chamber, which was evacuated and the anterior chamber in each instance injected with 10% solution of argyrol. In this case atropin was used twice daily, hot fomentations applied several times during the day, and the patient was discharged on March 14th —eleven days after admission. The eye cleared up, but there was some circumcorneal injection and slight shrinkage of the eyeball at the time of discharge of the patient. Two weeks later the child was readmitted on account of sympathetic symptoms in the left eye. At this time the offending eye was somewhat red and irritable. Two days later the injured eye was removed and all sympathetic symptoms disappeared from the opposite eye. The bacteriological examination in this case showed pneumococcic infection.

In connection with this last case, where sympathetic symptoms developed, it is interesting to note Schirmer's[2] treatment in similar cases, where he claimed not to have had any sympathetic inflammation follow. The author, during the past ten years, had instituted a long-continued, conservative treatment in 157 infected eyes after perforating wounds. In spite of the fact that among these there were certainly many inclined to sympathy, he had never observed a case of sympathetic inflammation during mercurial treatment, nor within three months after its discontinuance. He used the mercury to its full physiological effect. He concludes, therefore, that mercury exerts a prophylactic action against sympathetic ophthalmia, and considers this method of treatment preferable to injecting iodin. The fear of sympathetic ophthalmia has always been the chief obstacle, he thinks, to an adequate and long-continued treatment. During the past eight years Schirmer has seen a total of fifty cases in which the abscess was visible as a yellowish or grayish reflex from the vitreous, or the abscess had been found on exenteration or enucleation of the eyeball; 48% of these cases had to be exenterated or enucleated; of the remaining

52%, there was perfect recovery of 36% with preservation of vision. This is certainly a remarkable achievement, considering the gravity of such cases.

In looking over the literature on the use of argyrol in ophthalmic practice I find that H. V. Würdemann, in a personal communication, cited by C. A. Wood,[3] has used argyrol in 50% solution, "introduced into the anterior chamber through corneal incisions or wounds, and has thereby saved many eyes with hypopyon iritis."

Dr. E. S. Thomson[4] read before the New York State Medical Society a paper in which he cites a case from the clinic of Dr. F. N. Lewis, of the Manhattan Eye, Ear, and Throat Hospital, in which there was an infection following an extraction in a patient with inflamed eyelids. The wound in this case was reopened, the pus evacuated from the anterior chamber, and a 25 % solution of argyrol injected, "with remarkable checking of the process, and without any irritation to the iris whatsoever."

Angus McGillivray,[5] in a recent article, "The Uses and Limitations of Argyrol in Ophthalmic Practice," claims that in pneumococcal infection of the cornea (ulcers) the use of argyrol, even a 25% solution, and when applied frequently, is a failure; and in such cases no time should be lost in applying the cautery. It is interesting to note in this connection, in Case IV, reported by me, in which bacteriological examination was made and pneumococci found, that argyrol was effective in preventing panophthalmitis. It will, therefore, require wide clinical observations to arrive at an accurate estimate as to the value of different methods of treatment, medicinally or with serum and vaccine therapy, in these infections of the eye. That argyrol is efficacious in the treatment of acute inflammatory infections of the conjunctiva and tear sac, especially where there is much secretion, as in ophthalmia neonatorum, acute catarrhal conjunctivitis, etc., has been proved by abundant clinical experience. As to the value of this treatment by the injection

method here described, in infections of the globe of the eye, more cases with bacteriological examinations must be noted to make a definite decision. Infection of the globe is such a grave condition that any form of treatment, not too risky, and promising relief and possible preservation of useful vision, should be given a trial.

This is an opportune time and place also to refer to bacterial and serum therapy, which in the last few years has been used successfully in infective diseases, not only of general infection but also of the eye. Recent reviews on the subject are by Prof. Axenfeld,[6] Percival J. Hay,[7] and E. E. Irons.[8] The statement made by Irons, that prophylactic and curative sera, bacterial vaccines, and the specific diagnostic serum and bacterial reactions, with a few exceptions, are still in the experimental stage, is shared in by all these observers. As to the vaccine treatment (active immunization), Hay states that "it is only applicable by itself to chronic or subacute cases, because a certain length of time—on an average, a week or two—needs to elapse before the protective substances against the disease are produced in quantities sufficient to be of any use." It is needless to more than mention the fact that we are to expect but little from active immunization alone; that is, the injection of live or dead cultures of microörganisms in the treatment of acute infections of the eye. From the curative serums, however (passive immunization), much aid of a practical and effective kind is expected, and, in fact, has already been accomplished in the treatment of infective diseases of the eye; for example, in serpiginous ulcers of the cornea, hypopyon keratitis and iritis, infective wounds of the globe, perforating wounds, post-operative wounds, etc. But even here great difficulties in the use of serums, especially bactericidal serums, have been encountered, particularly in the treatment of deep infections, especially of the vitreous, which under normal circumstances does not share in any kind of immunity whatever. It only begins to show traces of immunity bodies after frequently

repeated paracentises or subconjunctival injections, or during inflammation (Axenfeld[9]). Even saprophytic germs may become pathogenetic in the vitreous. The same holds true in regard to the aqueous humor and the bacteriocidal immune bodies; none of the latter passing into the former from the blood until after repeated punctures of the anterior chamber, or by subconjunctival injections, or after active inflammation. The normal cornea, however, as has been pointed out by Loeffler, shares in general bacteriological immunity. It is only after abrasions that it is so liable to infection.

Because of lack of immunity on the part of the aqueous and the vitreous, antibacterial serum therapy, active or passive, must, in intraocular diseases in which the infection has extended to the media, experience great difficulty in its combat against bacteria (Axenfeld). They should be used, however, as an adjunct to other methods—surgical and medical—especially in acute and virulent infections.

Much discussion has arisen lately as to the relative value of *specific* and *non-specific* serums, Darier, Deutschmann, von Hipple and others, on the one hand, claiming that just as good or better results obtain by the use of non-specific serums, or with specific serums used for affections other than those for which they are a specific; *e. g.*, antidiphtheritic serum, the yeast serum, etc., as are to be obtained with the specific serums.

On the other hand, Axenfeld insists that we should use specific serums for each infection as far as it is possible; otherwise the whole matter becomes one of empiricism. This latter author doubts the accuracy of Deutschmann's observations in cases of infections reported by him, and ridicules the idea that it is not feasible to know the microörganisms at the basis of different infective processes. "What a great step forward it would be if it were to be confirmed! Only think; it would be quite unnecessary to determine the special etiology of any infection!"

Deutschmann,[10] who published his results in 1907, used a

serum obtained from rabbits which had been fed on yeast. This serum was supposed to be polyvalent, and, although it manifested neither bactericidal nor antitoxic properties, he claimed it was most potent in the treatment of certain general infections (staphylococci and streptococci), and even in tubercular infections, as well as in the treatment of inflammatory infections of the eye; *e.g.*, hypopyon keratitis, purulent iridocyclitis, perforating wounds, wound infections, post-operative infections, etc.

Von Hipple [11] has used this same yeast serum in similar cases, and reports most excellent results. To test the value of this serum, Axenfeld requested his assistants, Happe[12] and Szily, to make some experiments on rabbits. In all, 100 inoculations of pneumococci or staphylococci were made into the cornea, anterior chamber, and vitreous. Fifty of the rabbits had been previously immunized, part of them fed with sterile yeast tablets, and part of them injected with Deutschmann's yeast serum or antidiphtheritic serum. Fifty of the rabbits were not immunized at all, but were used as controls. The experiment failed to determine the bacteriological effects of Deutschmann's yeast serum, either as a prophylactic or as a cure.

"Treated animals when injected into the vitreous by pneumococci not only developed panophthalmitis, but even died in a few days, exactly as did the control animals; that is, the serum did not exhibit any influence against either local or general infection" (Axenfeld).

Antidiphtheritic Serum.—This, the best known of all the serums, besides being used as a specific serum in diphtheritic infections, has been used in many other infections, general and local, several observers claiming that it is polyvalent.

Darier [13] especially is of the opinion that non-specific serum therapy should take a very important part in general therapeutics and in prophylaxis and all constitutional and local infections. The Roux-Behring antidiphtheritic serum he con-

siders the best and most reliable, and he reports marked success in the treatment of the infections of the eyes through its use; for example, in purulent conjunctivitis, gonorrheal conjunctivitis, conjunctivitis of streptococcal origin with ulceration of the cornea, keratitis of pneumococcal origin, hypopyon keratitis, traumatic iridocyclitis, perforating wounds, post-operative infections, etc. He uses it also as a prophylactic in operative and traumatic cases. Usually he makes three injections of 10 c.c. of serum, on three successive days. However, he does not rely on the serum treatment alone, but follows the usual local treatment, including surgical interference; and, where the above methods fail, he resorts to intravenous injections of collargol; *e. g.*, in septic ulcers, panophthalmitis, and infective operative cases. It is quite evident that Darier is not willing to depend on the serum treatment alone in these cases, especially in the more serious cases of infected wounds of the globe, serpiginous ulcers of the cornea, etc.

Antipneumococcic Serum of Roemer.—This serum has been used especially in pneumococcic infections of the cornea (serpiginous ulcer); also in some general infections, as in pneumonia. In the general affections it has proved inefficient, and in serpigenous ulcers it has not proved very satisfactory. In his later reported cases Roemer combined active immunization (injections of dead pneumococci) with passive immunization (the serum), and with the combined treatment the results were apparently much superior to the passive treatment alone; as in a series of 24 cases of serpiginous ulcer he secured healing in 20. Two of these, in which serum treatment failed, required surgical interference—galvanocautery—and two developed panophthalmitis. Commenting on the antipneumococcic serum Axenfeld states that it may be used as a "help" in these cases, but it does not act so certainly that it can take the place of surgical means. It is only justifiable to try an exclusive serum therapy in those cases which, in consequence of their benign character, can be treated by conservative methods, and in

those in which the other treatment is not capable of arresting the destruction of the cornea.

Roemer[14] has given a great deal of attention to the development of the pneumococcal serum, and has brought out a polyvalent serum; that is, by the injection of several strains or varieties of pneumococci into an animal, he has produced a serum that acts against more than a single strain of pneumococci; in other words, it is polyvalent. This polyvalent serum, however, seems not to have proved altogether effective in the treatment of pneumococcal affections of the eye, although the results were better than in the first experiments.

Antistreptococcic, antistaphylococcic and antigonococcic serums are still more or less in the experimental stage, especially the latter two. Simeon Snell[15] reports a case of a man, aged thirty-six years, admitted to the hospital with both lids of the right eye filled with a large suppurating mass and with marked symptoms of general sepsis. Several injections of antistreptococcic serum arrested the progress and ended in a complete recovery.

In contrast to this is the case cited by Maddox,[16] where he reports a virulent infection of the eye after cataract extraction, in a man aged seventy-six, the condition of the eye apparently being beyond recall as far as vision was concerned. Treatment consisted of antistreptococcic serum and yeast tablets without effect; then, by one injection of Wright's antistaphylococcic vaccine (s. aureus) into the back of the patient, the eyes began to clear on the following day, the pus was absorbed from the anterior chamber and the patient made a good recovery. Silver nitrate, however, was brushed along the edge of the wound as an adjunct to the treatment. A discission made some months later gave the patient $\frac{7}{12}$ vision, which he maintained. No microscopic examination was made to determine the nature of the exciting organism.

H. Grimsdale[17] cites a case similar to the above, in a case of cataract extraction in a man, aged seventy-six years, followed

by virulent infection of the eye. Six days after the extraction the patient was treated by the vaccines of staphylococci, given by the mouth, 1,000,000 given the first dose and increased 1,000,000 each week for six consecutive weeks. Patient made a good recovery, with vision $\frac{6}{9}$. The same author reports a case of metastatic infection from a tooth abscess, in a blind eye with detachment of the retina. Panophthalmitis was imminent, but by three doses of antistaphylococcic vaccine given by the mouth,—1,000,000 the first dose and 2,000,000 and 4,000,000 in the two following weeks,—the infective process cleared up completely. In neither of these cases was a microscopic examination made to decide the nature of the exciting organism.

The vaccines seemed to act admirably in these cases, although they are not supposed to be of great value in the treatment of acute virulent wound infections in which a rapid effect is of importance; for in these cases, as Axenfeld has pointed out, we have less to expect from vaccine immunization, as the formation of antibodies after the injection of living or dead bacilli requires, generally, a certain time.

Conclusions.—1. In the treatment of infective processes of the eye, especially in those due to traumatism, perforating wounds, post-operative infection, etc., the well-established methods of treatment, medicinal and surgical, must yet hold a prominent place in the attempt to relieve these desperate conditions.

2. Argyrol, in solutions from 2% to 30%, may be safely injected into the anterior chamber, and seems to be of marked value in arresting virulently infective processes, such as hypopyon keratitis, iritis, wound infections, and post-operative infections.

3. Serum and vaccine therapy have proved of benefit in certain infective processes, but in the more virulent forms they should not be relied upon exclusively, especially in the deep infections of the eyes and where the vitreous is involved.

4. A combination of medicinal, surgical, and serum therapy, holds out the best hope for recovery in the most serious cases, and all three should be tried when available.

1. H. F. Hansell (Philadelphia): Annals of Oph., vol. xv, p. 537, 1906.
2. Schirmer: Report 33d Meeting Oph. Soc., Heidelberg, Aug., 1906. Knapp's Archives, vol. xxxvi, p. 254, 1907.
3. C. A. Wood: "Ophthalmic Therapeutics," p. 90.
4. E. S. Thomson: N. Y. Medical Record, May 30, 1903.
5. Angus McGillivray: "Ophthalmoscope," London, May, 1907.
6. Axenfeld: Oph. Review, London, Jan., Feb., Mar., 1909.
7. Percival J. Hay: Ophthalmoscope, London, p. 496, 1908.
8. E. E. Irons: "Ophthalmic Therapeutics," pp. 183 to 206.
9. Axenfeld: Oph. Review, London, Jan., Feb., Mar., 1909.
10. Deutschmann: Münch. med. Woch., May 7, 1907.
11. Von Hipple: Deutsch. med. Woch., July 2, 1908.
12. Happe: Report from Oph. Soc., Heidelberg. Knapp's Archives, Jan., 1909.
13. Darier: Ophthalmoscope, 1907; also Die Oph. Klinik, 1908.
14. Roemer: 34 Versammd d. Ophthalmol. Gesellschaft, Heidelberg, 1907.
15. Simeon Snell: British Med. Journal, July 4, 1908.
16. Maddox: Ophthalmoscope, London, p. 414, 1908.
17. H. Grimsdale: Ophthalmoscope, London, Jan., 1909.

DISCUSSION.

DR. ALEXANDER DUANE, New York: I have seen a case analogous to that of Maddox, *i. e.*, a case of impending panophthalmitis resulting from late secondary infection of an operation scar, in which an intraocular suppuration that had already set in with stormy symptoms was arrested, the arrest being apparently due to repeated subcutaneous injections of an emulsion of dead staphylococci. In this case cultures taken from the eye were sterile, so that a specific vaccine treatment could not be adopted, and injections of a staphylococcus vaccine —not, be it noted, of a staphylococcus serum—were used empirically.

DR. S. LEWIS ZIEGLER, Philadelphia: I desire to add one therapeutic measure to the array Dr. Davis has laid before us. For more than ten years I have been relying on the application of formalin, in varying strengths, in order to secure the best results in cases of infection. I believe that this drug is the best antiseptic we possess, but it has the single disadvantage of causing marked pain whenever it touches healthy tissues. This can often be overcome, however, by the use of a local anesthetic, together with the careful localization of the application to the area of the diseased tissue.

For external use I employ a 1% solution of formalin by saturating a small wisp of cotton on an applicator and gently rubbing it into the suppurating and macerated areas, being careful to avoid touching any healthy tissue.

For intraocular use I inject into the anterior chamber a solution of formalin ¼% in which hyoscin hydrobromate, gr. ½, and cocain hydrochlorate, gr. iv to f℥j, have been dissolved. This gives us the combined effect of an antiseptic, an analgesic, and an anesthetic.

I have one criticism to offer to the treatment suggested by Dr. Davis in Case I, and that is an absolute condemnation of the use of hot fomentations in any case having a tendency to suppuration, unless it should be our desire to promote suppuration. I have recently had a most annoying experience of this kind, where heat was substituted for cold without my knowledge, in a case of capsulotomy which was infected by a conjunctival discharge several days after operation. By a single injection of the antiseptic solution I have just described, together with the continuous application of ice pads day and night, and frequent leechings, I succeeded in changing the inflammation from a suppurative to a plastic one, and confined it to a small area on the ciliary body, about 5 mm. in diameter, as was demonstrated by the strictly circumscribed chemosis which appeared over that location. The patient is now convalescent and good vision has been preserved (rough test shows $\frac{20}{70}$). There still remains a small dimpling in the ciliary region from shrinkage of the limited area involved, while a few shreds can be seen floating in the vitreous. Although the formalin injection was most efficient in changing the character of the inflammation, the continuous use of ice pads undoubtedly exerted a most potent effect in restoring the eye to its normal condition. The application of cold also inhibited any tendency to extension of the suppurative process.

DR. A. E. DAVIS, New York: I am sorry to say that in my cases I had no microscopic examination in any but one, the fourth, which showed the pneumococcus.

I would ask Dr. Ziegler if, in case he had any infection of the eye itself, the cold would prevent panophthalmitis, or if he thinks it is simply an aid in preventing more marked inflammation.

I hoped to bring out a discussion regarding the use of argyrol to ascertain if the other members of the Society had used it, and the results obtained. I have used heat most of the time, though sometimes cold early in the case, but have resorted to hot applications, and I think I have had better results with it.

THIRD SERIES OF CASES OF INJURIES FROM FOREIGN BODIES EXAMINED BY THE ROENTGEN RAYS, WITH RESULTS OF OPERATION.

WILLIAM M. SWEET, M.D.,

Philadelphia.

At a meeting of this Society in 1901 I reported a series of 102 cases of injury to the eye from foreign bodies in which the Roentgen rays had been used for diagnosis, and gave the results of operation in the 65 cases in which a foreign body was located in the eyeball or surrounding structures. A second series of 318 cases, in 173 of which a foreign body was shown by the *x*-rays, was published in 1906.* In the present communication are reported 282 cases of ocular injury, in 157 of which the substance was found to be lodged in the eyeball or orbit. For the purpose of comparison, the 702 cases are embraced in the following statement:

Position of Body.	First Series.	Second Series.	Present Series.
In the eyelid	1	2	0
In the lens	3	14	16
In the iris or posterior chamber	1	4	4
In the ciliary region	24	27	12
Near the equator	21	69	52
Posterior part of eyeball	12	46	48
In the orbit	3	11	25
No body shown by *x*-rays	37	145	125
	102	318	282

In the above subdivision of the vitreous chamber, the "ciliary region" includes all cases in which the body was situated in or close to the ciliary body, the equatorial region, all bodies situated at the equator or in an area 3 mm. in front or 3 mm. behind it, while the third division includes all cases in which the body was in the posterior part of the globe. Of the total 702 cases of injury, 571 were caused by particles of iron or steel, 49 by copper, brass, or other non-magnetic metal, 50 by shot, and 32 by glass,

* Section on Ophthalmology, American Medical Association, 1906.

stone, or coal. In the 42 instances in which the foreign body was situated in the eyelid or orbit, the eyeball on the corresponding side was injured.

The right eye was injured in 308 cases and the left in 390, and both eyes in 4 cases. The greater frequency of injury of the left eye is explained partly by the position taken by right-handed workmen in using tools in hammering or chipping metal, by which the left eye is more exposed to flying particles, and partly by the fact that the nose affords some protection to the right eye from missiles coming from the left side.

The following figures give the ultimate result in the 65 cases in the first series and the 173 in the second series in which a foreign body was located in the eyeball or surrounding tissues, with details of the 157 cases in the present group. Some changes have been made in the first two groups from the previously published figures, based upon later information:

	First Series.	Second Series.	Present Series.
Eyeballs enucleated:			
Extraction not attempted or failed	14	23	19
Extraction successful — enucleation later	10	28	39
Eyeballs saved:			
No operation attempted	7	11	4
Extraction failed	2	4	9
Bodies in eyelid or orbit	4	9	17
Extraction successful			
Vision $\frac{6}{12}$ or better	7	20	17
Vision $\frac{6}{15}$ to $\frac{6}{60}$	4	13	11
Fingers or hand movements, etc.	0	7	12
Good light projection	9	27	15
Light perception	6	21	9
No light perception—eye normal size	0	6	2
Eyeballs shrunken	2	4	3
No Bodies Shown by *x*-rays	37	145	125
Total	102	318	282

In the third group, extraction was not attempted or failed, but the eye was not removed, in 13 cases—3 of copper, 1 of brass, 1 of lead, 7 in which the steel had remained in the eyeball for periods between three months and nine years, and 1 refused operation.

In the 19 instances in which enucleation followed failure to secure the foreign body or in which no operation was performed, two were gunshot injuries, in which shot was situated within the globe, two in which rapidly developing panophthalmitis made immediate enucleation imperative, six were injuries by copper or other non-magnetic metal, and nine were cases in which the steel was imbedded in exudation.

Most of the patients examined were referred to me for *x*-ray localization, and I am under obligations to the surgeons who treated the cases for aid in determining the ultimate result as to vision. In instances in which the patients did not return to the hospitals after extraction for subsequent examination and treatment, record of the condition of the eye and the vision was secured by visits to them at their homes or places of labor in this city or by correspondence and examination by physicians in the cities in which the patients lived. In some cases it has been impossible to locate individuals, and the period between operation and last examination has not been so long as could be wished.

EYEBALLS SAVED.—In the first series extraction was successful and the eyeballs saved in 28 cases, 7 with vision better than $\frac{6}{12}$ and 21 with vision less than $\frac{6}{12}$. In the second series the steel was successfully removed in 98 cases, 20 with vision better than $\frac{6}{12}$ and 78 with less than $\frac{6}{12}$. In the present series extraction succeeded in 69 cases, 17 with vision better than $\frac{6}{12}$ and 52 with less than $\frac{6}{12}$. In many of the cases with vision poorer than $\frac{6}{12}$ sight could be distinctly improved by the removal of the existing cataract or capsular membrane. In the last series of 52 cases with less than $\frac{6}{12}$ cataract was present in 30, the removal of which would have given much better sight than is shown by the tabular statements.

The details of the present series of cases, which includes those in which the foreign body was removed, those in which extraction failed or was not attempted (excluding eyeballs enucleated). and those in which the body was in the orbit, are given in Table I.

TABLE I.—EYEBALLS SAVED.

Case.	Surgeon.	Eye.	Situation of Wound.	Time between Injury and Extraction.	Time between Operation and Last Examination.	Vision.	Remarks.
LENS OR IRIS:							
538	Vau Pelt.	L.	C.	3 days	1 yr.	6/9	Lens curetted.
563	Risley.	L.	C.	2 yrs.	18 mo.	Hand movements.	Capsular cataract.
571	Sweet.	L.	C.	3 wks.	15 mos.	6/9	Capsular cataract.
599	Pontius.	L.	C.	5 wks.	6 mos.	6/9	Lens curetted.
604	Sweet.	L.	C.	4 yrs.	1 yr.	6/6	In iris. Lens clear.
605	Radcliffe.	R.	C.	3 yrs.	6 mos.	6/5	Lens curetted. V-shaped capsulotomy.
608	Oliver.	R.	C.	3 days	13 mos.	6/12	Lens curetted.
609	Sweet.	R.	C.	5 days	1 yr.	6/9	Lens curetted.
626	VanPelt.	L.	C.	3 mos.	1 yr.	6/12	Lens curetted.
627	Oliver.	L.	C.	3 days	1 yr.	6/12	Lens curetted.
632c	Oliver.	R.	C.	3 days	1 yr.	Good L. Proj.	Cataract. Extraction not attempted.
640	Ziegler.	R.	C.	18 mos.	3 mos.	Good L. Proj.	Cataract.
645	Sweet.	R.	C.	8 mos.	1 yr.	6/5	Vision after capsulotomy.
655c	Pontius.	L.	C.	6 days.	1 yr.	6/12	Lens curetted.
658	Ziegler.	L.	C.	4 days.	10 mos.	6/12	Lens curetted.
680	Dewey.	L.	C.	7 mos.	6 mos.	5/15	Lens curetted. Cap. cat.
684	VanPelt.	L.	C.	2 yrs.	..	L. P.	Extraction failed. Cat.
687	Oliver.	L.	C.	11 days	8 mos.	1/100	Capsular cataract.
CILIARY REGION:							
502	Turnbull.	L.	S.	3 days	6 mos.	Hand movements.	Membrane in vitreous.
527	Posey.	R.	C.	6 days	1 mo.	Light proj.	Vit. opacities.
545	Fisher.	L.	C.	9 days	10 mos.	Light proj.	Cataract.
580c	Ziegler.	R.	C.	1 yr.	14 mos.	6/6	Removed by forceps, with vitreous illuminated by head mirror.
629	Radcliffe.	R.	C.	6 mos.	1 yr.	6/18	Lens curetted. Cap. cat.
633	Sweet.	R.	L.	5 days	10 mos.	Fingers 2 ft.	Cataract. Good L. P.
651c	Risley.	L.	C.	1 yr.	..	Imp. L. P.	Ext. not attempted.
686	Risley.	L.	L.	1 yr.	3 mos.	Imp. L. P.	Globe shrunken.
EQUATOR:							
423	Ziegler.	R.	L.	5 days	2 yrs	6/60	Cataract.
434	Zentmayer.	R.	C.	3 mos.	..	Light proj.	Brass. Extraction not attempted. Cataract. Eye quiet 3 yrs. later.
435	Sweet.	L.	C.	2 mos.	2 yrs.	6/9	After capsulotomy.
445	Ziegler.	L.	C.	5 days	2 mos.	Light proj.	Cataract.
46;	Hansell.	L.	C.	3 days	6 mos.	6/18	Capsular cataract.
466	Posey.	L.	C.	2 yrs.	2½ yrs.	Fair L. proj.	Some exud. in vitreous. Eye diverg. 20°.
472	Posey.	R.	L.	2 days	10 mos.	5/200	Vitreous opac.
495	McClure.	R.	C.	2 days	2 yrs.	Imp. L. P.	Membranous hyalitis.
501	Risley.	L.	C.	3 days	3 mos.	Imp. L. P.	Pupil irregular. Membrane in vitreous.
512	Ziegler.	L.	S.	7 mos.	2 mos.	Imp. L. P.	Siderosis. Vit.membrane.
530c	Sweet.	L.	L.	18 mos.	..	Imp. L. P.	Extraction failed.
534	McClure.	R.	C.	3 days	10 mos.	Good L. Proj.	Cataract.
537	Sweet.	L.	L.	7 days	1 yr.	6/30	Vitreous opacities.
547	Hansell.	R.	S.	4 hours	20 mos.	10/100	Atrophic optic nerve.
548	Zentmayer.	R.	L.	1 day	14 mos.	Imp. L. P.	Eyeball normal size. Membranous hyalitis.
549	Sweet.	R.	C.	3 mos.	..	Light proj.	Extraction failed.
551	Radcliffe.	R.	C.	10 mos.	8 mos.	6/60	Capsular cataract.
555	Ziegler.	R.	L.	3 days	..	..	Extraction failed.
557	Sweet.	R.	C.	9 days	10 days	6/12	Cap. cataract.
564	Ziegler.	R.	C.	5 days	18 mos.	Fingers 3 ft.	Capsular cataract.
577	Risley.	R.	C.	4 days	6 mos.	Imp. L. P.	Membranous hyalitis.

c = Copper.

TABLE I.—EYEBALLS SAVED.—(*Continued.*)

Case.	Surgeon.	Eye.	Situation of Wound.	Time between Injury and Extraction.	Time between Operation and Last Examination.	Vision.	Remarks.
EQUATOR.—*Continued:*							
593	Radcliffe.	L.	C.	1 week	7 days	Good L. Proj.	Cataract.
597	Leopold.	R.	C.	1 day	1 yr.	6/12	Lens curetted.
601	Fisher.	R.	C.	5 mos.	1 yr.	Hand movements.	Lens removed. Cap. cat.
613	Risley.	L.	C.	2 yrs.	..	Poor L. Proj.	Extraction failed. Mass in vitreous.
647	Risley.	L	S.	1 day	1 yr.	6/12	
648	Sweet.	R.	C.	2 days	4 mos.	Hand movements.	Cataract.
652	Dewey.	R.	C.	15 mos.	..	Imp. L. P.	Extraction failed. Refused enucleation.
657	Pontius.	R.	C.	7 mos.	5 mos.	Light proj.	Cataract.
672	Chance.	L.	C.	1½ yrs.	..	..	Extraction failed. Lens curetted. V=6/12.
676	Sweet.	R.	L.	1 day	9 mos.	Good L. Proj.	Cataract.
677	VanPelt.	L.	C.	3 days	8 mos.	Good L. Proj.	Cataract.
679	Sweet.	R.	C.	1 wk.	2 mos.	5/22	Partial cataract.
POSTERIOR PART OF EYE							
438	Taylor.	R.	S.	8 yrs.	..	6/12	Extraction failed.
450	Dewey.	L.	C.	4 days	2 yrs.	Good L. Proj.	Cataract.
462	Zentmayer.	R.	C.	3 days	3 mos.	Imp. L. P.	Globe slightly atrophic.
463	Sweet.	R.	C.	20 days	2 yrs.	6/60	Choroidal absorption.
464	VanPelt.	R.	L.	3 days	14 mos.	Poor L. Proj.	Exudation in vit.
469	Zentmayer.	L.	S.	1 day	2½ yrs.	Imp. L. P.	Exudation in vit.
476	Harbridge.	L.	C.	2 mos.	2½ yrs.	Fingers 3 ft.	Capsular cataract.
524	Sweet.	R.	C.	2 days	2 yrs.	No sight.	Ball slightly atrophic.
532	Radcliffe.	R.	C.	4 days	1 yr.	Imp. L. P.	Ball slightly atrophic.
546	Sweet.	R.	C.	1 day	6 mos.	Shadows 3 ft.	Cataract.
554	Oliver.	L.	C.	1 day	6 mos.	Fingers 1 ft.	Cataract.
587	Ziegler.	L.	C.	2 days	2 mos.	Good L. Proj.	Cataract.
590	Posey.	L.	C.	4 days	3 mos.	Good L. Proj.	Cataract.
595	Sweet.	R.	S.	17 days	..	Imp. L. P.	Refused extraction.
600	Hansell.	L.	C.	10 days	1 yr.	Light Proj.	Cataract.
620	Ziegler.	R.	C.	9 yrs.	..	..	Extraction failed.
623	Zentmayer.	R.	S.	7 days	2 mos.	Fingers 2 ft.	Opacities in vitreous.
646	Risley.	R.	L.	3 days	1 yr.	20/70	Vision=20/40.
669	Sweet.	L.	S.	3 days	3 mos.	Light proj.	Cataract.
673	Oliver.	R.	C.	3 days	8 mos.	5/15	Lens curetted.
675	Sweet.	L.	C.	2 days	6 mos.	Imp. L. P.	T-2.
681	Gibson, R. D.	R.	C.	1½ yrs.	7 mos.	No sight.	Globe of normal size.
692	Risley.	L.	C.	2 wks.	1 mo.	Good L. Proj.	Cataract.
IN ORBIT:							
424	Harlan.	R.	C.	20 days	3 mos.	L. Percep.	Cataract.
428s	VanPelt.	R.	S.	3 days	6 mos.	L. Percep.	Vitreous membrane.
477	Radcliffe.	L.	C.	3 days	1 yr.	Light Proj.	Cataract.
481s	Sweet.	L.	S.	2 wks.	2 yrs.	Imp. L. P.	Cataract.
489s	Posey.	L.	S.	2 mos.	1 yr.	6/12	
491s	Sweet.	L.	S.	3 mos.	13 mos.	Light proj.	Vit. degen.
496s	Oliver.	L.	S.	1 mo.	5 mos.	Light proj.	Membrane in vitreous.
542	Sweet.	L.	L.	6 hrs.	2 yrs.	6/6	
589	Sweet.	R.	S.	5 days	18 mos.	6/9	
598s	Hansell.	L.	S.	4 days	1 yr.	6/60	Membrane in vitreous.
606s	VanPelt.	R.	S.	3 days	6 mos.	6/30	Retinal degeneration.
616	Sweet.	L.	S.	3 wks.	1 yr.	Moving objects.	Exudate in vitreous
630	Cramer.	L.	L.	3 days	1 yr.	6/45	Capsular cataract. Corneal macula.
636	Pontius.	R.	C.	2 days	6 mos.	6/12	Nasal side of orbit.
656	Oliver.	R.	C.	3 days	1 year	Good L. Proj.	Lens curetted. Cap. cat.
685	Pontius.	R.	C.	5 days	6 mos.	Good L. Proj.	Cataract.
695	Ziegler.	R.	S.	3 days	5 mos.	Good L. Proj.	Exudate in vitreous.

s = Shot.

EYEBALLS LOST.—Of the total of 157 eyes of the present series in which a foreign body was situated in the eyeball or orbit, enucleation was required in 58. In 39 the injury was from iron and steel, in 9 from copper or other non-magnetic metal, 9 from shot, and 1 from coal. The causes which caused the removal of the eyeballs are tabulated below, compared with the cases in the previous reports:

	First Series.	Second Series.	Third Series.
Extraction not attempted or failed....	14	23	19
Iridocyclitis.....	5	14	15
Panophthalmitis.....	1	8	14
Shrunken or lacerated eyeball.....	2	5	7
Symp. irritation.....	0	0	2
Recurring hem. anterior chamber.....	2	1	1
Total.....	24	51	58

Two causes stand out prominently as contributing in a large measure to the loss of eyes injured by foreign bodies: first, the period elapsing between the injury and the removal of the body; and, second, the size of the metal entering the globe. A few days may suffice for a firm exudate to surround a body imbedded in the retina or choroid, and even if the extraction is successful the amount of damage that follows the drag of the magnet upon the tissues in disengaging the metal cannot be estimated. I believe the importance of prompt diagnosis of the lodgment of a foreign body in the eyeball and its immediate removal are being more fully recognized even by the workingmen in the larger industrial establishments, and they seek experienced advice rather than accept the opinion of the local physician, who is too often disposed to say that he thinks there is nothing in the eye. It is unfortunate, however, that a certain proportion of injured eyes will be lost from panophthalmitis or iridocyclitis, even though the patient is promptly seen and the steel at once removed.

The details of the 58 cases included in the present series in which enucleation was required are shown below:

TABLE II.—EYEBALLS LOST.

Case.	Surgeon.	Eye.	Time between Injury and Extraction.	Situation of Wound.	Time Between Extraction and Enucleation.	Size of Body, mm.	Cause of Enucleation.	Remarks.
	Lens:							
427	Van Pelt	L.	7 days	C.	2 wks.	8 x 4	Panophthalmitis.	Through posterior capsule. Evidence of infection at time of extraction.
572c	Sweet.	L.	2 wks	C.	3 days	1 x 1	Panophthalmitis.	Copper imbedded in post. capsule.
	Ciliary Region:							
422	Posey.	L.	1 year	[illegible]	.	1 x ½	Extraction failed.	Body imbedded in lymph.
506	Radcliffe	R.	2 wks.	C.	3 days	6 x 4	Irido-cyclitis.	Coal, not shown by *x*-rays.
638c	VanPelt.	L.	1 wk.	C.	1 wk.	1 x 1	Irido-cyclitis.	Attempt to extract with forceps failed.
633	Behrens.	L.	2 days	C.	..	2 x 1	Panophthalmitis.	Extraction not attempted. Eye infected.
	Equator:							
421	Sweet.	R.	10 hrs.	S.	6 days	12 x 4	Irido-cyclitis	Eye collapsed after extraction. Refused enucleation until later.
467	Fisher.	R.	3 days	L.	15 days	7 x 3	Irido-cylitis.	Immense coagulated mass in centre of vitreous.
475	Hansell.	L.	1 wk.	C.	1 wk.	4 x 1	Panophthalmitis.	Purulent masses removed with body.
498a	Risley.	L.	1 wk.	S.	..	Shot.	Irido-cyclitis.	Extraction not attempted.
525a	Zentmayer	R.	2 days	S.	..	Shot.	Irido-cyclitis.	Extraction not attempted.
525	Risley.	R.	1 wk.	C.	2 wks.	4 x 2	Rec. hem. ant. chamber.	Severe pain, unrelieved by medicine. Yellowish mass found in vitreous.
530	Sweet.	R.	2 days	C.	3 days	4 x 1	Panophthalmitis.	Death 2 days later from septic meningitis.
539	Radcliffe.	R.	1 wk.	S.	2 wks.	2 x 1	Irido-cyclitis.	
544	Sweet.	L.	4 days	C.	3 mos.	2 x ½	Irido-cyclitis.	Evidence of infection at time of extraction.
589	Radcliffe.	L.	1 day	L.	4 days	6 x 5	Irido-cyclitis.	Ragged wound at limbus.
592	Radcliffe.	R.	1 day	C.	3 days	4 x 2	Panophthalmitis.	
603	Posey.	R.	3 days	S.	4 mos.	6 x 3	Shrunken ball.	
606c	Ziegler.	L.	2 days	S.	..	7 x 6	Collapsed ball.	Lacerated wound of sclera, with protruding vitreous.
641	Schweak.	R.	3 days	C.	2 wks.	2 x ½	Irido-cyclitis.	Not shown by *x*-rays.
655	Fisher.	L.	1 day	C.	1 mo.	5 x 2	Irido-cyclitis.	Large lymph exudation in ciliary region.
662a	Postius.	R.	5 wks.	S.	..	Shot.	Degenerated ball.	
668a	Postius.	R.	3 days	C.	..	Shot.	Lacerated ball.	Mass of flattened lead shot found in vitreous.
697	Radcliffe.	L.	2 days	L.	2 days	9 x 4	Panophthalmitis.	*x*-Rays located 2 bodies. Evidence of infection at time of extraction.
698a	Hansell.	R.	2 days	L.	..	Shot.	Irido-cyclitis.	
	Posterior Part of Eye:							
423c	Schweak.	L.	7 days	C.	..	4 x 2	Irido-cyclitis.	Piece of copper cartridge.
429	Oliver.	L.	3 days	S.	1 yr.	2 x 1	Shrunken globe.	Extraction not attempted. Vitreous filled with mass of organised lymph.
442	Ziegler.	L.	3 days	S.	2 days	8 x 3	Tender eyeball.	Steel perforated posterior scleral wall, injuring nerve.
443	Shoemaker.	L.	4 days	C.	..	4 x 2	Extraction failed.	Body non-magnetic.
447	McClure.	R.	4 mos.	S.	..	7 x ½	Extraction failed.	Imbedded in lymph.
452	Schweak.	L.	4 days	C.	..	2 x 1	Extraction failed.	Body imbedded in sclera.
455c	Risley.	R.	15 days	C.	..	1 x 1	Extraction not attempted.	Copper, in purulent mass in vitreous.
459	Fisher.	L.	4 days	[illegible]	..	7 x 6	Extraction failed.	Brass.
466a	Radcliffe.	R.	5 days	[illegible]	..	Shot.	Irido-cyclitis.	
473	Oliver.	L.	18 days	S.	..	14 x 6	Extraction failed.	Steel projected through

c=Copper. s=Shot.

TABLE II.—EYEBALLS LOST.—(*Continued.*)

Case.	Surgeon.	Eye.	Time between Injury and Extraction.	Situation of Wound.	Time between Extraction and Enucleation.	Size of Body, mm.	Cause of Enucleation.	Remarks.
POSTERIOR PART OF EYE.—*Continued.*								
505	Ziegler	L.	20 days	S.	..	8 x 7	Extraction failed.	Body imbedded in lymph.
506	Schwenk.	L.	17 days	C.	..	2 x 1	Extraction failed.	Body imbedded in lymph.
513	Posey.	L.	3 days	C.	..	3 x 2	Extraction failed.	Body imbedded in sclera.
526	VanPelt.	R.	2 days	L.	2 mos.	4 x 2	Irido-cyclitis.	Body imbedded in sclera. Magnet point entered vitreous.
536	Fisher.	R.	1 day	C.	6 wks.	3½ x 1	Irido-cyclitis.	Extracted through wound in cornea.
541	Fisher.	L.	3 days	C.	2 mos.	10 x 6	Irido-cyclitis.	Perforation of post. scleral wall.
559	Fisher.	R.	3 days	C.	2 days	2 x ½	Panophthalmitis.	Evidence of infection at time of extraction.
565	Radcliffe.	L.	1 day	L.	2 mos.	2 x 1	Irido-cyclitis.	Magnet point entered vitreous.
575	Zentmayer.	L.	13 days	C.	6 days	3 x 2	Pur. choroiditis.	Eye in bad shape at time of extraction.
586	Radcliffe.	R.	10 days	C.	..	Shot.	Irido-cylitis.	
588	Turnbull.	R.	16 days	C.	..	8 x 2	Extraction failed.	Babbitt metal, non-magnetic.
520c	Posey.	L.	2 days	C.	..	3 bodies.	Extraction not attempted.	Three pieces dynamite cap in vitreous.
618	Risley.	R.	3 days	L.	5 mos.	4 x 2½	Shrunken and tender.	
666	Zentmayer	L.	1 mo.	C.	..	1 x ½	Extraction failed.	Body imbedded in lymph.
668	Shoemaker.	R.	10 yrs.	C.	..	1 x 1	Extraction failed.	Vision normal for 10 years. Then symp. irritation.
IN ORBIT:								
425	Fisher.	L.	2 days	C.	..	4 x 3	Extraction not attempted.	Double perforation. Steel found in sheath of optic nerve.
507	Sweet.	L.	5 hrs.	S.	..	3 x 2	Panophthalmitis.	
518s	Fisher	L.	6 wks.	S.	..	Shot.	Severe Pain.	Shot close to nerve. Complete relief of pain.
579s	Oliver.	R.	2 wks.	S.	..	Shot.	Irido-cyclitis.	
591	Radcliffe.	L.	2 wks.	C.	..	4 x 1	Irido-cyclitis.	Yellow mass filled vitreous chamber.
602	Pontius.	R.	2 days	L.	..	9 x 5	Lacerated ball.	Steel located in nasal structures—attempts to extract failed.
603s	Posey.	R.	2 days	C.	..	Shot.	Lacerated ball.	Shot perforated ciliary body.
607s	Cramer.	L.	1 mo.	L.	..	Shot.	Extraction failed.	Shot perforated sclera and found in Tenon's capsule.

c = Copper. s = Shot.

Few eyeballs recover from the violent concussion of large pieces of steel. In the first and second series of cases a large proportion of the eyes lost could be directly traceable to the severe traumatism at the time of injury, and the same is true of the cases included in the present series. In over one-half of the cases in the above table the metal was of large size, varying in 7 cases from 4 x 2 mm. to 5 x 2 mm., in 3 from 6 x 3 mm. to

6 x 5 mm., in 4 from 7 x 1 mm. to 8 x 4 mm.; one was 7 x 6 mm., one 8 x 7 mm., one 9 x 5 mm., one 10 x 6 mm., one 12 x 4 mm., and one 14 x 6 mm.

Of the 58 eyes which required enucleation, the entrance wound was in the cornea in 29, at the limbus in 10, and through the sclera in 19.

With few exceptions it is the usual custom for the surgeons connected with the hospitals from which the cases have been referred, to wait for *x*-ray localization before attempting to extract the steel with the magnet. The few instances in which the steel was extracted through the open entrance wound, without *x*-ray examination, are therefore not included in this report. To determine to what extent the magnet was used at the Wills Hospital, from which institution the majority of the cases were referred, to extract the metal without previous *x*-ray localization, Dr. J. Milton Griscom examined the records during the year he was resident surgeon, and found that, in addition to the 74 cases subjected to *x*-ray examination and included in this report, of which 40 cases showed a foreign body in the eyeball or orbit, there were only 7 cases which were subjected to magnet extraction without the use of the *x*-rays. All of these were seen within a few hours after injury, in all the wound was open, and in two the foreign body could be seen in the lens. Of the 5 cases in which the steel was in the vitreous, two eyeballs were subsequently lost, one was advised enucleation but refused, one had vision of fingers at two feet, and one secured $\frac{20}{30}$ at the end of three months. The ultimate vision in the 2 cases of steel in the lens was $\frac{20}{40}$ and $\frac{20}{30}$, respectively.

Three of the cases included in the above tabular statements are sufficiently unique to warrant a more extended report.

CASE 451.—Piece of steel, 12 x 4 mm., passed along inner orbital wall, and penetrated eyeball back of equator. Panophthalmitis. Enucleation.

J. D., came to the Polyclinic Hospital in the writer's service with history of injury of the right eye while driving a bridge girder into position. Examination showed a ragged wound of

the skin equidistant between the inner canthus and the bridge of the nose. No wound of the eyeball could be found, but the globe showed T-3, with proptosis and edema of the conjunctiva and lids. Hemorrhage from right nasal cavity had continued since accident. A large piece of metal, 12 x 4 mm., was shown to have penetrated into the eyeball immediately back of the equator, with one-third of it projecting into the orbit. An incision was made in the conjunctiva immediately above the insertion of the internal rectus, and the body extracted by the magnet. From the situation of the entrance wound, the steel must have passed along the inner orbital wall and become deflected outward into the eyeball. In a few days panophthalmitis developed, and the eyeball was removed.

CASE 697.—Two pieces of steel located in vitreous. Magnet extraction successful. Panophthalmitis. Enucleation.

C. M. came to the Wills Hospital, service of Dr. McCluney Radcliffe, and stated that he had been injured in the left eye the day before while chipping rivets. Scar at upper and inner limbus, 5 mm. long, with wound of the iris and hyphemia. Radiographs showed two bodies within the eyeball, one, 10 x 6 x 3 mm., and the other 3 x 2 mm., both situated in lower portion of vitreous chamber near the equator. The magnet secured both bodies, but there were evidences of infection at the time of operation, and panophthalmitis compelled enucleation on the second day after magnet extraction.

CASE 580.—Piece of dynamite cap in eyeball for one year. Removal by forceps, with vitreous illuminated with an electric head-light. V = $\frac{6}{6}$.

J. D., aged fourteen years, was injured in the right eye by the explosion of a dynamite cap one year before coming to Wills Hospital, in the service of Dr. S. Lewis Ziegler. No wound or scar could be seen, and ophthalmoscope showed a dark, floating mass in the vitreous, probably a piece of copper. Radiographs showed a metal body, 1 x 0.5 mm., situated in the vitreous, back of the ciliary body on the nasal side. The metal was removed by forceps through a scleral incision with the vitreous illuminated by a small, electric head-lamp. Lens subsequently became opaque, was needled, and later a V-shaped discission of the capsule was made. V, with correction, $\frac{6}{6}$.

VALUE OF THE *x*-RAYS.—It is hardly necessary further to emphasize the importance of *x*-ray examination in foreign body injuries, since it is now more generally recognized that the size and shape of the metal and its position in the globe are important factors in the diagnosis and treatment, whether extraction is made through a scleral incision or by the route of the anterior chamber. In recent injuries, and while the entrance wound is open, expediency may prompt the immediate employment of the magnet in an attempt to remove a body of unknown size and position through its path of entrance, but there is the risk that the metal is larger than the wound indicates, and in coming forward with great force under the pull of the magnet may cause

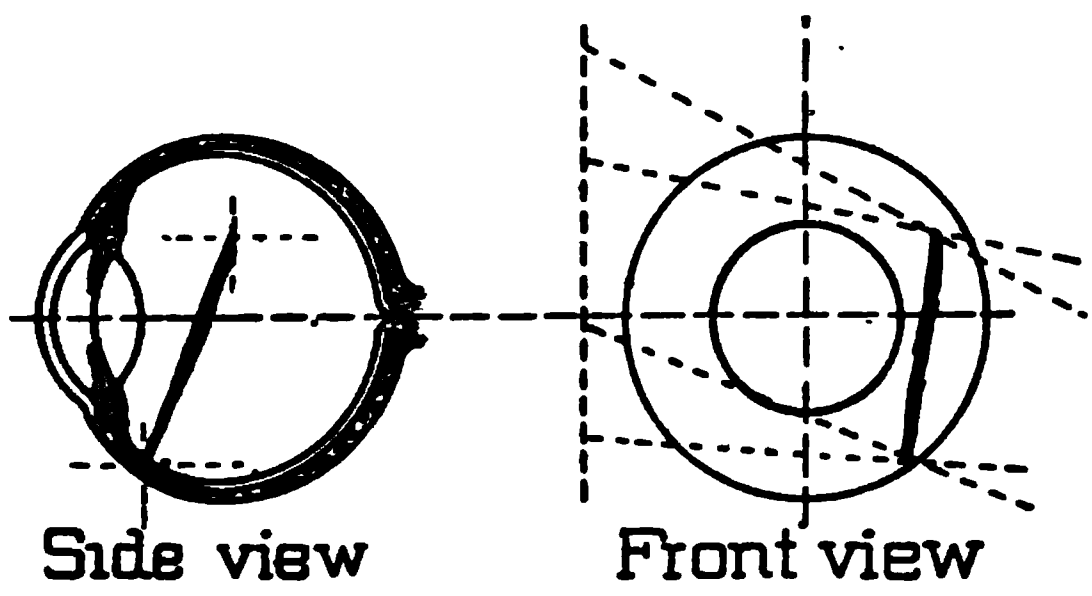

Fig. 1.—Diagram of position of foreign body.

serious damage to the anterior structures of the globe. A long, thin body often makes a small entrance wound, and rests in a position that renders extraction by the path of entry impossible. The operator, ignorant of this fact, injures the internal structures with each application of the magnet. A recent case which shows the value of *x*-ray localization is as follows:

CASE 704.—Long, thin piece of metal penetrated through the lid and sclera. *x*-Ray localization indicated proper method of extraction.

F. S. came to the Methodist Hospital, service of Dr. P. H. *Moore, with* the history of failing sight in the right eye for nearly *one year.* Vitreous clouded, and no view of interior of eye

possible. Radiographs indicated a piece of steel, 16 mm. long, and as thin as a medium-sized sewing-needle, resting vertically in the vitreous, with the lower end imbedded in the choroid, at a point 4 mm. in front of the equator. A small scar in the upper lid indicated the point of entrance of a foreign body, the man recalling a slight injury in that situation a year previously. Since the small entrance wound gave no indication of the size or shape of the metal, an attempt to remove the metal without this knowledge would probably have resulted in the loss of the eye. The position of the body, as shown by the *x*-rays (Fig. 1), with one end imbedded in the structures at the bottom of the globe, indicated that extraction must be made through an opening in the upper portion of the sclera, in order to release the end of the metal caught in the choroid. The body was readily removed in the manner indicated by the localization.

FAILURE OF THE *x*-RAYS.—In two cases the *x*-rays failed to locate a foreign body which was later shown to be present in the eye. The detailed histories of these cases are as follows:

CASE 605.—R. E., history of injury three years before. Foreign body localized and removed. L. E., no history of injury. Lens cataractous. Radiographs failed to show a foreign body. Small piece of steel removed with soft lens.

C. K., patient of Dr. McCluney Radcliffe, was struck in left eye by a piece of steel three years before coming to Wills Hospital. Small scar of cornea, lens opaque. Vision of right eye had been failing for one month before visit to the hospital. No history of injury. Cornea clear, but lens partly cataractous. Small spot in nasal margin of lens suspiciously like foreign body. Radiographs showed a piece of metal in left eye, none in right eye. The lens of the left eye was curetted, and a small spicule of steel, $1\frac{1}{2} \times \frac{1}{4}$ mm. and extremely thin, came out with the soft lens. Later, V-shaped incision of dense capsular membrane; V = $\frac{6}{5}$, with correction.

The failure of the rays to secure a shadow of the foreign body in the above case can be explained by the metal presenting the *thin* edge to the tube, so that the faint shadow made by the steel was lost in the denser shadow of the bony structures forming

the external orbital margin. The body was in the nasal portion of the lens, and therefore at its greatest distance from the plate. In instances of a piece of metal in the lens, it should be possible to show even a minute body if the tube is placed in a position to shadow the anterior portion of the ball in front of the bones forming the external orbital margin. This was not done, as the lens was curetted before a second *x*-ray examination could be made.

CASE 641.—Small foreign body in vitreous not shown by *x*-rays. Iridocyclitis. Enucleation.

A. C., patient of Dr. P. N. K. Schwenk, was injured while chipping armor-plate the day before coming to Wills Hospital. Examination showed incised wound of cornea in horizontal plane to temporal side of the center, iris irregular, hypopyon, and cataract. *X*-Ray examination showed no foreign body; a second examination also gave negative findings.

The character of the injury pointed to the probable entrance of a foreign body in the eyeball, and, although two sets of radiographs were made, no shadow was found on the plates. The eyeball remained inflamed, iridocyclitis developed, and the globe was removed. Upon sectioning the ball, the vitreous was sanguinous, and an enormous lymph exudation was found in the ciliary region. A piece of steel, 3 x 1 mm., and extremely thin, was found in the equatorial region, inner side.

It is difficult to explain the failure of the *x*-rays to indicate this body, except upon the assumption that the thin edge of the metal presented to the tube, and, with the body situated on the nasal side of the globe at considerable distance from the plate, the thin line of shadow was lost in the shadow of the orbital walls.

POSSIBLE ERROR IN LOCALIZATION OF BODIES SITUATED NEAR THE POSTERIOR SCLERAL WALL.—In bodies which are shown to be situated close to the posterior scleral wall or imbedded in it there should always be considered the possibility of a variation in the diameters of the eyeball from the average of 24 mm., the size adopted for the diagrammatic charts employed for localization. This is well illustrated in the following:

CASE 505.—Large piece of steel in vitreous chamber. Localization indicated perforation of posterior scleral wall. Enucleation. Body imbedded in choroid.

M. W. was injured in L. E. one week before coming to the Wills Hospital, service of Dr. S. Lewis Ziegler, on December 28, 1906. Scar on eyelid and sclera and hemorrhage in vitreous. Radiographs located a piece of steel, 8 x 7 mm., situated 25 mm. back of the corneal center, 5 mm. above the horizontal plane, and 3 mm. to the nasal side of the vertical plane, indicating perforation of the posterior scleral wall. On December 31st attempts to extract metal failed and the patient refused enucleation. A second *x*-ray examination made six days later showed that the position of the body had not been changed by operation. On January 18, 1907, the patient went to the University Hospital, service of Dr. G. E. de Schweinitz, and consented to enucleation in the event of failure to secure the body with the magnet. Extraction failed and the eye was removed. The body was found in a mass of thick exudate at the position indicated by the *x*-rays. It did not, however, penetrate the posterior scleral wall, as was indicated by the radiographs, and this was positively determined by microscopic examination of serial sections of the sclera at the point of lodgment of the foreign body.

CASE 473.—Piece of steel localized as projecting through posterior scleral wall into orbit. Enucleation. Body exactly in position indicated.

H. M. was injured in L. E. two weeks before coming to Wills Hospital, service of Dr. C. A. Oliver. Large wound of sclera, in the lower inner portion, 4 mm. anterior to equator, with pupil drawn down in direction of wound. Radiographs located a metal body, 14 x 6 x 4 mm., situated 3 mm. below the horizontal plane and 2 mm. to nasal side of the vertical plane of the globe, with the anterior end of the body 14 mm. and posterior end 26 mm. back of the center of the cornea, indicating perforation of the posterior scleral wall by the end of the metal to the extent of 3 mm. The eye was in bad condition and was removed by Dr. Oliver two days later. In a letter he said: "Body found exactly as localized, one end extending 3 mm. beyond the sclera into orbit."

The error of localization in the first case may be explained by the eyeball exceeding in size the diagrammatic globe of 24 mm. of the localizing chart. The attempt made to secure the metal led to considerable loss of vitreous, and the globe collapsed during enucleation, so that it was inpossible to demonstrate that the eye measured more than 24 mm. in its anterior posterior diameter, as was probably the case. The situation of the steel in the second case was found after enucleation to correspond exactly with the plotting made on the diagrammatic eyeball of 24 mm. diameter.

Since all measurements are made from the indicator opposite the center of the cornea, there is always a possible error in localization from carelessness on the part of the *x*-ray operator in determining the distance of the corneal summit from the indicating ball. The situation of the foreign body is determined with reference to this fixed point, and any error in measurement gives a false indication of the depth of the metal in the eyeball or orbit.

FOREIGN BODIES IN THE ORBIT.—In 25 of the cases of ocular injury included in the present series the radiographs showed the presence of a foreign body in the orbit, and in 8 cases enucleation was necessary. The injury was by iron and steel in 14 cases and by shot in 11. In addition to the above 14 cases, in which a particle of steel passed completely through the eyeball into the orbit, there were 3 cases of partial double perforation by steel, the localization being verified by subsequent enucleation.

NO FOREIGN BODIES SHOWN BY THE *x*-RAYS.—Of the 282 cases embraced in the present series, 125 were shown by the *x*-rays to have no foreign body in the eyeball or orbit. In every instance there was reason to suspect the lodgment of a foreign body in the eyeball from the character of the injury, the occupation of the individual, and the depreciation of vision. In the majority of cases there was a wound or scar upon the cornea and opacity of the lens. In a few instances no wound

or scar could be determined. A summary of the cases is given in the following statement:

SITUATION OF WOUND OR SCAR.	TOTAL.	CATARACT.	HEM. ANT. CHAMBER.	HEM. OR OPAC. OF VITREOUS.
Cornea	82	62	6	14
Limbus	16	4	2	10
Sclera	12	..	..	12
No wound	15	6	..	9
Total	125	72	8	45

Of the above total of 125 cases, 89 were injured by iron and steel, 12 by copper, usually from the premature explosion of dynamite caps, 11 by small shot, 10 by glass or stone, and 4 by coal. Coal is not shown by the *x*-rays, but examination of the above 4 cases was made to determine the possible entrance at the time of injury of a particle of metal into the eye.

COMPARATIVE RESULTS OF MAGNET EXTRACTION.—Two recent reports of magnet operation permit an appropriate comparison to be made of the result of extraction by the Haab magnet by the route of the anterior chamber, and by the medium-sized magnet operated upon the 110-volt lighting circuit through a scleral incision, either in the immediate vicinity of the metal, as shown by *x*-ray localization, or as near the body as possible. Unlike other operative procedures upon the eyes, in which there is a general uniformity of technic and a consequent definite expectancy in the final results, each foreign body injury must be studied as a separate and distinct condition, the ultimate result of operation being influenced not alone by the method followed by the operator, but depending upon the situation and character of the injury, the extent to which the structures of the eye have been injured by the foreign substance, the length of time it has remained in the eye, and the ease with which it is removed.

In a recent paper Wharton* reports 50 cases of extraction of

* Ophthalmoscope, May 1, 1909.

foreign bodies operated upon by him at the Royal Eye Hospital, Manchester, England, 33 of which were saved and 17 lost. Of 37 cases in which the entrance wound was in the cornea, the steel was anterior to the vitreous in 12, and in the vitreous in 25, of which latter 11 eyes were lost. In 10 cases the path of entry of the steel was through the ciliary body, with loss of 5 eyes, and in 3 the steel entered through the sclera, with subsequent loss of 1.

In these cases, 26 were operated upon on the day of accident, with loss of 8; 9 on the second day, with loss of 3; 8 on third day, with loss of 5; 2 from the fifth to the seventh day; 2 on the tenth day, with loss of 1; and 3 between the sixteenth day and five months. With the exception of 2 cases in which a scleral incision was made after localization of the metal by the *x*-rays, the steel was removed through the open entrance wound or drawn into the anterior chamber by the Haab magnet and extracted.

Detachment of the retina was found in 5 eyes in which the giant magnet was employed, four instances of recent injury (three on the same day and one on second day) and one in which the steel entered the eye five months previously. Wharton regards the use of the giant magnet as inadvisable in cases not seen for several weeks after injury, confirming the opinion expressed in the second series of cases here reported, that it is impossible to gage the amount of traction of the giant magnet upon a body the size and position of which are not known and which has remained in the globe until covered with exudation. Wharton reports one of the cases in which, even though the patient's eye was more than a foot from the magnet point, the whole of the iris was torn from its base and slipped through the corneal wound with the metal. The eye was lost.

A somewhat similar report of the results of magnet extraction has been made by Goulden,* late Senior House Warden at Moorfields, London. His report covers a period of five years,

* Royal London Ophthalmic Hospital Reports, vol. 17, 1908.

from 1901 to 1905, inclusive, in which 118 cases of iron and steel foreign bodies within the eye were submitted to the operation of magnet extraction by the surgeons at this hospital. Of the total number, 42 were examined over one year after operation, 38 could not be located after leaving the hospital, and 38 eyes were enucleated.

Of the 34 cases in which the path of entrance was in the cornea or corneo-scleral junction, extraction was through the cornea or limbus in 29 and through a scleral incision in 5; in 4 cases in which the steel entered through the sclera, extraction was through the original wound or scleral incision. Of the 38 eyeballs lost, the steel entered through the cornea in 33, at the limbus in 2, one through the sclera, and 2 unknown.

Several methods are followed by the surgeons at Moorfields in the extraction of foreign bodies, but the usual plan is to drag the foreign body into the anterior chamber by the Haab magnet, incise the cornea opposite to the situation of the body half-way between the edge of the pupil and the limbus, and then introduce the terminal of the small magnet or magnetized spud.

A comparison of the visual results of the cases embraced in the two reports above mentioned, with those secured in the cases included in this paper, is as follows: Since only those cases which have been under observation for a period of at least eight months are included in the reports of Wharton and Goulden, the same plan is followed in compiling the cases of the writer.

	WHARTON.	GOULDEN.	SWEET.
Wound of cornea or limbus:			
Steel anterior to vitreous—			
V = $\frac{6}{12}$ or better	12	11	14
V = Less than $\frac{6}{12}$	0	6	6
Steel in vitreous—			
V = $\frac{6}{12}$ or better	0	8	24
V = Less than $\frac{6}{12}$	14	9	62
Wounds of ciliary body:			
V = Less than $\frac{6}{12}$	5	..	...
Wounds of sclera:			
V = $\frac{6}{12}$ or better	0	1	2
V = less than $\frac{6}{12}$	2	3	12
	33	38	120

The figures of Wharton and Goulden comprise cases in which extraction in the majority of instances was practised by the giant magnet, drawing the foreign body through either the anterior chamber or the open entrance wound, without previous *x*-ray localization, while those included in the writer's tables were all examined by the *x*-rays prior to operation, and the steel in most instances was attracted through a meridional scleral incision as close as possible to its indicated position. While some interest may attach to a study of the visual results of the two plans of treatment, such a comparison is of little value in determining the superiority of either method. The fate of an injured eye depends more upon the several factors to which attention has previously been called than upon the particular method pursued in removal of the metal. The advocates of the scleral incision believe that the use of the giant magnet in the extraction of bodies of unknown size and position through the anterior segment of the eyeball is not without danger, and evidences are not wanting to prove that this contention is true. The objections made that a scleral incision for the purpose of extraction is followed by retinal detachment at the point of operation is not borne out by the cases in which clear media permit ophthalmoscopic examination years after operation. Retinal detachment after injuries of foreign bodies is not uncommon, but I have not seen it occur at the point of the scleral incision. The lodgment of a piece of steel in the retina or choroid, the subsequent inflammation, and the shrinkage of the new-formed fibrous tissue that must follow the removal of the metal are probably more important factors in the cause of retinal detachment than is a clean-cut meridional incision in the sclera. Wharton shows 5 cases of retinal detachment following extraction by the giant magnet through the anterior chamber, and in 4 of these the injury was recent.

DISCUSSION.

DR. CHAS. STEDMAN BULL, New York: I wish that such cases as these could be followed out, in order that we might know the final results as to vision; for I have been making some investigations in regard to cases of my own in the past year where I was able to follow the cases, and I was surprised to learn what a very large percentage of the cases which had left my observation with useful vision had ended in total loss of the eye.

There are two or three facts mentioned in the paper that most of us do not appreciate. One which attracted my attention at once was the matter of the shock given to the eye by the entrance of a foreign body, that shock varying in intensity according to the size of the foreign body and the impression made upon the eye by such shock. Moreover, many of us have not appreciated the violence done to an eye by the action of the giant magnet in drawing the foreign body forward to a region where it could be extracted.

DR. CHARLES J. KIPP, Newark: In regard to the point brought out by Dr. Sweet of the difficulty of locating a foreign body near the posterior pole, some time ago I saw a case in which one of the most expert operators in New York localized the foreign body immediately behind the sclera, and the case was not operated upon. I saw the patient six months later, when there were symptoms of siderosis, and the eye was lost. Since then I have applied the magnet in all cases in which the radiograph showed the foreign body outside the eye.

DR. P. A. CALLAN, New York: I wish Dr. Sweet had emphasized more the necessity of not being satisfied with one series of plates. I had a case recently in consultation where an expert in New York had taken two plates and concluded that there was no foreign body there. The patient, at my suggestion, was turned over to Dr. Dixon, who located a foreign body, 2 by 2 mm., 13 mm. back from the cornea and about in the median line. It had been there two or three weeks and there was then no chance of saving the eye.

I would like to emphasize, too, that the surgeon should not be satisfied with one or two attempts to remove the foreign body. I do not think we can do better than follow out Haab's suggestion, bringing it around into the anterior chamber and removing

it; but in doing that we must be careful not to get it entangled in the ciliary process. That can be avoided by manipulating the magnet in a proper way. I believe making a flap in the sclera leads to disaster.

With regard to this foreign body, I would like to know how it was gotten out. The smallest one I have ever taken out weighed $\frac{1}{400}$ gr., but the giant magnet had no effect on it. I did an iridectomy and used the small magnet. This one is much smaller than that.

DR. H. W. RING, New Haven, Conn.: I would emphasize what Dr. Bull has said as to the giant magnet. From my observations I have become convinced that the giant magnet had better be used as a last resort rather than the first. The smaller magnets, like the Parker, Johnson, and Sweet, will remove the foreign body in the great majority of cases and will produce less shock and damage to the eye.

DR. W. B. JOHNSON, Paterson: I feel certain that Dr. Bull's statement that many cases in which foreign bodies have been removed by the magnet result eventually in loss of sight is correct. Even if a slow form of cyclitic inflammatory trouble does not develop, there is a loss of vision, and these cases, if followed, will generally show progressive loss of vision until such time as the eye is useless. My experience has not been that these eyes become a source of sympathetic irritation frequently, but they certainly do lose their vision.

In relation to the use of any form of magnet, I believe as a routine procedure it is much better to use a small magnet. My own, which is the lightest of any, and which is very portable, has in my hands been very satisfactory, that is to say, I have been able to remove any foreign body I have tried, except, I think, in one instance. That case I afterward took to the giant magnet, and that magnet was also unsuccessful. I believe that a great deal of injury can be done to an eye by the use of a large magnet, especially if the foreign body is of considerable size, by efforts to lead it around the lens. The manipulation of the magnet is uncertain. It is surprising, however, to see a foreign body in the eye follow the motion of the magnet, but still, with all that, in undertaking to lead the foreign body around the periphery of the lens one is apt to lead it unintentionally into the ciliary process and do a considerable amount of damage.

DR. MCCLUNEY RADCLIFFE, Philadelphia: In answer to Dr. Callan's question as to how this foreign body was removed, I would say that I found it by accident. Dr. Sweet had informed me that there was no foreign body there, and I then proceeded to remove the soft lens cortical, and during the operation saw the little black speck, which was washed out with the cortical matter.

DR. SAMUEL THEOBALD, Baltimore: I am glad to have had Dr. Sweet explain how it may happen that a foreign body which seems to be lodged outside the eyeball may be within. I have had such a case recently at the Johns Hopkins Hospital. Dr. Baetjer, who is the hospital skiagrapher, is very skilful, and had special instruction from Dr. Sweet in eye work, but in a case which I had several months ago, he located the foreign body outside the scleral coat. The eye was in bad condition and I enucleated it, and, after having done so, put the tip of the magnet in the orbit, hoping to pick up the foreign body. When the eye was opened, a small piece of steel was found which I was able to show to Dr. Baetjer.

DR. S. LEWIS ZIEGLER, Philadelphia: Dr. Sweet has kindly placed two of my patients on his list of unusual cases. The first case illustrates two strong points: (1) the value of the grooved foreign-body forceps in the removal of non-magnetic foreign bodies; (2) the value of good illumination when it is possible to utilize it. The second case illustrates two weak points in the technic: (1) failure in the exact localization of foreign bodies when near the ocular tunics, and (2) failure in the removal of foreign bodies covered with exudate, even with the giant magnet.

The first case he has referred to is Case 580, in which a young boy was injured by the explosion of a dynamite cartridge. The piece of copper entered the eye, became encapsulated, and suspended in the vitreous by a fibrous thread. Dr. Sweet confirmed the uncertain diagnosis of a foreign body, and it was removed through a scleral incision by the aid of a finely grooved "nettoyer" forceps. Although the lens was a trifle hazy, the electric head-lamp thoroughly illuminated the field of operation and enabled me to see the blades of the forceps as they engaged the foreign body and extracted it. I have examined this little patient within two weeks, and find that he still retains practically normal vision with a correcting cataract glass, although the eye

has passed through the operations of discission and V-shaped capsulotomy since the foreign body was extracted.

The second case he has referred to is Case 508. The examination of this case revealed considerable trauma, which had occurred a week before he was seen by me, and Dr. Sweet thought there might be scleral perforation. Both the Sweet magnet and the Haab magnet were applied internally and externally with negative results. The patient would not consent to enucleation and eloped, but later succumbed to the more persuasive manner of Dr. de Schweinitz and consented to enucleation. The foreign body was found inside the eye, but a mass of exudate had covered and held it against the retina. Had I realized this condition I would have acted as I did in another case of one and one-half years' standing, where, after making the scleral incision, I drew the Graefe knife across the encapsulated foreign body, applied the Sweet magnet directly to the foreign body, and removed it en masse, fibrous capsule and all. The latter case well illustrated the possibilities of two foreign bodies being projected toward the eye, the larger one having cut the eye and dropped downward, while the smaller one perforated the sclera, passed across the eye, and lodged on the ciliary body. Although vision had been maintained for a year after the accident, mild siderosis and cataract had developed before I saw him. Recovery was uneventful.

I desire to call attention to still another point of interest in this radiographic work, and that is the great value of negative findings. I am sure I have referred many cases to Dr. Sweet in which the assurance of the absence of a foreign body was most gratifying to both patient and surgeon. On the other hand, in a very few instances my slight suspicion was confirmed by the radiographic diagnosis of a minute foreign body.

Dr. Sweet is to be congratulated on his carefully prepared statistics. I feel sure that he has sometimes had greater difficulty in extracting foreign bodies from our records than we have had in removing foreign bodies from our patients' eyes.

DR. WILLIAM M. SWEET, Philadelphia: It is impossible to follow all the cases of injury from foreign bodies, as suggested by Dr. Bull, since most of them are workingmen in the large industrial establishments, and frequently change not only their place of work, but also their residence. The last depression in

business scattered many of the men whom I had examined, and it was impossible to trace them. The comparative tabular statement at the end of the paper includes only cases that have been under observation for a considerable time, and is therefore a fair indication of the results of operation.

I think it is rare for the *x*-rays to fail to show a foreign body situated in the eyeball. In all suspicious cases it is my custom to make several sets of plates, changing the position of the tube with each exposure. If a set of radiographs is secured that gives a clear outline of the orbital bones, and no shadow is shown on the plates, I feel confident that the eyeball does not contain a foreign body. It is possible, however, for a minute body, as in Dr. Radcliffe's case, to be situated in the anterior portion of the eyeball, and the shadow cast to be so faint as to be lost in the denser shadow of the bones at the external orbital margin.

I do not see how it is possible, except in cases of recent injury, to guard against a foreign body, as it comes forward under the pull of a powerful magnet like the Haab, from becoming imbedded in the ciliary processes, as cautioned by Dr. Callan. The attraction of the magnet and the distance it is away from the eye are proportionate to the size of the metal and the resistance of the tissues in which it is imbedded. It is impossible, therefore, to measure the amount of resistance offered by the exudation which covers the metal, so that the magnet must often be brought close to the eye before the power exerted is sufficient to disengage the body. The metal then comes forward under the full strength of the magnet, and often is imbedded in the ciliary body.

I believe extraction through a scleral incision, especially if the case is not seen immediately after the injury, to be a safer procedure, and I do not recall an instance of detachment of the retina occurring at the point of the scleral incision. If the medium-sized magnet fails to remove the foreign body, even if the giant magnet succeeds, the eye is apt to be ultimately lost from iridocyclitis.

PHYSICAL ECONOMICS,

COMPRISING A MATHEMATICAL FORMULA FOR DETERMINING THE EARNING ABILITY OF A PERSON WHICH MAY BE USED EITHER TO RATE HIM, OR TO OBTAIN HIS ECONOMIC VALUE, AND TO ASCERTAIN DAMAGES TO ANY PART OR PARTS OF HIS BODY FROM INJURY OR DISEASE IN A MANNER EQUITABLE TO ALL CONCERNED.

ERASTUS EUGENE HOLT, A.M., M.D., LL.D.,

Portland, Maine.

The mathematical formula for the normal earning ability of the body has been specially devised for determining the earning ability of a person in accordance with all the existing conditions of its indispensable elements, defined by an analysis as the functional, the technical, and the competing ability. When these elements are used as factors in the formula, and the problem is solved according to the principles upon which it is constructed, the resulting value is the earning ability. This may be used either to rate that person, or to obtain his economic value. With his economic value his economic loss from damages to any part, or parts, of his body from injury or disease may be ascertained in a manner equitable to all concerned. In this analysis of a person it is evident that the structures and functions of the body are absolutely indispensable to the earning ability of that person. These, therefore, are of first importance, and may be designated the functional ability of the body, and represented by F, the first letter of the first word, as a symbol to be used in the formula.

The next most important element of a person's earning ability is his education, in its broadest sense. He must have training of the mind and body to prepare himself to perform the duties of some occupation if he is to have an earning ability

of economic value. The second element of the earning ability of a person may be designated the technical ability, and represented by T, the first letter of the first word, as a symbol to be used in the formula.

The third and last element of the earning ability of a person is his ability to secure work and accomplish what is required of him, or to secure an occupation and perform the duties of it successfully. He must obtain some kind of work and serve an employer successfully in order to have an earning ability of economic value. This third and last indispensable element of the earning ability may be designated the competing ability, and be represented by C, the first letter of the first word, as a symbol to be used in the formula.

We have thus analyzed a person and determined that there are three indispensable elements to his earning ability, represented by the three symbols, F, T, and C.

We will let E be a symbol to represent the earning ability, and now, expressing these three factors as equal to E, we have F T C = E, the mathematical formula for the normal earning ability of the body.

It is evident that these three elements of a person fulfil all the requirements of his earning ability, and that they must be used as factors to meet every existing condition of the elements of that earning ability. They are not of equal value in the earning ability, although the efficiency of each one is interdependent upon the other, F being the most important; T second in importance; while C is least important, because it depends on the efficiency of the other two factors and the demands of employers. C not only depends upon F and T for its efficiency, but the elements of which it is composed are the same as F, and therefore when F is damaged from injury or disease, C is also damaged, either to the same extent or to a greater or less degree, according to the functions of the part or parts involved in the vocation of the person.

In order to determine the condition of F in any given case of

damage to the body we must examine the different systems and organs of which it is composed and compare and test them with standards of measurement. The difference between what we find the functions of any given system or organ to be and the standard of measurement is a fraction of that system or organ which, subtracted from it regarded as unity, gives a remaining fraction which represents the remaining functions of the system or organ examined. In order to obtain these values of F upon the same principles upon which E is determined we must analyze the structures and functions of the body and see how they may be grouped into units according to their development and associated functions, and used as factors in a mathematical formula for obtaining the existing functional ability of the body. In this analysis we again use the same method employed in the natural sciences to obtain the value of any physical force, because this method will give the values of the structures and functions of the different systems and organs, which will always agree with all their existing conditions. Therefore, this method, as here applied, not only gives results which are scientifically correct, but which agree in every particular with the actual existing conditions of the elements of E. In the analysis of F for the purpose of determining the elements which may be used as factors in a mathematical formula for obtaining its value by a method based upon the same principles as that by which E is obtained, F is resolved into its component parts by first selecting and grouping all the systems and organs of the body into four units; and, second, dividing each unit into three parts by selecting such systems and organs as may be used as factors of the unit. We thus have three parts of each unit as factors of the unit and four units as factors of F, making twelve factors of the four units, each one of which bears the same relation to its unit as each unit does to F. We are thus able to determine the structural and functional conditions of each system and organ of the body separately and together as they carry on their functions in the body.

As much as possible systems and organs have been selected and grouped together as units in accordance with their development and associated functions in the body, it having been found sufficient for all practical purposes to have four divisions of F as units, and to have three divisions in each unit as factors of the unit which when designated by the first letters of the alphabet are as follows:

F = {
- a = { Osseous, articular, and muscular systems, consisting of: ..... } { e, the bones; f, the joints; g, the muscles. }
- b = { Circulatory and respiratory systems, consisting of: ..... } { h, the vascular system; i, the blood; j, the lungs and their accessory organs. }
- c = { Digestive and genito-urinary systems, consisting of: ..... } { k, the alimentary canal and its accessory organs; l, the skin; m, the kidneys with the genital organs. }
- d = { Cerebro-spinal system, nerves, and organs of special sense, consisting of: ..... } { n, the brain, its membranes, and its nerves; o, the spinal cord, its membranes, and its nerves; p, nerves and organs of special sense. }

This analysis of F shows its composite nature, and it also shows that each division of a unit must be regarded as a factor of the unit and the units as factors of F, in order to meet and fulfil every condition of the systems and organs of the units that may exist in health, or take place in damages to the body from injury or disease.

This may be illustrated very readily in unit d, if from injury or disease we suppose that a person becomes permanently blind and deaf. It must be admitted, without argument, that a person who has become permanently blind and deaf has no functional ability and, if so, no earning ability. This is exactly the value obtained by considering unit d equal to the product of its three factors, namely, n o p = d, for, if in examining unit d of a person we found the functions of sight and hearing

gone, we would give the remaining functions of the factor p as equal to O, and in any computation, if one of the factors becomes O the product is O also; hence, d becomes O, and if d becomes O, F also becomes O. If F becomes O, then E becomes O. It will be seen then that, by considering the divisions of a unit as factors of the unit and multiplying them, we arrive at values which correspond exactly to the existing conditions of the factors of a unit, and by considering the units as factors of F we arrive at a value of F which corresponds exactly to the existing conditions of the units, and, finally, by considering F, T, and C as factors of E we arrive at values which correspond exactly to the existing condition of the elements of E. Thus, all these values are obtained by one uniform method which corresponds in every particular to that which is employed in the natural sciences to obtain the value of any physical force. The only other way to obtain values from similar conditions is by addition and subtraction. This leads to an absurdity, as may be seen from the case just cited; for, if the other two divisions of the unit d were normal, which is a conceivable condition of a person (he might be blind and deaf and the other two parts of the unit d, n, the brain, and o, the spinal cord, might be normal), and we arrived at the value of the unit d by addition and subtraction, we would have two-thirds of it left; and if the other three units of F were normal, which is also conceivable, we would have eleven-twelfths of F left, which would be an absurdity when that person was permanently blind and deaf. Those who are still inclined to cling to empirical methods reply that no one would think of attempting to determine the functional ability of a person permanently blind and deaf. That would be true in such a manifest total disability, but if these empirical methods are employed to obtain the loss from damages to the body of lesser degrees, the results thus obtained are just as liable to be proportionately as far from the actual disability of that person as that obtained by these methods in the case cited of the person permanently

blind and deaf. In other words, when damages to the body are obtained by empirical methods, the results are uncertain: they may or they may not agree with the actual existing conditions, whereas scientific methods which agree with the actual conditions of the body in health will also agree with the actual existing conditions of the body when standards of measurement have been agreed upon and are used to obtain the remaining functions of the systems and organs of the body in accordance with the principles upon which the formula is constructed.

In this analysis of F we have changed its coefficient of unity into (a b c d), and as C depends upon the same elements for its existence as that of which F is composed, its coefficient becomes (a b c d), and thus expressed in the formula for the normal earning ability of the body we have:

$$(a\ b\ c\ d)\ F\ T\ (a\ b\ c\ d)\ C = E.$$

T is gained during the growth of the body, and is largely dependent upon the condition of F, as may be observed in persons with partial loss of sight or hearing. As T is so largely dependent upon F, the latter should be taken into consideration in ranking at school. We might mention, parenthetically, that this is being done at the University of Maine, where F and T are considered factors of the efficiency of a student. The gain in the efficiency between the beginning and the end of the first four years, by this method which ended in 1908, showed that it was those students who made the greatest effort to improve their physical and mental conditions that had the greatest percentage of gain and therefore won the prizes.

As important as T is to the person in ranking him and in his earning ability, when that person's vocation becomes fixed, T becomes fixed also and equal to one in establishing damages. The technical ability is not injured, but limited only in proportion to the damage to F, whose impairment includes these damages; therefore, T may be discarded and the formula, modified

for determining damages to the body from injury or disease, becomes:

$$(a\ b\ c\ d)\ F\ (a\ b\ c\ d)\ C = E.$$

In determining damages to any system or organ of the body, the physician must first examine the system or organ and compare the condition in which he finds it with standards of measurement for such system or organ. By this comparison he determines the amount of the loss to the system or organ in any given case. If he assumes that the system or organ was in a normal condition before this particular damage occurred, then the difference between what he finds and the standard of measurement represents a fractional loss of that system or organ. This fractional loss, subtracted from the system or organ regarded as unity, gives the remaining value of that system or organ. When the injury to the body occurs in different parts of a system or organ included in either one of the three divisions of a unit, namely, in either one of the factors of a unit, the damage to the several parts may be added together for the purpose of obtaining the total amount of damages to that factor of the unit, and this amount subtracted from the factor of the unit regarded as one gives the remaining value of that factor. When an injury occurs to any other factor of that unit the total damage to that factor and its remaining value may be obtained in the same manner. If these are the only two factors of a unit damaged, their remaining values are to be multiplied together for the remaining value of the unit. If all three factors of a unit are damaged, their remaining values are to be multiplied together for the remaining value of the unit. If either of the other three units of the body have been injured, their remaining value is to be obtained in a similar manner. If only one unit of the body has been injured, the remaining value of that unit is the remaining value of F. If two or more units of the body have been injured, then the remaining value of these damaged units are to be multiplied together for the remaining

value of the units, and this remaining value will be the remaining value of F.

The methods here set forth apply alike to all the systems and organs of the body. They are based upon scientific principles, and when used with standards of measurement obtained upon the same basis will determine the damage of F of all classes corresponding to the loss in each individual case.

We will now illustrate their application first to damages to the eyes alone, and then in connection with damages to other parts of the body occurring at the same time.

Assuming that both eyes were normal previous to an injury that caused sudden loss of sight of one eye, the eye itself being retained and presenting nothing abnormal in appearance, what is the damage to the person's earning ability? The loss is in the field of vision and in the functions of binocular vision. It diminishes a person's ability to guard himself against an injury which may come in the region of the lost field of vision, and it also subjects him to accidents from his inability to estimate distances correctly. This loss affects a person more at first than after he has become accustomed to it, and more in some occupations than in others; nevertheless, the loss is a constant one and liable to lead to serious accidents. On the law of averages this liability to further accidents and loss of functions must be taken into consideration in determining the loss of sight of one eye. We must also consider the cause of the loss of sight of one eye and its effect in the near future, or remotely upon the functions of the other eye. The actual loss in the field of vision when the sight of one eye is lost may be ascertained by considering the two fields to extend from a common center 90 degrees each way, half of a circle, or 180 degrees. Each eye has a field of 90 degrees to the temporal side and 60 degrees to the nasal side of its own, thus leaving 30 degrees on the temporal side belonging to each eye alone. Therefore, when the sight of one eye is gone the loss in the field of vision of the two eyes together is 30 degrees belonging to the eye alone

whose sight has been lost. This is one-sixth of the field of vision of both eyes together, therefore five-sixths of the field of vision is left. This loss in the temporal field of vision of 30 degrees is not so serious to a person as the loss of 120 degrees of the field of vision which is in common with the other eye, as the latter is more important in estimating distances, etc., as anyone may ascertain by a little experiment. Taking into consideration the loss in the temporal field, which leaves a person unguarded against injuries from that direction, and the loss in the person's ability to estimate distances and avoid accidents from that source, the loss may be determined to be 0.16 in factor p, and therefore 0.84 of that factor remains. No other factor of the unit d being injured, this is the remaining value of unit d, and no other unit of the body being injured, it is the remaining value of F also. Introducing this value into the formula as the coefficient of F and C, we have 0.84 F 0.84 C = E.

We must now determine the status of C of a person with the loss of the sight of one eye with the external appearance as good as the other eye, which is normal. It is evident that it would be but slightly affected either in his ability to execute or in the estimation of an employer to perform his duties. He would not be selected to perform the duties in any public conveyance, neither would he be selected to perform the duties of a mechanic around machinery, other things being equal in another man with two good eyes who was available. Taking all these conditions into consideration, on the law of average we will select for the exponent of $C_{\frac{1}{10}}$, and we have (1) 0.84 F $0.84_{\frac{1}{10}}$ C = E. Hence E = 0.8257, and the loss in E is 0.1743, or $174.30 on each $1,000 of the economic value of the person. If the person were twenty-five years of age and earning $1 per day, or $300 per year, his economic value would be according to the evom table $6114.51, equal to 6.11451 thousands, and multiplying the loss on $1,000, namely, $174.30 by 6.11451, we have $1,065.75, the economic loss for the loss of the sight of one eye of a person earning $1 per day at the age of twenty-five whose

economic value is determined on the basis of $1 a day or $300 a year, at a 3½ per cent. discount.

If the same person met with an accident and the eye had to be removed, the loss in the functional ability of the eyes would be the same, but C would be more seriously affected, for, however well an artificial eye might match the good eye, it would be difficult to conceal the fact that the eye had been removed. Therefore, C would be damaged more by the removal of an eye than by the loss of the sight of an eye in any vocation. If we deterimne that C is damaged as much as F, in a certain vocation when an eye has been removed, we would have (2) 0.84 F 0.84 C = E. Hence E = 0.7056, and the economic loss would be 0.2944, or $294.40 on each $1,000 of the person's economic value. Multiplying $294.40 by 6.11451, we have $1,800.11, which is $734.36 more than when the sight of an eye was lost as obtained by 0.84 C being considered damaged 6 degrees less than 0.84 F. If the vision in one eye was 0.4 scientific standard of measurement, and the good eye should be lost by accident, then the damage to C would be more serious than to F, and consequently C would be diminished in value to a greater degree, because the person would not be able to do so much or so good work as before. To diminish C in accordance with the principles upon which the formula is constructed, we must multiply it by itself in order to have the remaining value of E correspond to the damage to C. If it were determined that C was damaged to the first degree more than F, then we would have (3) $0.84\ F\ 0.84^2\ C = E$. Hence E = 0.5927, and the economic loss would be 0.4073, or $407.30 on each $1,000 of the economic value of the person. Multiplying $407.30 by 6.11451, we have $2,490.43, which is $690.32 more than when C is damaged to the same degree as F. We thus have to consider three conditions of C, namely, when it is damaged to the same degree as F, and when it is damaged to a greater or a less degree than F.

The treatment of these conditions may be stated as follows:

(1) When C is damaged to the same degree as F, their co-

efficients are to be multiplied together to obtain the value of E.

(2) When C is damaged to a degree greater than F, the coefficient of C must be diminished in value before it is multiplied by the coefficient of F, in order to have E diminished to correspond with the greater amount of damage to C.

(3) When C is damaged to a less degree than F, the coefficient of C must be increased in value before it is multiplied by the coefficient of F, in order to have E increased in value to correspond with the lesser amount of damage to C.

The computations of (1) and (3) are given in Table 1, which gives E when C is damaged to six different degrees less than F, and the economic loss on each $1,000 of economic value for these computations is given in Table 3.

The computations for (2) are given in Table 2, which gives E when C is damaged to nine different degrees more than F. The economic loss on $1,000 for each of these computations is given in Table 4.

Table 5 gives the fractional loss of the parts therein named as standards of measurement for them. When found convenient, these may be used for comparisons for the loss of functions in other parts of the body.

Table 6, the evom table (the word having been made from the first letter of each word of the phrase, economic value of man), is constructed on the dollar basis, so that the economic value of a person earning any fractional part of $1 a day, or $300 a year, or any number of times $1 a day, or $300 a year, may be readily computed. By these tables computations for obtaining the economic loss of a person from damages to his body from 0.01 to 0.80 are given, and are as accessible as those of any tables in which the values have been worked out for the purpose of shortening computations. There are therefore no more computations to be made than in obtaining the amount of a town or city tax of a person when we know the rate of taxation on $1,000 and the amount of property for which that

person is assessed. Indeed, the process is similar, and for that reason may be readily understood. It will be seen that in Tables 1 and 2 the values of E are worked out for all practical economic conditions that may occur in F and C, and the economic loss on $1,000 is given in Tables 3 and 4 for each computation.

For the purpose of illustrating how E is obtained when two different units of the body are injured, we will suppose that a person having two normal eyes meets with an accident which necessitates the removal of one of his eyes and his left hand at the wrist-joint. The loss in the functions of unit d is 0.16, and, therefore, 0.84 remains. The loss in the functions of unit a is 0.20, and, therefore, 0.80 remains. No other units of the body being injured, their value is normal and equal to one; therefore, we have 0.80 a 0.84 d = F. Hence F = 0.672, and, introducing this value as the coefficient of F and C into the formula for the normal earning ability of the body, we have, 0.672 F 0.672 C = E. We must now determine C in the vocation followed. It is evident that C is damaged to a greater degree than when the eye alone was lost. We then considered C damaged to the same degree as F. In the loss of an eye and the left hand we will determine that C is damaged to the first degree more than F, therefore we have (4) $0.672\ F\ 0.672^2\ C = E$. Hence E = 0.3034, and the economic loss is 0.6966 or $696.60 on each $1,000 of the economic value. Multiplying this by 6.11451, we have $4,259.36 for the loss of an eye and the left hand of a person earning $1 per day, or $300 per year, when the economic value has been determined upon a 3½ per cent. discount basis. This gives the loss of the left hand in connection with the loss of an eye as $2,459.25, on the basis of the person's economic value being $6,114.51. If the right hand were lost with an eye, C would be damaged to a greater degree than when the left hand was lost. If it were determined that C was damaged to the second degree greater, then we would have, (5) $0.672\ F\ 0.672^3 C = E$. Hence E = 0.20389, and the economic loss would be $4,868.47. If it were determined that C was

damaged to the next degree greater, or the third degree, then we would have (6) 0.672 F 0.672ᵉC = E. Hence, E = 0.137, and the economic loss would be $5,276.81 on the basis of the person's economic value being $6,114.51. It will be seen by these illustrative cases that C can be varied to meet every possible condition that may occur to it from damages to F from injury or disease, and thereby E may be determined in accordance with every existing condition in F and C.

There may be a difference of opinions as to the standards of measurement for determining the loss to F in any given case of damage, yet, when these have been agreed upon, and the loss to F has been determined by them and a mathematical formula, the resulting value will always agree with the existing conditions of F in accordance with these standards. Therefore, it becomes a question of obtaining standards which will meet the economic conditions of F after being damaged from injury or disease. Although it is true that standards of measurement have not been determined and agreed upon for all parts of the systems and organs of the units of the body, nevertheless it is evident that if F has value the functions of each of the systems and organs of which it is composed must have its proportionate value. When each of these has been weighed, measured, compared, and tested in a scientific manner with regard to its economic value in a large number of cases, and an average value determined upon, this average value becomes a standard of measurement for that particular system or organ of the units of the body. It is in this way that all the scientific and economic standards of measurement now employed have been determined and agreed upon, and it is in this way that all the remaining ones will be established. Until the work of establishing these standards is completed we shall be obliged to employ such standards as have been agreed upon, and by the same methods by which these have been obtained determine new ones for all the remaining systems and organs of the units of the body which will eventually be accepted as standards of measure-

ment. The question of standards of measurement for determining the functional ability of the body after damage from injury or disease is fundamental to the question for obtaining the remaining earning ability in such conditions. Without the former the latter cannot be obtained by the mathematical formula for the normal earning ability of the body. In determining whether the functions of the body are normal or abnormal in any given case, we must have a standard of measurement for the normal conditions of these functions, whether viewed separately or in conjunction with each other, as they exist in the body at the different periods of life. In other words, we must have the standard man for the different periods of life in order to determine how much a person is damaged in a given case.* The difference between what we find in this given case and the standard man for this period of life is a fraction of the functions of the part or parts examined, regarded as a whole, which when subtracted from it gives the remaining functions of the system or organs examined. For instance, if by an injury the sight of both eyes is reduced to 0.5, scientific standards of measurement, the fields of vision being only slightly affected, what is the loss to the person? The first question that arises is, how does this loss of half the sight of both eyes affect the functional ability of the body? The next question is, what is his competing ability in his vocation?

Therefore, in order to determine the loss in the earning ability of the person, we must find out how much the loss of one-half the vision of both eyes affects the functional ability of the eyes in the vocation followed. According to Magnus and Würdemann,† students of all professions, that is, skilled laborers, actually require three-fourths of normal vision, accord-

*The dismembered parts of the standard man scattered throughout medical literature have been collected by Dr. C. R. Burr, of Portland, Maine, into a composite whole for each of the different periods of life, which he has designated, infancy, childhood, youth, manhood, change of life, old age, and second childhood.

†"Visual Economics."

ing to scientific standards of measurement, in order to perform the duties required of them. If this is the standard accepted, then a person who has sustained a loss of half the vision of both eyes would have sustained a loss of one-third of the vision actually needed to carry on the work of his profession, because 0.5 from 0.75 leaves 0.25, and 0.25 is one-third of 0.75; therefore, the person has lost one-third of the vision actually needed, and, if so, has two-thirds left. If no other system or organ is damaged this becomes the coefficient of F and C, and we have: $\frac{2}{3}$ F $\frac{2}{3}$ C = E. We must now consider how the loss affects the person in the particular vocation he follows, namely, in his competing ability. If it is determined that the loss of half the vision of both eyes damages a person's competing ability less than it does his functional ability, because there is no external appearance of the damage, and from this fact and all the circumstances in the case we determine that his competing ability is damaged only to the first degree less than his functional ability, we have for the formula, $\frac{2}{3}$ F $\frac{2}{3}$ C = E. Hence E = 0.5487, and the loss is 0.4573, which is $457.30 on each $1,000 of the economic value of the person. Multiplying $457.30 by 6.11451, we have $2,759.47 for the loss of half the vision of both eyes in a person earning $1 per day, or $300 per year. If he were earning $2 per day, then the economic loss would be two times $2,759.47, or $5,518.94. If he were earning $3 per day, then the economic loss would be three times $2,759.47, or $8,278.41, and so on. If the indemnity is too much for the person's earning ability, then the standard of measurement for determining the remaining functional ability is too high. If the person was an accountant, the standard of measurement would be reasonable and the result equitable. If the person was in a profession with less demands upon the eyes, and we determined that the competing ability was damaged to the least degree given in Table 1 column 9, then we would have $\frac{2}{3}$ F $\frac{2}{3}$C = E. Hence E = 0.6432, and the loss would be 0.3568, or $356.80 on each $1,000. Multiplying $356.80 by 6.11451,

we have $2,169.65. This is $589.82 less than when C is considered damaged to the first degree less than F. There would be just this difference in each computation when C is considered damaged to the first degree less than F, and when it is considered damaged to the least degree less than F, as given in Table 1, for any number of times one dollar a day, or $300 per year. It will be seen, then, that it is a question of standards of measurement for the functional ability and of a determination of the competing ability for the vocation followed.

Why not determine the earning ability directly from the loss in the functional ability, that is, estimate it from this loss according to the method universally in use to-day? Why is this method not just as good? In the first place, it would be guesswork, and that is not a scientific method. Why is such a method guesswork? To reiterate, for the purpose of making this point clear, let us refer to what has gone before in this paper.

In the analysis of a person to determine the elements which are indispensable to the earning ability, and which may be used as factors and multiplied to produce it so as to meet all the existing conditions relative to the earning ability, we found them to be three, namely, the functional, the technical, and the competing ability. We have shown conclusively that these elements must be used as factors to meet all the existing conditions of the earning ability. We will apply this analysis to one of the most common of physical forces, namely, a water power, to show why a mere estimation of the loss in the bodily functions will not give the loss to the earning ability, and why such loss to the earning ability cannot be determined from the functional loss alone. In applying this analysis to a water power we will let the volume of water in pounds going over a dam be the functional ability of the water power, because it is what nature gives to it, just as the body is what nature gives to man. The dam, the water-wheel, and its connections to the counter-shaft we will designate the technical ability of the water power, because it is what man gives to it in consequence

of his own technical ability, just as the technical ability is given to man by man. The competing ability of a water power depends upon its location and its ability to perform work in competition with other powers, such as steam, gasoline, animal, and man power. It will be seen that in order for a water power to have an earning ability it must have all three of these elements. There can be no question about the need of the first two elements, namely, the volume of water in pounds going over a dam, and, second, the dam, water-wheel, and its connections to a counter-shaft in order to give power. To illustrate the importance of the third we might mention that in Labrador there are some magnificent water powers. These might be converted into power by building dams and installing water-wheels and counter-shafts, so as to furnish thousands of horse power, but these thousands of horse power would have no earning ability without a competing ability and what would be the competing ability of thousands of horse power up in Labrador? It is plainly evident, that at present, it would have no competing ability on account of its location, and therefore would have no earning ability.

From the comparison of the earning ability of man with that of a water power, it is evident that the earning ability cannot be determined from a consideration of his functional and technical ability alone or any estimation of them. We must have another element used as a factor, namely, the competing ability, in order to make the earning ability available in man and in a water power. The earning ability of man, or a water power, cannot be estimated from what nature gives to them alone, for without taking into consideration the technical and competing ability needed for both there would be no value in them for economic purposes, because they would have no earning ability. We have dwelt upon the fundamental part of this subject sufficiently to show that any estimation of the loss of the earning ability from the loss in the functions of the body alone is mere guesswork; that the loss in the earning ability

from damages to the functional ability can be determined only by the use of an analysis which defines the indispensable elements of the person's earning ability, namely, the functional, the technical, and the competing ability, to be employed as factors in a mathematical formula, and that it must be solved in accordance with the principles upon which the formula is constructed in order to arrive at the value of an earning ability which will agree with all the existing conditions of the essential elements of that earning ability.

These principles are involved in the traffic in all commodities, in daily use by man, such as animals, hay and grain, vegetables, fuel, lights, and manufactured articles of all kinds.

In the earning ability of a horse we have an illustration of the application of these principles, just as in the case of man, for it depends upon the same elements which may be given the same name and may be represented by the same letters as symbols in a mathematical formula, and we then have F T C = E, for determining the value of a horse. In determining the functional ability of a horse we have to know all the elements that enter into such functional ability the same as in man, namely, age, height, weight, girth, and the functional conditions of the four units of the horse. The technical ability is quite as important, for a horse would have no earning ability if he was not trained as a driving or a work horse. Man gives him this in consequence of his own technical ability. The competing ability is also of quite as much importance, for the horse has had to compete with all kinds of powers and has steadily been displaced by them until he is narrowed down to a limited field of service. It is therefore plainly evident that we must take into consideration all three of the elements of a horse and use them as factors in order to determine his earning ability, which will agree with all the existing conditions of that earning ability.

If we analyze the traffic in commodities we see how these principles, here applied to man, are in daily use without the

person using them having the least consciousness of their employment. Take, for instance, the purchasing of a barrel of apples. Here we have three elements that determine their value and earning ability to the producer, namely, quantity, quality, and price. If we employ the first letter of each of these words as a symbol, and use it in a mathematical formula, we have Q q p = V. Now, supposing we had a full barrel of apples, first quality, and the price was $4 per barrel, the value would be $4. When these values are introduced into the formula we have 1Q 1q 4p = V. Multiplying, we have V = 4. Now suppose at the next purchase there was only a half barrel of apples, same quality and price per full barrel. The storekeeper would tell you at once the cost would be $2. If we introduce these values into the formula we have ½Q 1q 4p = V; multiplying, we have V = 2; hence the cost of a half barrel of apples is $2. At the next purchase let us suppose that it was late in the season and the storekeeper had only half a barrel of apples and the quality was only half as good as first quality. The storekeeper would say you can have that half barrel of apples for $1. He does not consciously determine the result on a mathematical formula. Let us see how it is worked out on the formula. We have, ½Q ½q 4p = V. Multiplying, we have V = 1. Hence the value of that half barrel of apples is $1 when the price of a full barrel of first quality is $4. The same methods would be true in regard to the other commodities named. Thus we see these principles are really used in every-day life in determining the value of any commodity, which is the earning ability to the producer. We have extended these illustrations in order to show that the principles here advocated for determining the earning ability of a man and his economic value are employed in obtaining the values of commodities in every-day life, that really the elements of their earning ability must be used as factors in a mathematical formula and multiplied in order to have that earning ability agree with all the existing conditions of those elements.

TABLE 1

(1)	(2)		(3)	(4)	(5)	(6)	(7)	(8)	(9)
Loss in F	Computation made when C is damaged to the same degree as F, and when C is damaged to six different degrees less than F.								
	F	C	E=	$C^{1.2}$ E=	$C^{1.3}$ E=	$C^{1.4}$ E=	$C^{1.5}$ E=	$C^{1.7}$ E=	$C^{1.10}$E=
0.01	.99	.99	=0.9801	0.985	0.9865	0.9875	0.988	0.9884	0.989
0.02	.98	.98	=0.9604	0.9702	0.9731	0.9751	0.976	0.9770	0.9780
0.03	.97	.97	=0.9409	0.9554	0.9593	0.9622	0.9641	0.9651	0.9670
0.04	.96	.96	=0.9216	0.9408	0.9465	0.9504	0.9523	0.9542	0.9561
0.05	.95	.95	=0.9025	0.9262	0.9388	0.9376	0.9405	0.9424	0.9452
0.06	.94	.94	=0.8836	0.9118	0.9202	0.9259	0.9277	0.9315	0.9343
0.07	.93	.93	=0.8649	0.8965	0.9067	0.9132	0.9151	0.9197	0.9234
0.08	.92	.92	=0.8464	0.8822	0.8942	0.9006	0.9043	0.9089	0.9126
0.09	.91	.91	=0.8281	0.8681	0.8898	0.8881	0.8927	0.8972	0.9001
0.10	.90	.90	=0.81	0.8541	0.8685	0.8766	0.8811	0.8865	0.8901
0.11	.89	.89	=0.7921	0.8392	0.8552	0.8641	0.8695	0.8748	0.8784
0.12	.88	.88	=0.7744	0.8254	0.8430	0.8527	0.8580	0.8641	0.8685
0.13	.87	.87	=0.7569	0.8108	0.8308	0.8404	0.8456	0.8526	0.8578
0.14	.86	.86	=0.7396	0.7972	0.8187	0.8290	0.8342	0.8419	0.8571
0.15	.85	.85	=0.7225	0.7828	0.8058	0.8160	0.8228	0.8304	0.8347
0.16	.84	.84	=0.7056	0.7694	0.7926	0.8047	0.8114	0.8190	0.8257
0.17	.83	.83	=0.6889	0.7561	0.7802	0.7885	0.7992	0.8075	0.8142
0.18	.82	.82	=0.6724	0.7429	0.7675	0.7806	0.7880	0.7970	0.8036
0.19	.81	.81	=0.6561	0.729	0.7549	0.7686	0.7759	0.7857	0.7929
0.20	.80	.80	=0.64	0.7152	0.7424	0.7568	0.7648	0.7752	0.7824
0.21	.79	.79	=0.6241	0.6915	0.7299	0.7449	0.7528	0.7639	0.7710
0.22	.78	.78	=0.6084	0.6887	0.7183	0.7332	0.7417	0.7527	0.7605
0.23	.77	.77	=0.5929	0.6752	0.7060	0.7214	0.7299	0.7415	0.7499
0.24	.76	.76	=0.5776	0.6627	0.6938	0.7098	0.7189	0.7303	0.7394
0.25	.75	.75	=0.5625	0.6495	0.6817	0.6982	0.7072	0.7192	0.7282
0.26	.74	.74	=0.5476	0.6371	0.6697	0.6867	0.6963	0.7089	0.7178
0.27	.73	.73	=0.5329	0.6241	0.6577	0.6752	0.6847	0.6978	0.7073
0.28	.72	.72	=0.5184	0.6112	0.6458	0.6638	0.6739	0.6868	0.6969
0.29	.71	.71	=0.5041	0.5985	0.6340	0.6517	0.6624	0.6759	0.6858
0.30	.70	.70	=0.49	0.5859	0.6223	0.6405	0.6517	0.6650	0.6755
0.31	.69	.69	=0.4761	0.5738	0.6099	0.6285	0.6403	0.6541	0.6679
0.32	.68	.68	=0.4624	0.561	0.5984	0.6174	0.6296	0.6432	0.6541
0.33	.67	.67	=0.4489	0.5487	0.5862	0.6056	0.6184	0.6324	0.6432
0.34	.66	.66	=0.4356	0.5365	0.5748	0.5946	0.6078	0.6217	0.6329
0.35	.65	.65	=0.4225	0.5239	0.5629	0.5830	0.5967	0.6110	0.6220
0.36	.64	.64	=0.4096	0.512	0.5516	0.5721	0.5856	0.6003	0.6118
0.37	.63	.63	=0.3969	0.4995	0.5399	0.5607	0.5745	0.5896	0.6010
0.38	.62	.62	=0.3844	0.4879	0.5288	0.5499	0.5635	0.5790	0.5908
0.39	.61	.61	=0.3721	0.4758	0.5172	0.5386	0.5526	0.5685	0.5801
0.40	.60	.60	=0.36	0.4644	0.5058	0.5280	0.5418	0.5580	0.5700
0.41	.59	.59	=0.3481	0.4525	0.4944	0.5174	0.531	0.5475	0.5593
0.42	.58	.58	=0.3364	0.4413	0.4837	0.5075	0.5202	0.5370	0.5492
0.43	.57	.57	=0.3249	0.4297	0.4725	0.4959	0.5090	0.5261	0.5386
0.44	.56	.56	=0.3136	0.4188	0.4614	0.4884	0.4984	0.5157	0.5286
0.45	.55	.55	=0.3025	0.4075	0.4504	0.4735	0.4878	0.5049	0.5181
0.46	.54	.54	=0.2916	0.3969	0.4395	0.4627	0.4773	0.4946	0.5076
0.47	.53	.53	=0.2809	0.3858	0.4287	0.4520	0.4664	0.4838	0.4971
0.48	.52	.52	=0.2704	0.3749	0.4180	0.4414	0.4560	0.4737	0.4872
0.49	.51	.51	=0.2601	0.3641	0.4080	0.4309	0.4447	0.4630	0.4768
0.50	.50	.50	=0.25	0.3535	0.3985	0.4205	0.4350	0.4530	0.4665
0.51	.49	.49	=0.2401	0.3430	0.3871	0.4096	0.4243	0.4424	0.4561

TABLE I—Continued

(1)	(2)		(3)	(4)	(5)	(6)	(7)	(8)	(9)
Loss in F	Computation made when C is damaged to the same degree as F, and when C is damaged to six different degrees less than F.								
	F	C	F=	$C^{1.2}F=$	$C^{1.3}F=$	$C^{1.4}F=$	$C^{1.5}F=$	$C^{1.7}F=$	$C^{1.10}F=$
0.52	.48	.48	=0.2304	0.3326	0.3758	0.3993	0.4142	0.4324	0.4459
0.53	.47	.47	=0.2209	0.3219	0.3651	0.3886	0.4037	0.4220	0.4356
0.54	.46	.46	=0.2116	0.3118	0.3551	0.3785	0.3937	0.4117	0.4255
0.55	.45	.45	=0.2025	0.3015	0.3447	0.3681	0.3834	0.4014	0.4153
0.56	.44	.44	=0.1936	0.2917	0.3348	0.3581	0.3735	0.3911	0.4052
0.57	.43	.43	=0.1849	0.2795	0.3225	0.3478	0.3633	0.3809	0.3951
0.58	.42	.42	=0.1764	0.2721	0.3145	0.3381	0.3532	0.3708	0.3851
0.59	.41	.41	=0.1681	0.2624	0.3046	0.3321	0.3431	0.3595	0.3747
0.60	.40	.40	=0.16	0.2528	0.2948	0.3180	0.3332	0.3504	0.3648
0.61	.39	.39	=0.1521	0.2433	0.2847	0.3081	0.3229	0.3408	0.3549
0.62	.38	.38	=0.1444	0.2340	0.2751	0.2983	0.3131	0.3309	0.3450
0.63	.37	.37	=0.1369	0.2249	0.2652	0.2886	0.3030	0.3207	0.3348
0.64	.36	.36	=0.1296	0.216	0.2559	0.2791	0.2934	0.3110	0.3250
0.65	.35	.35	=0.1225	0.2068	0.2481	0.2709	0.2835	0.3010	0.3150
0.66	.34	.34	=0.1156	0.1982	0.2373	0.2597	0.2740	0.2913	0.3053
0.67	.33	.33	=0.1089	0.1894	0.2280	0.2501	0.2643	0.2814	0.2953
0.68	.32	.32	=0.1024	0.1811	0.2188	0.2406	0.2547	0.2720	0.2854
0.69	.31	.31	=0.0961	0.1726	0.2095	0.2312	0.2452	0.2622	0.2755
0.70	.30	.30	=0.09	0.1644	0.2007	0.222	0.2358	0.2526	0.2658
0.71	.29	.29	=0.0841	0.1560	0.1902	0.2125	0.2262	0.2430	0.2560
0.72	.28	.28	=0.0784	0.1481	0.1831	0.2035	0.2170	0.2335	0.2464
0.73	.27	.27	=0.0729	0.1401	0.1744	0.1944	0.2076	0.2238	0.2367
0.74	.26	.26	=0.0676	0.1326	0.1658	0.1856	0.1986	0.2145	0.2272
0.75	.25	.25	=0.0625	0.1250	0.1572	0.1767	0.1895	0.2050	0.2175
0.76	.24	.24	=0.0576	0.1176	0.1490	0.1680	0.1804	0.1958	0.2080
0.77	.23	.23	=0.0529	0.1101	0.1407	0.1591	0.1713	0.1865	0.1984
0.78	.22	.22	=0.0484	0.1031	0.1328	0.1507	0.1625	0.1773	0.1889
0.79	.21	.21	=0.0441	0.0961	0.1247	0.1421	0.1537	0.168	0.1795
0.80	.20	.20	=0.04	0.0894	0.1170	0.1338	0.1450	0.1588	0.1702

TABLE 2

(1)	(2)	(3)	(4)	(5)	(6)	(7)	(8)	(9)	(10)
Loss in F	Computations made when C is damaged from 2 to 10 degrees more than F.								
	$C^2E=$	$C^3E=$	$C^4E=$	$C^5E=$	$C^6E=$	$C^7E=$	$C^8E=$	$C^9E=$	$C^{10}E=$
0.01	0.9702	0.9604	0.9507	0.9411	0.9316	0.9222	09129	0.9039	0.8948
0.02	0.9415	0.9222	0.9037	0.8856	0.8678	0.8504	0.8333	0.8166	0.8002
0.03	0.9126	0.8852	0.8586	0.8328	0.8078	0.7835	0.7599	0.7371	0.7149
0.04	0.8847	0.8493	0.8153	0.7826	0.7512	0.7211	0.6922	0.6645	0.6379
0.05	0.8573	0.8144	0.7736	0.7349	0.6981	0.6631	0.6299	0.5984	0.5684
0.06	0.8305	0.7806	0.7337	0.6896	0.6482	0.6093	0.5727	0.5383	0.5060
0.07	0.8043	0.7479	0.6955	0.6468	0.6015	0.5593	0.5251	0.4883	0.4541
0.08	0.7786	0.7163	0.6589	0.6061	0.5515	0.5073	0.4667	0.4293	0.3949
0.09	0.7535	0.6856	0.6238	0.5676	0.5165	0.4700	0.4277	0.3692	0.3359
0.10	0.729	0.6561	0.5904	0.5313	0.4781	0.4302	0.3871	0.3483	0.3133
0.11	0.7049	0.6273	0.5582	0.4967	0.4420	0.3933	0.3500	0.3115	0.2772
0.12	0.6814	0.5996	0.5276	0.4642	0.4084	0.3593	0.3161	0.2781	0.2447
0.13	0.6583	0.5727	0.4982	0.4334	0.3770	0.3279	0.2852	0.2481	0.2158
0.14	0.6360	0.5469	0.4703	0.4044	0.3477	0.293	0.2519	0.2166	0.1862
0.15	0.6141	0.5219	0.4436	0.377	0.3204	0.2723	0.2314	0.1966	0.1671
0.16	0.5927	0.4978	0.4181	0.3512	0.295	0.2478	0.2081	0.1748	0.1467
0.17	0.5717	0.4745	0.3938	0.3268	0.2712	0.225	0.1887	0.1566	0.1299
0.18	0.5513	0.4520	0.3706	0.3038	0.2491	0.2042	0.1674	0.1372	0.1125
0.19	0.5314	0.4304	0.3486	0.2823	0.2286	0.1851	0.1499	0.1214	0.0983
0.20	0.512	0.4096	0.3276	0.2620	0.2096	0.1676	0.134	0.1072	0.0859
0.21	0.4930	0.3894	0.3076	0.2430	0.1919	0.1516	0.1197	0.0945	0.0746
0.22	0.4745	0.3701	0.2886	0.2251	0.1755	0.1368	0.1067	0.0832	0.0648
0.23	0.4565	0.3515	0.2706	0.2083	0.1603	0.1234	0.095	0.0731	0.0562
0.24	0.4389	0.3335	0.2534	0.1925	0.1463	0.1111	0.0844	0.0641	0.0487
0.25	0.4218	0.3163	0.2372	0.1779	0.1334	0.1000	0.075	0.0562	0.0421
0.26	0.4052	0.2998	0.2218	0.1641	0.1214	0.0898	0.0664	0.0491	0.0363
0.27	0.3890	0.2839	0.2072	0.1512	0.1103	0.0805	0.0587	0.0428	0.0312
0.28	0.3732	0.2687	0.1934	0.1392	0.1002	0.0721	0.0519	0.0373	0.0268
0.29	0.3579	0.2541	0.1804	0.1280	0.0908	0.0644	0.0457	0.0324	0.023
0.30	0.343	0.2401	0.168	0.1176	0.0823	0.0576	0.0403	0.0282	0.0197
0.31	0.3285	0.2266	0.1563	0.1078	0.0743	0.0512	0.0353	0.0243	0.0167
0 32	0.3144	0.2137	0.1453	0.0988	0.0671	0.0456	0.031	0.0210	0.0142
0.33	0.3007	0.2014	0.1349	0.0903	0.0605	0.0405	0.0271	0.0181	0.0121
0.34	0.2874	0.1896	0.1251	0.0825	0.0544	0.0359	0.0236	0.0155	0.0102
0.35	0.2746	0.1784	0.1159	0.0753	0.0489	0.0317	0.0206	0.0133	0.0086
0.36	0.2621	0.1679	0.1073	0.0686	0.0439	0.028	0.0179	0.0114	0.0072
0.37	0.2500	0.1575	0.0992	0.0624	0.0393	0.0247	0.0155	0.0097	0.0061
0.38	0.2383	0.1477	0.0915	0.0567	0.0351	0.0217	0.0134	0.0083	0.0051
0.39	0.2269	0.1384	0.0844	0.0514	0.0313	0.019	0.0115	0.007	0.0042
0.40	0.216	0.1296	0.0777	0.0466	0.0279	0.0167	0.01	0.006	0.0036
0.41	0.2053	0.1211	0.0714	0.0421	0.0248	0.0146	0.0086	0.005	0.0029
0.42	0.1951	0.1131	0.0655	0.0379	0.0219	0.0127	0.0073	0.0042	0.0024
0.43	0.1851	0.1055	0.0601	0.0342	0.0194	0.011	0.0062	0.0035	0.0019
0.44	0.1756	0.0983	0.055	0.0308	0.0172	0.0096	0.0053	0.0029	0.0016
0.45	0.1663	0.0914	0.0502	0.0275	0.0151	0.0083	0.0045	0.0026	0.0014
0.46	0.1574	0.0849	0.0458	0.0247	0.0133	0.0071	0.0038	0.002	0.001
0.47	0.1488	0.0788	0.0417	0.0221	0.0117	0.0062	0.0032	0.0016	0.0008
0.48	0.1406	0.0731	0.038	0.0197	0.0102	0.0053	0.0027	0.0014	0.0007
0.49	0.1326	0.0676	0.0344	0.0175	0.0089	0.0045	0.0022	0.0011	0.0005
0.50	0.1250	0.0625	0.0312	0.0156	0.0078	0.0039	0.0019	0.0009	0.0004
0.51	0.1176	0.0576	0.0282	0.0138	0.0067	0.0032	0.0015	0.0007	0.0003
0.52	0.1105	0.0530	0.0254	0.0121	0.0058	0.0027	0.0012	0.0005	0.0002
0.53	0.1038	0.0487	0.0228	0.0107	0.0050	0.0023	0.0010	0.0004	0.0001

TABLE 2—Continued

(1)	(2)	(3)	(4)	(5)	(6)	(7)	(8)	(9)	(10)
Loss in F	Computations made when C is damaged from 2 to 10 degrees more than F.								
	$C^2 E=$	$C^3 E=$	$C^4 E=$	$C^5 E=$	$C^6 E=$	$C^7 E=$	$C^8 E=$	$C^9 E=$	$C^{10} E=$
0.54	0.0973	0.0447	0.0205	0.0094	0.0043	0.0019	0.0008	0.0003	0.0001
0.55	0.0911	0.0409	0.0184	0.0082	0.0036	0.0016	0.0007	0.0003	0.0001
0.56	0.0851	0.0374	0.0164	0.0072	0.0031	0.0013	0.0005	0.0002	0.0000
0.57	0.0795	0.0341	0.0146	0.0062	0.0026	0.0011	0.0004	0.0001	
0.58	0.0740	0.0310	0.013	0.0054	0.0022	0.0009	0.0003	0.0001	
0.59	0.0689	0.0282	0.0115	0.0047	0.0019	0.0007	0.0002	0.0000	
0.60	0.064	0.0256	0.0102	0.004	0.0016	0.0006	0.0002		
0.61	0.0593	0.0231	0.009	0.0035	0.0013	0.0005	0.0001		
0.62	0.0548	0.0208	0.0079	0.0030	0.0011	0.0004	0.0001		
0.63	0.0506	0.0187	0.0069	0.0025	0.0009	0.0003	0.0001		
0.64	0.0466	0.0167	0.006	0.0021	0.0007	0.0002	0.0000		
0.65	0.0428	0.0149	0.0052	0.0018	0.0006	0.0001			
0.66	0.0393	0.0133	0.0045	0.0015	0.0005	0.0001			
0.67	0.0359	0.0118	0.0038	0.0012	0.0003	0.0000			
0.68	0.0327	0.0104	0.0033	0.0010	0.0003				
0.69	0.0297	0.0092	0.0028	0.0008	0.0002				
0.70	0.027	0.0081	0.0024	0.0007	0.0002				
0.71	0.0243	0.007	0.002	0.0005	0.0001				
0.72	0.0219	0.0061	0.0017	0.0004	0.0001				
0.73	0.0196	0.0052	0.0014	0.0003	0.0000				
0.74	0.0175	0.0045	0.0011	0.0002					
0.75	0.0156	0.0039	0.0009	0.0002					
0.76	0.0138	0.0032	0.0007	0.0001					
0.77	0.0121	0.0027	0.0005	0.0001					
0.78	0.0106	0.0023	0.0005	0.0001					
0.79	0.0092	0.0019	0.0003	0.0000					
0.80	0.008	0.0016	0.0003						

TABLE 3

(1)	(2)	(3)	(4)	(5)	(6)	(7)	(8)
Loss in F	Loss on $1,000, when C is damaged to the same degree as F, and when C is damaged to six different degrees less than F.						
	C^1	C^{1-2}	C^{1-3}	C^{1-4}	C^{1-5}	C^{1-7}	C^{1-10}
0.01	$ 19.90	$ 15.00	$ 13.50	$ 12.50	$ 12.00	$ 11.60	$ 11.00
0.02	39.60	29.80	26.90	24.90	24.00	23.00	22.00
0.03	59.10	44.60	40.70	37.80	35.90	34.90	33.00
0.04	70.40	59.20	53.50	49.60	47.70	45.80	43.90
0.05	97.50	73.80	66.20	62.40	59.50	57.60	54.80
0.06	116.40	88.20	79.80	74.10	72.30	68.50	65.70
0.07	135.10	103.50	93.30	86.80	84.90	80.30	76.60
0.08	153.60	117.80	105.80	99.40	95.70	91.10	87.40
0.09	171.90	131.90	110.20	111.90	107.30	102.80	99.90
0.10	190.00	145.90	131.50	123.40	118.90	113.50	109.90
0.11	207.90	160.80	144.80	135.90	130.50	125.50	121.60
0.12	225.60	174.60	157.00	147.30	142.00	135.90	131.50
0.13	243.10	189.20	169.20	159.60	154.40	147.40	142.20
0.14	260.40	202.80	181.30	171.00	165.80	158.10	152.90
0.15	277.50	217.20	194.20	184.00	177.20	169.60	165.30
0.16	294.40	230.60	207.40	195.30	188.60	181.00	174.30
0.17	311.10	243.90	219.80	211.50	200.80	192.50	185.80
0.18	327.60	257.10	232.50	219.40	212.00	203.00	196.40
0.19	343.90	271.00	245.10	231.40	224.10	214.30	207.10
0.20	360.00	284.80	257.60	243.20	235.20	224.80	217.60
0.21	375.90	308.50	270.10	255.10	247.20	236.10	229.00
0.22	391.60	311.30	281.70	266.80	258.30	247.30	239.50
0.23	407.10	324.80	294.00	278.60	270.10	258.50	250.10
0.24	422.40	347.30	306.20	290.20	281.10	269.70	260.60
0.25	437.50	350.50	318.30	301.80	292.80	280.80	271.80
0.26	452.40	362.90	330.30	312.30	303.70	291.10	282.20
0.27	467.10	375.90	342.30	324.80	315.30	302.20	292.70
0.28	481.60	388.80	354.20	336.20	326.10	313.20	303.10
0.29	495.90	401.50	366.00	348.30	337.60	324.10	313.50
0.30	510.00	414.10	377.70	359.50	348.30	335.00	324.50
0.31	523.90	426.70	390.10	371.50	359.70	345.90	334.90
0.32	537.60	439.00	401.60	382.60	370.40	356.80	345.90
0.33	551.10	451.30	413.80	394.40	381.60	367.60	356.80
0.34	564.40	463.50	425.20	405.40	392.20	378.30	367.10
0.35	577.50	476.10	437.10	417.00	403.30	389.00	378.00
0.36	590.40	488.00	448.40	427.90	414.40	397.70	388.20
0.37	603.10	500.50	460.10	439.30	425.50	410.40	399.00
0.38	615.60	512.10	471.20	450.10	436.50	421.00	409.20
0.39	627.90	524.20	482.80	461.40	447.40	431.50	419.90
0.40	640.00	535.60	494.20	472.00	458.20	442.00	430.00
0.41	651.90	547.50	505.60	482.60	469.00	452.50	440.70
0.42	663.60	558.70	516.30	492.50	478.80	463.00	450.80
0.43	675.10	570.30	527.50	504.10	491.00	473.90	461.40
0.44	686.40	581.20	538.60	511.60	501.60	484.30	471.40
0.45	697.50	592.50	549.60	526.50	512.20	495.10	481.90
0.46	708.40	603.10	560.50	537.30	522.70	505.40	492.40
0.47	719.10	614.20	571.30	548.00	533.60	516.20	502.90
0.48	729.60	625.10	582.00	558.00	544.00	526.30	512.80
0.49	739.90	635.90	592.00	569.10	555.30	537.00	523.20
0.50	750.00	646.50	601.50	579.50	565.00	547.00	533.50
0.51	759.60	657.00	612.90	590.40	575.70	557.60	543.90

TABLE 3—Continued

(1)	(2)	(3)	(4)	(5)	(6)	(7)	(8)
Loss in F	Loss on $1,000, when C is damaged to the same degree as F, and when C is damaged to six different degrees less than F.						
	C^{1}	$C^{1.2}$	$C^{1.3}$	$C^{1.4}$	$C^{1.5}$	$C^{1.7}$	$C^{1.10}$
0.52	769.60	667.40	624.20	600.70	585.80	567.60	554.10
0.53	779.10	678.10	634.90	611.40	596.30	578.00	564.40
0.54	788.40	688.20	644.90	621.50	606.40	588.30	574.50
0.55	795.50	698.50	655.30	631.90	616.60	598.60	584.70
0.56	806.40	708.30	665.20	641.90	626.50	608.90	594.80
0.57	815.10	720.50	677.50	652.20	637.70	619.10	604.90
0.58	823.50	727.90	685.50	661.90	646.80	629.20	614.90
0.59	831.90	737.60	695.40	667.90	656.90	640.90	625.30
0.60	840.00	747.20	705.20	682.00	666.80	649.20	635.20
0.61	847.10	756.70	715.30	691.90	677.10	659.20	645.10
0.62	855.60	766.00	724.90	701.70	686.90	669.10	655.00
0.63	863.10	775.10	734.80	711.40	697.00	679.30	665.20
0.64	870.40	784.00	744.10	720.90	706.60	689.00	675.00
0.65	877.50	793.20	751.90	729.10	716.50	699.00	685.00
0.66	884.40	801.80	762.70	740.30	726.00	708.70	694.70
0.67	891.10	810.60	772.00	749.90	735.70	718.60	704.70
0.68	897.60	818.90	781.20	759.40	745.30	728.00	714.60
0.69	903.90	827.40	790.50	768.80	754.80	737.80	724.50
0.70	910.00	835.60	799.30	778.00	764.20	747.40	734.20
0.71	915.90	844.00	809.80	787.50	773.80	757.00	744.00
0.72	962.60	851.90	816.90	796.50	783.00	766.50	753.60
0.73	927.10	858.90	825.60	805.60	792.40	776.20	763.30
0.74	932.40	867.40	834.20	814.40	801.40	785.50	772.80
0.75	937.50	875.00	842.80	823.30	810.50	795.00	782,50
0.76	942.40	882.40	851.00	832.00	819.60	804.20	792.00
0.77	947.10	889.90	859.30	840.90	828.70	813.50	801.60
0.78	951.50	896.90	867.20	849.30	837.50	822.70	811.10
0.79	955.10	903.90	875.30	857.90	846.30	832.00	820.50
0.80	960.00	910.60	883.00	866.20	855.00	841.20	829.80

TABLE 4

(1)	(2)	(3)	(4)	(5)	(6)	(7)	(8)	(9)	(10)
Loss in F	Loss on $1.000 when C is damaged from 2 to 10 degrees more than F								
	C^2	C^3	C^4	C^5	C^6	C^7	C^8	C^9	C^{10}
0.01	$ 29.80	$ 39.60	$ 49.30	$ 58.90	$ 68.40	$ 77.80	$ 87.10	$ 96.10	$106.20
0.02	58.50	97.80	96.30	114.40	132.20	149.60	166.70	183.40	199.80
0.03	87.40	114.80	141.40	167.20	192.20	216.50	240.10	262.90	285.10
0.04	115.30	150.70	184.70	217.40	248.80	278.90	307.80	335.50	362.10
0.05	142.70	185.60	226.40	265.10	301.90	336.90	370.10	401.60	431.60
0.06	169.50	219.40	266.30	310.40	351.80	390.70	427.30	461.70	494.00
0.07	195.70	252.10	304.50	353.20	398.50	440.70	474.90	511.70	545.90
0.08	221.40	283.70	341.10	393.90	448.50	492.70	533.30	570.70	605.10
0.09	246.50	314.40	376.20	432.40	483.50	530.00	572.30	630.80	664.10
0.10	271.00	343.90	409.60	468.70	521.90	569.80	612.90	651.70	686.70
0.11	295.10	372.70	441.80	503.80	558.00	606.70	650.00	688.50	722.80
0.12	318.60	400.40	472.40	535.80	591.60	640.70	683.90	721.90	755.30
0.13	341.70	427.30	501.80	566.60	623.00	672.10	714.80	751.90	784.20
0.14	364.00	453.10	529.70	595.60	652.30	707.00	748.10	783.40	813.80
0.15	385.90	478.10	556.40	623.00	679.60	727.70	768.60	803.40	832.90
0.16	407.30	502.20	581.90	648.80	705.00	752.20	791.90	825.20	853.30
0.17	428.30	525.50	606.20	673.20	728.80	775.00	811.30	843.40	870.10
0.18	448.70	548.00	629.40	696.20	750.90	795.80	832.60	862.80	887.50
0.19	468.60	569.60	651.40	717.70	771.40	814.90	850.10	878.60	901.70
0.20	488.00	590.40	672.40	738.00	790.40	832.40	866.00	892.80	914.10
0.21	507.00	610.60	692.40	757.00	808.10	848.40	880.30	905.50	925.40
0.22	525.50	629.90	711.40	774.90	824.50	863.20	893.30	916.80	935.20
0.23	543.50	648.50	729.40	791.70	839.70	876.60	905.00	926.90	943.80
0.24	561.10	666.50	746.60	807.50	853.70	888.90	915.60	935.90	951.30
0.25	578.20	683.70	762.80	822.10	866.60	900.00	925.00	943.80	959.90
0.26	594.80	700.20	778.20	835.90	878.60	910.20	933.60	950.90	963.70
0.27	611.00	716.10	792.80	848.80	889.70	919.50	941.30	957.20	968.80
0.28	626.80	731.30	806.60	860.80	899.80	927.90	948.10	962.70	973.20
0.29	642.10	745.90	819.60	872.00	909.20	935.60	954.30	967.60	977.00
0.30	657.00	759.90	832.00	882.40	917.70	942.40	959.70	971.80	980.30
0.31	671.50	773.40	843.70	892.20	925.70	948.80	964.70	975.70	983.30
0.32	685.60	786.30	854.70	901.20	932.90	954.40	969.00	979.00	985.80
0.33	699.30	798.60	865.10	907.70	939.50	959.50	972.90	981.90	987.90
0.34	712.60	810.40	874.90	917.50	945.60	964.10	976.40	984.50	989.80
0.35	725.40	821.60	884.10	924.70	951.10	968.30	979.40	986.70	991.40
0.36	737.90	832.10	892.70	931.40	956.10	972.00	982.10	988.60	992.80
0.37	750.00	842.50	900.80	937.60	960.70	975.30	984.50	990.30	993.90
0.38	761.70	852.30	908.50	943.30	964.90	978.30	986.60	991.70	994.90
0.39	773.10	861.60	915.60	948.60	968.70	981.00	988.50	993.00	995.80
0.40	784.00	870.40	922.30	953.40	972.10	983.30	990.00	994.00	996.40
0.41	794.70	878.90	928.60	957.90	975.20	985.40	991.40	995.00	997.10
0.42	804.90	886.90	934.50	962.10	978.10	987.30	992.70	995.80	997.60
0.43	814.90	894.50	939.90	965.80	980.60	989.00	993.80	996.50	998.10
0.44	824.40	901.70	945.00	969.20	982.80	990.40	994.70	997.10	998.40
0.45	833.70	908.60	949.80	972.50	984.90	991.70	995.50	997.40	998.60
0.46	824.60	915.10	954.20	975.30	986.70	992.90	996.20	998.00	999.00
0.47	851.20	921.20	958.30	979.90	988.30	993.80	996.80	998.40	999.20
0.48	859.40	926.90	962.00	980.30	989.80	994.70	997.30	998.60	999.30
0.49	867.40	932.40	965.60	982.50	991.10	995.50	997.80	998.90	999.50
0.50	875.00	937.50	968.80	984.40	992.20	996.10	998.10	999.10	999.60
0.51	882.40	942.40	971.80	986.20	993.30	996.80	998.50	999.30	999.70
0.52	889.50	947.00	974.60	987.90	994.20	997.30	998.80	999.50	999.80
0.53	896.20	951.30	977.20	989.30	995.00	997.70	999.00	999.60	999.90

TABLE 4—Continued

(1)	(2)	(3)	(4)	(5)	(6)	(7)	(8)	(9)	(10)
Loss in F	Loss on $1.000 when C is damaged from 2 to 10 degrees more than F								
	C^2	C^3	C^4	C^5	C^6	C^7	C^8	C^9	C^{10}
0.54	902.70	955.30	979.50	990.60	995.70	998.10	999.20	999.70	999.90
0.55	908.90	959.10	981.60	991.80	996.40	998.40	999.30	999.70	999.90
0.56	914.90	962.60	983.60	992.80	996.90	998.70	999.50	999.80	1000.00
0.57	920.50	965.90	985.40	993.80	997.40	998.90	999.60	999.90	
0.58	926.00	969.00	987.00	994.60	997.80	999.10	999.70	999.90	
0.59	931.10	971.80	988.50	995.30	998.10	999.30	999.80	1000.00	
0.60	936.00	974.40	989.80	996.00	998.40	999.40	999.80		
0.61	940.70	976.90	991.00	996.50	998.70	999.50	999.90		
0.62	945.20	979.20	992.10	997.00	998.90	999.60	999.90		
0.63	949.40	981.30	993.10	997.50	999.10	999.70	999.90		
0.64	953.40	983.30	994.00	997.90	999.30	999.80	1000.00		
0.65	957.20	985.10	994.80	998.20	999.40	999.90			
0.66	960.70	986.70	995.50	998.50	999.50	999.90			
0.67	964.10	988.20	996.20	998.80	999.70	1000.00			
0.68	967.30	989.60	996.70	999.00	999.70				
0.69	970.30	990.80	997.20	999.20	999.80				
0.70	973.00	991.90	997.60	999.30	999.80				
0.71	975.70	993.00	998.00	999.50	999.90				
0.72	978.10	993.90	998.30	999.60	1000.00				
0.73	980.40	994.80	998.60	999.70					
0.74	982.50	995.50	998.90	999.80					
0.75	984.40	996.10	999.10	999.80					
0.76	986.20	996.70	999.30	999.90					
0.77	987.90	997.30	999.50	1000.00					
0.78	989.40	997.70	999.50						
0.79	990.80	998.10	999.70						
0.80	992.00	998.40	999.70						

TABLE 5

Standard of Measurement for determining Damages to F (a) of the body.

Loss in F (a) in anchylosis of Fingers,		Toes,		Loss in F (a) in amputation of Fingers,		Toes,	
Little,	0.01	Little,	0.005	Little,	0.01	Little,	0.005
Ring,	0.02	Fourth,	0.005	Ring,	0.02	Fourth,	0.005
Middle,	0.02	Middle,	0.005	Middle,	0.03	Middle,	0.01
Index,	0.02	Second,	0.005	Index,	0.04	Second,	0.01
Thumb,	0.03	Big,	0.01	Thumb,	0.05	Big	0.02
Wrist,	0.10	Ankle,	0.10	Hand,	0.20	Foot,	0.20
Elbow,	0.15	Knee,	0.15	Fore Arm,	0.25	Leg,	0.25
Shoulder,	0.15	Hip,	0.15	Arm,	0.30	Thigh,	0.30

No. 6—EVOM TABLE

Based on the premises that F T C=E and that the gross economic value of man is the present value of all his earnings for a prospective working life, and that the net economic value of a man is the present value of all his earnings less the present value of all his personal expenses for his prospective life.

The money values here given may be used either for the gross, or the net, economic value of man, depending upon whether $1 per day is the gross, or the net, income per day for three hundred days of the year, namely $300 per year, for a prospective working life.

This table is computed on a 3½ per cent. discount basis.

At the age of	Money value	Annual increase	Percentage of increase in 5 yrs.	No. living at	No. deaths in 5 yrs.	Per. of death in 5 yrs.
Birth	133.29			513		
5	1388.44	251.03	911.31	372	141	27.48
10	2900.98	302.50	108.94	355	17	4.57
15	4754.26	370.65	63.88	346	9	2.53
20	5797.72	208.69	24.05	335	11	3.17
25	6114.51	63.35	5.46	321	14	4.17
	Decrease	Decrease	Decrease			
30	5985.71	25.76	2.10	307	14	4.36
35	5664.43	64.25	5.36	291	16	5.21
40	5262.30	80 43	7.13	275	16	5.49
45	4784.29	95.62	9.08	257	18	6.54
50	4178.96	121.04	10.57	237	20	7.78
55	3420.67	151.68	18.14	215	22	9.28
60	2413.00	201.52	29.45	189	26	12.09
65	1141.72	254.25	52.68	156	33	17.46
70	19.10	224.73	98.33	118	38	24.35
75	—609.32	125,68	3293.50	79	39	33.05
80	—1017.88	81.71	67.05	44	35	44.30

(Copyright 1909.)

Spontaneous rupture of the eyeball.

SPONTANEOUS RUPTURE OF THE EYEBALL. REPORT OF A CASE.

JAMES W. INGALLS, M.D.,

Brooklyn, N. Y.

On May 17, 1908, the writer was asked to visit a woman suffering from severe pain in the right eye. In about half an hour a message was sent saying that the eye had burst and blood was running down the cheek. On my arrival, a short time later, blood was oozing from the eyeball. Examination showed a confused mass of clots and prolapsed iris protruding from the lower segment of the cornea. The mass was estimated to be 10 or 12 mm. in diameter.

The following history was obtained: Mrs. C. E., aged eighty-nine. For the past ten years patient has suffered more or less from gout. Four years ago the sight in right eye began to fail, and gradually grew worse, so that in the course of two years it was nearly blind. Patient then went to an optician, who sold her a pair of glasses "to relieve the strain," as he said. In a few months the affected eye became entirely blind. Left eye was apparently normal.

About an hour before rupture, pain was intense. So far as could be learned there had not been any abnormal appearance of the eye, except a dilatation of the pupil or "spreading of the sight," as the friends expressed it. In all probability this was a case of chronic glaucoma.

After rupture, patient suffered from shock, but did not complain of pain in the eye. On May 23d, Dr. Jonathan S. Prout saw the case with me in consultation. A few days later, patient was attacked with a severe diarrhea, which caused her death on June 1, 1908. The relatives then allowed me to remove the

eyeball. The report of the pathologist, Dr. E. L. Oatman, is as follows:

Pathological Examination.—The eyeball is slightly collapsed. Projecting from the anterior surface of the cornea is a black, lobulated mass of prolapsed uveal tissue, etc., measuring about 10 mm. in diameter. The base of the prolapse is constricted to pass through a perforation in the cornea 4 mm. in diameter. The eye has been the seat of extensive subchoroidal hemorrhage which has produced total detachment of the choroid, retina, and ciliary body, with consequent displacement of lens and iris. These structures are massed along the polar axis of the eye and contribute to the prolapse described above. The scleral cavity is filled with an old blood-clot. The prolapse consists of degenerated uveal elements, lens capsule, detritus, and disorganized blood. Its external surface is covered with a thin layer of fibrous connective tissue, but not with epithelium. The margin of the corneal perforation is smooth and the tissues are condensed. Descemet's membrane extends to the opening and for a short distance along its course. Degenerative and proliferative changes in the retina, optic nerve-head, and uveal tract which have resulted from the detachment render it impossible to state their condition previous to the hemorrhage.

Diagnosis.—Choroidal hemorrhage and spontaneous perforation of cornea in chronic glaucoma.

So far as can be learned, only five cases of spontaneous rupture of the eyeball have been reported in ophthalmic literature. They are as follows:

Case I. Female, aged sixty-eight. Chronic glaucoma. Reported by Dr. B. L. Millikin in Transactions of the American Ophthalmological Society, 1899.

Case II. Female, aged twenty-eight. Reported by Hauenschild, of Würzburg, Ophthalmic Review, Jan., 1901.

Case III. Female, aged seventy-one. Chronic glaucoma. Reported by Terson, Ophthalmic Review, Feb., 1902.

Case IV. Female, aged eighty-seven. Reported by Dr. W. Whitehead Gilfillan, Medical News, Jan. 25, 1902.

Case V. Reported by Dr. James Moores Ball, "Modern Ophthalmology," page 418.

DISCUSSION.

DR. GEO. F. LIBBY, Denver: Last winter before the Colorado Ophthalmological Society a case was shown by Dr. W. M. Carling, which you may have seen reported, but as the final report has not been published, I think I may briefly mention it. A woman twenty-four years of age had recently experienced a spontaneous rupture of the eyeball. In our Society the case was discussed at great length, opinion being divided upon the question of whether it was due to glaucoma or scleritis. Later, however, a typical gumma developed at the seat of perforation. This gummatous growth disappeared under anti-syphilitic treatment.

DR. F. H. VERHOEFF, Boston: From the number of cases I have seen of eyes enucleated for expulsive hemorrhage I should say that it is not so extremely uncommon for rupture of the cornea to take place in these old glaucomatous eyes, but there is usually first ulceration of the cornea. Perforation does not take place until some time afterward. The remarkable feature of this case is that rupture took place while the cornea was perfectly normal.

As I pointed out several years ago, it is important to examine such eyes very carefully to exclude the presence of choroidal sarcoma. A sarcoma, although comparatively small, may undergo necrosis and give rise to an expulsive hemorrhage. In such a case the tumor may be difficult to distinguish from the mass of blood filling the globe.

DR. W. K. BUTLER, Washington: I was surprised some time ago to find that this condition of rupture of the eyeball was so rare. I saw a case occurring in an elderly person living in the country that was due to an old glaucoma. The eye ruptured from a large intraocular hemorrhage.

DR. WM. M. SWEET, Philadelphia: I have seen one instance of spontaneous rupture of the globe in a blind glaucomatous eyeball. The man, aged seventy-five, gave a history of a sudden loss of sight in the right eye three years previously, which was associated with severe pain in the head and with vomiting, the attack occurring while he was eating dinner. The inflammation gradually subsided, and the eye did not give him any further trouble, but there was no return of vision. Two days before

coming under observation the eye became watery, and the following day, about twelve hours before I saw him, there was a severe hemorrhage from the eyeball, which the attending physician stopped by means of a pressure bandage. There was severe pain at the time, but it ceased with the appearance of the hemorrhage. At my first examination there was a horizontal, somewhat irregular opening in the cornea, extending from the upper outer limbus slightly downward for a distance of 6 mm. There was no evidence of ulceration at the point of rupture and the remainder of the cornea appeared healthy. A large clot, which protruded through the opening, was cut off, a pressure bandage applied, and the man put to bed. He refused to have the eyeball removed. He remained in the hospital for four days, there was no recurrence of the hemorrhage, and several months later the corneal wound had cicatrized, but the ball was slightly atrophic.

The case is similar to others that have been reported, the hemorrhage occurring in an eye blind from glaucoma. It was impossible to find any ulceration of the cornea at the point of rupture, but Coppez, in reporting a case, believed that the corneal changes may be so circumscribed that the ulcerated part may be carried away in the blood-clot. The lacrimation which existed for twenty-four hours preceding the rupture may have been due to some corneal disease. Villard reports two cases in which the rupture was preceded by ulceration of the cornea.

DR. HIRAM WOODS, Baltimore: In reference to intraocular tumors as a cause of scleral rupture, referred to by Dr. Verhoeff, I saw a woman five or six years ago with choroidal sarcoma in the outer fundus of the left eye. She was urged to submit to enucleation, but declined. She attended the hospital irregularly, then disappeared, and came back later with history of sudden severe pain the previous night. There had been a rupture of the sclera about 2 or 3 mm. behind the limbus. Even then enucleation was declined. When last seen, the patient presented a large mass in the orbit. I mention the case in connection with Dr. Verhoeff's remarks.

ADENOCARCINOMA OF THE PITUITARY BODY. REPORT OF A CASE UNDER OBSERVATION FOR FOUR AND A HALF YEARS. PATHOLOGICAL EXAMINATION.

WILLIAM T. SHOEMAKER, M.D.,

Philadelphia.

Tumors of the hypophysis are not uncommon, a great number of them having been accurately recorded by different observers. The case here reviewed was under constant observation for four and a half years, and upon first examination the diagnosis of tumor of the optic chiasm pushing down into the left orbit was made, and concurred in by Dr. Wm. G. Spiller, who saw the case in consultation several times.

I am indebted to Dr. George P. Müller for the most careful autopsy and examination and preparation of the specimens, and to Dr. Alfred Reginald Allen for the microscopic examination and interesting report herewith contained.

Most of the reported tumors which have come to pathological examination were sarcomas, a number were adenomas, and a few were carcinomas or adenocarcinomas. They are always of interest, not only *per se* as are all intracranial tumors, but also in their relation to and bearing upon acromegaly; and, furthermore, on account of any disclosures which they might make relative to the function of the pituitary body. Whatever these disclosures might have been, however, the exact use and function of the pituitary body and its relation to acromegaly are still in question. For example, Thom* points out that enlargement of the pituitary is by no means constant in acromegaly; and Kollaritis,† while reporting two cases of his own of

* Archiv. f. microscop. Anat., 1901.

† Deutsche Zeitschrift für Nervenheilkunde, 1904.

tumor of the hypophysis without acromegaly, tabulates fifty-two other cases without acromegaly. He rather regards tumor as one of the symptoms and not the cause of acromegaly.

The anatomical situation of the hypophysis, at the base of the brain in the median line forward, is such as to give in case of tumor or enlargement a fairly constant and quite characteristic symptomatology, so that diagnosis, in so far as location is concerned, is comparatively easy.

Headache, very frequently occipital, would seem to be a part of almost if not every case. Vertigo, generally present at times during the course of the disease, is less intense than in cerebellar tumors. Nausea and vomiting are quite variable in their onset, persistence, and intensity. The intellectual faculties may remain intact throughout, or may suffer deterioration. Schuster* found mental disturbances in 66% of hypophyseal tumors; more, he says, than found in tumors of any other region except in tumors of the frontal lobe and corpus callosum.

Among the mental disturbances noted in case records are, hallucinations, insomnia, hebetude, disorientation, delusions of persecution, drowsiness, and somnolence. Drowsiness has been especially commented upon by Dr. Hansell, who reported a case of pituitary tumor before this Society in 1906; the patient for twenty-two days slept twenty-two hours out of each day. Hansell regards this symptom as having some diagnostic value.

Glycosuria is a frequent complication, and obesity has been observed in some cases. Interference, sooner or later, with one or more of the cranial nerves would seem to be an absolute necessity with any progressive growth or enlargement of the hypophysis. Escape for the optic chiasm is infrequent, although the observations of Zander upon the "*Position and Dimensions of the Chiasm, and their Significance in the Diagnosis of Hypophyseal Tumors*," are extremely interesting and worthy of attention.

*Quoted from Barrett, Journal of Nervous and Mental Diseases, p. 531, 1905.

Zander* found great variation in the anatomical situation of the optic chiasm, and declared the generally accepted and taught view that it occupied the so-called sulcus chiasmatis to be incorrect. The posterior margin of the chiasm generally overreaches the upper edge of the dorsum of the sella turcica. The hypophysis cannot, according to Zander, lie behind the chiasm, but lies much more frequently in front of it. Furthermore, in 60% of cases the chiasm is displaced markedly to the right or left.

Enlargement of the hypophysis, he says, in a vertical direction must reach at least 0.5 cm. before the chiasm would be pressed upon. In these variations of anatomical position, Zander finds an explanation for the relatively large number of cases of acromegaly with hypophyseal tumor without temporal hemianopsia. Fawcet and Lawrence also found that the chiasm did not occupy the sulcus, but lay behind it.

The symptoms referable to involvement of the optic chiasm, optic tracts, or optic nerves are, however, very variable. Often enough we have bitemporal hemianopsia, unilateral, and, finally, double blindness with optic atrophy. Such a course might be considered classic, but as variations we have to note optic atrophy, without hemianopsia, the presence of scotomas, partial contraction of the visual field preceding probably the development of a bitemporal defect, contraction for color only, and paracentral as well as hemianopic scotomas.

These conditions were discussed by de Schweinitz in connection with Hansell's case. Choked disc is said to be uncommon. Rath,† in an analysis of 38 cases of hypophyseal tumor from the literature, found it noted but five times. The relative frequency of choked disc in tumor of the hypophysis, as compared to tumors of the brain in other localities, may be judged from Kamperstein's statistics. In 76 cases of brain

* Quoted from Wilbrand and Saenger, iii, 119.

† Archiv. f. Ophthal., Bd. 34, 1888.

tumor with choked disc the tumor was of the hypophysis three times.

The other localities for the tumor accompanied with choked disc were as follows: Cerebellum, twenty-three times; frontal lobe, twelve times; corpora quadrigemina, seven times; temporal lobe, six times; occipital lobe, five times; parietal convolution, four times; corpus callosum, three times; optic thalamus, twice; third ventricle, twice; peduncle of the cerebellum, twice; fourth ventricle, once.

Optic atrophy more or less complete, on the other hand, has been noted in most of the cases studied. So frequent is it that Hansell considers it "not improbable that some of the cases of so-called idiopathic optic atrophy, so often unexplainable, are cases of tumor of the pituitary body, for such tumors may exist for a long time without other symptoms than obscuration of vision through optic nerve atrophy."

The third nerve is often affected. Ptosis, ophthalmoplegia interna, or other third nerve paralyses may occur. Bruno claims that ptosis is frequently one of the first if not the first symptom. It is also noted by Wilbrand and Saenger that ophthalmoplegia and ptosis may recover.

An important and significant cranial nerve involvement is that of the trigeminus, and one, too, which I think is apt to be overlooked or disregarded. The above authors say that *photophobia*, due to irritation of the trigeminus, may be a prodromal symptom. Trigeminal palsy follows. This was the condition in Audry's case.* The first symptoms were vomiting, vertigo, and intense photophobia. Five weeks later anesthesia of the conjunctiva and cornea, suppurative retinitis, conjunctivitis, etc. The tumor was a carcinoma.

The olfactory nerves would escape injury unless there were great extension forward. Tests of the sense of smell should be carefully made on both sides. Positive or negative findings would be of diagnostic value. The auditory nerves may be

*Virchow-Hirsch Jahresbr., 743 1888.

affected if the roaring in the ears noted in my case, and probably in others, was due directly to the pressure or irritation of the tumor.

Operation for the removal of hypophyseal tumor has been performed a few times in the last three or four years, and marks a distinct advance in brain surgery. The first successful operation of this kind was performed by Hochenegg,* of Vienna. The great difficulty lies in reaching the hypophysis in a manner suitable for the removal of a tumor. The best way of doing this would seem to be by the method devised by Eiselsberg, Schlofer, and Tandler. The nose is turned back and the entire nasal cavity reamed out until the apex of the cone so formed reaches the bed of the hypophysis.

H. Borchardt† operated for hypophyseal tumor through the frontal sinus. By lifting the frontal lobes, the hypophysis could be reached, but was inaccessible for removal. The operation was accompanied by alarming hemorrhage. Eiselsberg‡ reports three cases operated upon in January, 1907. He used the nasal flap approach with removal of the base of the frontal sinus, but thinks Hochenegg's idea, of going directly through the nasal fossæ without disturbing the frontal sinuses, good, in that it would prevent subsequent deformity, and quite feasible, especially where the tumor is benign.

AUTHOR'S CASE.—On May 26, 1904, an unmarried German woman, then thirty-five years of age, presented herself at the eye dispensary of the Presbyterian Hospital, Philadelphia. She had had pain in the left eye for one week and the vision in this eye had been noticeably poor for one year. She gave no history of headache, vertigo, nausea, or vomiting, but all four symptoms played their rôle in the course of the disease. With the exception of muscular rheumatism at times, she had always enjoyed good health, and, while no history of lues was obtainable, her subsequent tolerance to mercury and potassium iodid would justify suspicion. Her eyes had been examined two years previously and glasses prescribed.

* Annals of Surgery, p. 781, 1908. † Loc. cit. ‡ Loc. cit.

Examination showed the left eye to be slightly proptosed, the proptosis being directly forward. Movement of the left eye toward the temporal side was subnormal; other ocular movements on both sides were full. There was less room within the orbit all around when the fingers were pushed beneath the margin, and the skin of the face and the cornea were less sensitive than on the right side. V. O. D. = $\frac{5}{7\frac{1}{2}}$; Ac. = ty. 50–14–35 cm.; V. O. S. = counting of fingers at 20 cm.

The pupils were equal, about 3 mm. in diameter, solar illumination, and the irides responded to light, accommodation, and convergence. The test for hemianopic pupillary inaction was negative.

Fig. 1—Visual fields in May, 1904.

Ophthalmoscopic Examination.—Right eye: Media clear, nasal margin of disc blurred, trace of definition temporal side. The disc was moderately swollen, the summit being seen with + 3 D., while the fundus elsewhere was about + 1 D. The arteries and veins were tortuous. There were no hemorrhages. *Left eye:* Media clear; disc rather sharply defined and atrophic. The veins were large but not tortuous.

The right visual field showed concentric nasal contraction and complete or almost complete temporal loss, with a fairly well defined vertical line of separation, 8 degrees or 10 degrees overshot. Color fields for red and green corresponded.

The left visual field consisted of a large nasal area 10 degrees or more beyond fixation, and a smaller temporal area about

30 degrees beyond fixation connected by a 10 degree band or isthmus above.

The headache which appeared about August varied much in frequency and severity, but was always of like character and location. The pain was in the back and left side of the neck, and the left side of the head up to the level of the eye. Sometimes it was excruciating, causing the patient to scream; at times it would be of daily occurrence, and sometimes she would be free from it for a long time and feel perfectly well. The vertigo, noted first in July, was also very irregular, but was more or less in evidence throughout. Nausea was never a very disturbing symptom, although noted at times, after August, 1904, and the vomiting occurred in paroxysms.

Fig. 2.—Visual fields in October, 1905.

In October, 1905, it was persistent for nearly a week. Again, in July, 1908, shortly before death, vomiting was frequent and persistent. At other times no history of it could be obtained.

The nutrition remained excellent and only very late did mental deterioration commence, but even then was scarcely noticeable. She gained markedly in weight after 1905, and presented a different facial expression, possibly becoming acromegalic.

November 29, 1904; October 6, 1905, and in July, 1908, she was admitted to the German Hospital. Every time there was a concentrated outbreak of all the symptoms she ever

had—a veritable storm—her suffering was intense, and it was thought that each attack would be final.

The first time she remained seven weeks. She received 3j daily of mercury by inunction, but was not ptyalized at the end of five weeks. Potassium iodid was started about the third week and continued until four months later, when she was taking 420 grains daily and was feeling well.

The second time she remained five weeks, improved rapidly, and was again discharged feeling well, and apparently no worse off than at any time previously.

The third time she died, as she was expected to do the first and second. Her condition during the last ten days, as it ap-

Fig. 3.—Field of right eye, 1906. **Fig. 4.—Field of right eye, 1907.**

pears on the hospital record, was as follows: Persistent headache, nausea, vomiting, and loss of bladder control. Cerebration slow; questions answered in a thick guttural tone; masklike expression. Parotitis and throat condition as noted below. No hemiplegia. Sensory examinations unsatisfactory. On August 1st she gave the first signs of dissolution. Irregularity of heart action; very rapid, poor quality to first sound. Commencing dilation of right side of heart; chest beginning to fill; breathing labored but no Cheyne-Stokes. Glycosuria, sugar 1½% to 2%. Death on August 3, 1908.

In 1907 these "spells," as she called them, were more frequent but less severe than the three noted above. She would

at times fall, but would not lose consciousness. Once she fell down a flight of steps, but sustained no serious injury.

The knee-jerks were always active, and during her periods of greatest suffering were exaggerated, being more so on the right side. Kernig's sign was generally positive, and was also more pronounced on the right side.

Station remained generally good until 1908, when she walked with some uncertainty and hesitation. At this time she also complained of a constant buzzing in the left ear. In June, 1907, she had, rather suddenly, difficulty in breathing. Examination of her nose and throat by Dr. Barton H. Potts disclosed a large nasal polyp, which was removed. The sinuses were

Fig. 5.—Visual field of right eye, 1908.

examined at the same time, and a negative report given, with the remark that the right side was suspicious.

A second examination was made by Dr. Potts, July 24, 1908. The report reads: "Chronic laryngitis, but no acute process; no thickening, swelling, or great changes. Both cords move freely and approximate normally. Left side, parotitis." Three days later, marked congestion of the roof of mouth, tonsils, and pharynx. Marked parotitis, left side. The right parotid gland became involved August 1st. Cultures from the throat showed pure staphylococci, but no streptococci.

The sense of smell was tested several times during the course of the disease and found to be intact on both sides. Blood and urine analyses were also made at different times. Two of

these, one in 1905 and one in 1908, showed albumin, hyaline and granular casts in the urine, and a slight reduction of hemoglobin in the blood, with a leucocyte count of 13,000.

In 1904 an *x*-ray was made of the head by Dr. Wm. S. Newcommet. An unmistakable malposition and malarrangement of the structures along the base in the middle fossa were demonstrated. There seemed to be a saddle-like depression in this region.

The more important changes, which were noted during the four and one-half years of observation, can best be summarized as follows:

From May 25, 1904, to November 29, 1904, the vision of the right eye was mostly $\frac{5}{7\frac{1}{2}}$, partial; once it was $\frac{5}{10}$, and once $\frac{5}{5}$, partial.

The left eye was recorded as counting fingers at 20 cm., then at 10 cm.; then in the nasal field imperfectly; and finally as hand movements a little in the nasal field.

During 1905 the vision of the right eye ranged from $\frac{5}{10}$ to $\frac{5}{7\frac{1}{2}}$, but was more often $\frac{5}{7\frac{1}{2}}$. The left eye counted fingers imperfectly at 10 cm., saw hand movements at 50 cm., and finally registered light perception only.

In 1906 the vision of the right eye was $\frac{5}{7\frac{1}{2}}$ during the first two months. This was her best year, and she was seen but few times.

In 1907 the vision of the right eye was generally $\frac{5}{15}$, once it was $\frac{5}{20}$. Corrected with a cyl. + 1 D. axis 90° it was again brought to $\frac{5}{7\frac{1}{2}}$; with correction, ty. .75 was read with some difficulty.

The left eye had light perception only. It will be noticed that central vision in one eye remained good, in spite of several attacks of the optic neuritis and increasing atrophy until the end. At no time was she unable to go around alone on account of blindness.

The ophthalmoscopic changes are interesting, as showing repeated or recurrent attacks of acute neuritis.

Fundus.—May 26, 1904, right eye: Optic neuritis, with

moderate swelling of disc; arteries and veins rather full and tortuous. Left eye: Post-neuritic atrophy, veins large and dark, but not tortuous.

Three months later, the swelling of the right disc had almost subsided. The disc was atrophic; the vessels were of good size. This was immediately followed by a recurrence of neuritis. August 16, 1904, right eye: Swelling of the disc increased and the veins became wider. There were no hemorrhages. The atrophy of the left nerve was progressing. Three months later the swelling of the right disc began to subside. Near the disc margin glistening exudation covered in part some of the vessels.

In May, 1905, the right disc was noted as becoming very pale and atrophic. The vessels were still tortuous. The left disc was very atrophic and the vessels were not tortuous. Three months later the conditions were about the same.

In November, 1905, after leaving the German Hospital, the right disc was quite sharply defined and the atrophy had progressed. The condition was becoming like that in the left eye.

No special changes other than increasing atrophy and quiescence were observed until May, 1907, when the right disc was swollen about 2 D., the margins were again blurred, and the vessels were very large and tortuous, making sharp turns. No hemorrhages. One month later white spots were accumulating on disc below, and the disc margins were becoming sharper.

In April, 1908, the atrophy had advanced, the vessels were noted as still being tortuous and kinky, and narrowed as they entered the disc.

The visual fields were quite characteristic of the disease.

They are shown in Figs. 1, 2, 3, 4, and 5. They correspond to the fields most often found in chiasm disease. The nasal field, greatly contracted, of one eye will persist, and the fellow-eye will in a comparatively short time become blind. In this case the left optic nerve was found to be infiltrated with the tumor cells.

Pathological Report, by Dr. George P. Müller and Dr. Alfred Reginald Allen.

Autopsy No. 1176. F. S., aged thirty-nine, died August 3, 1908. Autopsy performed ten hours after death.

Anatomic Diagnosis: Tumor of the brain; chronic parenchymatous nephritis; fatty degeneration of the liver; passive congestion of the spleen; chronic adhesive pleuritis (left).

The thyroid and adrenal bodies appeared perfectly normal in size and appearance.

Upon opening the calvarium the dura was observed as being thickened and tending to adhere to the skull. There was no bulging of the brain on opening the dura, the pia-arachnoid was slightly congested, and some excess of fluid was observed. Upon drawing the frontal lobes upward a growth was encountered adherent to and growing into the base of the skull in the middle fossa. The sella turcica, body and wings of the sphenoid were eroded, and upon the left side the sphenoidal and ethmoidal cells were opened up, the tumor extending as far as the soft part of the nasopharyngeal wall (Fig. 6).

The mucous membrane of the latter was perforated in one place. The optic nerve and the nerves leading to the sphenoidal fissure on the left side seemed to be involved. The growth was soft and spongy, and upon the inferior aspect of the brain was apparently encapsulated, but was free-growing in that portion, pushing into the ethmoid. It was of pinkish-yellow color. After removal of the brain the tumor was found to measure 5 cm. in length, 3 cm. in width, and to extend upward, backward, and laterally, finally protruding as nodular masses about 1 cm. in diameter through the floor of the third ventricle. The foramina of Monroe were thus obstructed, causing an obstructive hydrocephalus of moderate degree.

The tumor was examined histologically by Dr. Alfred Reginald Allen, who reports "that it possesses a rather fine and irregular alveolation. The alveolar walls are loose and indistinct,

Fig. 6.—Photograph of base of skull, showing destruction of bone.

and in them appear numerous thin-walled blood-vessels. The bulk of material consists of tumor cells, which are mostly, from pressure influences, of irregular shape, but here and there show distinctly a columnar arrangement. They infiltrate irregularly throughout the entire mass, with occasional tube-like formations being developed. These cells are provided with large, oval, vesicular nuclei. Occasionally one encounters cells staining faintly, but more markedly than the bulk of the cells, with eosin. These cells possess two or three neuclei and are most probably small giant-cells. Globules of varying size, clear, homogeneous, and taking eosin tints slightly, are occasionally found in spaces, sometimes in blood-vessels, and are likely colloid substances.

"The optic and third nerves were both examined, the right second and third being uninvolved except by pressure; those on the left side being infiltrated by the neoplasm."

DISCUSSION.

DR. ALEXANDER DUANE, New York: I have now under observation a young man with syphilitic history who has a nearly complete bitemporal hemianopsia with moderate impairment of vision and daily headache for three or four months. There is no optic neuritis, no optic nerve atrophy as yet, no involvement of any of the other cranial nerves. Careful examination shows that there is no disease of the accessory sinuses. There is no evidence of acromegaly. The radiographic picture shows a marked enlargement extending back from the anterior clinoid processes. On the supposition that this might be a gumma thorough specific treatment has been given for four weeks without any effect upon the symptoms or upon the vision and fields. The condition is probably a tumor in the region of the hypophysis, as in the case reported in the paper.

DR. W. ZENTMAYER, Philadelphia: I should like to speak of a phenomenon that has occurred in a case under observation fifteen years in which bitemporal hemianopsia, with vision of $\frac{5}{15}$, was maintained ten or twelve years. I saw the patient three years ago, and she still had bitemporal hemianopsia. Last

year she returned with the general symptoms (those of disease of the pituitary body) very much worse, but with complete recovery from the bitemporal hemianopsia. The field, however, remains greatly and irregularly contracted. My patient, a woman forty-five years of age, has increased very much in weight. General health was fairly good until the past few years. She has partial optic atrophy with a little blurring of the edges of the disc. Diplopia has developed of late. Dr. Spiller, to whom I sent the case, said it was not unique, as Dr. Packard reported a case of bitemporal hemianopsia which existed for a considerable period and cleared up.

DR. C. W. CUTLER, New York: I have recently observed a case the diagnosis of which is still uncertain, but the observations which have been made are interesting in this connection.

Male, aged fifty-three, first seen April 3, 1909. Has had much rheumatism. Eyes seemed normal until about two years ago, when he noticed that parts of the fields were limited. There have been no severe headaches, no vertigo or vomiting, no symptoms suggesting acromegaly. Vision with correction, $\frac{20}{30}$ in both eyes. A year ago he began to have slight diplopia at a distance. At present, it is not apparent with any tests. The nerves are pale, especially the temporal halves. Vessels normal. Pupils react normally. No Wernicke. The fields of vision are hemianopic for form and color. The *x*-ray findings are described by Dr. L. G. Cole as follows:

"Normal markings in the skull; the curve from the temporal artery and its branches and the sella turcica show distinctly; anterior clinoid processes also show distinctly and are normal in size and shape; the posterior clinoid processes are very much attenuated, and the space between them forming the sella turcica is twice its normal size.

"I make out no change in density except that which can be accounted for by the thinness of the posterior clinoid processes; the increased size of the sella turcica would make one suspicious of a tumor in this region, but I do not feel justified in making such a diagnosis exclusively on the plates."

The combination of typical bitemporal hemianopsia with the condition described by Dr. Cole makes the diagnosis of pituitary tumor almost positive. Operation has been urged, but not yet accepted. It is hoped that a complete report will be possible later.

DR. M. H. POST, St. Louis: In speaking of successful operation, was it meant simply that the patient survived the operation or that it had some effect on the eye condition?

DR. W. T. SHOEMAKER, Philadelphia: In the "Journal of the American Medical Association" for July 10, 1909, there is an article by Dr. Archibald Church in which the present status of operative procedure in cases of hypophyseal tumor is expressed as concisely as it well could be. If I may, I will quote from Dr. Church, for I think he answers in this article Dr. Post's question better than I could:

"Finally, the question arises whether, a diagnosis of pituitary tumor having been made, it is justifiable to ask the surgeon to remove the growth. If, as Paulesco and Cushing insisted, life is impossible in dogs without the pituitary, one may hesitate to establish a rapidly fatal condition for one which is less so, but it must be borne in mind that the animal experiments have been made on healthy dogs, and that the entire pituitary in full functional activity has been at once removed.

"The surgery of the pituitary is a new field that has been explored only to a limited extent. Sir Victor Horsley has operated in a number of cases of pituitary tumor; his plan of procedure is to make a large opening on one side of the head, preferably the right, and approach the pituitary from the side, the steps of the operation being similar to those for the extirpation of the trifacial ganglia. The temporo-sphenoidal lobe is lifted by the use of broad spatula-like retractors, and the tumor is finally seen by its lateral aspect and incised or scraped out as the case may require.

"A modification of this operation was done for me by Dr. L. L. McArthur, of this city, by making the incision in the scalp and skull farther forward, so as to approach over the orbital plate and under the frontal lobe. This route also presented very serious difficulties.

"A second method of operation has been developed by Schloffer, on the plan worked out by Tandler and Muscovitz. It consists in making an incision down the middle of the brow and along the lateral aspect of the nose, which is then reflected to the opposite side, the nasal bones being suitably divided. The septum of the nose is severed, the turbinate bodies removed, and finally the vomer leads directly to the base of the body of the

sphenoid bone. On its removal nothing but a thin shell of bone separates the pharynx and the nasal space from the tumor. Schloffer's patient, operated on in this fashion, lived seventy-five days; the wound healed soundly, but brain infection eventually destroyed the patient.

"Von Eiselsberg, of Vienna, has operated in five cases in this manner. By this method Hochenegg has operated in two cases; the first patient, operated on over a year ago, according to a personal report from him, remains in excellent health. This was a case of acromegaly, and most interesting recessional changes have occurred in the enlarged proportions of the extremities, jaw, etc., thus practically proving the causal relation of the pituitary disease and the value of the operation.

"Von Eiselsberg's first patient, operated on June 21, 1907, not only made an excellent recovery from the operation, but the very prominent symptoms of brain tumor subsided and the condition of the eyes even improved, so that at the date of the last report the pupil had regained its activity for light, and vision was good enough to enable the patient to travel on the railways."

REPORT OF A CASE OF SARCOMA AND BONE FORMATION IN AN ATROPHIC EYE, WITH PRESENTATION OF SPECIMEN.

DUNBAR ROY, A.B., M.D.,

Atlanta, Georgia.

J. R., white, male, aged forty-two, was first seen by me in my office on October 17, 1905.

Previous History.—When he was a baby, about six months old, patient had a severe inflammation in the right eye, which was transmitted to the left, and from the description was probably a purulent conjunctivitis. The right eye recovered with some vision, but the left was totally destroyed. He has gone through life in this condition, having been able to read and study

some, and also to make his own living. Was never very strong physically and yet was never sick. No history of syphilis or cancer in the family. About one year ago the left atrophic eye began to secrete and inflame, this continuing up to the present. He also suffered with severe neuralgia on that side of the face. About six months ago the contents of the left orbit began to protrude, which has gradually increased. This was the main reason for the consultation.

Examination.—Patient's general appearance is very good.

Right Eye.—Horizontal nystagmus. One small opacity on the nasal side of the cornea. Anterior chamber and pupil appear normal. There is a small anterior polar cataract, which is evidently the cause of his nystagmus and the oblique manner of carrying his head. ' Vision was about $\frac{20}{50}$ improved by no glass, and he could read Jaeger No. 3 with ease when held very close to the eye. No pain or lacrimation.

Left Eye.—Protruding about one-eighth of an inch between the palpebral fissure was a red, hard, conical growth, almost identical with the plate in Haab's atlas depicting a sarcoma of the choroid. The condition was immediately diagnosed as a sarcoma, which was afterward confirmed microscopically as one of the spindle-cell variety. The lids were not adherent to the growth, but the latter seemed to spring from the whole orbital contents. No eyeball could be seen, as the growth filled out the entire anterior portion of the cavity. By palpation through the upper lid the growth could be felt, and also a round, soft substance which I diagnosed as the atrophic globe.

Patient was sent to the hospital, and on October 19th, two days later, the whole orbital cavity was exenterated as thoroughly as possible. The lids were not removed because they were nowhere adherent to the growth. During the operation my finger encountered a hard, globular mass in the orbit which I thought was an exostosis. Later, after the whole mass was removed, this was found to be the atrophic ball, which was filled with a sphere of solid bone, evidently originating from

the choroid. The sarcoma had its origin from the eyeball. The globe was about two-thirds of its normal size and felt just like a marble. In order to make a section of the same, a small saw had to be used. This disclosed the whole of the interior, filled with a solid bone sphere. I show you the specimen now, with the sclerotic coat and the sarcomatous mass.

The subsequent history of this case was as follows: The orbital cavity gradually took on the appearance of healing, and was kept cleansed by the patient at home. It gave him no trouble, the pains were greatly relieved, and his general condition was improved. The patient claimed a betterment of the vision in the other eye, although the tests did not indicate it.

About January 1, 1906, three months after the operation, the patient complained of dimness of vision in his right eye. The pupil was dilated and the fundus examined. Nothing abnormal could be seen except a decided paleness of the optic disc. The tests indicated a decided diminution of vision. Deep in the left orbital cavity, on the outer wall, the bone was rapidly enlarging. From this time on the vision in the right eye became progressively worse, until absolute blindness ensued. There was a gradual enlargement of the whole temporal region on the left side and progressive mental symptoms. On June 5, 1906, eight months after the original operation, the patient died from general exhaustion. No autopsy could be obtained, but the evidences of the growth made it almost unnecessary.

In the "*Transactions*" of this Society for 1902 there is a complete article on "Ossification of the Choroid," by Drs. Millikin and Darby, in which the authors tabulate 42 cases of this condition which had been reported up to that time. Quite a number have been added since, and I believe there are a great many which have not even been reported.

In the list referred to there was only one case where this ossification was associated with a malignant growth, and this was a sarcoma. The case here reported and the specimen shown are unique in that the bone was a solid sphere, and I can find no analogous case on record in the literature.

METASTATIC CARCINOMA OF THE ORBIT, WITH THE REPORT OF A CASE.

EDWARD A. SHUMWAY, M.D.,

Philadelphia.

The involvement of the orbital tissues and ocular muscles by carcinoma, as the result of metastasis from distant organs, without involvement of the eyeball, is very rare, only four cases being on record. Metastatic carcinoma of the choroid, with extension through the sclera to the orbit, is much more common. Since the report by Perl,[1] in 1872, of the first case of metastatic carcinoma of the choroid, about 68 cases have been described. The literature of the subject has been carefully reviewed in recent years by Krukenberg,[2] and Oatman,[3] and especially by Suker and Grosvenor[4] in a paper last year before the American Academy of Ophthalmology and Oto-Laryngology. Suker and Grosvenor collected 64 cases, including one of their own and three unpublished cases seen by Ginsberg, Leber, and Sutphen. To these should be added cases by Bock,[5] Schmidt-Rimpler,[6] Pollack,[7] and Lafon,[8] a total of 68. In thirteen of these* there was an extraocular extension of the growth from the original focus in the choroid, but with few exceptions the orbital growth was small, did not interfere with the movements of the eyeballs, and was not diagnosed clinically. Cases of involvement of the intracranial portion of the optic nerves and of the chiasm have

* Schultze (Arch. f. Ophthalm., xxi, 1890); Uhthoff (Internat. Beiträge z. wiss Med. ii, 1892); Holden (Arch. of Ophth., xxi, 1892); Schultze (Arch. f. Augenheilk., xxvi, 1893); Samelsohn (Deutsche med. Wochenschr., p. 927, 1891); Michel (Beiträge zur Onkologie des Auges, Würzburg, 1899); Lagrange (Tumeurs de l'Oeil, i, Paris, 1901); Schmidt-Rimpler (Lehrbuch, 7th ed., Leipzig, 1901); Reis (Klin. Monatsbl. f. Augenheilk., xli, 1903); Oatman (Am. Jour. Med. Sci., 1903); Oeller (Arch. f. Augenheilk., 1905); Thomson (Arch. of Ophth., xxxv, 1906); Suker and Grosvenor (Trans. Amer. Acad. of Ophthalmology and Oto-Laryngology, 1908).

been recorded by Elschnig,[9] Holden,[10] Krohn,[11] Dittrich,[12] and Spiller and Weisenburg.[13]

The five cases of involvement of the orbit and extraocular muscles are as follows:

Horner,[14] in 1864, published a case of paralysis of the oculomotor nerve, with proptosis and severe headaches, in a man sixty-five years old. Four months after the first examination, all the recti muscles were paralyzed, there was ptosis of the upper lid, the eyeball protruded 3 lines, the pupils were dilated and immobile, the subconjunctival tissues were edematous, the veins dilated and tortuous. No nodules were felt in the orbit, but growths appeared in the thyroid and in the submaxillary region. The eye later became so prominent that it could not be covered by the lids, and death occurred about six months after the patient was first seen. Post-mortem examination disclosed carcinoma of the dura at the base of the sphenoid, involving the right optic nerve at its entrance into the foramen, and extending backward and downward at the base of the brain. In the orbit nodules were found in all the recti and in the levator palpebræ superioris. Numerous nodules were present throughout the body: in the thyroid, sternocleidomastoid and abdominal muscles, right pleura costalis, pericardium, peritoneum, and suprarenals. Horner thought the primary growth was in the dura, and that the first paralysis of the eye-muscles was due to pressure on the nerve, but that the subsequent proptosis and immobility of the eye were caused by metastatic nodules in the orbit and the muscles.

The second case was reported by Elschnig[15] in 1898. The patient, a woman seventy-three years of age, had carcinoma of the cervix, with metastases to the glands, skin, and right mamma; all of the eye-muscles in the left orbit were found to be the seat of nodules, with the exception of the inferior oblique. Microscopic examination showed hyaline degeneration of the muscle-fibers and almost complete degeneration of the nerves entering the muscle. Elschnig raised the question whether the disturb-

ance in motility was due to the degeneration of the nerves, or to the destruction of the muscle tissue and prevention of muscular contraction.

In 1899, Wintersteiner[16] described a case in a woman fifty-eight years old. The clinical history, recorded in one of the medical wards of the general hospital in Vienna, noted a disturbance of the motion of the right eye, which was ascribed to paresis of the internal rectus muscle. There was carcinoma of the left breast and neighboring lymphatic glands. Post-mortem examination showed metastases in the liver, retroperitoneal glands, and of all the ocular muscles of the right eye with the exception of the inferior oblique. A careful microscopic examination of the entire orbital contents showed, in addition, a small nodule in one place near the ophthalmic artery, but no involvement of the optic nerve. The metastasis preserved partly the fibrous character of the primary growth, and had caused simple atrophy of the muscle tissue. The fibers were thinner, distinctly fibrillated, and the Cohnheim fields, which are very clearly marked in the intact fibers, were absent. The contractile substance had retracted, and the elastic sheaths surrounding the fibers had almost entirely disappeared, where the atrophy was evident. In no place was there any evidence of compression of the nerves or degeneration of the nerve-fibers, although here and there the cells followed them and were spread out in the perineurium. As the involvement of the muscles was a very early one, Wintersteiner believes that his case answers Elschnig's question and proves that the disturbance of motility is due to destruction of the muscle tissue, and not to compression of the nerve. He thinks, too, as only one muscle was clinically paralyzed, although all but the inferior oblique were affected, that similar cases of involvement of the ocular muscles in metastatic carcinoma may not be so rare as has been thought.

The fourth case was reported by Axenfeld[17] before the Ophthalmologische Gesellschaft at Heidelberg, in 1907. The patient was a woman who, two years after extirpation of a mammary

carcinoma, showed progressive paralysis of the muscles of the left eye. As there were no distinct orbital signs of tumor, it was thought at first that the paralysis was of nuclear origin, perhaps of a toxic nature. Subsequently, exophthalmos appeared, and when the patient was seen by Axenfeld the eyeball was almost immovable, both actively and passively, and a firm resisting mass was evident above and below the eye within the orbital margin. The patient complained of severe neuralgic pain of the first and second branches of the trigeminus, and choked disc was present. The accessory sinuses were free, and as no other metastasis could be found in the body, intraperiosteal exenteration of the orbit was performed, and the bones covered by Küster's method. Primary union was obtained. Microscopic examination showed a conversion of the orbital tissue into a dense, fibrous mass, with scattered nodules of carcinoma cells. In this dense, fibrous tissue the single muscles were distinctly recognizable as tubes, densely infiltrated with cells, which indicated that they themselves were metastatically involved. Axenfeld thought operation was indicated only in the extremely rare cases in which no other metastases could be found in the body. Even in such cases it was not always possible to be sure that they were not present.

In the discussion of Axenfeld's paper, Wintersteiner[18] referred to a case of metastatic sarcoma of the external rectus muscle in a woman who had been operated upon for myosarcoma of the intestines. Metastatic sarcoma of the orbit has also been described by Poliagni[19]; and de Schweinitz and Meigs[20] reported a case of metastatic sarcoma of the choroid and orbit, in which the primary growth was found in the mediastinum. Axenfeld[21] thinks the latter case was probably of the same character as those recorded by Oxley,[22] Powell,[23] and Tomasi Crudelli[24] as cases of malignant lymphoma originating also in the mediastium.

My own case is as follows:

M. S., female, aged forty-nine years, was seen December 23, 1906, in consultation with Dr. I. W. Hollingshead, of Philadelphia,

under whose care she had been for about ten days. An accurate history was difficult to obtain, as the patient was mentally confused, partly because of exhausting pain, and partly as the result of drugs administered to control it. She had noticed a disturbance of vision in the right eye for five months. In September, 1906, her glasses had been changed by Dr. P. N. K. Schwenk, who subsequently wrote me that her vision at this time, with a glass correcting her hyperopic astigmatism, was $\frac{20}{20}$ in each eye, and no fundus changes or disturbance of motility of the eyeball were manifest. Shortly afterward she had an attack of pleurisy on the left side, and later developed some spinal trouble, with a gastro-intestinal disturbance. From this time on she was confined to bed, suffering with abdominal pain, nausea, and marked constipation, and her weight had gradually fallen from 165 pounds to 123 pounds. For three weeks the right eye had been very painful and prominent. On examination it was found to have no light perception, was proptosed straight forward about 8 mm., and its movements were limited in all directions. There were intense bulbar injection and chemosis, the cornea was ulcerated, and the anterior chamber one-third filled with a yellowish-white exudate. The patient complained of intense ciliary tenderness and great pain, which could be controlled only by hypodermic injections of morphin. No history of a growth could be elicited, and a diagnosis was made of acute panophthalmitis, possibly due to metastatic choroiditis from some focus of infection in the pleural or abdominal cavity. Exenteration of the eyeball was therefore advised, and she was admitted to the University Hospital, where the operation was performed on the following day. Much to my surprise, although the anterior chamber was full of pus, the vitreous was found clear, and a nodular mass could be felt in the orbit back of the globe.

As I had not obtained permission for anything beyond the exenteration of the eye, the orbit was not explored further. On the next day there was still marked chemosis, which gradually

subsided under the use of cold compresses, and on its disappearance the nodular mass could be felt extending forward nearly to the orbital margin, above and below. Further examinations by Drs. John Luther and A. O. J. Kelly showed typical scirrhus carcinoma, with retraction of the left breast, involvement of the axillary and supraclavicular lymphatic glands, fixation and enlargement of the uterus, thickening of the uterosacral ligaments, and an obscure mass in the abdomen, in the position of the transverse colon, possibly retroperitoneal. On account of the evident wide-spread carcinomatosis, further operative interference was considered inadvisable, and commencing on January 6, 1907, the patient was given *x*-ray treatment by Dr. Henry K. Pancoast. The exposures, lasting from twelve to twenty minutes, were made on alternate days to the orbit and abdomen. At the same time injections of trypsin were made daily by Dr. John Luther, beginning with 10 minims, and increasing 5 minims each injection until a dose of 60 minims was given. Under this treatment, and general tonic medication, the orbital mass apparently disappeared. The breast remained unchanged and the patient's weight gradually declined, being 118 pounds on February 8th.

On January 21st she complained of considerable pain in the head and blurring of vision of the left eye. Ophthalmoscopic examination showed beginning optic neuritis, which was thought to be due either to involvement of the meninges or to general toxemia. On February 1st, after the injection of trypsin, the patient developed toxic symptoms, with a chill, rise of temperature to 101.6° F., and repeated vomiting. The site of the injection became indurated, and at this and another position large abscesses developed, and the injections were discontinued. On February 8th injections of amylopsin alternately with the trypsin were resumed, but after ten days were stopped at the request of the patient, because of the pain. The *x*-ray treatments were, however, continued until she left the hospital, March 30, 1907. At this time no growth could be detected in the orbit, and the growth in the breast and the axillary glands were reduced in

size. She had steadily lost strength, however, was much emaciated, and there was almost complete anorexia, with frequent attacks of vomiting. Throughout her stay in the hospital the constipation was marked.

After reaching home she rapidly grew worse, the abdominal symptoms growing more pronounced, and died from intestinal obstruction one month later, April 30, 1907.

An autopsy was made on the following day by Dr. Samuel Leopold, and a diagnosis was made of schirrous carcinoma of the breast, bronchopneumonia, chronic adhesive pleuritis, chronic parenchymatous nephritis, fibrosis of the liver, chronic interstitial splenitis, and chronic peritonitis (multiple serositis). Sections were prepared in the McManes Laboratory at the University of Pennsylvania from the following tissues: mammary gland, spleen, liver, pancreas, kidney, uterus, ovary, broad ligament, and pelvic peritoneum. These were carefully reviewed by Prof. Allen J. Smith and a revised post-mortem diagnosis was made by him of schirrhous mucoid carcinoma of the mammary gland, with infiltrating, non-encapsulated metastases in the liver, spleen, kidneys, uterus, broad ligament, ovary, and pelvic adhesions. Dr. Smith's report is as follows:

"(1) *Mammary Gland* (left): A section from this indurated breast shows, in addition to a few scattered and small lobules of adipose tissue, the rest of the specimen to consist of a dense stroma of fibrillar connective tissue, in which are found occasional remnants of the old glandular structure and at places definite carcinomatous infiltrations. The fibrous matrix is of the wavy type characteristic of the mammary gland. A small bit of the epiderm overlies a part of the section. For the most part it is thin and evidently atrophic, but at one position extends in an irregularly branching root well down into the mass of the general stroma, this root inclosing a comparatively large cystic space lined with squamous cells and containing a loose concentric nest of the same. In the section there are to be found a very few atrophic gland lobules, showing no malignant change and several ducts without material alteration. Widely but sparsely scattered through the stroma are small groups of cells and isolated

cells of glandular type of epithelium, some of which present the "seal-ring" appearance of so-called "colloid" change (really mucoid, the cells in reality the same as "goblet cells"). Examples of large and hyperchromatic nuclei are occasionally seen; but no examples of karyomitosis were encountered; and many of the cells are decidedly small and evidently atrophic. Several small epithelial-lined cysts also exist in the section, but present no appearance of malignant change.

"(2) *Spleen:* The capsule of the organ is slightly thickened from fibrosis, and on the outer surface are met scattered strands of fibers and large endothelioid cells, probably representing the adhesive formations above mentioned. There is no appreciable overgrowth of the trabeculæ of the organ or of the blood-vessel walls; but there is a diffuse and at places a marked fibrosis of the pulp of the spleen. The section examined shows the vessels and capillary spaces filled with blood and irregular foci of hemorrhage both in subcapsular position and in the interior of the organ. All through the section, especially beneath the capsule, and more concentrated at some positions than at others, there are epithelial cells of the same type as met in the carcinomatous breast. Mitotic figures are not infrequent and the cells, as a rule, are larger than those of the breast; here, as in the breast, examples of mucoid "seal-ring" cells are met. In no position in the section are these cancerous metastases encapsulated, but represent a diffuse and irregular infiltration of the splenic tissue. Numerous coarse, yellow, granular deposits of hemosiderin are met in the tissue. The Malpighian bodies, as a rule, are small and normal in appearance, but now and again are invaded by the cancerous elements.

"(3) *Liver:* The capsule proper is not thickened, but beneath the capsule in several sections examined there are areas of replacement of the liver tissue by a diffusing non-encapsulated scirrhous cancer of the same type as above described. In this in places there are persisting bile-ducts, with normal epithelial lining, and occasional small deposits of golden granular pigment probably mark the sites of previously existing pigmented hepatic cells. In the cancerous areas of the liver there are noted particularly (seen in the previously described sections, but not so clearly and not nearly so frequently) fine examples of cell inclusions in many of the neoplastic cells. These are occasionally seen, too, in hepatic cells at some distance from the cancerous

areas. They have more similarity to protozoa in their best examples than is common; being sharply defined by a clear, deeply eosin-stained wall, their interior granular or reticular and faintly stained by the hematoxylin, and in the center a clear, hyaline, deeply eosin-stained, nuclear-like body. These inclusions vary in size, are spherical or ovoid in shape, and, while usually single in the cells, are sometimes present to the number of two or three. In addition, many of the cells show the usual seal-ring appearance with the hematoxylin-tinted mucin in the interior. The perilobular connective tissue varies. Usually of normal amount, it at places is distinctly and even greatly increased; and in such situations there is usually at least a minor presence of the infiltrating cancer cells. There is at no place in the section examined any attempt at definite encapsulation of the cancer foci. The hepatic cells at the border of the growth are commonly degenerate, often atrophic; but there are many cells, apparently hepatic in nature, which are decidedly approaching the appearance of the tumor cells and might well be appealed to as evidence of metaplasia. The general hepatic structure shows considerable venous dilatation, especially of the central lobular venules, and the columns of liver cells are widely separated and often broken as if the tissue were edematous. The cells are more or less necrosed, and the remaining ones are granular and stain with poor definition.

"(4) *Pancreas:* No important change in the vessel walls, but some evidence of a venous hyperemia. Distinct overgrowth at places of the interlobular connective tissue and more diffused intralobular fibrosis of fairly marked grade. Islets of Langerhans for the most part intact, but some walled off by a thick and dense fibrous capsule and some the seat of intrainsular fibrosis. Scattered areas of post-mortem necrotic change evident. Otherwise parenchyma in fair state. No cancerous metastasis recognized in material sectioned.

"(5) *Kidney:* Two different sections examined, presumably from the two organs. Both show no appreciable change of the capsule, but the existence of minor fibroid change of the capsules of Bowman and local areas of intertubular fibrosis in the cortex. In both there is more marked fibrosis of the intertubular tissue of the pyramids. Both show advanced, cloudy swelling and even necrosis of the cortical epithelium, with less marked change of the medullary parenchyma; no important desquamation;

numerous casts in the tubules. In neither of the sections were there present the changes corresponding to the pale infarct noted in the gross protocol. But both show minute foci of infiltration in the cortex of cells of the same type as described in the neoplasms found in the previously mentioned organs. These were not encapsulated, but occurred in situations about vessels or Malpighian bodies where there was evident some increase of fibrous tissue in which the cancerous elements occurred.

"(6) *Uterus:* Endometrium absent from sections examined, which include only a part of the thickness of the muscular wall of the uterus. The tissue is diffusely infiltrated by great numbers of the cancer elements already described, the cells large and well preserved, often hyperchromatic or mitotic, and frequently showing the mucoid changes and the cell inclusions already mentioned.

"(7) *Ovary:* The tissue is markedly sclerosed, without persistence in the section of Graafian follicles or other structures characteristic of the organ, save a number of dense and hyaline corpora fibrosa, the scars of former corpora lutea. Widely diffused through the organ are the same cancerous elements as already described in the organs above detailed.

"(8) *Broad Ligament:* A section of the thickened broad ligament shows the presence of a diffuse cancerous infiltration of the same type as mentioned elsewhere; there is marked hyperemia and evidence of progressive connective tissue of the part.

"(9) *Adhesive Material from Pelvic Wall:* This is merely a thickened fibrous structure containing a few strands of smooth muscle and diffusely infiltrated, as described for the other structures, with cancerous elements."

At the autopsy the roof of the orbit was broken through, and a hard nodule 1.5 by 1 by 1 cm. in diameter was found directly back of the remains of the eyeball, and was removed for microscopic study. Sections were prepared by Dr. C. M. Hosmer in the ophthalmological laboratory. They include a cross-section of the optic nerve at the entrance of the central vessels, surrounding orbital fat and connective tissue, a portion of the inferior rectus muscle, and of either the internal or external rectus muscle. The orbital connective tissue is converted into a dense, fibrous tissue, which is diffusely infiltrated with epithelial cells

Fig. 1. –Cross-section of rectus muscle, showing infiltrating carcinoma cells and several nerve bundles.

of the same type as those described in sections of the mammary gland, liver, etc. The dense, fibrous tissue is either the result of a fibroid degeneration of the carcinoma metastasis, as described by Axenfeld in his case, or of the action of the *x*-rays. At the point of entrance of the vessels into the optic nerve the carcinoma cells follow the vessels through the dural sheath and surround the pial envelope as a ring, several cells deep. There is no invasion of the nerve-fibers, and sections a short distance back of this point show no involvement of the nerve at all. The nerve-fibers are in a state of advanced degeneration, with fine vacuoles in the spaces between the septa, ordinarily occupied by the axis-cylinders. The nerve is shrunken, considerable space existing between the pial and dural sheaths, and the septa within the nerve appear relatively broad, because of the disappearance of the nerve-fibers.

The two recti muscles exhibit marked infiltration of their substance with the carcinoma cells. In places the muscle bundles have been replaced by them, in others the cells have proliferated between the bundles. The remaining muscle-fibers show an advanced stage of simple atrophy, with loss of the transverse striations and indistinctness of the muscle-columns in cross-section. The infiltration is fairly well shown in the accompanying sketch by Mrs. J. D. Z. Chase (Fig. 1), in which the nerve-bundles appear especially prominent on account of the atrophy of the muscle substance.

The histological examination, therefore, confirmed the clinical diagnosis, and in the absence of involvement of the choroid, as proved by the examination of the eyeground by Dr. Schwenk, we are justified in placing it among the very rare cases in which the metastatic elements enter the branches of the ophthalmic artery which supply the muscles or orbital tissue, instead of passing into the more numerous ciliary arteries, under which circumstances we have the production of the much more common condition, metastatic carcinoma of the choroid. Whether, as Wintersteiner suggests, the occurrence of orbital involvement is

more frequent than has been assumed, is a matter for still further study. In every instance of isolated paralysis of an ocular muscle in an adult, the patient should be examined for carcinoma, and a metastatic nodule should be suspected in the presence of general carcinomatosis. The prognosis is very bad, and operation is only justifiable where metastatic growths elsewhere can be excluded, or where it is to be performed for the relief of pain.

BIBLIOGRAPHY.

1. Perl: Virchow's Archiv, lvi, 1872.
2. Krukenberg: Klin. Monatsbl. f. Augenheilk., xli, Beilageheft, 1903.
3. Oatman: Amer. Jour. of the Med. Sci., 1903.
4. Suker and Grosvenor: Trans. Amer. Acad. of Ophthal. and Oto-Largngol., 1908.
5. Bock: Virchow's Archiv, xci, 1883.
6. Schmidt-Rimpler: Erkrankungen des Auges in Zusammenhang mit anderen Krankheiten, Vienna, p. 556, 1898.
7. Pollack: Zeitschrift f. Augenheilk., xiii, 1905.
8. Lafon: Rec. d'Ophthalm., 1903–8.
9. Elschnig: Arch. f. Ophthalmologie, xxxix–4, xl—1.
10. Holden: Archives of Ophthalmology, xxxi, 1902.
11. Krohn: Zehender's Monatsbl., x, p. 103.
12. Dittrich: Prag. Vierteljahrschr., xii, p. 171, 1846.
13. Spiller and Weisenburg: Jour. of Ment. and Nerv. Dis., 1906–8.
14. Horner: Klin. Monatsbl. f. Augenheilk., p. 186, 1864.
15. Elschnig: Wiener Klin. Wochenschr., No. 5., 1898.
16. Wintersteiner: Klin. Monatsbl. f. Augenheilk., p. 331, 1899.
17. Axenfeld: Bericht. der Ophth. Gesellschaft, Heidelberg, p. 30, 1907.
18. Wintersteiner: Ibid.
19. Poliagni: Lavori dell' Instituto di anatomia pathologica dell' ospedale degli Incurabile, Naples, 1894.
20. de Schweinitz and Meigs: Amer. Jour. of the Med. Sci., 1894.
21. Axenfeld: Lubarsch-Ostertag, Ergebnisse: Sinnesorgane, p. 69, 1894.
22. Oxley: Brit. Med. Jour., 1870.
23. Powell: Trans. of the Pathological Society, vol. xxi.
24. Crudelli: La Rivista Clinica, April, 1871.

DISCUSSION.

DR. CHARLES J. KIPP, Newark: During the forty years I have been in practice I have seen about two cases of this character, and, assuming that I am fairly busy, the cases must be extremely rare. I have here the notes of a case seen some years ago, which I will read:

A woman, fifty-eight years of age, came to me in 1874, complaining of the drooping of her upper eyelid of the left eye. She stated that up to a week ago she could raise this lid like the upper lid of the right eye. The drooping came on suddenly overnight. There was nothing in her family or personal history to throw light on the present condition. I learned, however, some time afterward from her family physician, that she had cancer of her breast, a fact which she failed to mention to me. A thorough examination showed the right eye and its adnexa to be normal. The left eye was closed by the drooping upper lid, which the patient was unable to raise. The mobility of the eyeball was greatly impaired in all directions. There was very slight exophthalmos. The eye itself was normal, $V=\frac{6}{6}$. The pupil was active to light. The eyeground was normal. I was unable to discover a new-growth in the orbit.

Seven months after my first examination I discovered a swelling of about the size of a bean on the outer third of the lower orbital margin. It could not be well defined; it was apparently adherent to the orbital margin, and extended backward as far as my little finger could reach. The integument was not adherent to it. Gradually the swelling extended toward the inner canthus, but never quite reached it. The skin over the swelling, which had been normal in appearance heretofore, three months after the appearance of the swelling became red and moist. While in this condition the patient passed from my observation for some months, and when I saw her again the skin of both upper and lower lids, left half of the forehead, left side of the nose, and left cheek was covered with scales, after the removal of which the skin was found to be deprived of epidermis and moist. Adjoining the inflamed area the skin was simply red and somewhat raised in patches of irregular forms. There was no pain, but the skin felt hot. The eyelids were much swollen. The globe was somewhat protruded, and mobility greatly impaired in all directions. The ocular conjunctiva was injected. The cornea in several places was deprived of its epithelium. The eyeground was still normal.

A few weeks later I discovered a swelling with a sharp crescentic edge, between outer half and upper orbital margin and the globe. It extended in the depth of the orbit as far as my finger could reach. The inflammation of the skin continued to spread over the nose to the eyelids of the right eye and right cheek, and

also down on the neck of the left side. The part first affected gradually became much paler and dry, and was desquamating. The eyelids were less swollen; the ocular conjunctiva was still injected. The cornea was ulcerated in its horizontal meridian and was anesthetic. The eye was not painful.

Eleven months after I first saw the patient I found the following condition: The skin of eyelids and face was still hyperemic, but dry. The lids of the left eye were thickened and could be opened but slightly. The eyeball was immovable in any direction, but was not much protruded. The injection of the ocular conjunctiva was still present, and a large ulcer occupied the central part of the cornea. The tumor has grown so much that it can now be felt above and below, between the orbital margin and the globe. The patient's general health has failed steadily in the last year, and she is now very weak. Her physician has discovered a growth of considerable size in the abdomen, and his diagnosis is scirrhus of the omentum. I did not see her again. She died of exhaustion a few months later—less than two years after I first saw her. Although in the absence of an autopsy I am unable to say positively that the orbital growth was a carcinoma or that it was not a primary neoplasm, I think that there is little doubt as to the correctness of the diagnosis.

My case seems to be a good deal like the one recorded by Axenfeld.*. The dermatitis which developed in my case I should have called a herpes zoster but for the fact that the painlessness of the eruption made me think that it was due to an invasion of the branches of the fifth nerve by the growth.

DR. LUCIEN HOWE, Buffalo: The history in most of these cases is characteristic. But in the differential diagnosis we should not lose sight of one disease with which this can be very easily confused—that is, inflammation of the muscles themselves—a myositis. Interesting cases of this kind have been reported by Bock, Gleason, and others.

*Bericht der Ophthalmologisches Gesellschaft, Heidelberg, 1907, p. 20.

ORBITAL FIBROMA, WITH UNUSUAL CLINICAL MANIFESTATIONS.

G. ORAM RING, M.D.,

Philadelphia.

In March of the present year the writer had referred to him, as ophthalmic consultant to the American Oncologic Hospital, a case of extraordinary interest which had been studied at some period since the development of the symptom-complex by several well-known ophthalmologists. The patient was a perfect example of that migratory type that quaffs from many clinical fountains the bitter-sweet of manifold advice.

After I had completed my study of the case, and had performed the operation in my judgment indicated, I concluded that it would greatly add to the interest of its published history if the results of the examinations of Drs. de Schweinitz, Posey, and Harlan, to whose hospital clinics at various times he had applied for treatment, could be introduced at this point, since their reports were based upon a much earlier study of the case than my own.

In May, 1903, about one year after the development of his symptoms in the left eye, he consulted Dr. de Schweinitz at the eye clinic of the University of Pennsylvania, at which time vision in the R. E. was $\frac{6}{5}$; accommodation, 50 m.; p. p. 10 cm. L. E., $\frac{6}{12}$; accommodation, 50 m.; p. p., 17 cm. At this time patient thought bulging of left eye was stationary, but complained of morning closure of left nostril. No enlargement of the thyroid, *no tumor*, and no rapid pulse were present. The eye was pushed forward, and by straining effort the proptosis was increased. No diplopia was present in any part of field. The eyeball

attained its prominence in two weeks and has so remained for a year. Vision thought to be worse in the morning. Marked optic neuritis, swelling equals + 3D. No other fundus lesions. Fields normal. R. E., media clear, no neuritis, but decided enlargement of veins. Disc red, fundus otherwise normal.

About one year later, May 16, 1904, he again applied at the University clinic, at which time there was no change in the symptoms other than the failing of the vision of L. E. to $\frac{6}{15}$. While attending the clinic he was placed on iodid of potassium, which was gradually increased until he was taking 100 grains three times a day, with entirely negative results upon the proptosis. At this period it was thought possible that an orbital growth was present.

On September 2, 1907, he applied for treatment at the Wills Eye Hospital, in the service of Dr. Posey. The complaint was the prominence of the eyeball. Neither pain nor headache was present. Examination at that time by Dr. Posey showed moderate proptosis of the left eye. Motions of eyeball were good in all directions. No diplopia could be elicited, and there were no ocular signs of Graves' disease. Dr. Posey adds the following note: "I find no record of the examination of the fundus or of vision, which was due to the fact that he eloped before entering the dark room. It was my impression at the time that the man was suffering from sinusitis, as in the recital of his history he also complained of the left side of his nose having been blocked for a long time past."

The next record of an examination I have traced to the Pennsylvania Hospital in February, 1908,—about one year before he came under my care,—in the service of Dr. Harlan, where he was admitted for operation, but remained only a few hours. The following notes were made just previous to admission: Vision, R. E. = $\frac{15}{15}$, with glass, $\frac{5}{15}$; L. E., $\frac{10}{200}$, with glass, $\frac{15}{200}$. Patient stated that during the year previous to this examination exophthalmos had not increased. There was no change in health and no specific history. R. E., external ap-

pearance and fundus normal; L. E., eye exophthalmic nearly to the point of dislocation. All tissues to the nasal side dark in color. A growth not attached above or below can be felt at the nasal side of orbit. Pupil same size as the other and responds normally to stimulation. Ophthalmoscopic examination, complete choked disc, without other changes. Prominent vessels, + 5 D. Dr. Harlan has kindly inclosed me a copy of the fields made by Dr. C. P. Franklin, which are reproduced.

Fig. 1.—Visual fields, February 19, 1908.

The patient was also examined by three other surgeons at a later date, two of whom regarded the condition as due to orbital sarcoma, and the third to sinusitis.

The following clinical story was elicited at my examination: There is nothing of moment in the family history. The patient is thirty years of age; height, 5 feet 8 inches; weight, 145 pounds; well built and apparently well nourished. Kidneys were normal; no metastatic enlargement could be determined. Pulse was slow, volume fair, an occasional intermission was noted. No valvular lesion was present. The thyroid was not involved.

A distinct choreic tendency was present, which evidenced itself by a sudden movement of the head from side to side. This occurred many times each day, and has almost subsided since operation.

A mental symptom which occasioned considerable anxiety was a disposition to suddenly begin to count from one to ten or beyond. This was done a number of times each day without any relevancy whatever to the subject of conversation. This has also almost entirely disappeared.

He was hit on the temple with a brick when a boy, resulting in a black eye. A small scar one-quarter inch long is present just back of the orbital margin.

At twenty-three years of age the left eye was normal both as regards vision and position. Between six and one-half and seven years ago the eye evidenced a beginning proptosis, which has gradually increased to its present proportions, but which he thinks has remained quiescent for some months. This opinion, however, was not shared by other members of the family, who believe, on the contrary, that the exophthalmos has been progressive. The patient states that the use of liquors will at once induce a markedly blood-shot condition.

The pronounced exophthalmos, which was down and out, had carried the most prominent part of the eyeball to a point about 15 mm. in advance of the fellow-eye. The maximum effort to close the lids resulted in the exposure of the caruncle and a horizontal area of conjunctiva seen between the lid fissure at its inner third. The structures of the upper lid gave the impression of attenuation from the effort which was made to cover the eyeball.

The veins of the eyeball were intensely engorged, and near the inner canthus the area of exposure was characterized by a moderate conjunctival hypertrophy, the veins at that point being distinguished by an intense distention and varicosity. The caruncle was greatly swollen, extending 10 mm. in its greatest diameter.

When the eyes are directed forward the lid fissure measured 16 mm., as compared with 6 mm. on the right side.

Just within the upper and inner orbital margin could be outlined a semi-hard mass, apparently not attached, which could be traced from the region in front of the os planum to about the middle of the upper orbital rim, from which region the greatest pressure was evidently exerted. Pulsation and bruit were not present.

The vision of the left eye equaled fingers at one meter. Under lateral illumination pupil enlarged from 3 to 5 mm. In accommodation almost immobile. Media were clear. The nerve showed a well-marked papillo-edema, the most prominent vessels of the disc measuring 6 to 6.50 D. The central veins emerged in strong horseshoe bends. Those running into the lower and outer periphery were more prominent by one diopter than those upon the disc. No hemorrhages nor splotches were present. Sclera stiff. Had been wearing + 1.50 s. = + .75 c. axis 180.

The eye was by no means immobile, as the following rotations attest: Upward rotation, 50°; downward rotation, 15°; inward rotation, 15°; outward rotation, 60°; up and in rotation, 20°; down and out rotation, 30°; down and in rotation, 20°. This was regarded as a distinctly favorable symptom.

Right eye vision equals $\frac{6}{5}$ plus. Iris reacted promptly to light and accommodation. Media clear, nerve vertically ovoid, refraction low H. and H. A. S., the prominent vessels being blurred by + 1; central excavation shelved out. An irregular choroidal crescent bounded the outer disc margin. Moderate retinal striation present, with slight obscuration of the nasal edges of the disc. Veins full and dark. Fundus abnormally red, but no gross changes were evident.

Nasal examination revealed a deflection of the nasal septum upward and to the left, partly obscuring the middle turbinal and pressing upon it. No other intranasal abnormality was visible.

The illumination of the frontal, ethmoid and maxillary

sinuses was done with the assistance of Dr. Samuel D. Risley. Those on the right side showed no abnormality. The illumination of the left maxillary and ethmoidal sinuses was negative, but pressure upon the os planum with the finger placed within the orbit over the position of the anterior ethmoidal cells, revealed an extremely thin and probably eroded plate giving a distinct crackling sensation upon pressure. The left frontal sinus was absolutely dark, strikingly in contrast to that on the other disc. Dr. Risley felt it not probable that the exophthalmos was due to ethmoidal and frontal sinus disease.

Fig. 2.—Visual fields, March, 1909.

Dr. Wm. S. Newcomet, director of the *x*-ray department, kindly made three plates, an anterior-posterior, a left and a right lateral, and gives the following brief report of his findings: The anterior-posterior plate shows that the left orbit is distinctly larger than the right orbit. Frontal sinuses are clearly seen; the right sinus is somewhat clearer than the left. Antrums on both sides are about same size and gave no evidence of disease. The eyeballs can be seen in both lateral plates. The left lateral plate shows that the orbit on the left side is greatly enlarged

posteriorly; the eyeball is pushed forward from its natural position; the bony structure otherwise appears normal. The right lateral plate shows nothing abnormal.

Had it been possible to make an absolutely positive diagnosis, the operative procedure would naturally have promptly suggested itself. Exophthalmos had been variously ascribed by the surgeons who examined the case to the presence of disease of the accessory sinuses (possible mucocele), to an orbital sarcoma, or to a benign neoplasm, of which fibroma, the growth found, is a type.

Syphilis at the time of my examination could with comparative ease be eliminated, apart from the patient's denial, by reason of the comparatively tardy forward extension of the eye and by reason of the fact that large dosage of iodid of potassium had been previously given with negative results. The administration of the drug had extended over a period of several months and had reached 300 grains a day. The skiagraph by Dr. Newcomet served to eliminate any bony growth. Aneurysm should have been indicated by pulsation or bruit, neither of which was present.

Pressure did not induce recession, but, from the circumstance that the right frontal sinuses illuminated perfectly and the left was absolutely dark; that crepitation could be distinctly elicited over the os planum of the affected side; that the evident swelling was most marked up and in, giving an outward and downward ocular displacement, and that the early suggestion of exostosis in sinus disease later is apt to give way to a parchment-like feeling—these considerations strongly suggested an investigation of the frontal and ethmoidal cavities as aids in establishing a diagnosis, before proceeding to the more radical enucleation of the eye and growth.

Sarcoma was regarded as a possibility. The family history, as pointing to this diagnosis, was negative. No secondary glandular involvement was present, and there was only a history of a slight personal traumatism far removed in point of time from the development of the proptosis.

The freedom of the ocular excursions made me personally somewhat doubtful of this diagnosis, as the orbital sarcomata that I have studied, as a rule, induced comparative fixation of the globe. Orbital disease of this type is usually of a more rapid growth, although I am aware that the case of Leenheer, of endothelioma of ten years' standing, as well as others in medical literature, modifies the value of this diagnostic aid.

Had an exploratory incision indicated sarcomatous involvement of the accessory nasal cavities, I proposed to immediately desist from further operative interference by reason of the well-grounded belief that such surgery is meddlesome and invariably hastens a rapid extension. On the other hand, if a malignant neoplasm in this locality was enscapulated, I would still advise its removal, upon the ground, not yet disproved, that such disease is primarily local. If sessile and having a bony attachment, as complete operative removal as possible, to be followed by the application of the so-called Ionic method, or better known as mercury zinc cataphoresis, must be tried by reason of its success in other regions.

The patient was therefore told that an absolutely certain diagnosis previous to operation could not be made. That the indications pointed in the direction of a benign condition, probably an orbital tumor. That while the results of sinus illumination could not be regarded as final, they warranted exploratory incision as the first stage of the operation, to be followed by further interference as indicated by the findings.

Operation at Oncologic Hospital, Wednesday afternoon, March 24, 1909, under ether, in the presence of Drs. Massey, Hewson, Longenecker, Newcomet, and Brinkerhoff, of the hospital staff, and with the courteous assistance of Drs. Joseph S. Gibb and George Friebis.

In order to investigate the relation that the accessory nasal sinuses might bear to the condition, the skin of the left side of the forehead, including the eyebrow, was well drawn up and a curved incision to the bone, just within the orbital margin, was

begun at its inner third and carried a trifle below the anterior palpebral ligament. In order to protect the eye during this portion of the operation, the upper and lower lids were brought together with a stitch through the lid borders.

The Killian incision was purposely modified, since there was no intention of investigating the frontal sinuses through the regular route, but rather to approach it from the orbit. After separating the soft tissues, the upper inner orbital roof, corresponding to the location of the normal floor of the frontal sinus, was carefully explored, and showed neither erosion nor the evidence of escape of any frontal secretion.

The orbital plate of the ethmoid was next bared and found to be extremely thin, crackling under the slightest pressure, to this extent confirming the tactile impression gotten during my initial examination, when the finger was pressed into the inner bony orbital wall in this region.

No opening was discovered into the ethmoid, but the friable character of the separating wall suggested an exploratory opening into and gentle curetting of the anterior ethmoidal cells, which was done. The sinus was carefully probed, but no secretion from the ethmoid was found. In the absence of any discoverable grumous secretion pointing to the sphenoid, it was assumed that the accessory nasal sinuses bore no etiological relation to the symptom-complex.

By carefully inserting the finger well back into the orbit at this stage of the operation, a moderately hard growth running toward the orbital apex could be partly outlined. It did not spring from the inner wall and was not sessile. Its development, however, was distinctly more pronounced toward the inner and upper orbital quadrant.

These discoveries, plus the impressions of possible benignity as considered by the clinical symptoms, made me decide at once to enucleate the eye, since the location of the growth made a Krönlein operation inadvisable. The encapsulation of the growth and the possibility of its non-malignancy rendered orbital

evisceration unnecessary. There was no involvement of bone nor periosteum.

The eye was enucleated without accident. It was now possible to outline a growth the size of an average walnut, slightly irregular and more prominent up and in. With the finger the tumor was separated from its connective-tissue bed, the only incision being made with a stout scissors through some connective-tissue strands near the orbital apex. It was encapsulated. The hemorrhage was not excessive. No other nodules were discovered.

The skin-wound in the sinus exploratory incision was closed with silk sutures. The conjunctiva was likewise stitched and the wound dressed with moist iodoform gauze compress and bandaged. The skin wound healed promptly, the scarring being extremely slight, its position partly under the brow emphasizing a not unimportant point in the technique suggested by Risley and others.

Pathological Report.—(By Dr. J. M. Swan, Director of the Pathological Laboratory of the American Oncologic Hospital.) A tumor from the orbit, spherical in shape, measuring one inch by one and one-half inches in diameter, surrounded with a distinct, thin, fibrous capsule. On bisecting the tumor the interior of it was found to contain an irregular shaped mass of blackish material, resembling a blood-clot. Microscopic examination shows that the capsule is composed of a recticulum of fibrous tissue fairly rich in blood-vessels, which are filled with partly clotted blood.

The bulk of the tumor is composed of fibrous tissue fairly rich in cells of the fibroblast type. The tumor contains numerous blood-vessels with indistinct endothelial lining, containing partly clotted blood. Some of them are quite full, others only partly filled with clot. In one part of the growth these vessels are quite numerous, and some of them were almost empty. I do not consider the tumor to be malignant, but regard it as an orbital fibroma.

In order that an accurate record could be preserved of the microscopic changes induced by the long-continued pressure of

Photograph of section of orbital fibroma. Magnification × 125.

the growth upon the eyeball, I requested Dr. C. M. Hosmer, of the pathological laboratory of the University of Pennsylvania, to section the ball. His report is herewith appended:

Eye received April 12, 1909; has lain for nineteen days in 5 per cent. formalin. In the post-equatorial segment,—nasal half,—and especially inferior mesial quadrant, there is a decided flattening. Measurements: A. P., 23 mm.; V., 25 mm.; H., 24.5 mm. Cornea, h. 10.5 mm.; v. 12 mm. Pupil 4.5 mm.

Aside from the flattening noted above, and the nerve exit being pushed slightly temporalward and slightly above the horizontal meridian, the eye appears normal. Measurements from points on a horizontal line 6 mm. below the posterior pole and equidistant nasally and temporally, from a perpendicular dropped from the posterior pole, to points on the lower limbus equidistant from the vertical meridian, show these diameters,—18 mm. and 19.5 mm. respectively. Vorticose veins may be slightly more prominent than usually seen. The upper nasal is double. The sections cut from lower half of globe show:

1. A moderate papillo-edema in the stage of regression with early formation of connective tissue at disc margins.

2. Incomplete detachment of retina, with edema and partial atrophy of that membrane. Detachment, in part, is due to subretinal transudate, which is seen coagulated about the swollen and atrophied rods and cones. The ganglion cell layer shows atrophy and infiltration with moderate number of leucocytes. The edema is seen mainly in the nerve-fiber and reticular layers.

3. Apparently early atrophy of the optic nerve.

4. Deposit of coagulate about the optic nerve fibers anterior to the lamina cribrosa.

5. Coagulate (fine) lining the posterior surface of the cornea and occupying the anterior chamber.

6. Shallowing of the anterior chamber.

7. Narrow anterior peripheral synechiæ and evidence of agglutination of the pupillary margin of the iris to the anterior lens capsule.

8. Questionable early cupping of the lamina cribrosa.

The photographs, which so well show the exophthalmos at the time the patient came under my care, were kindly taken by Dr. C. B. Longenecker, of the Oncologic Hospital staff.

DISCUSSION.

DR. W. C. POSEY, Philadelphia: Dr. Ring's case illustrates, I think, the great difficulty one frequently encounters in diagnosing orbital conditions, for not only does the comparative rarity of orbital diseases render a familiarity with them impossible to most of us, but the anatomical structure of the cavity hides the contents so effectually that one learns but little from inspection and palpation. In recent years, since our knowledge of the accessory sinuses has broadened, there has been a disposition to attribute an increasing proportion of orbital cases to sinus involvement, and while it is undoubtedly true that displacement of the eyeball and orbital cellulitis may be occasioned by conditions within the sinuses, nevertheless experience has taught me at least that in many orbital cases where there are undoubted symptoms of sinus involvement, these are either but secondary to some primary condition within the orbit itself, or merely coincidental and unrelated to the orbital lesion. Dr. Ring's case is such an one, for even in the early stage of development of the growth, morning closure of the left nostril was complained of, while later on the crackling sensation upon pressure over the anterior ethmoidal cells and the absolute darkness of the left frontal sinus in contrast to the unobstructed passage of transmitted light through the other passages pointed toward sinus involvement.

A case under my care during the past winter also served to show the difficulty in differentiating between primary orbital disease and that occasioned by sinusitis.

Dr. Packard had found evidence of ethmoiditis in this case and had opened the ethmoid cells through the nose. Notwithstanding this, however, the proptosis, which had been slightly marked at the time of the intranasal operation, became more and more marked, and when I saw her the eyeball was jutting out some 3 or 4 mm. in advance of its fellow. Dr. Packard and I thought best to do a Killian, and accordingly an Arnold Knapp modification of this operation was done. We found the mucous membrane of the sinus thickened, with some polypoid growths. Examination was made of the inner aspect of the orbit, but no trace of the growth found, and we thought we were dealing with a case of orbital cellulitis secondary to a condition of frontal and ethmoidal disease. Recovery from the operation was prompt and the proptosis was somewhat lessened for some

weeks, but, the proptosis being still marked at the end of some months, I decided that there must be a growth at the back of the orbit, and so did a Krönlein operation and found a sarcoma surrounding the optic nerve. Here was a case, then, of sarcoma at the apex of the orbit simulating a sinusitis, and with actual disease of these cells when they were opened.

Two years ago I reported a case which turned out to be mucocele of the sinus in which at the time of operation sarcoma was suspected.

When disease of the sinuses can be excluded and the diagnosis of neoplasm seems positive, there is often great difficulty in determining whether the growth is malignant or benign, for, as Dr. Ring has pointed out, the degree of rapidity of growth is not always an index. I understand that Dr. de Schweinitz has recently removed a sarcoma from the orbit of a girl whom I saw in consultation with my assistant, Dr. Swindells, five years ago. At that time the proptosis, which had already existed for two years, was thought to be symptomatic of Graves' disease, and this diagnosis, which was established by Dr. Swindells and myself, was corroborated by no less a neurological authority than Dr. W. G. Spiller. Even up to the time of the removal of the growth, I am told, seven years after the first appearance of proptosis, there was a doubt as to its true nature.

In view of this difficulty in recognizing orbital conditions, every known means of diagnosis should be utilized, and in this connection I would urge the Krönlein operation for diagnostic as well as for remedial purposes. The procedure is not a difficult or lengthy one, and when accurately and carefully performed leaves but an insignificant scar. I am convinced that if it were resorted to earlier in many of these orbital cases, their true nature would be frequently ascertained, and eyes conserved, and even life itself saved in a number of instances.

DR. G. E. DE SCHWEINITZ, Philadelphia: The patient whose case history Dr. Ring has recorded in his very interesting report was for a short time under my care, and I would like to refer to several points connected with the operative procedure which has been described and the diagnosis of orbital lesions. As one of my chiefs once said to me, "the man who is on the ground is the best judge of the surgical procedure required in any given case," and as Dr. Ring was not only on the ground, but was the operator,

he is therefore the best judge of the technic which he adopted. But I cannot help expressing the hope that he will tell us why, after he opened the orbit and felt the growth beneath his finger, he did not enucleate it, which it seems to me he could perfectly well have done without removing the eye. I have been somewhat surprised in some recent experiences after opening the orbit, not by Krönlein's method but by an ordinary incision beneath the orbital arch, with what comparative ease an encapsulated growth could be removed, as it was, for instance, from the orbit of the patient to whom Dr. Posey has referred, the growth having been present for six or seven years. The tumor proved to be a sarcoma about as large as a small egg, growing from the surface of the sphenoid and filling the outer and lower part of the orbit. The entire orbital contents were subsequently removed, not because there was any difficulty in enucleating the tumor, but because it was perfectly evident that the morbid process had already attacked the bone beneath it, as well as surrounding tissues, and it was therefore believed that the chances of recurrence were less likely to arise after the radical procedure than if the more conservative course had been followed. Another question is why Dr. Ring states that he would not perform a Krönlein operation because the growth was at the upper and inner portion of the orbit. As is well known, after this operation exploration is complete only when it has been carried to the nasal side, and in a number of instances growths have been so removed, even cysts which have proceeded from the ethmoid. To be sure, it is much more difficult, but it does not seem to me that it would be a contraindication for this operation. I would, finally, like to call attention to those cases of unilateral exophthalmos in which there is inability to reduce the exophthalmos by pressure, because there seems to be a growth or thickening at the bottom of the orbit, but where no growth of this character exists. In a recent experience such an exophthalmos was present, and the proptosis could not be reduced because there seemed to be a resistant mass at the back of the orbit, which some of my colleagues who examined the patient believed to be an orbital growth, but which after prolonged study I excluded. After the death of the patient an autopsy was performed, and an intracranial growth was found which sprang from the middle fossa of the skull, growing from the periosteum. Such a case only indicates the difficulty of diagnosis, but must not be forgotten in our study of these

patients, nor must we forget that in a certain number of these cases of exophthalmos the protrusion depends upon an intracranial growth, either one which is in the cerebrum itself, or arises from the meninges, and which by causing edema of the tissues of the orbit simulates an orbital growth.

DR. C. W. CUTLER, New York, reported the following case: Patient, aged thirty-seven. In 1906 began to feel pain over left eye and first noticed exophthalmos. At this time his liver was said to be enlarged. No record is obtainable of his condition at this time, so that it is not possible to say whether the exophthalmos or the enlargement of the liver occurred first.

When first seen, in August, 1907, chief complaints were swelling of abdomen, with sharp pain over liver on coughing, and protrusion of left eye, with impairment of vision. Pain in right arm; diarrhea; profuse sweating. Physical examination: lungs negative except for dullness and diminished breathing over both bases. Heart not enlarged; systolic murmur. Abdomen hard and resistant; liver percusses from fifth space to level of umbilicus; edge hard and sharp. Weight, 170 pounds. Urine, 1028 to 1038; acid; trace of albumin and sugar; granular and hyaline casts.

Blood: hemoglobin, 86; leukocytes, 10,000 to 16,000 (two examinations); poly., 65%; lymph., 23%; large mono., 1%; trans., 1%; eosin., 3%; no myelocytes found. Temperature normal. Pulse 80 to 100. Respiration normal.

Discharged from hospital October 26, 1907. Readmitted April 14, 1908. Chief complaint, bearing down in abdomen with severe cramps. No pain in region of eye. Exophthalmos not increased. The exophthalmos was of about the same degree as shown in Dr. Ring's picture. The liver had increased in size nearly to the crest of the ilium. A similar mass filled the left side of the abdomen—the left lobe of the liver.

In right posterior triangle of neck and below lobe of right ear were enlarged, movable lymph-nodes. One of these was removed and proved to be an endothelioma.

The appearance of the eyes was the same as when first seen: Left eye protruded directly forward. Movements upward and to both sides unimpaired; downward limited; no pain on pressure. Pressure backward and downward meets firm resistance. Scleral vessels below cornea dilated and tortuous. Pupils equal

and react normally. Media clear. Optic nerve pale, slightly swollen, with edges blurred, arteries poorly filled. Veins not tortuous. Vision much reduced (fingers). Field concentrically narrowed for white, colors lost.

Downward and to the nasal side about three p.d. is a nearly square patch of pigmentation, about the size of a nerve-head, somewhat grayish; elevation about 1 D.; around this is a good deal of irregular pigmentation of a fine granular nature; below there is more gray degeneration of choroid, or infiltration. No new vessels.

The urine was found to contain melanin. Glands in the neck and axilla enlarged.

Patient died March 1st. The autopsy by Dr. Elser, of New York Hospital, showed endothelioma of the orbit, multiple metastases of the liver, kidneys, lungs, heart, and bronchial and retroperitoneal lymph-glands. Abscess of the lung. Acromegaly. The liver weighed 23 pounds 4 ounces. The hypophysis is enlarged, about the size of a small walnut. Enlargement of hands and feet and of the head had been noted and verified by measurement and skiagraph.

The right orbit contained a tumor about the size of a bantam's egg, situated between the base of the orbit and the optic nerve. The tumor was easily removed; was adherent to the sheath of the optic nerve at one point. Cut surface grayish-pink in color, granular in appearance. The base of the orbit seemed slightly eroded. The eyeball was pushed forward; was normal in size. Microscopic examination revealed the presence of innumerable alveoli, filled with small flattened endothelial cells, possessing relatively large, dense, richly chromatic nuclei and provided with a small amount of pale or pinkish cytoplasm. The alveoli were separated from one another by non-cellular, poorly vascularized connective tissue.

In this case the orbital disease, which was probably primary, since such growths do not begin in the liver usually, was practically quiescent during the two years that he was under observation, while the metastases increased and multiplied. The case has many interesting points, which will be treated when it is presented in full. Not the least among these is the development of acromegaly with enlargement of the pituitary body. Unfortunately, the eye had to be preserved so that the relations of the orbital growth could not be studied precisely. It seems probable

that the slightly elevated area of pigmentation and infiltration noted in the fundus was due to the pressure of the firm tumor mass.

DR. G. ORAM RING, Philadelphia: Dr. de Schweinitz raises two points, the first why I did not remove the tumor through an enlarged incision beneath the orbital arch, and, secondly, why I thought a Krönlein operation contraindicated.

The clinical symptoms pointed so strongly to an investigation of the frontal and ethmoidal sinuses as the primary step in the operation that, having made the suggested incision, if the growth could have been removed without undue traumatism, and without enucleation of the eyeball, it should naturally have been done by a suitable enlargement of this incision, rather than by the osteoplastic resection.

I inadvertently omitted to state in the paper that the growth was situated in the muscle cone. This fact added to its size made me feel that an attempt to remove it through the incision at the orbital rim without eyeball enucleation would induce a degree of traumatism I did not feel warranted in risking.

While it is true that with the incision in question one can always partly outline an orbital growth yet it is extremely difficult and at times quite impossible to tell the character of said growth.

Knowing there was a distinct possibility of malignancy, fearing the amount of traumatism its removal by this method would involve, and knowing that the vision was practically nil, I thought enucleation of the eye the wiser course. This view was also shared by Dr. Geo. Friebis, who assisted at the operation.

A Krönlein was not considered, because there was a possibility that the growth was malignant, some well-known authorities denying the existence of orbital fibroma, claiming that such growths are usually one of the forms of sarcoma.

The location and size of the growth—the development having been up and in—made it strongly improbable that it could have been removed in its entirety, and to remove a growth piecemeal, where there is a question of malignancy, is to assume an altogether unnecessary risk of recurrence. Fortunately, the tumor was encapsulated. Could we have definitely known that it was benign, then either of the two procedures would have been fraught with a minimum of risk.

SYMMETRICAL LYMPHOMATA OF THE LACRIMAL AND SALIVARY GLANDS (MIKULICZ'S DISEASE).

S. LEWIS ZIEGLER, A.M., M.D.,

Philadelphia.

It is now twenty years since Mikulicz first described, in 1888, a characteristic and symmetrical enlargement of the lacrimal and salivary glands, chronic in character, of a non-inflammatory and non-painful type, and not associated with any demonstrable systemic disease. Four years later (1892) he contributed to the Billroth Festschrift a special study based on three cases of this rare disease, including the case reported by him in 1888, another reported by Haltenhoff in 1889, and a third which Fuchs had placed on record in 1891, to which he added a brief review of ten similar cases, and thus fixed in ophthalmic literature the characteristics of a disease which has since borne his name. The most important contributions since that time have come through the clinic of Mikulicz, Tietze in 1896 having reported one case, and Kümmel in 1897 having collected six additional cases which he presented in a review of the literature of the subject, comprising a tabulated analysis of twenty-one cases, including his own. Many interesting monographs have since been presented, including those of Axenfeld, Zirm, Bock, Pick, Hirsch, Fleischer, Baas and others. Among these, that of von Brunn (1905) is probably the most complete, while Meller (1906) and Snegireff (1906) have each added some very interesting observations. Valuable contributions have also been made by certain French observers, the most important being those of Abadie, Delens, Gayet, Haltenhoff, DeLapersonne, Panas, Debierre, DeWecker and Masselon. A series of similar cases were briefly reported before the Ophthalmological Society of the United

Kingdom (1887–94) by Power, Frost, Juler, Brailey, Silcock, Snell, Sandford and Griffith; while in America interesting examples of this rare disease have been placed on record by Randolph (1897 and 1909), Osler (1898), Stieren (1901), Posey (1902), Shoemaker (1904), Cutler before this Society (1904), and Ziegler (1906).

SYMPTOMATOLOGY.—The disease is sufficiently described by its name—symmetrical lymphomata of the lacrimal and salivary glands. Mikulicz originally segregated cases in which the lac-

Fig. 1.—Symmetrical enlargement of the lacrimal, parotid, and submaxillary glands. (Original case of Mikulicz.)

rimal, parotid, and submaxillary glands were symmetrically and simultaneously enlarged (Fig. 1). Later reports from his clinic, however, included cases that were non-symmetrical, and cases in which only a single pair of glands were involved. It is quite possible that these atypical cases might have developed lymphomata of the unaffected glands if they had been kept under observation long enough, without instituting treatment. This would seem to limit the characteristics of this symptom-complex, therefore, to a chronic, indolent, symmetrical enlargement of one or

more glands of the head, of a non-inflammatory and non-painful type, not associated with any systemic disease, beginning, as a rule, in the lacrimal, and soon involving the parotid and submaxillary glands. This sequence, however, may be reversed. The accessory lacrimal glands and the accessory parotids are frequently involved, while the preauricular glands may participate in this process. The sublingual (Fig. 1, *a*) glands and the glands of the palate (Fig. 2) have also been affected in many cases. Involvement of the Blandin-Nuhn glands may cause a distinct nodular swelling on the tip of the tongue.

Occasionally some of the other glands have shown enlargement, but their interrelation has not been proved. Osler noted

Fig. 2.—Enlarged glands of the palate. (Mikulicz.)

enlargement of the spleen, of the cervical chain, and of the tonsils in his case. Sandford reported hypertrophy of the tonsils and adenoid tissue of the pharynx. Haltenhoff found marked tonsillar enlargement. I have likewise noted enlarged tonsils in both of my cases. Such conditions were usually antecedent, however, and neither synchronous nor associated. Otherwise, no evidence of a general lymphatic disturbance has been educed.

The objective symptoms of this disease are chiefly a dense, brawny swelling of the glands involved, non-painful but sometimes tender to pressure, freely movable under the skin, but occasionally adherent to the subjacent tissues. The facial

appearance is quite characteristic. There is a marked broadening of the cheeks as in mumps, and partial ptosis on the temporal side, the drooping eyelids resembling those of a bloodhound. Elevation of the lid at the external canthus often reveals a downward displacement of the retrotarsal fold by the swollen and pendulous lacrimal gland (Fig. 3). Both parotid regions are occupied by a broad, oval tumor, which may be knobby or lobulated, and frequently displaces the ear lobe upward and outward. The submaxillaries do not, as a rule, protrude on the skin surface, but may become unduly prominent on the floor of the mouth.

Fig. 3.—Downward displacement of pendulous lacrimal glands. (Mikulicz.)

The subjective symptoms noted in these cases are dryness of the conjunctiva from partial suppression of the tears, obstruction of the vision from ptosis, with consequent inability to see through the chink-like palpebral fissure, dryness of the mouth from lessened salivary secretions, and limited ability to swallow or talk owing to the interference of the enlarged submaxillaries.

Respiratory disturbances are not uncommon. Kümmel has noted hypertrophic rhinitis, bronchitis, asthma, and the sequelæ of influenza in several of his cases. Haltenhoff records eczema of the nostril, sneezing, coughing, swelling of the pharynx, and enlarged tonsils in his case. Adler relates that his patient

suffered from hoarseness and swelling of the pharynx of so marked a character that a laryngeal examination could not be made. Osler mentions a nasal discharge, thickening of the cartilaginous septum, enlarged tonsils, and other obstructions to free breathing in the case he reports. Pick refers to a chronic cough with expectoration. Ranzi records a persistent post-nasal catarrh. My first case showed hypertrophy of the turbinates, antral discharge, and intranasal adhesions, with unusually large tonsils. My second case, herein reported, has a similar history of respiratory obstruction. Both were confirmed mouth-breathers. Dryness of the lips and mouth has frequently been noted in these cases, and may arise either from oral breathing or from lessened activity of the salivary glands due to pressure on the acini from interstitial deposits in the gland. Carious destruction of the teeth has been noted by Kümmel, probably caused by mouth-breathing.

A summary of the cases reported shows that the age at which this disease was first manifested ranged from four years to seventy years. Males and females appeared to be affected about equally. The duration of the attack varied from two months to ten years and upward, which fact of itself would emphasize the chronic, indolent character of this disease. No constitutional disease has been found complicating these cases, when typical.

REPORT OF CASES.—As I shall later refer to certain facts observed in my first case, I will include a condensed history of it.

CASE I. Agnes M., colored, aged eighteen years. Came to Wills Eye Hospital, January 13, 1905, with symmetrical swellings of the lacrimal, parotid, and submaxillary glands; duration six weeks. Palpation shows that glands are hard, not tender, and non-adherent. Slight ptosis. Lips dry. Tonsils very large but soft and relaxed, filling the post-pharyngeal space and interfering with respiration. Is a mouth-breather and shows facial pallor in spite of her color. Hypertrophy of inferior turbinates, with adhesions to septum and discharge from antrum. No systemic disease. Spleen not enlarged. Blood and urine normal. Visual acuity unimpaired.

Fig. 4.—(Case II) Author's case of Mikulicz's disease.

Treatment.—No medicine was administered, but tonsillectomy was strongly urged.

Operation.—On January 16, 1905, the tonsils were thoroughly excised. Free breathing was at once established. Retrogression of the submaxillaries began promptly, followed by the parotids, and finally included the lacrimals. Convalescence covered a period of about two months. Coincidently, she was wholly freed from her chronic head colds.

CASE II. David H., colored, aged thirty-four years, came to my clinic at Wills Eye Hospital, April 10, 1908, with bilateral enlargement of the lacrimal, parotid, and submaxillary glands, which began about eighteen months ago, and involved the glands in the order named. The swellings are symmetrical (Fig. 4) of a dense, board-like hardness, non-painful but tender on pressure; not adherent to the skin but attached to the subjacent tissues. There is some slight ptosis of the upper lids at the outer side, the drooping resembling that of a bloodhound. There are three small lymph-nodes on the chest. Spleen is not enlarged. Sublinguals and Blandin-Nuhn glands are not involved.

There is puffing of the turbinates in both nostrils; tonsils are enlarged and soft; uvula is relaxed and pendulous; is subject to frequent head colds and is a mouth-breather. Extra exertion causes shortness of breath. Suffers from dryness of lips and mouth. For first six months following onset of disease had a bad cold with attacks of choking; also had alternating attacks of diarrhea and constipation. General health good. Blood and urine normal. Family history negative. Has never had any fevers or other serious illness. Had mumps in childhood. Occasional attacks of chilliness; no malarial history. Has not had syphilis. Injection of Koch's "old tuberculin" gives negative reaction. By a control test the same tuberculin gave a positive reaction in two other cases on the same day, which demonstrates the activity of the test fluid and his freedom from tubercular infection. Vision is practically normal.

Treatment.—I decided to withhold all medication, as in my previous case, and to simply restore nature's functions by resorting to operative measures.

Operation.—On April 15, 1908, double tonsillectomy was performed, and the uvula was excised. The throat healed rapidly, and the intranasal condition showed marked improvement. Free nasal breathing was reëstablished and the physical condition

improved. The first retrogressive symptom noted was the softening of the lacrimal and submaxillary glands, which began to be apparent about the time he was discharged from the hospital, May 11, 1908. The parotids still maintained their fibrous hardness, although the swelling was somewhat reduced.

ETIOLOGY.—The etiological factors which most writers have recorded in these cases are: (1) Infection from buccal or conjunctival bacteria, (2) glandular irritation from some toxic agent in the blood or lymph-stream causing lymphatic hyperplasia, and (3) some idiopathic origin. Mikulicz and Kümmel favor the theory of "an infectious or parasitical process in the widest sense of the word," but do not explain the origin of their belief. No specific bacteria have been demonstrated in these cases, the microscope usually revealing lymph-cell infiltration of the interstitial tissue, which Mikulicz considers wholly responsible for the enlargement of the gland.

Although bacterial infection is usually accompanied by an acute inflammatory process, no inflammation has been noted in these cases. Granting the possibility of infection, whence would it originate—from the eye, the mouth, or the nose? It is claimed that trachoma of the fornix has caused lacrimal adenitis (Baquis). By analogy it is deduced that buccal bacteria might be transmitted through Steno's duct and thus infect the parotid (Hanau). I think it is much more probable, however, that the source of infection is nasal, and the means of transmission through the lymphatic capillaries. It certainly seems possible that a steady stream of toxic, bacteria-laden secretions could be absorbed from the accessory sinuses (chiefly antrum) and carried directly to these contiguous glands. If, however, the origin is an infection from neighboring parts, why should the course of this disease be so sluggish and the condition remain unchanged for months and even years? On the other hand, may this not be a chronic hyperleucocytosis strictly localized to these enlarged lymph-glands?

How can we explain the retrogression of these glandular

swellings during the course of an acute intercurrent disease, and their recrudescence in some cases soon after convalescence? Kümmel has reported such an occurrence during pneumonia, Mikulicz during appendicitis, Haeckel through a severe enteritis, Delens after an attack of cholera, Zirm during an attack of erysipelas which followed partial excision of the gland, Quincke from a similar cause, and Osler after an attack of acute pleurisy with effusion. I have seen slowly healing operative cases improve during an attack of facial erysipelas, and relapse to their previous condition when the attack was ended. This is particularly noticeable in operations about the nose, as the sinus discharges wholly cease for a time, but gradually reappear when convalescence is thoroughly established. The query naturally arises, does the general disease create a systemic polymorphonuclear leucocytosis that temporarily overwhelms and obliterates the localized hyperleucocytosis in the affected glands?

As to the question of hematogenous infection, Kümmel says: "There is in no case any reliable evidence as to the transmission of bacterial infection from the blood to the salivary and lacrimal glands." Other skilled observers who have made a careful study of the blood in these cases have likewise noted the absence of bacteria or other abnormal conditions, and thus corroborate this view. The fact that only the glands of the head are attacked would also militate against the probability of a bacteremic origin, although it is not possible to explain the process of "pathological selection."

On the other hand, Mikulicz suggests the theory that the "disease exciter" is ectogenous, the port of entry being through the conjunctiva; hence the lacrimal gland is attacked first. From thence it passes by the lacrimal canal to the nose, naso-pharynx, and mouth, which through their similar mucous membrane linings form a "continuum" that carries this agent to the other glands. In view of the fact that no specific infectious germ has been isolated, this theory of transmission seems too hypothetical to merit our acceptance.

There still remains for our consideration the view that some toxic agent or chemical irritant in the lymph-stream might cause an occlusion of the efferent lymph-channel of the gland, and thus encourage leucocytic engorgement. This could occur in one of two ways: (1) From some perversion of glandular function resulting in the secretion of irritating materials and their retention within the gland substance, and (2) from irritation of the gland by some toxic fluid which is absorbed and transmitted from neighboring parts. Both of these processes may be properly included under the general term of chemotaxis or toxic leucocytosis.

The first proposition has a typical exemplification in the case McHardy has placed on record, in which sudden enlargement of the lacrimal glands resulted from excessive indulgence in grief. Lagrange has reported a case of temporary enlargement of these glands due to the perverted metabolism of the menstrual period. We also know that the antrum may secrete a fluid so irritating that it will cause swelling of the Schneiderian membrane and excoriation of the nostril and lip.

The second proposition is amply demonstrated, as I have previously intimated, by the fact that the fluid contents of the accessory sinuses (chiefly antrum) may be absorbed by the lymphatic capillaries and carried to these contiguous glands. In confirmation of this view I can recall having seen a case of chronic, indurated lymph-node of the cheek that had been diagnosed sarcoma by several competent surgeons. It promptly and spontaneously disappeared after a nasal operation that restored antral drainage and free breathing. Whether this lymphoid hyperplasia was caused by a bacterial infection or by the absorption of an irritating lymph fluid is difficult to determine. That it was not sarcoma was convincingly demonstrated by its rapid and complete resolution.

I have previously noted the respiratory disturbances which have been present in the majority of the cases reported, and which require our careful consideration as etiological factors. The relation of suboxidation and disturbed metabolism to these

glandular enlargements is a vital one. My own cases showed marked interference with respiration and greatly lowered oxidation. They were both confirmed mouth-breathers, and suffered from antral discharge. Excision of the tonsils removed the respiratory interference, and resolution of the enlarged glands quickly followed. Although Kümmel made a careful examination of nasal mucous membrane clippings in his case of hypertrophic rhinitis, the result of his study was negative. He was, nevertheless, greatly impressed by the clinical fact that whenever the nasal obstruction and asthmatic attacks became more pronounced a recurrence of the glandular swellings soon followed. Per contra, in my patients, involution of the enlarged glands was promptly established as soon as the respiratory obstructions were removed. These are significant facts worthy of our most careful thought. The conviction is forced upon us that a careful examination of every case of Mikulicz's disease would probably reveal some lesion of the respiratory tract which had not been reported, either through inadvertence or through lack of special knowledge on the part of the observer.

Finally, we should bear in mind the etiological element of hereditary or racial predisposition to lymphatic dyscrasiæ, which factor has been most pronounced in the cases so far reported in America, all of whom were members of the negro race.

PATHOLOGY.—The pathology of this disease is obscure. The histological picture has not been painted in the clearest colors, nor are the microscopic details as distinct as they should be. The macroscopic examination of the section of an extirpated gland made by Mikulicz showed enlarged normal gland structure imbedded in a loose mass of pale, yellowish-red tissue of fatty consistency, but very poor in blood-vessels. The microscope revealed this mass to be an enormous infiltration of small, round cells into the interstitial tissue. In this mass were grouped the apparently unchanged acini, which seemed to be pushed or torn apart by the new tissue. In certain areas a portion of the normal gland had been choked out by the engorgement. I will

quote Mikulicz's own pithy description: "The microscopic examination shows that the gland parenchyma proper plays a completely passive rôle. The enlargement is produced solely by the enormous small-cell infiltration of the interstitial connective tissue." He claims that the preservation of the capsule of the gland, and of the interlobular septa, forbid a diagnosis of typical sarcoma, the small-cell infiltration histologically resembling most nearly the lymphadenoid tissue of true lymphoma.

Fuchs examined the nodular growths in his case and found the glandular elements absent, but the avascular texture of lymphoma present. Reymond's case showed lymphoid tissue with areas of amyloid degeneration. Adler found what he diagnosed as small-cell sarcoma, but complete resolution occurred under arsenic. The patient reported a "perfect cure" at the end of four and a half years, although he continued to take the arsenic for some time as a preventive. Mikulicz pertinently remarks that this is not the usual behavior of sarcoma. In the case of Arnold-Becker there were dense accumulations of lymphoid elements imbedded in a delicate reticulum, with here and there a stronger connective-tissue band, resembling completely a type of lymph-follicle. These tumefactions were declared to be lymphadenomata. Power found hypertrophy of the interstitial web, but the gland substance was unchanged. Tietze noted entire absence of any glandular web, but the presence of a very spongy web of connective tissue, which was thickly permeated with small, round cells. Osler's case showed that the lacrimal glands had been replaced by fibrous tissue. No microörganisms were discovered in any of these cases.

Kümmel examined the salivary glands extirpated by Mikulicz and made a most elaborate report. Macroscopically he found them very soft, marrow-like in consistency, intensely white, and poorly vascular. The microscope showed a lymphoid trabeculum lacking in connective-tissue fibers, imbedded with densely pressed round cells and lymphocytes poor in protoplasm. He formulated two alternative propositions: (1) The lymphoid

proliferation may start at the acinus, the disease-agent entering through the efferent duct of the gland, and forming a lymph-follicle around the acinus: (2) the lymphoid web might also develop itself from the blood-vessels, this cell-poor web thus representing the germinating center. He later abandoned these theories as hypothetical, because of the slight evidence in their favor, and further acknowledged that the microscopic findings had often proved to be unreliable. He believed that lymphoma had an ectogenous origin, while leucemia and pseudo-leucemia were hematogenous. He suggested that instead of leucocytosis of the lacrimal and salivary glands, the synonymous designation of "achroöcytosis" should be adopted. As, however, this glandular enlargement is due to a lymphatic hyperplasia from leucocytic infiltration, I think we should accept the name "lymphoma" as more distinctly descriptive of this tumefaction.

DIAGNOSIS.—The diagnosis of Mikulicz's disease should not be difficult. I have previously noted the characteristic facial appearance, consisting of ptosis of the temporal half of the upper eyelids, broad parotid swellings as in mumps, and tumefactions in the floor of the mouth. As the lacrimal and salivary glands are usually affected in pairs, the symmetrical character of their development should be emphasized as a diagnostic sign.

A differential diagnosis must be made between lymphoma and the glandular swellings of leucemia and pseudo-leucemia. The freedom from the hemic dyscrasiæ of the latter lesions, the non-participation of other lymph-glands, and the absence of enlarged spleen, liver, or kidneys should decide the diagnosis in favor of lymphoma. Physical weakness, emaciation, and pyrexia are seldom present in a case of lymphoma, while total extirpation of the glands is not followed by recurrence. Enlarged tonsils are usually antecedent, and not developed synchronously, as may happen in pseudo-leucemia. Petechia, hemorrhage, and edema are also manifestations of the latter disease. In the opinion of v. Brunn, there is no reason for segregating diseases that are only differentiated by degrees. He believes that

leucocytic infiltration of these glands is the first stage, leucemia the second stage, and pseudo-leucemia the final stage of one continuous pathological process. This extreme view, however, is hardly sustained by the recorded facts, although there is some ground for his belief. We know that the blood-picture presented by these radically divergent diseases, may vary from normal to almost complete disorganization. And yet the enlarged lacrimal and salivary glands seen in leucemia and pseudo-leucemia show but little difference, either clinically or histologically, from the true lymphomata of Mikulicz's disease. The well-known cases reported by Dunn and Derby typically illustrate the similarity of the facial characteristics. In fact, there are those who assert that a typical case of Mikulicz's disease can occur synchronously with these hemic disorders, and, as it were, independent of them.

The malignant neoplasms may also complicate the diagnosis, especially lymphosarcoma. The microscopic examination of these glands has proved to be unreliable in several of the cases reported, the subsequent involution demonstrating the benign character of the tumor. This was notably true in Adler's case, where arsenic caused complete retrogression, in Mikulicz's case, where the unoperated tumors underwent resolution, and in the case of Frost, where one lacrimal gland was extirpated and the other disappeared spontaneously and permanently while awaiting the microscopic report of "sarcoma." Lymphosarcoma may or may not be bilateral, and is rarely primary in this location. It rapidly invades the surrounding tissues, spreads by metastasis, and when extirpated quickly recurs. Superficial cutaneous varicosities may form, and the skin may adhere and ulcerate. Carcinoma occurs but seldom, and is generally secondary to some initial growth elsewhere. It is usually non-symmetrical, invades the surrounding tissues, and is accompanied by pain and cachexia.

Tuberculous adenitis can generally be excluded by Koch's tuberculin test. As a rule, the attack is not bilateral and

other foci of infection may be found. Sooner or later there is a tendency to periadenitis, and suppuration may develop. Syphilitic adenitis can be differentiated by the history, the symptoms, and the therapeutic test. The glandular swellings may be unilateral. The additional evidence of enlarged cervical, epitrochlear, or inguinal glands will help to confirm the diagnosis.

These two diagnostic possibilities have probably interfered the most with the isolation of this disease. Abadie and DeLapersonne were both dubious about the tuberculous origin of their cases. Osler first inclined to hereditary syphilis in his case, although there was neither interstitial keratitis nor dental notching present. Complete involution of the glands occurred during an intercurrent attack of pleurisy. The patient's death from tuberculosis two years later suggested a tuberculous origin, but the inference could not be substantiated. Posey's case was diagnosed as hereditary syphilis, because it yielded to potassium iodid after a year's treatment. This does not necessarily confirm the diagnosis, as the same drug is useful in Mikulicz's disease. Stieren has reported an interesting case of supposed tubercular dacryoadenitis which his own careful tests showed was absolutely free from tubercular infection. These are all typical examples of Mikulicz's disease, occurring in negroes, and have been included in the reported list.

In rare instances the occurrence of lipoma of the lids has obscured the diagnosis. As both lids are usually involved, and the tumor is not so hard as lymphoma, there should be no difficulty in differentiating this condition.

PROGNOSIS.—The prognosis is favorable, although the course of the disease is very chronic and liable to relapses. Some cases, like those of Adler and Bronner, have required continuous treatment for many years in order to maintain convalescence. Although the swollen glands may cause marked physical discomfort, no fatal issue has so far been reported.

TREATMENT.—The therapeutic agents that have been advo-

cated in Mikulicz's disease are arsenic, the iodids, and pilocarpin. Of these, arsenic has had the greatest measure of success, the majority of cases yielding promptly to the internal administration of Fowler's solution. Many patients, however, are intolerant of its use in doses sufficiently large to influence this disease. Mikulicz, Adler, Axenfeld, Fuchs, Kümmel and others have reported success in some cases and failure in others. Bronner records relief in his case, but a relapse when its administration was stopped. Its therapeutic value lies almost wholly in its ability to increase the oxidation of the blood, which, again, would suggest a certain underlying relationship between this disease and leucemia or pseudo-leucemia.

The iodin preparations have been utilized successfully in some cases. Their activity depends upon an alterative effect on the lymphatic system, which in turn tends to increase the oxidizing power of the blood. Haltenhoff, Reymond, Horner, Scheffels and others report success in their cases from the use of iodid of potassium, and from syr. ferri iodid., the latter having been administered to children. Lugol's solution should exert the same specific action in this disease that it yields in exophthalmic goiter.

Pilocarpin has been employed by Mikulicz and others, but without marked success, notwithstanding the fact that it possesses a decided lymphagogue effect. Although apparently not as valuable as other remedies have proved to be, it should still be kept in mind as a therapeutic reserve.

In this connection the administration of thyroid extract in small doses (gr.j to v, t.i.d.) should prove to be a most valuable therapeutic suggestion, as the disturbance in metabolism, the suboxidation, and the katabolic stasis, all indicate the employment of such a remedy.

The tentative suggestion of Kümmel, that since intercurrent diseases cause retrogression of the enlarged glands it might be advisable to make an inoculation of such a disease for its therapeutic effect, does not merit our approval, as these results have

not been permanent. All such cases of involution have shown recrudescence soon after convalescence was established, except those in which death intervened.

The application of the *x*-rays has had a moderate degree of success in some cases. Fittig, v. Brunn, Ranzi, and Pfeiffer have recorded good results from their use, while Cutler has noted their failure. Like arsenic, therefore, the *x*-rays are useful in some cases, and of no value in others. I will quote Ranzi's views on this subject: "Next to internal medicines, we possess in the *x*-rays an efficient remedy for the reduction of the gland tumors, as our case shows. This applies particularly to the parotids, where, as previously mentioned in the history, operative measures are contraindicated. A favorable influence of the *x*-rays on the salivary and lacrimal gland tumors of Mikulicz's disease has previously been mentioned in only one case (Fittig). In the case treated by v. Brunn, complicated with pseudo-leucemia, the enlarged lymph-glands were reduced to half their size by the *x*-rays, but an irradiation of the salivary gland tumors was not attempted. It is not to be expected that the retrogression caused by the *x*-rays means a lasting cure; in the course of years there were repeated small relapses in our case. But it always happened that the same shrinkage again occurred after short séances. This intense effect of the *x*-rays on the described tumors corresponds entirely with their histological composition. We know, through the experiments of Heinecke on animals, as well as through the clinical knowledge of leucemia, that the *x*-rays possess an elective action on the lymphatic tissues, and that very small doses lead to greater destruction of the lymphocytes. In the same way also in cases of Mikulicz's disease (which in their essentials resemble a local hyperplasia of the lymphatic tissues occurring normally in the salivary glands) the prompt involution of the gland tumors through irradiation can be explained."

Operative measures may be indicated in certain isolated cases. Extirpation of the enlarged glands has been practised by many,

including Mikulicz, Kümmel, Gayet, and others, but not with any degree of success. Partial excision has been followed by renewed growth in the remaining portion, while total extirpation has been successful in preventing recurrence only because all glandular elements have been removed. The remaining glands have shown a more rapid growth on this account. We should bear in mind the important fact that the total destruction of these glandular functions may bring discomfort and possible disaster to the patient. On the other hand, if the glands are so large that their encroachment is distinctly harmful, then they must be extirpated. This, however, should only be considered as a *dernier ressort*. The operation of extirpation, especially of the parotids, is a difficult one, and often attended with considerable danger.

As previously pointed out, the usual treatment of this disease has for its objective aim the stimulation of lymphatic action and the increase of systemic oxidation. The correction of all obstructive respiratory lesions is, therefore, a therapeutic suggestion distinctly in line with this purpose. The fortunate results in my cases demonstrated this fact beyond a doubt. Respiratory obstructions should, on this account, be removed with promptness and good judgment, so that free nasal breathing may be quickly reëstablished. Restoration of this physiological function tends to increase systemic oxidation, to encourage the evaporation of sinus secretions by the mechanical passage of the inspired air through the upper chambers of the nose, and to promote free drainage of the antrum. These retained fluids, as we have seen, may become either a nidus of bacterial infection or a cesspool of toxic secretions. Enlarged tonsils and adenoids should, therefore, be promptly removed, and swollen inferior turbinates should be reduced by linear cauterization, while obstruction of the upper air-passage by a flabby or enlarged middle turbinate should call for its early excision.

RECAPITULATION.

In closing I desire to emphasize a few of the more important points by giving a brief résumé of the statements recorded in the paper.

1. Careful differentiation of the symptom-complex described by Mikulicz demonstrates that this disease is a pathological entity, *sui generis*, and not associated with any systemic disease.

2. The syndrome of symmetrical enlargement of the lacrimal and salivary glands is sufficiently characteristic to be accepted as pathognomonic of Mikulicz's disease.

3. The enormous lymph-cell infiltration into the interstitial tissue, and the relative passivity of the gland structure, demand that this tumefaction shall be classed as true lymphoma or lymph tumor, as distinguished from adenoma or tumor of the glandular substance.

4. As no specific bacteria have been discovered, either in the glands or in the blood, the pathogenesis is probably chemotactic, thus causing a localized toxic hyperleucocytosis in the affected glands.

5. Toxic fluids that are chemically irritating are probably absorbed from the accessory sinuses (chiefly antrum) and transmitted through the lymphatic capillaries to these contiguous glands.

6. Respiratory obstruction not only hinders the evaporation and drainage of these sinus secretions, but also causes suboxidation and other disturbances of metabolism. It should, therefore, be considered a true etiologic factor.

7. The diagnosis of tuberculous adenitis and of lymphosarcoma has been repeatedly proven wrong by the spontaneous involution of the lymphomatous glands.

8. The glandular enlargements of leucemia, pseudo-leucemia, syphilis, lipoma and carcinoma are so characteristic that they should easily be differentiated.

9. The course of Mikulicz's disease is chronic, but the prognosis is favorable, with a tendency to relapse.

10. The treatment aims to improve lymphatic action and systemic oxidation. Arsenic, the iodids, pilocarpin, thyroid extract, and the *x*-rays have each shown some field of usefulness. All respiratory obstructions must be promptly and thoroughly removed. Extirpation is rarely indicated.

BIBLIOGRAPHY.

1. Abadie: Tumeurs rares symetr. des paup. (Archiv. d'Ophtal., 1881, T. i, p. 432.)
2. Arnold und Becker: Doppelseit. symmetr. gelegen. lymphadenom d. Orbita. (Graefe's Archiv., 1872, Bd. 18, ii, p. 56.)
3. Axenfeld: Zur Lymphombildung in d. Orbita. (Graefe's Archiv., 1891, Bd. 37, iv, p. 102.)
4. Baas: Ein Fall v. symmetr. Geschwülsten d. Thränendr. (Zeitschr. f. Augenheilk., 1903, Bd. 10, p. 184.)
5. Baquis: Il trachoma della glandula lacrimale. (Annali di Ottalmol., 1894, p. 227.
6. Berl: Pseudoleukäm. Erk. d. Bindehaut u. d. Orbitalgeweb. (Beiträge z. Augenheilk., 1899, Bd. 37, p. 498.)
7. Berlin: Zur Pathol. und Anat. d. Thränendr. (Wurttemb. Korr-blatt, 1878, p. 249.)
8. Bock: Zur Kenntnis d. gesund u. krank. Thränendr. (Wien, 1896.)
9. Boerma: Ueber einen Fall v. symmetr. Lymphom. in d. Orbita. (Graefe's Archiv., 1894, Bd. 40, iv, p. 219.)
10. Brailey: Discussion of Juler's case. (Trans. Oph. Soc. of U. K., 1892, p. 46.)
11. Bronner: Lymphoma of eyelids cured by arsenic. (Trans. 8th Int. Oph. Cong., 1894, p. 202.)
12. v. Brunn: Die symmetr. Schwellung d. Thränen- u. Mundspeicheldr. (Bruns' Beiträge, 1905, Bd. 45, ii, p. 225.)
13. Caspary: Ein fall v. Mikuliczscher Krankheit. (Deutsch. med. Woch., 1905, p. 444.)
14. Coppez: Cinq cas de tumeurs et pseudoteum. de la glande lacrymale. (Archiv. d'Ophtal., 1903, p. 348.)
15. Cutler: Symmetrical enlargement of parotid and lacrymal glands. (Trans. Am. Oph. Soc., 1904, p. 390.)
16. Debierre: Un case de tumefac. symmetr. d. glandes lacrym. et parotid. (Revue Gen. d'Ophtal., 1893, T. 12, p. 433.)
17. Delens: Observation de tumeurs lymphad. des deux orbites. (Archiv. d'Ophtal., 1887, T. 6, p. 154.)
18. Derby: Hodgkin's disease, with tumors of both lacrymal glands. (Med. News, 1882, vol. ii, p. 681.)

19. Dunn: Leukemia with rare lymphoid growths of orbits and parotid glands. (Am. Jour. Med. Sci., Mar., 1894, p. 285.)
20. vanDuyse: Tuberculose attenuée glande lacrymale. (Archiv. d'Ophtal., 1896, p. 554.)
21. vanDuyse: Contrib. a l'étude d. tumeurs symetr. lymphom., pseudo-leucém. d. glandes lacrymal. et saliv. (Archiv. d'Ophtal., Dec., 1905, p. 705.)
22. Fittig: Röntgenbestrahlung e. Fälles v. Symmetr. Erk. d. Parotis, (Allg. med. Centralzeit., 1904, p. 606.)
23. Fleischer: Ein Fall v. eigentüm. symmetr. Thränen-u. Ohrspeicheldrüsenschwellung. (Klin. Monatsbl. f. Augenh., 1902, Bd. 1, p. 398.)
24. Förster: Symmetr. Tumor an der Thränendrüsen.
25. Fröhlich: Ein seltener fall von Pseudoleukämie. (Wiener med. Woch., 1893, p. 285.)
26. Frost: Chronic enlargement of both lacrimal glands. (Trans. Oph. Soc. of U. K., 1887, p. 112.)
27. Fuchs: Gleichzeit. Erk. d. Thränendr. u. d. Parotiden. (Deutschmann's Beiträge, 1891, Bd. 3, p. 208.)
28. Galezowski: Inflammation des deux glandes lacrymales. (Recueil d'Ophtal., 1886, p. 415.)
29. Gallasch: Ein seltener Befund bei leukämie im Kindesalter. (Jahrbuch f. Kinderheil., 1874, Bd. 7, p. 82.)
30. Gayet: Sur les tumeurs symmetr. des deux orbites et leur caract. symptomat. (Archiv. d'Ophtal., 1887, T. 6, p. 15.)
31. Goldzieher: Das lymphom der Conjunctiva. (Wiener med. Woch., 1893, p. 1366.)
32. Goldzieher: Beitrag z. Kenntnis d. symmetr. Orbitaltumoren. (Zeitsch. f. Augenheilk, 1902, Bd. 7, p. 9.)
33. Griffith: Some cases of orbital growth, Case III. (Trans. Oph. Soc. of U. K., 1894, p. 175.)
34. Gutman: Mikuliczsche Krankheit in ihrer Beziehg. z. Lues. (Berliner klin. Woch., 1907, p. 1141.)
35. Haeckel: Beitrag z, Kenntnis d. symmetr. Erk. d. Thränen-u. Mundspeicheldr. (Langenbeck's Archiv., 1903, Bd. 69, p. 191.)
36. Hähnle: Zwei fälle v. Thränendrüsentumoren. (Oph. Klinik, Nr. 24, 1900.)
37. Haltenhoff: Hyperplasie lymphat. d. glandes lacrym. et saliv. (Annal. d'Oculist., 1889, T. 102, p. 110.)
38. Hanau: Ueber d. ensteh. d. eiterig. Entzünd. d. Speicheldr. (Beiträge z. Path. Anat. von Ziegler, 1889, iv, p. 487.)
39. Hirsch: Ein weit. Beitrag z. lehre v. d. symmetr. Erk. d. Thränen-u. Mundspeicheldr. (Mitteil. a. d. Grenzgeb. d. Med. u. Chir., 1898, Bd. 3, p. 381.)
40. Hirschberg: Mumps der Thränendrüsen. (Centralbl. f. Augenheilk., 1890, p. 77.)

41. Hochheim: Ein Beitrag z. Kenntnis d. Symmetr. Lid-u. Orbitaltumoren. (Graefe's Archiv., 1900, Bd. 51, p. 347.)
42. Hofmeister: Discussion of Ranzi's Case. (Centralbl. f. Chir., 1905, p. 1358.)
43. Horner: Entzündung beider Thränendr. (Zehender's Klin. Monatsbl., 1866, p. 257.)
44. Juler: Symmetrical tumors of both orbits. (Trans. Oph. Soc. of U. K., 1892, p. 44.)
45. Korn: Doppelseitige Thränendr. Entzündung. (Klin. Monatsbl. f. Augenh., 1869, p. 181.)
46. Kümmel: Weit. Beiträge z. Lehre v. d. symmetr. Erk. d. Thränen-u. Mundspeicheldr. (Mitteil. a. d. Grenzgeb. d. Med. u. Chir., 1897, Bd. 2, p. 111.)
47. Lagrange: (Revue generale d'Ophtal., 1900, p. 329.)
48. DeLapersonne: Tuberculose probable de la glande lacrymale. (Archiv. d'Ophtal., 1892, T. 12, p. 211.)
49. Leber: Ueber e. selten. Befund v. Leukämie m. gross. leuk. Tumoren. (Graefe's Archiv., 1878, Bd. 24, i. p. 295.)
50. Maklakow: Dacryoadenitis. (Ophthal. Klinik, 1901, p. 355.)
51. Marcuse: Ein Fall v. Mikuliczscher Krankheit. (Berliner klin. Woch., 1904, p. 1205.)
52. McHardy: Discussion of Power's Case. (Trans. Oph. Soc. of U. K., 1887, p. 109.)
53. Meller: Ueber d. Beziehung d. Mikuliczscher Krankheit u. Chron. entz. prozess. (Monatsbl. f. Augenheilk., 1906, ii, p. 177.)
54. Meller: Ueber d. Beteilig. d. Orbita u. d. Aug. a. d. lymphom prozess. (Zeitsch. f. Augenheilk, 1906, p. 358.)
55. Michel: Neubildungen, Fall xviii. (Graefe's Archiv., 1881, Bd. 27, ii, p. 257.)
56. Mikulicz: Verein f. wissenschaftl. Heilkunde z. Königsberg. (Berliner klin. Woch., 1888, p. 759.)
57. Mikulicz: Ueber e. eigenart. symmetr. Erk. d. Thränen-u. Mundspeicheldr. (Beiträge z. Chir., Festschrift d. Billroth., 1892, p. 610.)
58. Millee et Vidaur: Double dacryadénite avec iritis double. (Le Progres Medical, 1902, T. 16, Oct. 25, p. 257.)
59. Osler: Chronic symmetrical enlargement of the lacrimal and salivary glands. (Amer. Jour. Med. Sci., Jan., 1898, p. 27.)
60. Osterwald: Neuer Fall v. Leukämie m. doppelseit. Exophthal. d. Orbitaltumoren. (Graefe's Archiv., 1881, Bd. 27, iii, p. 203.)
61. Pause: Zwei weit. Fälle v. Thränendrüsentumoren. (Oph. Klinik, Nr. 20. 1901, p. 305.)
62. Pfeiffer: Röntgentherapie d. symmetr. Thränen-u. Speicheldr. Erk. (Bruns' Beiträge, 1906, Bd. 50, Heft i, p. 245.)
63. Pick: Beiträge z. d. Thränendrüsentumoren. (Centralb. f. Augenheilk., 1896, p. 97.)

64. Pollack: Sogenannte Mikuliczsche Krankheit. (Zeitschrif. f. Augenheilk., 1905, Bd. 14, p. 71.)
65. Posey: Chronic dacryoadenitis, bilateral. (Philada. Med. Jour., April 26, 1902.)
66. Power: Hypertrophy of right lacrimal gland, left removed for same condition. (Trans. Oph. Soc. of U. K., 1887, p. 109.)
67. Quincke: Sitzung d. Physiol. Vereins z. Kiel. (Münch. med. Woch., 1906, Nr. I, p. 47.)
68. Randolph: Bilateral, non-suppurative dacryoadenitis. (Archives of Ophthal., 1897, vol. 26, p. 63.)
69. Randolph: A case of Mikulicz's disease. (Ophthal. Record, Jan., 1909, p. 18.)
70. Ranzi: Ueber e. m. Röntgenbestrahl. behandelt. Fall v. Mikuliczscher Krankheit. (Mitteil a. d. Grenzgeb. d. Med. u. Chir., 1906, Bd. 16, p. 554.)
71. von Reuss: (Wiener med. Presse, 1885, Nr. 52.)
72. Reymond: Linfomi volumineux delle due orbite. (Annali di Ottalmologia, 1883, T. 12, p. 337.)
73. Reymond: Lymphomes volumineux developpes dans les deux orbites. (Archiv. d'Ophtal., 1887, T. 6, p. 23.)
74. Rollet: Lymphome bilat. d. glandes lacrymales. (Trans. 10th Int. Oph. Cong., 1904.)
75. Sandford: Enlargement of both lacrimal glands. (Trans. Oph. Soc. of U. K., 1893, p. 22.)
76. Scheffels: Ein Fall v. acuter doppelseitige Thränendrüsenentzündung. (Centralbl. f. Augenheilk., 1890, p. 136.)
77. Schirmer: Entzündung d. Thränendrüsen (dacryoadenitis). (Graefe-Saemisch, 1877, Bd. 70, Heft 5, p. 5.)
78. Senator: Mikuliczscher Krankheit m. Chlorom. u. Lymphat. Leukämie. (Med. Zentralzeit., 1907, Nr. 34.)
79. Shoemaker: Bilateral enlargement of the lacrimal glands. (Annals of Ophthal., July, 1904, p. 513.)
80. Silcock: Discussion of Juler's case. (Trans. Oph. Soc. of U. K., 1892, p. 47.)
81. Snegireff: Ueber doppelseit. gleichzeit. Erk. d. Thränen-u. Speicheldr. (Klin. Monatsbl. f. Augenheilk., 1906, Beilage, p. 142.)
82. Snell: A case of symmetrical dacryoadenitis. (Trans. Oph. Soc. of U. K., 1892, p. 51.)
83. Sporleder: Ueber e. Fall v. symmetr. Lymphom. d. orbita. (Dissertat., Leipzig, 1897.)
84. Stieren: Tubercular dacryoadenitis and conjunctivitis. (Johns Hopkins Hosp. Bull., Nov., 1901, p. 349.)
85. Stock: Ueber Augenveränder. b. Leukäm. u. pseudoleukäm. (Klin. Monatsbl. f. Augenheilk., 1906, Bd. i, p 328.)
86. Stöwer: Ein Beitrag z. Pathologie d. Thränendr. (Münch. med. Woch., 1901, p. 177.)

87. Terrien: Hypertrophie et déplace. d. l. glande lacrymale. (Soc. d'Ophtal. de Paris, July 2, 1901.)
88. Tietze: Beitrag z. lehre v. d. symmetr. Erk. d. Thränen-u. Mundspeicheldr. (Bruns' Beiträge, 1896, Bd. 16, p. 816.)
89. Verhoeff: The mixed tumors of the lacrymal and salivary glands. (Jour. Med. Res., 1905, p. 319.)
90. Wallenfang: Beitrag. z. lehre v. d. symmetr. Erk. d. Thränen-u. Mundspeicheldr. (Virchow's Archiv., 1904, Bd. 176, p. 90.)
91. Walton: Diseases of the lacrimal gland and its ducts. (Med. Times and Gaz., Jan.–June, 1854, p. 317.)
92. Warthin: Endothelioma of lachrymal glands, with analysis of lachrymal gland tumors. (Archives of Ophthal., 1901, p. 601.)
93. DeWecker et Masselon: Tumeurs symetr. des glandes lacrymal. palp. et des parotids. (Archiv. d'Ophtal., 1892, T. 12, p. 65.)
94. Ziegler: Bilateral lymphomata of the lacrimal, parotid and submaxillary glands. (Annals of Ophthal. Jan., 1906, p. 72.)
95. Zirm: Ein Fall v. gleichzeit. chron. Thränendr. u. Parotidenschwellung. (Wiener med. Presse, 1891, p. 1954, und Deutschmann's Beiträge, 1893, iv, p. 314.)

DISCUSSION.

DR. C. W. CUTLER, New York: I reported a case of this disease in 1904, and have not seen a case like it since. Certain enlargements of the lacrimal gland or of the parotids alone may belong to the same class. It may not be necessary to await the appearance of the entire group of symptoms before making the diagnosis of Mikulicz's disease.

In the case I reported there were nodules in the iris, which has not been noted in any of the other reported cases, so far as I am aware. If the modern methods of tubercular diagnosis had been in vogue at that time, I should have employed them. As I remember the appearance now, it seems possible that that would have been the diagnosis of the condition of the iris, but the resemblance of my case to that described by Michel,* in which a microscopic examination of the iris nodules permitted a diagnosis of pseudo-leukemia, inclined me to make a similar provisional diagnosis. The only treatment which was of any value was arsenic, under which the condition greatly improved.

DR. WM. C. POSEY, Philadelphia: Dr. Ziegler has been kind enough to include in his report the case of a negro boy I saw in 1902. This boy showed bilateral and symmetrical involvement

*Von Graefe's Archiv, Bd. xxvii, II, p. 256.

of both glands. There were no other symptoms, and because of lack of any other etiological factor I put him on the iodides in large doses, for six months, but without inducing any change in the character of the swellings. The patient passed from observation, without treatment, for a year, but when seen at the end of that time, the swellings had disappeared.

DR. S. LEWIS ZIEGLER, Philadelphia: I have recently had another case of Mikulicz's disease, somewhat like the one referred to by Dr. Cutler, in a patient of the mixed negro and Indian type. This patient had bilateral involvement of the accessory glands only, both lacrimal and parotids, as is shown in the photographs. He had complicating iritis in the left eye, and in the stroma of the iris there were small nodules, such as Dr. Cutler describes, and a deposit on Descemet's membrane, which, though it had the pyramidal appearance of that of serous iritis, was of a different character. It was a curious sort of yellowish exudate deposited on Descemet's membrane to an extent that gave evidence of considerable thickness. There was also an exudate in the lower part of the anterior chamber at one time, but this has since disappeared. It resembled that seen in gelatinoid iritis. The lesion was non-tubercular, as shown by tests. The duration was six months. There was some nasa obstruction. The tonsils were not enlarged. As the case was one of marked metabolic disturbance, I adopted my own therapeutic suggestion and put him on thyroid extract. He has shown just as remarkable improvement as the other cases did. He has been under this treatment for about six weeks.

A CASE OF COMPLETE ALBINISM: OBSERVATIONS ON THE CHANGES IN THE DIAMETERS OF THE LENS AS SEEN THROUGH THE IRIS.*

GEORGE F. LIBBY, M.D.,
Denver, Colo.

The noteworthy investigations of albinism by Nettleship and Pearson, and by Lagleyze, and the reports of individual cases by scattered observers, make it seem worth while to record this case. The interesting speculations by Sisson and C. E. Woodruff on the ocular effects of the short wave light rays, especially in countries where excessive sunshine prevails, and Woodruff's recent suggestion of using amber-tinted lenses to shut out those rays, further justify a description of this Colorado albino child and the effect of such lenses upon her distressing photophobia, for the past year and a half. The pupillary reflexes in irides wholly devoid of pigment and largely so of stroma seem worthy of remark; while the novel opportunity of making measurements of the lens diameters with the ciliary muscle in action and at rest lends interest, if not importance, to this report.

H. D. C., a girl of three years and eight months, was brought for examination October 18, 1907. Her mother and aunt stated that at birth the child's hair was silver gray, and had become snow white in nine months, at which time they noticed a low, alternating, convergent squint, which had come and gone ever since. Photophobia had been constant, and vision much depreciated; small objects like pins not being visible, and all things being held close in the effort to see. Her health had been and was still excellent, and her mind bright and active. She was an only child; the mother being rather dark, the father reported to be

* Shown before the Colorado Ophthalmological Society, Oct. 19, 1907

"very fair, with brown hair, blue eyes, and white eyebrows and lashes." The mother had experienced no miscarriages. Neither the intermarrying of relatives nor any case of complete or incomplete albinism was ascertainable as far as the family history was known, for four generations, unless the father's "white" (described later as "pale yellow") eyebrows and lashes could be taken as a partial albinotic manifestation.

Examination showed a pink skin, white hair on scalp, brows and lids, light blue irides, photophobia, lateral nystagmus, which was rarely absent, and alternating strabismus, with 2 to 3 mm. of esotropia. There was absence of the uveal pigment, the red reflex of the choroid showing through both iris and sclera, causing the iris to look pink in daylight and giving a firelight glow through pupil, iris and sclera when the interior of the eyes was illumined in the dark room. Each iris was very thin, only the sphincter pupillae and scattered radiating fibers showing. Through the thinned irides the entire circumference of the lens margin could be plainly seen.

Under cycloplegia from homatropin, enforced by atropin, skiascopy revealed mixed astigmatism of 4. D. in each eye. Full correction was prescribed, as follows: R. and L.—2. sph. ⊂+ 4. cyl. ax. 80°, ground in amber glass, shade of number 2 smoke. Under their use vision greatly improved at once, the photophobia disappeared immediately, and the nystagmus and squint were reported to be much lessened at the end of one month, and also after two months had elapsed.

The following measurements of the pupils were taken on different days. Under $\frac{1}{20}\%$ eserin, 1.5 mm; in bright light, 2 mm; in a darkened room, 4 to 4.5 mm; under $1\frac{1}{4}\%$ homatropin hydrobromat, 5.5 mm., and with 1% atropin sulphat, 6 mm.

Because of the thin irides the unique opportunity was afforded of making accurate measurements of the lens in moderate and in extreme accommodation, and under full cycloplegia. With the eyes accommodating at 40 cm., the transverse diameter of the lens was 9.5 mm. Two hours after the instillation of $\frac{1}{20}\%$

eserin it was 9 mm., and two hours after the use of 1% atropin it measured 10 mm.

A 10. D. spherical lens held 10 cm. in front of the cornea, was used in taking these diameters. Dr. Edward Jackson verified and concurred in these measurements of the lens diameters, the pupils and the refraction.

Under date of April 19, 1909, the child's mother wrote that improvement in vision continued and the disappearance of the photophobia remained unchanged, but that the nystagmus had returned and the squint had become fixed in the right eye. Thereupon remeasurement of the refraction was advised, in the hope that the squint and nystagmus might again be benefited, and the vision further increased, by the correction of a new development in the ametropia.

DISCUSSION.

DR. SAMUEL THEOBALD, Baltimore: The case is especially interesting, it seems to me, because of the transparency of the irides. I have not, I believe, seen any case of albinism where it was possible to distinguish the outlines of the lens through the irides even with the ophthalmoscopic mirror.

I recall one case of albinism in a negro, which is, I think, exceptionally rare.

DR. LIBBY: The outlines of the lens could be seen with the naked eye, without the aid of the ophthalmoscope.

Right
eye

Left
eye.

A case of double coloboma of the macula.

A CASE OF BILATERAL MACULAR COLOBOMA.

HOWARD F. HANSELL, M.D.,

Philadelphia.

A boy of eight years of age was admitted to the Jefferson Hospital in December, 1908, on account of defective vision, internal strabismus, and nystagmus. In the macular region and involving the fovea in each eye was a nearly circular patch, about three times the area of the disc and practically symmetrical in the two eyes, surrounded by sharply cut pigmented borders, traversed by one or two retinal vessels, and yellowish white in color, and containing a few blotches of pigment. The optic discs were pale and cupped, the blood-vessels and those of the retina rather smaller than usual. Central vision was abolished, and peripheral vision could not be accurately determined. The remaining parts of the eyes were normal, with the exception of the refraction, which was mixed astigmatism, the prevailing defect hyperopic. There was a moderate degree of internal squint and marked horizontal nystagmus. The head of the boy was larger than the average for his age, and the forehead projecting. He had no other physical deformity. His mind was clear and acute and his body well developed. He was not the child of blood-related parents, and the family has no history of ocular defects or diseases.

The article on colobomata in Parsons' "Pathology," vol. iii, is complete and recent, so that a review of the literature is unnecessary. He says that about forty cases of macular coloboma have been reported, of which seven are bilateral. If future reporters would note the still dubious points in the appearance of the coloboma, such as shape, size, vessels, field defects and refraction, and the family histories and the presence of other defects, clinical data would be collected which would be of value in the further investigation of the subject.

HEMORRHAGIC CENTRAL CHORIORETINITIS IN NON-MYOPIC EYES: A CLINICAL CONTRIBUTION.

CHARLES J. KIPP, M.D.,

Newark, N. J.

The disease to which I wish to call your attention is doubtless well known to all of you, but as no adequate description of it is to be found in any of the text-books with which I am familiar, I have thought it worth while to write out what I have learned of it from clinical observation, and to this have added what I have been able to find out about it in the writing of others.

Loring probably refers to this disease in his "Text-book of Ophthalmoscopy," vol. ii, p. 138, when he says: "Not infrequently in myopic and occasionally in other eyes there occurs a peculiar form of retinitis right at the macula lutea that would seem not only to be in the outer layers of the retina, but also in the pigment layers itself—as if, indeed, exactly at this spot there had been a development of pigment, a sort of hypertrophy of the pigment cell, a pigmentitis, if such a word can be used. This then shows itself by a collection of pigment at and around the fovea, accompanied by little or no other inflammatory symptoms. The pigment is usually collected in a circular mass of greater or lesser density, or it may present a reticulated shape similar to that of the coarser forms of black lace.

"It has usually been assumed that this pigment was the result of a preceding hemorrhage, from the fact that, with inflammation of the retina, we sometimes find, especially in myopic eyes, hemorrhage associated with the pigment changes. . . . The inflammation may, as it often does, extend to the choroid, and then we have the appearance of a spot, chorioretinal disease with choroidal exudation or atrophy and the lustrous surface of the sclera."

Th. Leber* refers to this disease at the end of the paper from which this is quoted: "Additionally, I may mention here also another form of hemorrhagic chorioretinitis which has its seat in the macular region; it is observed also in non-myopic eyes and is characterized by a marked resistance to treatment and by the frequency of relapses. I have not treated of it more fully here, because the extravasations, which are mostly small, are usually situated in the area of the choroidal foci themselves, and therefore impress one as having their source in the vessels of the choroid rather than those of the retina. This cannot, however, always be determined by the ophthalmoscopic examination. I have in the course of time seen a series of cases of this affection, in part with and in part without syphilitic antecedents, and have encountered a very marked resistance to treatment, whether it consisted of mercurial or other remedies continued for a long period."

C. Schweiger† has this to say about the affection: "There is a choroiditis of the macula lutea which makes its appearance in the form of a circumscribed disease focus of about the size of the diameter of the disc. In the region of the macula is seen a grayish spot, surrounded by a hemorrhage. In the course of a few months the blood is absorbed, the grayish spot becomes fringed by black pigment, and sometimes black pigment is also developed on its surface. The impairment of vision is considerable from the first, and it consists of metamorphopsia and a positive scotoma, which, according to the site of the exudation, covers sometimes the point of fixation, at other times a point very near it. . . . This form of choroiditis occurs more frequently in connection with myopia, but is observed also in non-myopic eyes."

I have been unable to find other references to this disease.

* "Ueber das Zusammentreffen von disseminiter Choroiditis und hemorrhagischer Retinitis oder Netzhaut blutungen am gleichen Auge," Festschrift zur Feier des siebzigsten Geburtstage von Hermann von Helmholtz, Stuttgart, 1891, p. 54.

† "Handbuch der Augenheilkunde," 6th edition, 1893, p. 400.

Personal Observations.—I have seen this condition in persons of different ages, in the young (Cases I, and III) and in the middle-aged (Cases II, IV, V, and VI), in persons in the best of general health without a sign of other disease, in a person with valvular heart disease (Case IV), and in persons who admitted having had syphilis. I have seen it in both sexes. In all of my cases but one eye was affected when the patient came first under my observation, and in most cases the other eye was not attacked while the patients were under observation—a period of over twenty-five years in some cases. In one of my cases the same disease developed in the other eye three years after the first was attacked.

The disease is fortunately not frequently met with. I cannot state in what proportion of all eye cases I have seen it, as the hospital records have been partly lost.

The symptom which brought the patients to me has always been a more or less sudden impairment of vision; usually the patient describes it as a cloud before the eye, or as a distortion of the objects looked at.

The external parts of the eye showed no signs of disease. The media were in most cases perfectly clear; in a few cases a few floating opacities in the vitreous were present; and in one there was, as the result of a previous iridocyclitis, great cloudiness of the vitreous with large floating flakes in it (Case V). In not one of the cases have I seen a deposit of precipitates on Descemet's membrane. The optic papilla was in all cases clearly defined and of natural color, and the retinal blood-vessels were normal in caliber. The retina was transparent everywhere except at the macula lutea, where small, thin extravasations of blood of light color were present. The extravasations seemed to be in the inner layers of the retina. There were more than the usual number of small blood-vessels seen in this region. The choroid in the macular region was of a dark grayish or blackish color, while in other parts it was of the normal red color. In the inverted image the area which appeared dark grayish or blackish,

in the upright image, was of a distinctly dark, greenish hue. Sometimes the discoloration was in the shape of a disc; at other times it appeared as a ring with a reddish area in the center of it. The discolored area was usually of about one-half of the disc's diameter in size.

Subsequently the following changes were observed. The retinal extravasations were slowly absorbed without undergoing changes in color; they were in no instance changed into white plaques. Other extravasations sometimes appeared in the same area during the following months. The darkish area under the retina remained unchanged and underwent but little change in color for many weeks and even months, and then it was gradually converted into a grayish-white patch, which later on became much larger. The grayish patch was seldom of the same color throughout; in some parts it was of a lighter color than in others, and, moreover, it seemed somewhat uneven on its surface. Gradually some pigment spots developed on it, more especially near its margins. Retinal vessels were seen on it, some of which were much larger than those seen in this region in the normal condition. Choroidal vessels were never seen in the grayish region. The picture was not that of a patch of atrophy of the choroid, but rather that of a new tissue formation in or under the retina.

Vision was greatly impaired at the time I first saw the patient, and was found to be due to a central or paracentral scotoma. There were no peripheral defects in the field of vision. In only one case have I seen vision improved under treatment—Case IV.

The impression I got from the examination of cases in their earliest stages. is that the disease is primarily one of the choroid. The changes in the retina visible in the upright image were always very slight; it was transparent, or at least so translucent that the hemorrhage in the choroid was distinctly seen, and the extravasations in the retina were small and thin and always of light red color. The extravasations seemed to me to come from capillaries or to be due to diapedesis. Later in the course of the

disease the outer layers became opaque so as to hide the choroid, but the inner layers remained transparent and the retinal vessels were in no part hidden. New vessels in the retina were usually seen in the diseased area after the case had been under observation for months. The choroid, except in the region of the macula, never showed signs of disease. In the center of the disease focus the choroid appeared of a much darker red color than elsewhere (extravasations of blood?), and the dark-colored area was usually of a round form and in most cases in size less than the disc's diameter. Pigment spots would make their appearance in this area later on, but never to the extent seen in cases of circumscribed plastic chorioretinitis. Months after the patients were first seen this grayish area had extended in all directions, and was often of twice the size of the original dark-colored area. From the fact that no choroidal vessels were visible in the grayish area, even years after the appearance of the disease, I am inclined to the view that in the grayish area the choroid is covered by an exudate, or that the outer layers of the retina have become so opaque as to hide it. I do not remember ever to have seen just such a picture in any other part of the fundus than the region of the macula. Why it should be seen here only, I am unable to explain. Possibly an explanation may be found in the anatomical arrangement of the choroidal blood-vessels in this region. Nuel,* who has studied the condition of the choroidea in the vicinity of the macula lutea, comes to these conclusions: "In the neighborhood of the periphery of the macula the number of capillaries and small vessels is increased progressively, while the vessels of large caliber become increasingly less in number. . . . In the predominance of the veins there exists a favorable preliminary condition for the production of a stasis of the products of inflammation carried through the

* "De la vascularisation de la choroide et de la nutrition de la retina principalement du niveau de la fovea centralis," Archiv d'ophtalmogie, xii, 1892, p. 70; citèd from Curt Cohen, "Aderhautabscess hinter der Macula lutea nach perforirender Zundkapselverletzung," Klinische Monatsblätter f. Augenheilkunde, Juni, 1908, p. 628.

vascular channels to the described region. A retention of the inflammatory products is always brought about by the marked slowing in the blood-stream carrying them, which occurs specially in this critical district. The resistance on the part of the wall of the vessel is, moreover, considerably increased in the macular region, inasmuch as the meshes of the capillary network of the choroidea in this region become decidedly finer than in other parts of the uvea."

In several of my cases I had an opportunity to make an ophthalmoscopic examination a few hours after the visual defect was first noticed, and in a few of these patients I had examined the same eyes some time before the visual defect was noticed and had found the fundus without changes from the normal. In these cases there were always, in addition to the small, thin, light-colored blood extravasations in the transparent or at least translucent retina, changes in the choroid, such as increase in the pigmentation and perhaps a hemorrhage in the membrane visible at the same time. Slight and thin extravasations of blood in the retina, such as are seen in these cases, alone rarely, if ever, cause such great impairment of vision, and therefore we must assume that the outer layers of the retina were involved in, if not destroyed by, the disease when the patients were first seen. According to Ginsberg,* "retinitis of the outer layers is always caused by choroiditis or such processes which have caused a circumscribed or diffuse wasting of the chorio-capillaris; that is, the nutritional area of the non-vascular layers of the retina. . . . . The changes in the retina in chorioretinitis are usually not of an inflammatory but rather of degenerative character, but it is self-evident that, in addition to the process due to the choroidal changes, simultaneously independent inflammatory changes in the outer layers of the retina brought about by the same cause as the choroidal disease, may he present."

Leber† is of the opinion that, in cases of disseminate choroidi-

* Grundriss der pathologischen Histologie des Auges," p. 340.

† Op. Cit.

tis with hemorrhages in the retina, we have to deal with a combination of two separate and independent affections, both of the choroid and the retina, which are due to a common cause, but not with an extension of the disease from one membrane to the other. On the other hand, Amman* thinks that the hemorrhages in the retina in cases of disseminate choroiditis may be the result of an extension of the disease from one membrane to the other, due to the direct contact of the retina with the disease focus in the choroid, by which the retinal vessels in this region undergo inflammatory changes and become either permeable for the blood or a stasis occurs in their peripheral parts.

In the disease under consideration an extension of the morbid process from the choroid to the retina through direct contact, seems to me to be the most plausible explanation for the simultaneous involvement of both membranes.

With regard to the treatment of this affection, I may say that I have tried nearly everything suggested by others, but without improvement to the vision except in Case IV, where, under the treatment for rheumatism, consisting of diaphoretics, a marked improvement followed three years after the commencement of the disease.

I append the histories of six cases, illustrating different phases of the disease.

CASE I.—Chorioretinitis hemorrhagica centralis.

S. W., a girl eleven years of age, was first seen by me April 10, 1882. She complained of pain in her eyes. I found she had a mild form of catarrhal conjunctivitis in both eyes. Both eyes were E., and $V=\frac{6}{6}$. Under the usual treatment the eyes got well in a short time.

I did not see her again till January 13, 1885, nearly three years afterward. At this visit she stated that on this day she had discovered that the right eye was blind. Having a headache, she had leaned her head on her left hand, thereby closing the left eye, and had thus discovered that she was unable to

* Deutschmann's Beiträge, z. prakt. Augenheilkunde, xxxviii, p. 1; cited from Wilbrand u. Sanger, "Neurologie des Auges," iv Band, 1 Haelfte, p. 179.

see with the right eye. Up to this time she had had no trouble with either eye except the slight conjunctivitis for which I had treated her three years before. The girl is of slight build, looks younger than she is, is very lean, has not yet menstruated, but says that she is in good health. Her physician tells me that she is apparently free from disease of any kind; she is not anemic. Her urine is free from albumin and sugar. Her mother is in good health, but, like her daughter, very thin. She is very myopic, 13–14 D. The girl's father is dead. I think he died of pneumonia. The examination of the girl's eyes showed that the left eye was E. V = $\frac{6}{6}$. With exception of a narrow zone of atrophy of choroid around disc, on which some pigment spots are scattered, the fundus is normal. The right eye is blind from a central scotoma. The movements of the globe are unimpaired. The eye is normal in appearance. The pupil is slightly larger than that of the left eye, but is active both to direct and indirect stimulation. The vitreous is perfectly clear. The optic disc is surrounded by a narrow zone of atrophy of choroid on which there are pigment spots. The disc is of normal color and transparency; its outline is distinct. The retina is perfectly clear except at the macula, and the retinal vessels are of normal size and appearance. At the macula the following changes are noted: Around the fovea lutea is a bright reflex of oval form, almost white. At the fovea is a round spot of darkish color; a little above this is a spot of triangular form with rounded angles, which in the inverted image is of a darkish-green color, but in the direct image is of a dark color. Above this triangular spot, as well as below the fovea, there are dark red round spots, apparently of the size of a pin's head and apparently in choroid. A little more below the fovea, close to a small blood-vessel, is a large patch of extravasation of blood in the retina. Otherwise the fundus is normal. The visual field is not contracted.

Three days later I examined the eye again, and found no change except that the reflex over the fovea was much less marked and the extravasations were somewhat lighter in color.

On January 20th she reported that she could see somewhat, and on examination she counted fingers at two feet. The fundus picture had not changed much, but the extravasations were apparently absorbing. The choroid around the fovea was of a deep red color.

The eyes remained in the condition here described for weeks

without change. About the middle of February the girl had an attack of dysentery which confined her to her bed for several weeks. I saw her again on the first of March (six weeks after her first visit). The appearance of fundus had changed as follows: There is now in the center of the macula a round spot of grayish color, about one-half of the diameter of disc in size. This is surrounded by a narrow zone of somewhat lighter color, and outside of this is a broad zone of deep red color. Just below the center of the grayish area is a large blood-clot of bright red color in upper half, and of deep red in lower portion. The central scotoma is larger than before. She is no longer able to count fingers with this eye.

The treatment consisted of rest in bed for the first few weeks. I gave small doses of hyrdarg. c. creta for several weeks, and afterward iodid of potassium. I applied leeches to the right temple, and ordered instillation of a ½ of 1% solution of atropin several times daily. Under this treatment the extravasations were gradually absorbed, and the greater part of the macular region became of lighter color. The choroid in this region was not visible. The retina became transparent again, and retinal vessels are seen over the yellowish-white patch.

During the past twenty-three years I have examined the eyes of this patient from time to time, but have not noted any further changes. She was married five or six years ago, has two children, and is apparently in better health now than she was twenty years ago.

CASE II.—Chorioretinitis hemorrhagica centralis.

Mrs. G., a well-developed woman, thirty-five years of age, married, has one child who has hip disease. She has always been in good health and is so now. Her urine is free from albumin and sugar. She has no symptoms of syphilis. She came to me because she had noticed for a week that the sight of her right eye was impaired. The left eye was normal.

On examination I found that the vision of the right eye was reduced to $\frac{5}{60}$. The V. F. was deficient downward. The eye was free from signs of inflammation; cornea, iris, lens, and vitreous were apparently normal. The fundus showed the following changes: In the choroid, above and outward of the apparently normal disc, were numerous small, round, pinkish spots and an irregular distribution of pigment. At the macula

there were a few pinkish round spots, and here also the pigment was unequally distributed. The retina was quite clear and the retinal vessels were normal. I prescribed small doses of bichlorid of mercury, instillations of atropin, and leeches to the temple. Six days later I noticed a dark spot, not quite as large as the disc, at the macula, and in the retina in front of this dark area an extravasation of blood. In the inverted image the dark area was of a dark greenish color. There were no other changes in the retina.

I did not see the patient again till February 28, 1888 (fourteen months after her last visit). The eye now presented the following appearance: The disc is whitish, outline well defined. Just below fovea is white area, in size about two diameters of the disc; the margins of this opaque spot fade gradually into the red choroid. A short distance from the outer margin of this area there are a number of white lines running toward the periphery such as are seen occasionally in the retinitis albuminurica. At the middle of the macula the retina is transparent, but under it are a number of dark spots with ill-defined outlines. Over the dark spots the retinal vessels are very distinct.

The patient came to me on this occasion because she had suffered from severe pain in the orbit and occiput for weeks. Has now pain in the left brow and left half of the upper part of the head. I was unable to discover an abnormal condition in the left eye, and attributed the pain to disease of the ethmoidal cells, for the treatment of which I sent her elsewhere.

Eight months after this last visit I saw her again. She had had many attacks of amaurosis fugax. The attacks were followed by vomiting and severe headache (migraine). She asserted that she had had as many as three attacks in one day. I found the left eye as good as ever, but prescribed glasses for her presbyopia. In the right eye there was now seen, in addition to the changes above described, below the atrophic area, a pinkish spot, about one-half diameter of disc in size and surrounded by an almost black ring. The eye was blind. In 1891 I had another opportunity to examine this patient's eyes, but found no change from the last examination.

CASE III.—Chorioretinitis hemorrhagica centralis.

W. W. W., a well-developed, healthy looking girl, fifteen years of age, came to me March 23, 1903, with the statement

that the vision of her right eye was much impaired for three weeks. I found that the left eye was perfectly normal in every respect and V = $\frac{6}{6}$ The right eye was blind from central scotoma. The ophthalmoscope showed the refraction to be emmetropic; a few floating opacities in the vitreous. The disc was normal as also were the retinal vessels. At the macula the choroid appeared of much darker color than elsewhere, and in the retina in front of this dark area was a light colored extravasation of blood. The extravasation had the form of a ring with a piece cut out above. Otherwise the retina was perfectly transparent.

A most thorough examination of this young woman by experienced physicians failed to discover disease of any other part of the body. The urine was free from albumin and sugar. I ordered leeches to the temple and gave iodid of potassium in small doses.

She returned a month later, when I found that the extravasation at the macula had almost entirely disappeared. The dark area beneath the retina had not changed in appearance. She was blind in this eye. Since then I have not seen the patient.

CASE IV.—Chorioretinitis hemorrhagica centralis in both eyes.

N. W., a tall, slender man, thirty-four years of age, was first seen by me in February, 1905. He stated that for the last four months objects seemed distorted to the left eye. The vision of the right eye was unimpaired.

On examination I found the exterior of the left eye to be entirely normal. The media were perfectly clear. There was no deposit on Descemet's membrane. The disc was normal and its outline distinct. The only change in the fundus was as follows: In the inverted image there was seen at the macula a round spot about one-half the diameter of the disc in size, which was of a greenish color, and just above this spot was an extravasation of blood in the retina. The extravasation was of about the same size as the greenish spot. In the upright image the spot was of a darkish color. A retinal vessel passed over it. V = fingers near the eye. Central scotoma, V. F. not contracted. Tn. I requested his family physician to make a thorough examination of the patient's general condition, and he reported that he had valvular disease of the heart, but was otherwise in perfect condition. His urine was free from albumin and sugar.

I applied leeches to the temple and prescribed potassium iodid in small doses and instillations of atropin. He remained under my observation for a month, during which time the picture changed but little. His vision did not improve.

I did not see him again till June 30, 1908, more than two years after the preceding visit. He came now because the right eye had become impaired in sight. Six weeks before this visit he had first noticed distortion of objects in this eye, which was followed by a marked diminution of vision. He had been under treatment for this trouble elsewhere. I found the eye E. V = $\frac{6}{24}$; V. F. intact for white and colors. The external parts of the eye were perfectly normal. The media were clear; there was no deposit in Descemet's membrane. The disc was of normal color and its outline distinct. Adjoining the nasal margin there was an oblong patch of opaque fibers. The retina was quite transparent, except in the macular region where there were a number of small extravasations of bright red blood. Under the retina, in the center of the macula, is a ring of darkish color, and in the ring a dark red spot. The diameter of the ring is about one-half the disc's diameter. In the inverted image the ring is of a distinctly dark green color. Retinal vessels pass over the darkish area. With the exception of a small white spot, without pigment on or around it in the lower periphery of the fundus, there are no other changes in the eyeground.

At my request his family physician had a thorough examination made of the patient, and according to his report the man is free from disease, with the exception of the valvular disease of the heart. He suffers, however, from habitual constipation. He writes: "Mr. W.'s heart reveals a mitral regurgitant murmur and a pulmonary regurgitation. The heart's area of dullness on percussion is normal. No pericardial friction sound. His heart has since his last examination, about two years ago, improved very much; at present there is no irregularity or heart block." The urine was free from albumin and sugar. An examination of the blood was negative. A careful inquiry as to his previous history revealed the fact that he had had acute rheumatism seventeen years ago, and that valvular disease of the heart was first diagnosed twelve years ago. He has had no other disease and his family history threw no light on his personal condition. So far as we have been able to ascertain there is no case of

tuberculosis among his relatives. The treatment consisted of small doses of calomel, subconjunctival injection of a 4% solution of sodium chlorid, leeching of temple, and rest for the eyes. Under this treatment the only change in the eyeground noticed was an increase in the number of extravasations in the retina. The extravasations were all small, except one which looked like a clot of the size of a pin's head. He complained that his vision was worse than when first seen. I discontinued the subconjunctival injection, but otherwise did not change the treatment. I used dionin in powder several times, but it failed to produce edema of the conjunctiva. I advised him to go into the country and to abstain from all work with his eyes. He returned to me September 21st, when I noted the following changes: The extravasations in the retina were almost completely absorbed except a small one in the temporal half of the macula. There is now a black round spot at the side of the dark greenish ring which was formerly present, and around this is a narrow zone of a somewhat lighter color than the rest of the choroid. Retinal vessels pass over the dark round spot. V = $\frac{6}{24}$; V. F. intact for form and colors, but the latter are not as bright in the center as a short distance from it. His general condition is good.

A careful examination of the left eye (the one first affected) shows V less than $\frac{6}{60}$. The ophthalmoscopic examination shows media perfectly clear. Optic disc pale. In region of macula is a grayish patch considerably larger than the disc, the lower margin of which is on a line with the middle of the disc and the nasal margin is about one and a half diameters of the disc from the optic papillæ. The patch is of irregular form, and, in part, of a darker gray than the rest. The lower margin is fringed with the pigment. Retinal vessels, some quite large, pass over it. No choroidal vessels are visible. There are no other changes in the fundus.

On April 13, 1909, five months later, I saw him again. He stated that since the last visit he had suffered from an attack of acute rheumatism. This began in the heel of the foot and spread to ankle, knee, and hip joints of both limbs. He was treated for this by sweats. He is now free from pains in his limbs. The condition of his eye is as follows: Right V = $\frac{6}{36}$. Small, absolute, central scotoma. Media perfectly clear, disc normal, retinal vessels usual size; at macula there is a dense, opaque, grayish spot surrounded by a narrow zone of very dark color.

In size it is somewhat larger than the diameter of the disc. A retinal vessel is distinctly seen to cross the spot. Left: V = $\frac{6}{12}$, a small negative central scotoma and a large absolute paracentral scotoma. Ophthalmoscopic picture as before. He attributes the improvement in vision in this eye to the perspiration during the attack of rheumatism.

CASE V.—Chorioretinitis hemorrhagica centralis in connection with syphilis.

The patient was a farmer, strong and muscular, thirty-five years of age. Up to March of this year his eyes had never been inflamed or given him any pain, and his vision had always been excellent. He was first seen by me on October 18, 1905. I learned from him that a year before he had had a primary syphilitic sore which was followed by secondary symptoms. Ten months before his visit he had had an acute inflammation of both eyes which had laid him up for five weeks. It was accompanied by much pain in the eyes and by impairment of vision. During the following three months the eyes were practically well and the vision fairly good, but since two months he had noticed a gradually increasing failure of vision in both eyes.

The examination made October 18th showed both eyes to be normal in appearance externally, with the exception of the presence of a few stretched posterior synechiæ. In both eyes the vitreous was full of floating opacities. The optic papillæ were flat and of normal color. In the left eye there was a streaked extravasation of blood in the macular region; M. 1 D. V = $\frac{6}{36}$. L., M. 1 D., movement of hand. I ordered inunctions of mercury, and gave potassium iodid, 10 grains three times daily.

January 1, 1906: M. 1 D. V = $\frac{6}{24}$; vitreous somewhat clearer. L., no central fixation, vitreous much clearer; extravasation at macula not much changed.

February 12th: V = $\frac{6}{12}$, L., V. as before, vitreous is now pretty clear; in upper part of macula is a deep red area, in size one-half of the disc's diameter; in region of fovea lutea a dark green spot of about same size as the red one above. Has been taking large doses of iodid of potassium since last visit.

February 12, 1907: M. 1 D. V = $\frac{6}{8}$, L., V as before. The right eye is now nearly free from vitreous opacities. The left eye has still some floating opacities in the vitreous. The macu-

lar region is now the seat of a dense grayish opacity, on which dark pigment is sprinkled irregularly.

February 1, 1908: M. 1 D., V = $\frac{6}{6}$, L., V as before. In both eyes the vitreous is now perfectly clear. The right eye shows normal eyeground. In the left eye the disc is surrounded by a narrow zone of atrophy of choroid. The region of the macula is occupied by an opaque grayish spot, nearly twice the size of the disc, and on it several small dots of pigment are deposited. No choroidal vessels are visible in this region. Otherwise the fundus shows no change from the normal.

The stretched posterior synechiæ found in both eyes at the first visit leaves no doubt that the inflammation of the eyes, from which he suffered six months before he came under my observation, was an iridocyclitis, and it is not improbable that the vitreous opacities which were present when I first saw him were the result of the inflammation. The hemorrhage found at macula of the left eye was undoubtedly very recent, and it was the failure of vision due to this that brought him to me. The dense opacities at the macula, which were seen as soon as the vitreous was clear enough for a satisfactory ophthalmoscopic examination, and the subsequent appearance of spots of pigment on it, leave no doubt in my mind that both the choroid and the retina were involved in the morbid process, and that this did not differ essentially from that observed in the other cases. Whether or not the syphilis can be held to be a cause of the disease I must leave undecided. In no other case of this disease that I have seen was the existence of syphilis admitted, or were there symptoms pointing to the presence of this disease.

CASE VI.—Chorioretinitis hemorrhagica centralis of one eye, alleged to be due to traumatism.

M. B., a married woman, forty-five years of age, born in England, was first seen by me June 27, 1907. She consulted me with regard to the loss of vision of her left eye. Her family history was negative. She has always been in good health and has always had good vision in both eyes up to the present time, and so far as she can remember has never had any inflammation of her eyes. Since a few days she has noticed that the vision of her left eye is greatly impaired. Examination of the right eye showed it to be normal in every respect; with + 0.5 D. V = $\frac{5}{5}$. The left eye has vision equal to counting fingers at

a few feet. It has a large, central scotoma. Tn. The eye is normal in its outer parts. The media are perfectly clear. The disc is normal in appearance and the retinal vessels are of normal dimensions. At the macula the retina is hazy, and on it are a number of small, bright red extravasations; otherwise the retina seems normal; there are no extravasations elsewhere. The choroid underneath the hazy retina appears of darker color than elsewhere.

She was told to rest her eyes, and was given small doses of extract of ergot.

A few weeks later she was seen again. At this time was found, on examination by the indirect method, a dark green spot about one-half the breadth of the disc in diameter at the macula, and in front of the green spot and above and below it were a number of small, bright red extravasations. In the direct method the greenish spot appeared of a dark color.

Several months later the picture had changed. In place of the greenish spot there was now seen a spot somewhat larger, of a yellowish-white color and opaque; no choroidal vessels were visible on it.

Twenty-one months after her first visit the picture was about as last reported, except that the yellowish-white opaque spot is now of a darker color in its temporal third, and that there were now again a number of small, bright extravasations around the opaque yellowish-white spot. The extravasations seemed to be in the retina. There was now a large central absolute scotoma. The right eye remains normal in every respect.

On her last visit to me she inquired whether a blow on the eye could have caused the loss of vision, and intimated that she would bring a suit for damages for the loss of vision, if I could testify that a blow was the cause. She volunteered the information that shortly before she first consulted me she had been struck on the eye by the fist of some person. The fact that for twenty months she in no manner intimated that a traumatism might be the cause of her eye trouble, seems to me to make it quite doubtful that she actually was struck on the eye. The interest in this case lies in the fact that small retinal hemorrhages recurred a year after the disease had apparently ceased to be active.

DISCUSSION.

DR. G. ORAM RING, Philadelphia: I desire to thank Dr. Kipp for his clear presentment of this matter. No one of us sees many of these cases.

The etiology is often very obscure. Atropin is usually quite safe in the young cases, but in those more advanced, especially if there is high arterial tension, myotics are better. Dionin, subconjunctival injections, and heat are aids. After eliminating the various dyscrasiæ, and having found that the kidneys, heart, intestinal tract, and blood are normal, we are driven back to a tonic and alterative treatment. These patients are often nervous and flabby and generally below tone. It is usually safe to push the alterative treatment. Exercise properly regulated is likewise important.

I would like to ask Dr. Kipp if he uses carefully regulated diaphoresis and if he takes the blood-pressure. If the blood-pressure does not contraindicate it, I employ diaphoresis in the beginning by means of the electric-light pack, which is safer than the electric-light cabinet. An ice-cap is applied to the head and hot-water bottles to the feet and legs. In twenty minutes the patient will begin to perspire, and this is allowed to continue for twenty or twenty-five minutes longer. I now make blood-pressure tests before and after the diaphoretic treatment. I am now treating a lady of thirty-four years whose systolic pressure was 146 and diastolic pressure 126. After seven packs, extending over ten days, the systolic pressure was 115 and the diastolic 90. We have accomplished for the present all we could expect from this form of treatment. The sight has improved.

DR. CHARLES J. KIPP, Newark: In my earlier cases there was no record of blood-pressure;. in my later ones there was.

In regard to the treatment: in one of the cases reported here, where there was heart disease and both eyes had been affected, the patient has improved lately under diaphoresis. In the eye first affected sight has improved to $\frac{20}{60}$, but he has had new hemorrhages while having the diaphoretic treatment.

ANGIOID STREAKS IN THE RETINA, WITH THE REPORT OF A CASE.

W. ZENTMAYER, M.D.,

Philadelphia.

References to this condition in literature are still few, a recent writer (Pagenstecher) having collected 10 cases, to which should be added one by Oellers, illustrated in his "Atlas of Rare Conditions of the Fundus." No case, to my knowledge, has been examined anatomically, so that our views concerning its nature are conjectural, and the theories thus far advanced have not been convincing.

The following case has many interesting and suggestive features:

T. Y., aged thirty-three years, tailor, had good health until two years ago, when he became ill with typhoid pneumonia which confined him to bed for two weeks and incapacitated him for work for two months. Before this illness he weighed 140 pounds, but since then never more than 125 pounds. He is married and has one healthy child two years old. His wife has had no miscarriages. His father died an accidental death; his mother is living. He uses tobacco and malt liquors in moderation. There is neither history nor evidence of syphilitic infection. As in all other reported cases, the history of our patient seems to disclose nothing that has bearing upon the eye condition.

In November, 1908, he came to St. Mary's Hospital complaining of dimness of vision in the right eye which had set in suddenly four weeks previously. There is a dendriform ulcer of the cornea of the right eye, otherwise the external conditions of the eyes are normal. Vision of R.E. = $\frac{6}{10}$; L.E. = $\frac{6}{6}$. The visual field shows slight contraction for form, more pronounced for the right eye, in which there is also a horizontal, oval scotoma extending on either side and just beneath fixation. The examination of the urine was negative. The blood count was normal. The plasmodium was not found.

Ophthalmoscopic Examination.—R.E. Media, all but cornea, clear. Disc round and slightly overcapillary, with a dense pigment conus and a sharp-cut scleral ring out. Surrounding the disc there is a pale zone which to the nasal side is grayish white. Extending from the margin of this zone there is a system of branching and anastomosing pigment bands. These originate principally from near the upper margin of the disc, and anastomosing form a coarse mesh over the upper inner part of the fundus. A finer streak begins beneath the inferior nasal artery and, passing below the disc, reaches the macular region. In general they taper toward the periphery of the fundus, where there is a retinochoroidal disturbance, manifesting itself in a mottled reddish-brown broken zone which is broadest and most pigmented beyond the region of the macula and absent in the inferior nasal periphery. The streaks have a jagged contour, their appearance having been well described by de Schweinitz as resembling a mole track. They vary in size from once to thrice the diameter of a vessel of the second magnitude. The color is pretty uniformly black, but in places it is chocolate brown with islets of bright red.

In the macular region, below the fovea and below the streak which courses in that region, there is an irregular, horizontal, triangular, fresh hemorrhage. A section of the pigment streak is here broadened and displaced downward, there being a whitish area of equal breadth and length along its upper border. Above this there is a small oval hemorrhage, apparently in connection with a retinal venule.

L. E. Disc is round and overcapillary. The scleral ring is complete. A dense pigment conus surrounds the temporal margin. The inner and lower margin of the disc is embraced by a grayish-yellow crescent about one-third the diameter of the disc in width. It and the disc are bordered by a band of pigment from which extend into the fundus similar streaks, coming off at equal distances from one another except at the lower outer margin. Above, down and in, and to the outer side two such streaks converge and meet at a short distance from the disc in broader bands which course and taper toward the equator. A broad pigment band which extends nasalward from the disc is interrupted by an oval patch of superficial retinochoroidal atrophy, in the center of which is a bright red spot; beyond this the band is continued and tapers off toward

the periphery. At equidistances within the streak are five or more bright red islets. The periphery of the fundus shows retinochoroidal disturbance similar to but much less extensive than that of the right eye.

To summarize: In both eyes there is a system of ramifying and anastomosing pigmented streaks which extend outward into the fundus from a similar band which surrounds a crescent of grayish-yellow retinochoroidal disturbance encircling the disc. They lie beneath the retinal vessels and taper toward the periphery of the fundus, which is the site of marked retinochoroidal changes. The color of the streaks is in general black, but in places there are islands of bright red color.

The points of interest in this case are: (1) The conformity of the arrangement of the bands with that of most of the other reported cases. (2) The extensive retinochoroidal changes at the periphery. (3) The interruption, in its course, of one of the bands by a small superficial area of disturbance of retinochoroidal pigment (L. E.). (4) The presence of a hemorrhage in intimate relation with one of the streaks (R. E.).

The first point is of interest because it shows that, whatever be the nature of these bands, they have the same location, the same general course and arrangement, and a similar contour and color in nearly all cases.

The second point is of interest because it is possible that a causal relation exists between the striæ and the peripheral fundus lesion, whether they are the product of inflammation or of metamorphosed blood.

The third point is of interest because, if the interpretation of which this lesion is susceptible, of a rupture with extravasation of the contents of a vessel, is correct, it lends support to the more recently expressed view concerning the possible nature of these streaks: that they represent a system of new-formed vessels developed in the course of a chronic retinochoroiditis (Lister).*

*In the American Journal of Ophthalmology for June, 1909, Alt pictures a condition found by him in portions of the retina removed for the purpose of studying the pigment epithelium in eyes with old choroiditic changes. The streaks which he found consisted of folds of pigment epithelium slightly raised by a small amount of exudate. It seems to him that this finding may give the right explanation of so-called angioid streaks in the retina.

The fourth point is of interest because it is the only fresh hemorrhage in either eye, and that in its vicinity there is a preëxistent broad pigment streak.

It is unnecessary to review the different theories that have been presented to explain this interesting condition, or to enter into a discussion of the various ingenious explanations of how extravasated blood may assume this arborescent arrangement, as these are well known to you, but it may be of value to call attention to the more recent views which associate these streaks with blood-vessel formation.

Oellers concludes that the pigment streaks originate through hematogenous pigmentation of the walls of preëxisting small retinal vessels and capillaries. He describes one of the pigment streaks in direct continuation with a retinal vein. His case was probably reported without knowledge of Lister's findings. Pagenstecher, after analyzing the different theories, accepts as the most tenable explanation the hypothesis put forward by Lister.

An important contribution bearing on the pathology of angioid streaks in the retina has been made by Lister. This author, in examining sectioned eyes macroscopically, came upon two showing pigment streaks in the substance of the retina. The first was an eye removed because of iridocyclitis and secondary glaucoma following cataract extraction. The anterior half showed the changes consequent upon ordinary iridocyclitis. The retina showed distinct streaks in its substance. These were in places pale and in places deeply pigmented. They lay external to the retinal blood-vessels and internal to the choroid. Microscopic sections showed, besides great degeneration of the retinal elements at the part corresponding with the most marked streak, the retina was detached, and here and there were seen deposits, both on the external surface of the detached retina and in its substance, which were partly granular and partly cellular and contained pigment. In this deposit, in several places, were well-marked blood-vessels, containing unmistakable red blood-corpuscles. Their walls were in places undergoing calcareous change.

In the second instance the eye was staphylomatous. Macroscopically there was pigmentation of the retina similar to retinititis pigmentosa, and occurring also in branching streaks, one of which passed to the margin of the disc. Besides degenerative changes in the external layers of the retina, in places corresponding with pigmented streaks, were well-marked obliterated blood-vessels of new formation. They had clearly defined walls, which were pigmented and had undergone calcareous degeneration with blocking of the lumen.

Lister says that, while these specimens are of a different class from the collected cases of angioid streaks, they have interest in showing: (1) That a new system of blood-vessels may occur in the deeper layers of the retina; (2) that these vessels appear to be the essential factors in a system of pigmented striæ similar in level, and in many ways in appearance, to those seen in angioid streaks, and, this being the case, there seems to be fair justification for putting forward the suggestion that angioid streaks are also associated with the formation of new vessels in the retina. Lister advances, as a possible hypothesis as to the cause of their appearance, that, in the first place, some chronic inflammatory change takes place in the retina; and, secondly, that vessels penetrate into this chronically inflamed tissue in the same way that vessels make their way from the optic disc into exudate or hemorrhage into the vitreous. The vessel walls become pigmented or undergo calcareous degenerative changes, accounting for the color of the streaks and the glistening patches seen in their course, while the presence or absence of exudate round the vessels, or degeneration of the surrounding retina, accounts for the presence of the broad white bands running with the streaks. He thinks it quite likely from the above hypothesis that hemorrhages of the retina may be derived from the newly formed vessels.

If we examine the reported cases with a view to determine whether there are any ophthalmoscopic changes tending to support the hypothesis of Lister, we find that there was in many

cases a whitish zone about the papilla suggestive of a retinochoroidal disturbance, and in several cases macular changes indicative of either active or quiescent inflammation of the choroid and retina. In several instances there were retinochoroidal changes at the periphery (Pagenstecher, Walser Plange, and the author), and in most cases there were pigment disturbances, aside from the streaks, in the fundus. In two instances the streaks were interrupted by an area presenting the appearance of a hemorrhage, but which closer examination convinced the observers was the underlying choroidal vessels. In my own case the interruption has all of the appearances of having been due to a rupture with extravasation of blood and subsequent absorption. In de Schweinitz's case the streaks resembled a system of obliterated vessels, slightly elevated. In Knapp's case the primary color of the streaks was in portions red, but finally it was black or dark brown throughout.

While the facts accumulated are insufficient to justify definite conclusions, it would seem to the author that they point to the streaks being pigmented vessels, the vessels being either of inflammatory or of congenital origin.

CONCERNING A FORM OF RETINAL DISEASE, WITH EXTENSIVE EXUDATION; BEING A CLINICAL CONTRIBUTION, WITH THE REPORT OF TWO CASES.

G. E. DE SCHWEINITZ, M.D.,

Philadelphia.

The following case histories are intended as a brief clinical contribution to a class of cases in which the lesions in the fundus of the eye are chiefly characterized by an extensive mass of exudation, sometimes associated with vascular disease. The whole subject has recently formed the basis of an admirable paper by George Coats,* who has gathered together the scattered literature and recorded pathological examinations of six cases that have come under his notice.

CASE I.—H. H., female, aged nineteen, unmarried, came for examination October 19, 1907.

Family History.—The patient's paternal grandfather died of softening of the brain after an illness of ten days, at the age of forty-four. The paternal grandmother died of diabetes mellitus, after an illness of four months, at the age of seventy-six. The maternal grandfather died of cardiac failure at the age of eighty, and the maternal grandmother of apoplexy at the age of sixty-seven. The patient's father and mother are living and in good health. The mother has had one miscarriage. One of the patient's uncles died of pulmonary tuberculosis at the age of fifty-two, another of cirrhosis of the liver at the age of forty; one aunt and three uncles are living and in good health. Several grand-uncles and aunts died of apoplexy or have suffered from paralysis. There is no history of syphilis or alcoholism in the family.

Personal History.—The patient in childhood had diphtheria, measles, chicken-pox, and whooping-cough, and a number of

* Royal London Ophthalmic Hospital Reports, xvii, Part 3, 1908.

attacks of malaria, but none of these occurred during the past five or six years. Menstruation began at the age of thirteen and has been quite regular, except at the age of sixteen, when for a short period of time there was a certain amount of irregularity. There have been several attacks simulating appendicitis.

General Examination.—This was made by Dr. David Riesman, who has kindly furnished the following notes: The patient is pale and has a slightly greenish tint. The heart's action is rapid, but there is no murmur; pulse 120; temperature 98.6; examination otherwise negative. The hemoglobin 76 by Dare, 80 by Talquist; red cells 4,365,000, white cells 8,400. Differential count: Polymorphonuclears 66, lymphocytes 27, large mononuclears 6.4, eosinophiles 0.2; one nucleated red cell. Otherwise nothing abnormal.

Urine Examination.—Color turbid-amber, reaction alkaline, specific gravity 1013, albumin none, sugar none.

Ocular Examination.—The vision of the right eye has always been defective, and with the best correction of a hyperopic astigmatism the vision was only $\frac{6}{150}$. The media were clear, the disc a vertical oval of good color; no abnormalities in the retinal vessels, but there was a large, shallow, probably congenital crescent, somewhat in the form of a posterior staphyloma, at the outer side of the disc.

Corrected vision of the left eye was $\frac{6}{20}$, the refraction being a hyperopic astigmatism. The sight had been defective for some months and had grown worse for the past three weeks. Ophthalmoscopic examination revealed decided punctate hyalitis, a nearly round disc, of somewhat grayish color; the scleral ring was broadened outward and slightly downward, somewhat in the form of the so-called congenital coloboma. The arteries were about normal in size, perhaps a little smaller than normal; the veins decidedly distended, particularly the upper temporal vein, which was swollen and tortuous. Lying beneath the retinal vessels, and crossing the entire length of the eyeground in a vertical direction, there was a broad area of greenish-white exudation, somewhat knobbed in appearance, over which were scattered numerous glistening masses, probably of cholesterin. This mass began about two discs' diameters from the optic papilla, and followed in general terms the sweep of the retinal vessels, particularly as they passed downward and outward, as well as upward. There was some fringing of pigment at the

margins, and, particularly on the disc side of the exudation in the macular region, scattered small areas of pigment. Beyond the main mass of the exudation, and separated by a narrow band of healthy retina, far out in the temporal periphery, there was a second mass of similar greenish-white exudation. (See colored plate.) The general elevation of this exudate was about 2 D., but in some areas, particularly in the thick masses in the lower and outer periphery, the elevation was as much as 6 D. In

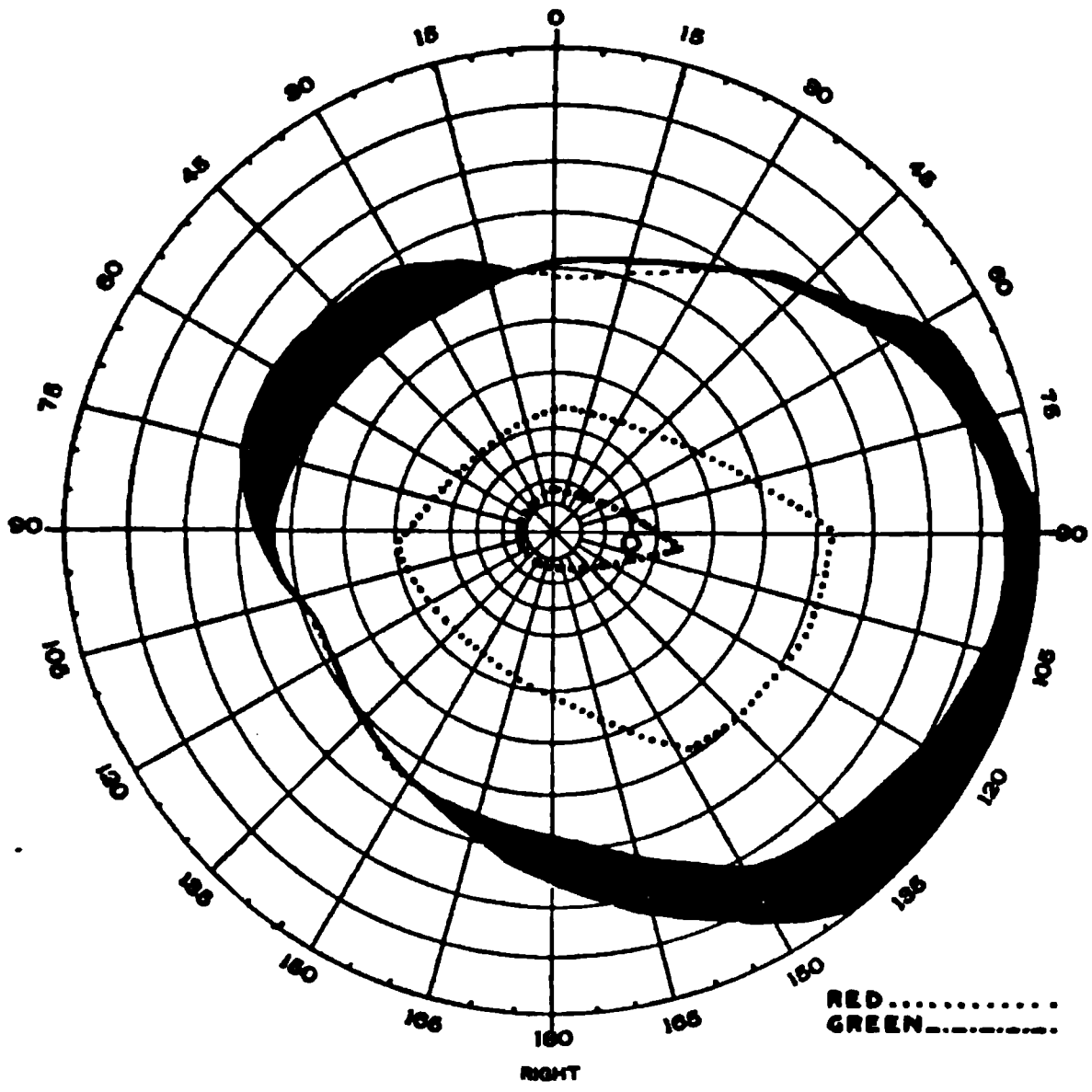

Fig. 1.—Visual field of the right eye.

places it partly covered the vessels and in one part there were some twisted vessels which may have been new formed.

The visual field of the right eye was practically normal for form, somewhat contracted for red and green (Fig. 1); that of the left eye normal on the temporal side, but with a large wedge-shaped defect upon the nasal side (Fig. 2).

At the suggestion of Dr. Riesman, the patient was placed upon a pill of reduced iron and arsenious acid, and later mercuric chlorid was added to the mixture. She also took Burnham's

tincture of iodin, iodid of potassium, and, in order to demonstrate, if possible, whether the process was a tubercular one, received both by my direction, as well as the direction of Dr. Riesman, a course of old tuberculin injections, reaching as high as 5 mg., without producing the slightest general or local reaction. These injections were continued for over a week.

The patient's physician writes, under date of April, 24, 1909: "Her general health is good. I have examined the left eye with the pupil moderately dilated, and the glistening cholesterin

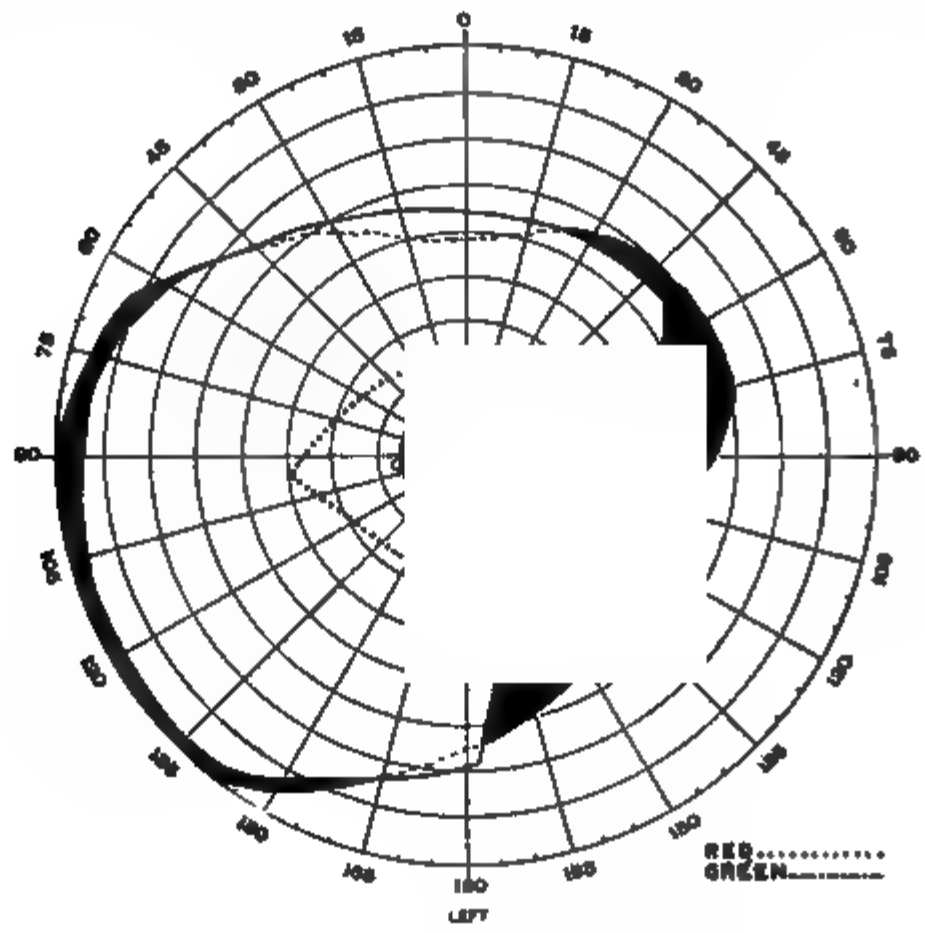

Fig. 2.—Visual field of the left eye.

masses seem to be less marked; that is, they are not piled up so high as they were when you examined her. On moving the eye numerous floating, glistening white bodies are perceptible, about the size and shape of oxalate of lime crystals as they are seen in the urine. I do not recall that these were previously present."

When I first examined her there was marked punctate hyalitis, and it is therefore possible that there has been some increase in this condition, giving rise to the appearance which her physician describes in the previous paragraph.

Remarks.—Dr. Coats has studied this disease in three groups, thus: Group 1, Cases Without Gross Vascular Disease; Group 2, Cases With Gross Vascular Disease; and Group 3, Cases With Arterio-venous Communication. Referring to the first of these groups, he writes* concerning the case just reported (he having examined the water-color which depicts the lesions in the patient's eye-ground, and the clinical record), "I should think your case undoubtedly belongs to the same class."

When the patient came under observation, the possible etiological factor claimed immediate attention, and at first it was thought that a tuberculous process was present, especially as in some respects the fundus lesions were similar to those described by W. Krauss and A. Brueckner.† As will be remembered these authors obtained a general reaction to tuberculin (0.5 mg. O. T.), as well as decided changes in the form of increase of retinal hemorrhages after each injection, in their first patient, who also had "suspicious signs of tuberculosis at the apices of both lungs." In their second patient, physical examination being negative, two injections of old tuberculin (2 mg.) gave no general reaction, but caused some changes in the fundus picture, *i. e.*, increase of hemorrhage and greater prominence of a layer of exudation in the summit of a detached retina. In one case reported by G. Carpenter and S. Stephenson in their list of cases of tubercle of the chorqid, quoted by Coats and with some hesitancy included by him in the present group, the patient had tuberculous disease of the right knee and slight enlargement of the cervical glands. The patient of Paton whose excised eye was examined by Parsons, the case history and pathological examination also quoted by Coats, had enlargement of the cervical glands. The case is described as one of "tuberculous choroiditis" with a question sign, but the sections of the eye failed to reveal any lesions certainly characteristic of this infection. In Wagenmann's case, reported in connection with Von Hippel's record of "A

* Personal communication.

† Archives of Ophthalmology, xxxvii, No. 5, 1908, p. 544.

Very Rare Disease of the Retina," which belongs to Group 2 of Coats's classification, there were signs of tubercle in the apex of the right lung, and the cervical glands were enlarged.

To quote the words of Coats, "perhaps the usual clinical diagnosis in cases of this kind is tubercle of the choroid, active or obsolescent." The pathological examinations thus far made are against this etiology, because, as Coats points out, if the lesions were tuberculous they would have originally been situated in the choroid and of necessity destroyed it, while in his series this membrane was "always distinguishable and sometimes almost free from change." Tubercle of the retina is extremely rare, and usually involves the inner retinal layers, while in Coats's specimens of massive retinal exudation the outer layers were "chiefly involved." He regards the evidence from tuberculin reaction as "very equivocal," but admits that genuine tubercle could readily closely simulate the cases at present in discussion, and that therefore Krauss's and Brueckner's cases may have represented instances of tuberculous disease of the choroid.

Returning to my own case, there is nothing in the clinical and family history to suggest tuberculosis except that an uncle of the patient died of this infection; the tuberculin injections failed to produce the slightest general or local reaction, and, finally, there has been no increase in the local lesions up to the present time. Tuberculosis may therefore, I think, be eliminated from the diagnosis.

Nothing in my patient's family or personal history throws light on the etiological factor, inasmuch as the illnesses which she experienced bore no relation to the advent of the ocular troubles. Except for a slight anemia, the general examination was negative. Neither hereditary nor acquired syphilis was present. It is interesting to note that the affected eye was the left one; usually, however, the right eye has been the one attacked; according to Coats, in the proportion of 11 to 6. In the cases thus far reported the male sex has preponderated (14 to 5). My patient was a young woman, whose age, however

(nineteen), exactly corresponds to the average age worked out by Coats, if one doubtful case is omitted.

Exactly how long the ocular disease existed prior to my first examination, in October, 1907, cannot be stated, but the following quotation from a letter from her physician is of interest in this connection: "My notes show that on June 20, 1906, vision of the left eye was $\frac{6}{6}$. My next examination was on August 24, 1907, when vision had fallen to $\frac{6}{24}$, and it was then I first detected the trouble in the fundus. In June of that year the patient had completed a four years' course at school in a distant city, and during the previous winter on one occasion was seized with a very severe pain over the left eye and was sent to the hospital of the school, where it was necessary to use morphin. This pain continued for twenty-four hours. Whether it had anything to do with the trouble in the eye or not I do not know. The patient's mother noticed at Easter that her daughter's vision was failing."

It would therefore seem that the ocular disorder must have begun some time between the 20th of June, 1906 and the 24th of August, 1907, at which time its earliest stages were first detected. It is probable that they had already begun in Easter of that year, therefore about the end of March. It is stated that the first ophthalmoscopic lesion discovered consisted in retinal hemorrhages. These, however, were not manifest at the time she came under my observation. Very likely the period of time during which these extensive lesions developed was a greater one than would be apparent from the records, and Coats calls attention to the probable insidious development of the disease, and to the fact that it doubless exists for a much longer period of time than many of the clinical reports would indicate.

Thus far treatment of the patient whose history I have reported has been unavailing, although there has been no progression of the disease, and, in fact, no notable alteration in the fundus lesions, and this record can do no more than place another example in the first group of Coats's classification of retinal disease with massive exudation.

There seems very little doubt that Groups 1 and 2, that is, those in which there is no association of gross vascular disease with exudation, and those in which such association exists, have the same pathological basis. Group 3—that is, those cases with arterio-venous communication—I have not referred to in the present paper, as I have not had the opportunity of studying this affection. Coats's pathological investigations indicate, as do also in most instances the clinical examinations, that while ophthalmoscopically the disease resembles tubercle, it is not of this nature, and he believes that these massive exudations are due to the slow organization of hemorrhages. Those who are interested will naturally consult Coats's paper for the full particulars of his pathological investigations.

In this connection I will report a second case, which probably, although not certainly, belongs to the same class.

CASE II.—A man, aged about sixty, came under observation November 16, 1907, in consultation with Dr. William J. Taylor, who has been good enough to furnish the following notes:

Family History.—So far as he is aware, there is nothing in the patient's family history which would throw light upon his ocular lesions.

Personal History.—The patient has always been, in general terms, nervous and apprehensive; for example, he was never willing to go about by himself, would not permit himself to remain within a room the door of which was locked, etc. He has manifested a gouty tendency, and has made several visits to Carlsbad on this account. In recent years he has exhibited a mild type of arteriosclerosis, although the arterial tension was never very high, nor the changes in his blood-vessels particularly marked.

General Examination.—The patient is a pallid, spare man, with slight stiffening of the radial vessels, but no definite cardiac disease. In point of fact, examination of the heart has always shown a regular action, the pulse being 75, full and strong. A blood examination, made April 14, 1907, was as follows: Hemoglobin 70 per cent., erythrocytes 3,230,000, leucocytes 7,700. A number of urine examinations made between April 4th and the time that he came under observation

revealed an average specific gravity of 1024, no albumin except on one occasion, and no sugar. Microscopically, there were numerous mucous threads, cylindroids, and a few hyaline and granular casts.

Ocular Examination.—The earlier ocular examinations were made by Dr. Charles A. Oliver, who has been kind enough to send the following communication: On December 3, 1906, the patient's eyeground presented the characteristic changes of old ametropic choroiditis, which was more marked in the right eye. Correction of the ametropia, as follows:

R. E. — 2.75 — 0.75 c axis 90
L. E. — 2 50 — 0.75 c axis 90

yielded normal vision. On the 3d of May, 1907, the patient complained of "a spot" before the right eye. The fundus appearance was unchanged; a vitreous opacity was present; vision was normal.

On the first of June, 1907, "the spot" before the right eye was much better and vision continued to be normal. Somewhat later the patient communicated with Dr. Oliver, and in this communication stated that his eye had become slightly clearer and that "the black element floating through it" seemed at times to "settle toward the nose." Practically no change was present when an examination was made sixteen days later, vision continuing to be normal.

At the next ocular examination, made by Dr. Oliver's assistant during Dr. Oliver's absence, the patient gave a history of rapid failure of vision, with neuralgic attacks and pain around the right orbit. The vision of the right eye was now reduced to $\frac{1}{45}$th of normal; vision of the left eye continued normal. The ophthalmoscope revealed obscuration of the disc, with much swelling of the retina, two spots of hemorrhage down and out; arteries narrowed, veins large and full.

Somewhat later in the same month I examined the patient, with the following result: Vision of R. E. $\frac{1}{60}$, L. E. $\frac{4}{4}$. In the right vitreous there were punctate and web-like opacities, and a large area of white exudation was noted above the disc, in the macular region and down and in from the disc, where it assumed a yellowish-white appearance and was elevated 4 D. above the level of the unaffected eyeground, the mass appearing to be for the most part beneath the retinal vessels. The edges of the disc

were cloudy; the veins uneven and full. In the left eye the conditions were exactly the same as those which have been already described in Dr. Oliver's report, namely, a moderate degree of epithelial choroiditis, without any signs of exudation or hemorrhage. After a long course of treatment, which consisted in the administration of iodid of potassium, nitroglycerin, and vapor baths, the vision remained unchanged in so far as the right eye is concerned and continued to be normal in the left.

At the last ophthalmoscopic examination, April 21, 1909, the exudation before described had assumed a somewhat knobbed appearance and was elevated as much as 6 D. above the level of the eyeground in places, and showed a brownish-yellow color in various portions of it. The veins were dilated, and the arteries showed sclerotic changes, but there were no new vessels. Above the macula the exudation assumed a concentric shape. Tests to determine whether or not the lesion was tuberculous were not applied, but there was nothing in the clinical history or in the general examinations to indicate the likelihood of a tubercular infection. Syphilis can be excluded, and the whole process is best explained by assuming the presence of an exudation which had formed as the result of hemorrhage.

Remarks.—In some respects this case resembles the one reported by Walter H. Jessop, in the person of a woman, aged sixty-three, which Coats has included in his doubtful list. Jessop found about ⅔ O. D. from O. D. an oval swelling covered by the retina, not transparent, about 3 O.D.s in length and 2½ O.D.s in height. The edges were fairly distinct, the swelling of a grayish color and in places white and reticulate, retinal vessels crossed it, its greatest height was 4 D., and at one side there were some brown pigment patches.

If the case which I report should be classified with those now under discussion, it has one important and interesting feature, namely, that the eyeground was the subject of expert examination at stated intervals for a year prior to the greatest manifestation of the disease. Moreover, except vitreous opacities and ametropic choroiditis, there was no lesion in the patient's eye as late as four months prior to the beginning of the ocular

affection, which, moreover, first appeared, according to the record of Dr. Oliver's assistant, in the form of a retinitis of considerable extent, with obliteration of the optic nerve edges and two small hemorrhages down and out from the nerve-head. Therefore, some time between the 1st of July, 1907, and the 20th of November, 1907, the process which I have described in its greatest elaboration must have taken place. Practically it has not altered during the time I have had this patient under observation, that is, from the 26th of November, 1907, until the 21st of April, 1909, or a period of seventeen months. At the last examination the patient was in excellent general condition and the affected eye entirely free from pain and inflammation.

DISCUSSION.

DR. ALEXANDER DUANE, New York: I have seen one case of extensive plastic chorioiditis resembling that pictured by Dr. de Schweinitz. It occurred in a woman of middle age with a clear history of syphilis. The condition was moderately progressive. There were little or no vascular changes.

DR. F. H. VERHOEFF, Boston: I have recently had the opportunity to examine histologically one of these cases. The eye, which was enucleated on account of glaucoma, was sent to me by Dr. Friedenwald. As I understand he expects to report the case in full, I shall mention here only what seemed the most important features. I have placed the specimens under the microscope, so that any one who is interested may examine them. The changes in the retina consist essentially in large, well-defined areas of hyaline degeneration, apparently following proliferative processes. In the hyaline areas there are deposits of lime salts and cholesterin crystals. I made serial cross-sections of the optic nerve, which I think was not done by Coats, and found that both central vessels were completely occluded by endovasculitis. The retinal vessels were also markedly degenerated, as were also some of the posterior ciliary, indicating that the vascular degeneration was general. Whether this vascular degeneration is responsible for the retinal changes or not I do not know. Senile arteriosclerosis certainly does not produce such changes. We get retinal hemorrhages, but not this peculiar degenerative change.

NEURORETINITIS IN CHLOROSIS, WITH REPORT OF A CASE.

WM. CAMPBELL POSEY, M.D.,

Philadelphia.

Although there are many subjective symptoms of chlorosis, it is comparatively seldom that structural changes occur in the fundi, just as it is rare to see extensive histological changes throughout the body the direct result of this disease. Thus, in a paper on the "Ocular Manifestations of Anæmia," which the author read before the Section on Medicine of the American Medical Association in 1897, it was noted that of 19 cases of marked chlorosis examined by him, appreciable swelling of the disc or true neuritis was not present in any instance, though a slight obscuration of the edges of the disc with broadening and some pallor of the retinal veins occurred in quite a number. Of 50 chlorotics examined by Saundby and Eales in 1882, however, some degree of neuroretinitis was found in 8%.

In addition to these slight degrees of neuroretinitis, chlorosis at times evokes a most intense inflammation of the optic nerve and surrounding retina, and a number of cases have been recorded where the changes in the fundi were so marked that they were mistaken for the ocular inflammations of albuminuria and of brain tumor. The writer has recently had a case of this intense form of neuroretinitis due to chlorosis under his care at the Wills Eye Hospital, the notes of which, together with an accurate picture of the inflammation when at its height in the two eyes, follow, the report being made with a view to calling further attention to this unusual form of ocular manifestation.

M. B., a Jewess, twenty-one years of age, was admitted to the wards April 10, 1909, complaining of poor vision and

general weakness. The family history was negative regarding tuberculous, nervous or mental, or other serious disease, both father and mother living and well at the ages of fifty-four and fifty, respectively, while a sister aged thirty-six and a brother aged twenty-nine are both in excellent health. The mother had suffered no miscarriages and had borne no other children.

The patient was born in Russia, but has been six years in America. She attended school until fourteen years of age, since which time she has worked in factories as seamstress. Her hours have been long and she has had but a half hour for lunch She has had no exercise, riding to and from her work, and reading incessantly in the evenings. She says her home is comfortable, and that she sleeps in a large, well-ventilated, and sunny upstairs room. She has never been very strong, but always fairly well, never having had to miss work on account of illness. She menstruated at thirteen years of age, always regularly, her periods lasting over three or four days, and being attended with but little pain. She has worn glasses for six years (high convex cylindrical glasses prescribed at the Pennsylvania Hospital), but had never had any previous ocular trouble beyond a transient inflammation in her left eye which the glasses corrected. She is not a mouth-breather and had never had any trouble with nose and throat until the past winter, when she began to suffer from frequent colds in the head. Her appetite has always been good, her bowels regular, never constipated, and she had never complained of shortness of breath or palpitation. There had never been any difficulty in urination. Any exposure to venereal contagion was denied. Her digestive powers were good. She was accustomed to drink one cup of coffee and two of tea daily, sometimes more.

Her present attack began about two months ago, when, in addition to repeated attacks of colds in the head, she developed a general sense of discomfort and weakness. There was pain, nearly constant in the subclavicular region and axilla on the right side, which was not increased by deep breathing, but always made worse by changes in the weather. Her extremities were never cold or swollen. Headache was not complained of, but riding in the cars nauseated her somewhat. The day before admission she noticed that the vision in her right eye had become obscured, apparently without cause and without pain, and the

next day, on waking, finding the blur persisting, she decided to seek relief at the hospital.

On examination, it was found that the eyes presented nothing abnormal externally, save for a somewhat sluggish pupil on the right side. The ocular movements were normal. Vision in the right eye was reduced to counting fingers at 1 foot; corrected vision in the left equaled $\frac{6}{12}$.

As shown by the accompanying illustrations, which were sketched by Miss Washington a few days after admission, both eyes were the seat of an intense neuroretinitis, that of the right

Visual field of left eye.

eye being accompanied by great edema of the retina. The veins in both eyes were enormously distended, while the arteries in the right were much reduced in size. The arteries in the left eye were of about normal caliber. Both veins and arteries were tortuous, especially the former. No spontaneous venous or arterial pulse was demonstrable or could be elicited by pressure. The veins were dark and full and hidden in places by the swollen retina. There were no hemorrhages or isolated areas of extravasation in either eye, save for a small, round, fluffy area of extravasation in the retina of the right eye far in the periphery in

A case of intense neuroretinitis in chlorosis.

close association with the inferior temporal vein. The swollen veins could be followed into the periphery of the retina, but the arteries in the right eye gradually faded away some 2 or 3 disc diameters from the papilla. The fields in both eyes were somewhat concentrically contracted; that of the left eye was free from scotoma, while a large absolute scotoma extended 20 degrees from fixation upward and outward in the right eye. (See charts.)

The unusual size of the veins awakening the suspicion of a profound blood dyscrasia, Dr. George W. Norris was called in consultation, and the writer is indebted to him for the following report:

Visual field of right eye.

Face and lips pale, finger-nails slightly curved and somewhat cyanotic. Hands cold. Body poorly nourished and developed. Right shoulder lower and smaller than the left.

Chest: Good expansion, equal on both sides. Jugular veins rather full when recumbent. Lungs: resonant throughout, except for small patch of dullness in the right axillary line above the hepatic dullness. Over this area vocal resonance and fremitus are diminished and the breath sounds weak. This region occasionally becomes painful (evidently pleural thickening).

Temperature 98°. Pulse 108. Respirations 20. Blood-pressure: Systolic 120, diastolic 100 mm. Hg.

Blood: Hemoglobin, 60%; erythrocytes, 4,790,000; leucocytes, 11,100.

Heart: Slightly enlarged to the right. There is no thrill. The aortic second sound is slightly, and the pulmonic second sound greatly, accentuated. There is no arrhythmia. The apex-beat is in the fourth interspace just within the mid-clavicular line. Slightly within the apex-beat a presystolic mitral murmur is heard, followed by a good, muscular sound, and a short, systolic murmur. Neither of these murmurs is transmitted.

Abdomen: Shows nothing abnormal. Neither liver nor spleen is enlarged. The stomach, according to auscultatory percussion, is normal in size and position. There is no rigidity or tenderness.

Diagnosis: Chlorosis. Mitral stenosis and insufficiency (slight).

Examination of the urine was negative.

Dr. F. R. Packard kindly examined the nasopharynx and accessory cavities, but reported nothing abnormal.

In the absence of all other symptoms, it appeared that the ocular inflammation had been occasioned solely by the anemia, and the patient was accordingly placed on full doses of iron (Blaud pills, gr. v, t.i.d.) and rest, with some slight exercise in the open air enjoined.

A blood count made a week later showed: Hemoglobin, 65%; erythrocytes, 4,710,000; leucocytes, 9,600. Corrected vision in the right eye had also risen to $\frac{6}{60}$, that in the left remained at $\frac{6}{12}$. The eye-grounds too showed marked improvement, the retinal edema and swelling of the discs having largely subsided, and the size of the veins being much reduced. The patient appeared in the best of spirits and said that she felt much better.

Hirschberg was the first (in 1879) to note the occurrence of optic neuritis in chlorosis. Other cases were reported shortly after this, however, by Bitsch,[1] Gowers,[2] Williams,[3] Mackenzie,[4] Schmidt,[5] Dieballa[6] and others, so that there are now about 20 fully recorded cases in the literature.*

Avoiding a detailed report of each of these cases, it may be briefly stated that in all a binocular inflammation of the optic nerve and retina of the most intense type was found to be de-

* For literature consult Westcott and Pusey, Archives of Ophthalmology 1902, p. 23; also Wilbrand and Saenger, iv, 1, p. 434.

pendent solely upon chlorosis, the reduction in the percentage of hemoglobin in some of the cases being but comparatively slight, while in others it sank to a low degree—20%.

In all there was greater or less papilledema, with obscuration of the edges of the disc, and more or less edema of the retina round about the disc. In nearly all, mention is made of the great increase in the size of the veins, of their tortuosity, and of their disappearance at times in the swollen retina. The arteries were often very small, sometimes of normal size and usually tortuous. In a number of cases the general infiltration of the retina was replaced by the appearance of dots and streaks, which arranged themselves at times in the form of a star about the macula, as is so frequently observed in albuminuric retinitis. In a case recorded by Schmidt,[5] where there were a few small hemorrhages and sharply outlined white plaques of different sizes scattered over the retina, and a sprinkling of small glistening points and patches in a semicircular zone about the macula, three separate medical examinations were made, before albuminuria, cerebral disease, and hysteria could be excluded and the inflammation referred to its proper source, examination of the blood revealing hemoglobin 56%, red blood-corpuscles 120,000, white-corpuscles 8000.

In quite a number of other recorded cases, also, retinitis albuminuria was simulated, and the differential diagnosis only made by the positive finding in the blood and the absence of changes in the urine.

Small hemorrhages were noted in a fair proportion of the cases, usually in association with the larger blood-vessels. The most frequent and largest extravasations of blood into the retina in chlorotic patients occur, however, at the menstrual period, which Wilbrand and Saenger explain by the scanty amount of blood in the vessels at that time, and the decrease in the blood-pressure; in an interference with the circulation at the point of bending of the central vein and the increase in size of the vein in consequence of the influence of the intraocular

pressure; and, finally, in an abnormal transparency of the blood in addition to the presence of great local diapedesis.

Symptoms highly suggestive of brain tumor were present in many of the cases, and intense and almost unendurable headache, with vomiting, dizziness, and in not a few cases localized and general convulsions, served in a number of instances to deceive for a time the physician in charge into the belief that a neoplasm was creating the symptoms. In one remarkable instance observed by Engelhardt,[7] in which he was able to follow the case from early in its course until death, the mistake in the diagnosis was confirmed only at the autopsy, when it was ascertained that the choked discs, which had been followed by atrophy and blindness, the terrific headaches, and profound drowsiness, dizziness, and general convulsions, were all occasioned by cerebral anemia without other pathological change. A tumor of the left cerebral hemisphere in the motor region had been suspected, as right hemiplegia of the extremities was present with total right hemianesthesia. A blood examination made shortly before death showed hemoglobin 50%, erythrocytes 3,000,000, no increase in leucocytes.

Other observers also have experienced no little difficulty in properly differentiating the neuroretinitis of chlorosis from the papilledema evoked by brain tumor, and Bannister[8] has reported* an instructive case where, but for the suddenness of the onset of the headache and other symptoms which suggested a doubt as to the existence of brain tumor and led to the examination of the blood, the diagnosis of brain tumor would have been established. In fact, the true nature of the case was only assured by the success of an iron and arsenic treatment. At the same meeting Patrick[9] referred to a somewhat similar case, in which, in addition to marked symptoms of cerebral irritation which pointed to a cerebral neoplasm, Wilder had found double choked discs with some small retinal hemorrhages and a paresis of the right external rectus muscle.

* Amer. Neur. Assoc., May, 1898.

The association of paralysis of the external rectus muscle with neuroretinitis has been recorded in quite a number of the cases, *i. e.*, by Stölbing, Riegel, Remer, Dieballa and others, Stölbing explaining the occurrence by the implication of the sixth nerve in the vascular sclerosis of the cavernous sinus, which he claims is present in all chlorotic cases.

Hawthorne[10] believes that the simultaneous occurrence of the inflammation of the optic nerve and the sixth nerve paralysis suggests a common origin, the nature and temporary duration of the two events making it difficult to imagine any single cause capable of producing them other than an intracranial lesion, and, as intracranial thrombosis is a recognized possibility in chlorosis, he asserts that it may be concluded with considerable surety that it is the underlying cause in producing the double vision. While, as Gowers[11] has remarked, the evidence of intracranial thrombosis in most cases of chlorosis is very small, nevertheless it must be acknowledged that Hawthorne's hypothesis is not without authority, for no less an observer than W. H. Welch has pointed out that chlorosis must always be assigned a leading place among the causes of spontaneous thrombosis of the central veins and sinuses in women. Kockel, Pincles, and Leichtenstern have also observed thrombosis from chlorosis.

Ballaban,[12] too, attributes the optic neuritis to thrombosis, but believes that the clot forms in the central vein, and not within a cranial sinus, basing his theory upon the study of a case in which there was intense neuroretinitis with veins three or four times the normal caliber. The arteries were very small. The blood columns in the veins presented a segmented appearance, and he was able to note the separation of the blood-current into colored and uncolored parts. Neither pulsation nor expulsion of the blood from the veins on the disc could be produced by pressure upon the globe with the finger. According to Ballaban, spontaneous thrombosis arises in the veins in consequence of the faulty condition of the blood and the poor circulation, especially

since the latter may occasion disease of the endothelium of the veins. In the case observed by him the blood showed oligocythemia.

Dieballa[6] avers that any local and transient cause which increases the anemia in chlorotic cases tends to produce papilloretinitis, and Schmidt[5] and he are agreed that the inflammation in the nerve is the result of a toxemia, the toxic products being generated by deglobulization. The former thought that in a case observed by him two influences were at work in the deglobulizing process—a physical strain (dancing) and the sudden appearance of menstruation after a period of amenorrhea. In his very interesting remarks upon this subject, Dieballa goes on to say that he considers physical exercise in chlorotics to be decidedly deleterious for the blood, as it consumes oxygen, the supply of which is already lessened in consequence of the lessened oxygen-bearing hemoglobin. He has observed also that menstruation lowers the percentage of hemoglobin as much as 8 to 10%.

Bannester sought the cause of the neuroretinitis in a cerebral irritation, the nature of which he thought still a matter of conjecture. He pointed out, however, that if the menstrual function is really in any way an excretory one, as some have held, or if the internal secretion of the ovary may become perverted or insufficient in such a way as to poison the system and produce chlorosis, it is not going much further to presume that it may in special cases cause symptoms strongly resembling those of organic cerebral disease and lead to embarrassing mistakes in diagnosis.

In the last volume of their exhaustive and invaluable work, Wilbrand and Saenger assert that, as Lenhartz has frequently found a very high intraocular pressure in patients with anemia and chlorosis upon whom lumbar puncture was practised, they believe the papilledema in chlorosis is occasioned by increased pressure as well as by the changes which occur in the vessels of the papilla. The changes observed in the vessels are explained by the lessening in the elasticity of the walls by the abnormal constitution of the blood and by fatty degeneration of the intima.

A recent paper by Cushing and Bordley,[13] of Baltimore, tends to confirm this theory, although their remarks are directed to the solution of the problem of the origin of the cerebral and ocular changes observed in uremia and albuminuria. These authors, after speaking of the generally accepted theory that the symptom-complex in nephritis is due to some toxic disturbance arising either in a disordered metabolism or in the retention of some products of normal metabolism which fail of elimination through the diseased renal epithelium, call attention to the suggestion made by Traube in 1861 that the symptoms in nephritis, so characteristic of an increase of cerebral tension, might actually be due to a cerebral edema—a mechanical process, therefore—rather than to any autotoxic disturbance. They then assert that any swelling of the brain, be it a general or a circumscribed process, necessarily leads to compression symptoms, the eyegrounds furnishing at an early stage an objective and sensitive index of the process, and aver that this is even more true of edema than of states of increased cerebral pressure due to an encroachment on the intracranial spaces by a solid growth or an abscess. Their ultimate conclusion is that "the alterations of the eyegrounds in nephritis can be attributed in part, if not wholly, to the mechanical effects of increased intracranial pressure resulting from cerebral edema." While they consider it a quibble to refer the edema back to some toxic agency, as in a sense all edemas are remotely due to toxic disturbances, they think that it is best to be conservative, and say at least that "the symptoms are elicited by edema resulting from some toxic agency, and are not, as is commonly supposed, due to the direct effect on the cerebral tissue of the toxic agent alone." They believe, further, from their clinical and experimental studies of choked disc, that the edema of the retina itself is due in large part, even in cases of nephritis, to a backing of cerebrospinal fluid under increased tension into the investing meningeal sheath of the optic nerve.

While the writer is not in a position to combat this theory, it

appears to him unlikely that increased intracranial pressure could have been a potent factor in evoking the changes in the eyes in the case which he has reported, for absolutely no other symptoms of cerebral irritation were present at any time during the course of the disease. He is inclined to attribute the changes in the eyegrounds primarily to the altered condition of the blood, but is at loss to explain why such extensive and unusual changes should complicate an anemia of so moderate and not uncommon degree.

Should it be established that the neuroretinitis of chlorosis as well as that of nephritis is occasioned by increased intracranial pressure, the recommendation of Cushing and Bordley, of "the propriety of permanent decompression in selected instances of renal disease when medical measures or lumbar puncture have failed to relieve existing cerebral (uremic) symptoms, or when blindness is threatened owing to rapidly advancing degenerative changes in the neuroretinal tissues," will have to be taken into consideration in cases of anemia as well as of nephritis. The influence of iron, however, upon the ocular changes in anemia is very remarkable, and in nearly all of the reported cases vision which had been profoundly affected rose to normal, eyes which had been the seat of the most intense inflammation of optic nerve and retina regaining full visual acuity and an almost normal ophthalmoscopic picture under the administration of that drug.

REFERENCES.

1. Bitsch: Klin. Monatsbl. f. Augenheilkunde, xvii, p. 144.
2. Gowers: Brit. Med. Journal, ii, 780.
3. Williams: Brit. Med. Journal, 1884, i, p. 10.
4. Mackenzie: Brit. Med. Journal, 1885, i, p. 238.
5. Schmidt: Arch. f. Augenheilkunde, xxxiv, p. 164.
6. Dieballa: Deutsche med. Wochenschr., 1896, No. 28.
7. Engelhardt: Münch. med. Wochenschr., 1900, p. 1233.
8. Bannister: Journal Nervous and Mental Diseases, xxv, p. 874.
9. Patrick: Jour. Nervous and Mental Diseases, xxv, p. 881, 1898.
10. Hawthorne: Brit. Med. Journal, July, 1902.
11. Gowers: Brit. Med. Jour., July, 1902.
12. Ballaban: Arch. f. Augenheilkunde, xli, p. 280.
13. Cushing and Bordley: Amer. Jour. Med. Sciences, Oct., 1908.

DISCUSSION.

DR. F. H. VERHOEFF, Boston: Dr. Posey has given some consideration to the possibility of thrombosis of the central vein in cases such as his. Obstruction of the central vein, however, never causes optic neuritis. A case of obstruction of the central vein due to endophlebitis that I examined anatomically and reported three years ago, showed this most conclusively. There was no edema of the nerve-head, simply edema of the retina.

DR. G. E. DE SCHWEINITZ, Philadelphia: About eleven years ago, in a paper on cases of unilateral optic neuritis, I included a report of the ocular conditions of a patient affected in a manner similar to that which Dr. Posey has described. It is a very interesting therapeutic experience to note that in a few cases so-called optic neuritis with edema of the retina simulating the choked disc of brain tumor is cured by the exhibition of tincture of iron, or some similar iron preparation. The case to which I refer was that of a young woman with a papilledema of 6 D. on one side and 2 D. on the other. Within a period of three months vision, which was nearly nil in one eye and much reduced in the other, was restored to the normal standard, with complete disappearance of the optic nerve-head swelling, by the administration of iron; and Dr. Hare, who studied the patient with me, tells me that he believes that, although there are many new preparations of iron at our disposal, the best results follow the use in all cases of anemia of the old iron preparations, that is to say, the tincture of the chloride of iron, carbonate of iron, etc., and that many of these modern preparations, while more agreeable in their taste, are not followed by the same admirable results. Dr. Posey's communication is a very timely one. He has referred to the fact that at the present time the appearance of optic neuritis and headache renders the patient liable to a decompression operation, and therefore while full of admiration of this operative procedure in the relief of the choked disc of brain tumor origin, in our study of these cases we must not forget that occasionally, at least, anemia is responsible for a similar appearance, although it may be a very rare etiological factor, and one which Mr. Risien Russell, in his recent communication on the significance of optic neuritis, is disinclined to regard as a potent one. I have nothing to add to what Dr. Posey has already recorded as to the etiological factor of the optic neuritis

associated with anemia. As Dr. Verhoeff has pointed out, obstruction of the central vein cannot explain it. Whether increased tension is the potent factor or not I do not know.

DR. ALLEN GREENWOOD, Boston: I wish to put on record a case followed for about twelve years: a young factory girl, who came to me with double optic neuritis and headache and vision much reduced, with a diagnosis by the family physician of probable brain tumor. In view of the patient's anemia she was placed upon reduced iron, strychnin, and Fowler's solution, and in six months vision returned to normal, the optic neuritis disappeared, and since then she has been under my care for the fitting of glasses and there has been no return of the previous optic neuritis, nor has the anemia returned.

THE DIFFERENTIATION OF THE DIPHTHERIA BACILLUS FROM ORGANISMS MORPHOLOGICALLY SIMILAR.*

CARL FISHER, M.D.

From the Pathological Laboratory of the Massachusetts Charitable Eye and Ear Infirmary, Boston.

The great frequency of diphtheria-like bacilli in the conjunctival sac has given the bacteriology of this group a particular interest to the ophthalmologist. There can be little doubt that the widespread lack of appreciation of the ease with which these diphtheria-like bacilli may be mistaken for the true bacillus of Klebs has led to inaccuracies in the statistics of diphtheria, more especially of ocular diphtheria. For instance, Dr. Verhoeff tells me that in the last nine years, among the numerous cases of conjunctivitis examined bacteriologically by him, in only two did he find true diphtheria bacilli, as shown by animal inoculation. Many cases thought to be diphtheria by the clinician were found to be due to other organisms. Moreover, in view of the increasing number of cases of serious serum disease reported, following the administration of antitoxin, a mistaken diagnosis of diphtheria must now be regarded as a more serious error than was formerly believed.

The literature bearing on the identification of the diphtheria bacillus is very extensive. A critical valuation of these investigations is rendered difficult by the confused state of the nomenclature and by the neglect of many writers to state the grounds on which they have identified the organisms studied. The term "pseudodiphtheria" furnishes a good example, for while it is applied by some writers to bacilli of the solid staining Hofmann

* Presented by invitation.

type, others use it merely in the sense of "diphtheria-like." In the absence of a clear description of the organisms studied, the reader has to guess at the author's meaning and accept his diagnosis blindly. Investigations in which the morphological and cultural characters have been the sole standard of differentiation have given rise to a large part of the confusion which now obscures our knowledge of the biology of these bacilli. A detailed review of the literature is beyond the scope of this paper; the subject has been exhaustively treated in a recent monograph by Nuttall and Graham-Smith, "The Bacteriology of Diphtheria," 1908.[1] Extensive bibliographies are also appended to papers by Goodman[2] and by Lewandowsky.[3]

We are confronted at the outset by the question whether the diphtheria bacillus is to be considered simply one of a group of several true species, all more or less alike morphologically and culturally, or whether these supposed species in reality comprise simply variants of the true diphtheria bacillus. The question is of considerable practical importance, intimately concerned with our procedure regarding quarantine and prophylaxis.

At the present time, the evidence rather points toward the existence of distinct species. Instead of the diphtheria bacillus being the variable organism the other view would require, it has been shown to be fairly constant in its more important features. In careful studies made by Williams,[4] Cobbett[5] and Graham-Smith[6] regarding the virulence of suspected organisms to laboratory animals, no intermediate degrees between complete virulence and total avirulence were found. T. Smith and Walker[7] found the toxin production to be fairly constant among the races of the diphtheria bacillus studied by them. The results of various observers who claim to have transformed pseudo-diphtheria bacilli into true diphtheria bacilli and conversely (Hewlett and Knight,[8] Richmond and Salter[9] and others) have failed to be confirmed in the hands of able investigators on repetition (Williams, Cobbett, Bergey[10]), and it has been my experience and that of others (Williams, Peters,[11] Axenfeld,[12]

Escherich[13]) that bacilli of this group retain their original characters after repeated transplantations for long periods. Williams has shown that strains of the diphtheria bacillus found in the throat retain their characters unchanged throughout the course of the disease to complete convalescence. It seems certain that these metamorphoses do not occur save under very artificial conditions, if at all, and it is probable that the so-called avirulent diphtheria bacilli reported from convalescent cases of faucial diphtheria are in reality nothing more than saprophytic organisms which begin to be discovered when the decreasing numbers of diphtheria bacilli cease to overwhelm them. By planting tubes of dextrin and saccharose media with equal quantities of a mixture of a race of b. diphtheriæ known to turn dextrin only, and an avirulent race known to turn saccharose only, I have repeatedly obtained acid fermentation in both tubes, showing that these species may grow well together. This symbiosis has been demonstrated in the body. Perhaps most significant is the failure that has attended attempts to render animals immune to diphtheria by the injection of pseudo-diphtheria bacilli or their products (Petrie,[14] Spronk,[15] Hamilton and Horton[16]) or to prevent the formation of lesions of these organisms by the use of diphtheria antitoxin. Pigs which have survived large doses of organisms, indistinguishable otherwise from b. diphtheriæ, have been found to die promptly from the injection of strains of known virulence.

BACILLUS DIPHTHERIÆ.—The morphology of this bacillus is most variable, not only in its change from the solid straining forms of the young growth to the bizarre involution forms of the older growths, but also in the general type of morphology, which may be the only one found in an epidemic. The various possible types of morphology have been carefully pictured in the now classic plates of Wesbrook.[17] These fall into three groups: granular, barred, and solid. Organisms of each form have been known to be virulent and to cause diphtheria. The important features of this organism, which have been generally

accepted as constant, are the acid fermentation of glucose, the failure to ferment saccharose, virulence to the guinea-pig, and the elaboration of a specific soluble toxin. The value of these as diagnostic criteria will be discussed later.

The various diphtheria-like bacilli have been commonly divided into three classes: xerosis, pseudodiphtheria (Hofmann), and the diphtheroid bacilli.

Xerosis.—The bacillus of Kutschbert and Neisser[18] is described as an avirulent bacillus, morphologically like the barred forms of the b. diphtheriæ, growing sparsely on blood-serum and found in the conjunctival sac. The term has come to be applied to all avirulent diphtheria-like bacilli found in the conjunctival sac having barred or granular protoplasm. These organisms may be recovered almost constantly from the secretions of normal or slightly inflamed eyes, and seem to be saprophytic, although they have been thought to cause a multitude of lesions, even neuropathic keratitis. These bacilli are often indistinguishable from true diphtheria bacilli except in virulence, and would seem to be identical with the so-called non-virulent diphtheria bacilli. Certainly these organisms have no etiological relation to the condition of xerosis, and the name is ill chosen.

Hofmann's Bacillus[19] ("Pseudodiphtheria Bacillus").—Bacilli corresponding to the D_2 and E_2 types of Westbrook have been the subject of many investigations, and there seems little doubt that avirulent bacilli of this type, which fail to ferment sugars, constitute a true species. It should be noted, however, that in old cultures this bacillus acquires involution forms indistinguishable from those of b. diphtheriæ, and, on the other hand, that virulent diphtheria bacilli as well as virulent diphtheroids and other pseudodiphtheria bacilli may present the solid staining protoplasm, even in fairly old cultures. The term "Hofmann" is used, also, as a convenient way of designating a certain type of morphology.

Diphtheroid Bacilli.—A general term, which has been used to cover many unrelated species, rarely met with in clinical

work, which have been isolated from well persons, animals, foods, and lesions in many parts of the body to which their etiological relation was a matter of conjecture. The names given them by their discoverers give some idea of their characters: b. maculatus, coryzæ segmentosus, diphtheroids liquefaciens, etc. Most of them have some marked cultural characteristic, such as chromogenesis, liquefaction of media, adherent colonies, indol or spore production, but some might be mistaken for diphtheria bacilli if morphology were depended upon for differentiation. Several observers have described diphtheroid bacilli which are fully virulent to the guinea-pig (Davis,[20] Williams, Hamilton and Horton). That these are not identical with the diphtheria bacillus is shown by the fact that their pathogenicity is not counteracted by the antitoxin of diphtheria. Furthermore, Hamilton and Horton were able to produce a specific antitoxin, which counteracted their pathogenicity, but not that of the diphtheria bacillus. The non-virulent diphtheria bacilli and the so-called xerosis bacilli, as well as these virulent diphtheroids, seem logically to come under this heading. The exact significance of the diphtheroid bacilli as causes of disease remains to be worked out; most of them are saprophytic.

Differentiation.—Many modern investigators believe with Westbrook that they are able accurately to identify the diphtheria bacillus by its morphology, when this is "typical" (*i. e.*, Westbrook A, C and D). It is obvious, however, that since the bacteriological examination is generally made only in cases suspected of diphtheria, the morphological diagnosis may usually be correct simply because the clinical diagnosis is more often correct than not. When the bacteriological finding is negative, its value is obviously great. The crucial question is, how often the morphological diagnosis is correct in cases which are either clinically atypical of diphtheria or in which the typical picture is produced by some other organism. In answer to this question, there are, unfortunately, no extensive statistics controlled by

animal inoculation. It has been the experience in this hospital, however, that a morphological diagnosis of diphtheria is of little significance, especially in cases of conjunctivitis, in which pseudodiphtheria bacilli ("xerosis") are so universally present. It is well to bear in mind that faucial diphtheria may be closely simulated by inflammations due to staphylococci, streptococci, b. fusiformis, scrofula, and syphilis. Statistics collected from various sources show that in approximately 20% of all cases called diphtheria on clinical grounds, the diagnosis is not supported by the bacteriological findings, even when these are based on morphology alone. On the other hand, diphtheria bacilli have been found associated with lesions quite unlike the classical picture and in well persons.

Attempts have been made to identify the diphtheria bacillus by means of serum reactions *in vitro*, but conclusive results have, thus far, not been obtained. The bacillus can, of course, be accurately identified by the determination of specific toxin production, but this is too cumbersome a process to be useful in general work. Of the various other means of differentiation suggested, two have continued to receive the attention of investigators: virulence and the fermentative action on carbohydrates. The fermentation test will be discussed later, here we will examine the validity of the test for virulence.

It has been generally accepted that non-virulent strains of the diphtheria bacillus exist. It seems certain, however, that if such is the case, they are at least much more rare than has been thought. To be virulent, the bacilli must be enabled by their environment to produce their soluble toxin. It is known that if the bacilli alone are injected subcutaneously, they are destroyed. In testing the virulence, therefore, it is necessary to inject with the organisms a quantity of the medium in which they grow well, and since toxin is not produced in the presence of more than a trace of a sugar fermented by the bacilli, this medium must be nearly sugar-free. The neglect of these precautions has been responsible, without doubt, for

most of the non-virulent diphtheria bacilli reported. Williams, in the large series of cases studied by her, found that many strains, quite non-pathogenic when inoculated from broth, were highly toxic when inoculated from serum cultures or from ascitic broth, and it was rare that the bacilli isolated from typical cases of diphtheria failed to prove fully virulent. Williams, Park, and Beebe,[21] and Cobbett have been led by their experience to believe that avirulent strains are incapable of causing diphtheria, as, indeed, one would expect *a priori.* Hence, the identification of the diphtheria bacillus by its virulence is, in practice, the most satisfactory method, and would be so, even if the avirulent strains were not as rare as they are. The virulent diphtheroids referred to above are easily recognized by the fact that diphtheria antitoxin does not protect a guinea-pig from their pathogenic action. Unfortunately, the antitoxin treatment of a case strongly suggestive of diphtheria cannot be delayed until the completion of the virulence test. Nevertheless, the virulence to both the normal and the immunized pig should be tested in all cases in which a positive diagnosis has been made, not only for the sake of abstract accuracy, but also to prevent unjust quarantine and as a guide to subsequent treatment. This becomes of especial importance in investigations intended for publication, since the literature is already burdened with inaccurate data.

The bacteriologist is usually called upon to determine simply whether the specimen submitted is the diphtheria bacillus or not, and hence arises the need of a general term to include all members of the group incapable of causing diphtheria. In spite of the preëmption of the term "pseudodiphtheria" for the bacillus of Hofmann, it would seem the logical one for this class, and has been so used. In the absence of any well-established terminology, the writer suggests, tentatively, the following one for guidance in practical work:

Bacilli corresponding morphologically to any of Wesbrook's types:

I. Virulent, virulence counteracted by antitoxin of diphtheria —*diphtheria bacillus.*

II. All others—*pseudodiphtheria bacilli.*

(*a*) Virulent, virulence not counteracted by diphtheria antitoxin—*virulent diphtherioid bacilli* (Ruediger's).

(*b*) Not virulent.

1. Solid staining protoplasm, not acid-producing—*Hofmann's bacillus.*

2. Granular and barred (rarely solid) protoplasm—*diphtheroid bacilli*, including "xerosis," non-virulent diphtheria and all other diphtheroid bacilli.

It will be seen that virulence is the basis of this scheme of classification; for reasons to be discussed later, the fermentative reactions have not been considered except as regards the Hofmann bacillus. The term "virulence" should be understood to include the production of local necrosis and edema (in diphtheria, not present in the immunized pig). Hyperemia of the adrenals is almost constant in diphtheria.

It is evident that an accurate means of differentiation, more rapid and less expensive than animal inoculation, is urgently needed. Such a method seemed to have been found by A. Knapp[22] in his experiments on the action of xerosis, Hofmann's, and diphtheria bacilli on various carbohydrates. Knapp found that he could differentiate the three by their action on dextrin and saccharose: his races of b. diphtheriæ always gave an acid fermentation with dextrin and never with saccharose, xerosis formed acid from saccharose only, while Hofmann's had no fermentative action. There were no variations and the reactions occurred in every case within forty-eight hours. It had been generally recognized that true diphtheria bacilli always fermented glucose and not saccharose, but so also did diphtheria-like organisms; apparently the fermentation of dextrin was peculiar to the diphtheria bacillus.

Knapp laid his results open to criticism by failing to mention the virulence of the races studied by him, and he very properly

recognized the necessity of confirmatory work. This was done by Zinnser,[28] who claimed to have confirmed Knapp's results in all important points, although he found five organisms, identical with the diphtheria bacillus in morphological and cultural characters, which yielded no toxin and which were not virulent to the guinea-pig, but still fermented dextrin and not saccharose, in the same way as did true diphtheria bacilli. His races of xerosis, while giving the same fermentative reactions as those of Knapp, did not do so until after a week's incubation. Hamilton and Horton and Graham-Smith state that they failed to confirm Knapp's results; the former, however, give no details of their work.

At the suggestion of Dr. F. H. Verhoeff, the writer has undertaken to ascertain the value of the dextrin-saccharose fermentation test in the actual work of this hospital, where many cultures showing members of this group, recovered from lesions of doubtful etiology—notably from inflammatory conditions of the eye—are submitted for diagnosis. With the exception of four cultures of the diphtheria bacillus, the specimens were unselected, and were obtained from a wide variety of cases: membranous, purulent and chronic conjunctivitis, keratitis, tenonitis, trachoma and various anginas.

Knapp describes his technic as follows: "The medium is composed of beef serum 1 part, distilled water 3 parts, and is practically sugar-free. After heating to 100° C. for a short time to destroy the enzymes of the blood, 1% additions of the following sugars (in this work, saccharose and dextrin) were added. Finally, litmus solution (5% in water) is added in the proportion of 1%. The media are then tubed and sterilized at 100° C. for ten minutes on three successive days." This technic was followed except as regards the method of sterilizing. It was found that sterilization at 100° on three successive days did not insure complete sterility, and sterilization in the autoclave was found to be more effective and convenient. It was found imperative to use fresh serum, since organisms that

react well in fresh serum failed to do so when old serum was used.*

Smears were made from all sugar tubes after a week's incubation, to make sure that the organisms were growing well, and plates were made to exclude misleading reactions due to contaminations. No tubes were recorded as "no reaction" until they had been incubated over a week. Variations in the fermentative action of any specimen, as well as the fermentation of both sugars, could always be traced to contamination.† All specimens producing acid did not coagulate the media, coagulation being simply an expression of intense action. The use of an indicator in the medium, as proposed by Knapp for this work, is preferable to the estimation of acid-production by titration, since the test is purely a qualitative one.

The organisms studied consisted of 42 specimens, of which, according to the above scheme of classification, 12 were diphtheria bacilli and 30 pseudodiphtheria bacilli. The virulence of these organisms was counteracted by antitoxin in all cases in which it was tried, though unfortunately it was omitted in 5 cases in which the cultures had been lost before the work with antitoxin immunization was begun. In view of the source and character of these specimens, as well as of the rarity of the virulent diphtheroids, it seems improbable that these were not diphtheria bacilli, and since they gave the same fermentative reaction as the proved specimens they have not led to any false conclusions. Inoculations were made from emulsions of the colonies in the water of condensation of blood-serum tubes, which was found to contain only a trace of dextrose,

* It is interesting to note in this connection that the organism Verhoeff (b), described by Zinnser[23] as having feeble fermentative action on dextrin, gave no reaction with us in a medium made from old serum, but when fresh serum was used, this strain always acted quickly and powerfully, even after cultivation for over a year on artificial media.

† For example, a specimen of xerosis bacilli, kindly sent us by Dr. Knapp, fermented saccharose at first, but after careful plating it turned neither, though tested repeatedly. The organism was received in ascitic agar, which is notoriously difficult to obtain quite sterile.

as shown by Fehling's test, and since the bacilli grow well in this medium it should be a favorable one from which to inoculate animals.

The fermentative reactions were as follows:

Virulent (b. diphtheriæ), 12: All fermented dextrin only, within forty-eight hours. Four of these were selected because of their known virulence, 7 were isolated from unselected cases of faucial diphtheria, and 1 from a case of membranous conjunctivitis.* One of these races had the Hofmann type of morphology; the possibility of this having been one of the virulent diphtheroids was excluded by the fact that it did not affect the pig immunized with antitoxin.

Not virulent: Five fermented dextrin only within forty-eight hours, thus having the same fermentative action as true diphtheria bacilli. Of these, 2 were recovered from the nose, 1 from the throat and 2 from the eye. All had granular or barred protoplasm. All patients recovered without the use of antitoxin. The clinical picture was not suggestive of diphtheria, except in one case.

Fourteen fermented saccharose only, the reaction occurring in from twenty-four hours to eight days, the average time being three and one-third days. These were isolated from the nose, throat and eye. Two had the Hofmann morphology. Several of these were obtained from lesions resembling those of diphtheria.

Eleven fermented neither sugar. These were obtained from the eye and throat. One of them had the Hofmann morphology. Some of the cases were thought to be diphtheria, clinically.

In this series neither the morphology nor the cultural characters on blood-serum bore any constant relation to the fermentative action nor the virulence. Should further investigation

* This case of membranous conjunctivitis is regarded as of special significance, since the patient recovered without the aid of antitoxin and there were no serious constitutional symptoms. The bacilli isolated, nevertheless had the usual high virulence of the diphtheria bacillus to the normal pig while the pig immunized with antitoxin was unaffected.

show that the non-virulent dextrin-fermenting bacilli are attenuated diphtheria bacilli, the fermentation test would have an obvious, if only an academic, value. At present, however, aside from this power of fermenting dextrin, there is no more evidence in favor of this view than that any of the pseudodiphtheria bacilli are non-virulent diphtheria bacilli. In any case the question would become of practical importance only if it could be demonstrated either that the non-virulent strains are capable, under certain conditions, of regaining their virulence, or that, in spite of their harmlessness to the pig, these bacilli are in some degree pathogenic to man. As already pointed out, our present evidence does not support these possibilities.

The above results show that the fermentation of dextrin will not serve to distinguish the true diphtheria bacillus from the non-pathogenic species. In this series of 38 consecutive cases, five organisms were found which gave the same reaction as true diphtheria, or, in a series of 13 unselected specimens of dextrin-fermenting bacilli, over one-third were not virulent. These results, however, confirm Knapp's to this extent, that true diphtheria bacilli always fermented dextrin within forty-eight hours and never saccharose. It is then safe to say that if a given bacillus does not ferment dextrin it is not the b. diphtheriæ. In the routine of a general clinic, and especially of an ophthalmic clinic, this test will usually be decisive, for the true diphtheria bacilli and the dextrin-fermenting pseudodiphtheria bacilli are relatively uncommon, compared with those which do not ferment dextrin.

Unfortunately, in actual practice, the fermentation test has not proved as useful as had been hoped. The ability of certain common organisms to ferment these sugars makes it absolutely necessary to obtain the bacilli to be tested in absolutely pure culture. Such organisms are easily overlooked, especially in young cultures, and their complete elimination is often a tedious process. On the whole, this test consumes

more time than animal inoculation, while it does not give as valuable information. Most often the contaminating organisms are harmless saprophytes or yeasts, combined with streptococci or staphylococci, which, although rendering the fermentation test valueless, do not affect the test for virulence, because the guinea-pig is remarkably resistant to moderate doses of them. A virulent strain rarely fails to kill within forty-eight hours, although four days is usually given as the longest period within which it may fail to kill.

Conclusions.—1. The diphtheria bacillus cannot be identified accurately by its morphology and its cultural characters alone.

2. True diphtheria bacilli always ferment dextrin within forty-eight hours and never saccharose. To this extent Knapp's results are confirmed. This reaction, however, is not distinctive of the virulent bacillus diphtheriæ, since it is also given by certain non-pathogenic organisms having the same morphology. Out of 13 unselected races which fermented dextrin, 5 were totally avirulent.

3. Since bacilli which fail to ferment dextrin are much more commonly encountered, the fermentation test would, in the majority of cases, be conclusive. Practically, it is of little value on account of the necessity of obtaining the bacilli in absolutely pure culture.

4. Animal inoculation is, at present, the only reliable practical method of identifying the diphtheria bacillus. To exclude the virulent diphtheroids, a guinea-pig immunized with diphtheria antitoxin must be inoculated also.

5. In practice, on account of the necessity of early treatment, the diagnosis of diphtheria should be based chiefly upon the clinical appearances and symptoms. Importance should be given to the microscopic examination only when it is negative. An erroneous early positive diagnosis of diphtheria is unavoidable in a large number of cases. To avoid unjustifiable quarantine, and as a guide to subsequent treatment, animal inoculation

should be carried out in all cases in which the diagnosis of diphtheria is made.

I wish to express my thanks to Dr. F. H. Verhoeff, not only for the material and facilities for this work, but also for helpful suggestions and criticism.

BIBLIOGRAPHY.

1. Nuttall and Graham-Smith: "The Bacteriology of Diphtheria," 1908.
2. Goodman: Jour. Inf. Dis., v, No. 4.
3. Lewandowsky: Central. f. Bakt., 1904, 36, 472.
4. Williams: Jour. Med. Res., viii, p. 85, 1902.
5. Cobbett: Jour. Hygiene, vol. i, p. 235, 1901.
6. Graham-Smith: Jour. Hygiene, 1904, 4, 258.
7. T. Smith and Walker: Ann. Rep. State Board of Health, Mass., 1898, p. 649.
8. Hewlett and Knight: Trans. Brit. Inst. Prev. Med., S. i, 1897.
9. Richmond and Salter: Guy's Hosp. Rep., liii, 58.
10. Bergey: Univ. of Penna. Bull., N. S., No. 10, 1898.
11. Peters: Jour. Path. and Bact., 1896.
12. Axenfeld: Berlin klin. Woch., 1898, n. 35, 188.
13. Escherich: Berlin. klin. Woch., 30, 492, 1893.
14. Petrie: Jour. Hygiene, v, 134, 1905.
15. Spronk: Deut. med. Woch., 1898, 571.
16. Hamilton and Horton: Jour. Inf. Dis., 1906, 3, 128.
17. Wesbrook, Wilson and McDaniel: Trans. Assoc. Am. Phys., 1900, 15, p. 98.
18. Kutschbert and Neisser: Deut. med. Woch., 1884, 20.
19. Hofmann and Wellenhof: 1888, Wien. klin. Woch., 3.
20. Davis: New York Med. News, 1899, lxxiv, 520.
21. Park and Beebe: Sci. Bull., No. 1, Health Dept., City N. Y., 1895.
22. Knapp: Jour. Med. Research, 1904, xii, 4.
23. Zinnser: Jour. Med. Research, 1907, xvii, 10.

DISCUSSION.

DR. F. H. VERHOEFF, Boston: It seems to me Dr. Fisher's paper is especially timely because physicians do not seem to understand the limitations of the microscope in the diagnosis of diphtheria. They send a culture to the bacteriologist, who returns a positive report, and they think that this necessarily means diphtheria. As a matter of fact, a negative report only is of any significance. I think the hospitals for contagious diseases are to be criticized for not having made inoculation ex-

periments in a large series of consecutive cases. This applies even more to the cases of suspected conjunctival diphtheria, because the organisms that simulate diphtheria are so common that mistakes are frequently being made. Moreover, from our experience in Boston, we can safely say that diphtheritic conjunctivitis is a very rare disease, and can almost be disregarded. In the few cases that I have been able to demonstrate the diphtheria bacillus, the conjunctivitis has been of a mild type, and recovery has taken place without antitoxin, while in other cases with supposed classical symptoms the organisms have not been found once.

DR. CARL FISHER: As an example of the unimportance of the morphological appearance of the diphtheria bacillus: one of the large contagious hospitals in Boston, where they examine a very large number of specimens every year, has once or twice sent reports back to the Eye and Ear Infirmary saying that we had sent them cases of diphtheritic conjunctivitis. They evidently took satisfaction in the fact that the condition had been overlooked by the specialist. It shows that they were quite unable to differentiate the pseudo from the real bacillus by means of the morphology.

TROPOMETERS AND MEASUREMENTS OF ARCS OF ROTATION.

DR. LUCIEN HOWE,

Buffalo, N. Y.

The purpose of this paper is to call attention to certain points concerning the so-called field of fixation, and to instruments for measuring it. It seems better, however, to avoid that term, for the reason that it implies the ability of the individual to see an object which is looked at, this involving also a function of the retina. But at present we are dealing simply with the number of degrees through which any eye, even a blind one, can turn in a given direction—up, down, in or out, or obliquely. Therefore it is better to speak only of arcs of rotation. The oldest way of measuring these, and the one which in principle is still the simplest, is with some form of the perimeter. The usual method, clinically, is to seat the individual under examination in front of the perimeter without taking much care as to the exact position of the eye, and direct him to look, if he can, at an object—a disc, for example—which is slid along the arc of the perimeter. When the object is at the limit of what is usually called the field of fixation, and he sees or thinks he sees this object immediately in front of the eye, that is supposed to mark the limit of ability of the eye to rotate in that direction.

Such a plan, with various improvements and precautions, was followed by most of the earlier students. The results obtained by some of them are given in the following table:

	Schuurmann.	Volkmann.	Hering.	Kuster.	Schneller.	Landolt.	Duane
Abduction	42	38	43	43	46–54	46	53
Adduction	45	42	44	45	52–56	44	51
Superduction	34	35	20	33	—	44	43
Subduction	57	50	62	44	—	50	63

At first glance these figures seem to agree fairly well. But the truth is that most of them are only the average of a number of observations. In reality the results differ in different individuals or even in the same individual at different times. If we try to account for these differences, it will tend to clearness and to brevity if for a moment we direct our attention still to the perimeter.

It would be far beyond the province of this paper to consider earlier forms of perimeters and their uses. When going over the literature of this subject, and trying to repeat the measurements rather carefully a few years ago, a number of improvements were made in the instrument. Most of these have already been described in the first volume of a work on the "Muscles of the Eye," but since then one or two features have been added.

For the sake of clearness it is worth while to refer to these changes very briefly. They are:

First, to make sure that the center of the eye under examination is as near as possible to the arc of rotation. This is a very important point, and one too often neglected, not only in the measurement of the arc of rotation but also in the measurement of the field of vision. It requires only a simple calculation to show that, by changing slightly the position of the eye with regard to the center of the arc of the perimeter, we can vary to a very great extent the apparent arcs of rotation, and, it may be added parenthetically, fields of vision also, if those are measured. Therefore it is worthy of note that, in the improved perimeter, after the person under examination has planted the teeth firmly into the Helmholtz bit, its position is changed until, when the eye under examination looks straight ahead through an opening which should exist at the zero point of the perimeter, the axis of vision corresponds with the radius of the arc of the perimeter which passes directly through that zero point. Or, with the eye in that position, a light placed at the zero point is reflected from the center of the observed pupil to the eye of an

observer, who looks at that reflection from over the zero point of the perimeter.

In order to make sure that other radii of the perimeter also pass through the center of rotation of the eye under examination, a special "carrier" has been constructed to slide along the arc of the perimeter. This carrier has at its edge what is practically an ordinary gun-sight. That is a strip of brass about 5 or 6 cm. long, with a point projecting at one end, corresponding to a notch at the other. This sight is attached, as just stated, to the edge of the carrier, and is placed exactly in the direction of a radius of the arc of the perimeter. Therefore when this gun-sight is placed at different portions of the arc, a line passing over the notch and the projecting point should transfix the center of rotation of the globe which is under examination, if that globe is in the center of the perimeter.

In order to determine this last point, the carrier also has an electric light attached to its inner surface. When, therefore, the eye is rotated outward a certain number of degrees, if the light is flashed, the observer should see the reflection of that light exactly in the center of the pupil of the observed eye. The extreme point on the perimeter at which it is possible for the observer to see this reflection of the electric light in the center of the pupil of the observed eye, indicates, of course, the limit of the arc of rotation of the eye in that direction. Another and more recent change in the perimeter is to arrange the Helmholtz bit so that it revolves on a vertical axis, and to have a pointer move with the bit over a horizontal graduated arc. In this way we can measure the number of degrees which the bit is turned in or out. The reason for this appears when we remember the point to which attention has already been called—that the center of the arc of rotation does not always correspond to a point directly in front of the eye.

It is evident, from the foregoing, that we can measure with some form of the perimeter the arc of rotation outward, with a fair degree of exactness, but any form of the perimeter is un-

satisfactory or entirely useless if we wish to measure the arc of rotation inward or up or down. That is for the very simple reason that as soon as the eye turns a certain degree inward, the cornea is obscured by the bridge of the nose, or when the eye turns upward it is obscured by the brow. Moreover, it would be inconvenient to attempt to use the perimeter looking downward on the cornea, and practically impossible to sight from below upward, across the perimeter, in order to measure the arc of rotation downward.

If, therefore, we wish to determine the position of the globe in any one of the three positions last mentioned, it becomes necessary to resort to some other appliance. It is for this reason that we have the special forms of apparatus which have been called tropometers. An examination of the literature shows that this term tropometer was first used by Nicati in the description of an instrument which he published in 1876. From that description it appears that the instrument was very similar to one described later by Stevens. The latter is familiar to American ophthalmologists principally by the illustrations in the catalogues. For the sake of those who may not remember that, it is worth while to say that the head of the person under examination is firmly fixed by the usual Helmholtz bit—that is, a strip of wood on which the subject bites. The eye under examination then looks at a point immediately in front, and in doing so the axis of vision strikes a mirror at an angle of 45 degrees. The image of the eye in the mirror is then reflected at right angles, through a tube, to the eye of the observer. In this tube there is a graduated scale which is placed horizontally when the observed eye is moved horizontally, or the same graduated scale can be turned vertically when the observed eye moves through an arc up and down. In order to measure the amount which an eye does turn to the right or left, the observer arranges this graduated scale horizontally, and notes a point on the scale, which, for example, is just tangent to one edge or the other of the observed cornea. The subject is then asked to turn

the eye as far as possible to the right, for example. The number of degrees through which the globe is rotated is then shown by the vertical lines of the horizontal scale. In the same way, by turning the graduated index vertically, we may measure the number of degrees which the eye turns up or down. Stevens' tropometer is apparently an improvement over the tropometer of Nicati, but this and every instrument of its kind presents some objections.

One of these is the difficulty in deciding exactly when a given line on the graduated scale is just tangent to the edge of the cornea. For, as the cornea blends by imperceptible gradations into the sclerotic, it is impossible to select any one point on it as tangent to a given line, and then to recognize that same point as tangent to another given line after the eye has been rotated into a new position. I have called attention elsewhere to the fact that the rather complicated tropometer of Stevens is unnecessary.

In earlier attempts to become familiar with it, I soon found that it was possible to obtain an excellent view of the cornea and of its excursions by taking out the mirror situated at the distal end of the telescope, and thus looking straight at the eye. This naturally suggested a still further simplifying of the apparatus. That consisted in steadying the head by a form of the Helmholtz bit which I had already ascertained would keep the head perfectly still. That did away with at least a part of the machinery of the Stevens tropometer.

Then I had a tangent scale photographed on a larger disc of glass which fitted into the eye-piece of the large microscope, which I had described in 1897. This microscope is still manufactured, and without this eye-piece is known as the "corneal microscope." With this simple addition of the tangent scale in the eye-piece it serves very well as a tropometer.

In spite of all of the efforts thus far made to measure exactly the arc of rotation, much remains to be accomplished. These modifications of the tropometer have already been referred to

in the volume on the muscles already mentioned, but are now given in rather more detail.

But in using any such instrument, it should be remembered that the *behavior* of the eye is of quite as much importance as the extent of the arc of rotation in any direction. It is well known that the amount which an eye can rotate in a given direction is not the same in different individuals nor in the same individual at different times. Thus, if a person is told to turn the right eye as far as possible to the right, it will turn a given number of degrees in that direction. But if the examiner then calls loudly and sharply to the subject under examination to look still farther to the right, the globe will often rotate outward, perhaps six or eight degrees more.

Or, again, in one person the eye swings steadily and promptly to a given point and remains there, while with another it approaches that point only slowly and with a hesitating or vacillating movement. In other words, it is necessary here to keep in mind the fact just stated—that the behavior of the globe is quite as important as the extreme limit to which it can be rotated. Familiarity with these methods soon teaches the examiner, however, to distinguish between a normal and an abnormal swing of the globe.

But after all has been said concerning the limits of the arc of rotation, and methods of measuring that arc, either by some form of perimeter or by some form of tropometer, the question arises, of what clinical value is this?

Apparently it is of more importance than is usually considered. For the more we study the different forms of deviations of the globe from the normal position, the more important does it appear to distinguish the kind of deviation with which we have to deal. That is to say, when a globe turns inward, for example, and the question of operation is considered, we naturally ask in each case whether we should make a tenotomy of the internus or advancement of the externus. It is true that some are accustomed to decide this question in rather an ipse-dixit fashion.

Some operators favor one plan, and some the other. But those who have studied this question most exactly, after having met with good results, and also with bad ones, both from advancement and from tenotomy, are inclined to consider that neither tenotomy or advancement alone are suited to all cases. Apparently each case must be studied by itself. When the eye turns in, for example, because the adductors are too strong, then, other things being equal, tenotomy will give a good result in that case, as it has in thousands of others. On the other hand, if that eye turns in, not because the adductors are too strong, but because the abductors are too weak, then tenotomy of the internus is apt to give a result which is disappointing to the patient and embarrassing to the surgeon. In other words, each case of deviation has to be studied by itself, carefully and patiently and conscientiously. In doing this the measurement of the limit of the arc of rotation is by no means the only test, but it is one which should always be used, and the importance of it in cases like this is so great as to warrant perhaps this rather detailed consideration of the subject.

DISCUSSION.

DR. GEO. T. STEVENS, New York City: Certain of the statements in Dr. Howe's paper, doubtless there through inadvertence, might lead to incorrect impressions and prove misleading were not attention called to them.

1st. No tropometer "very similar" to that of Stevens was described or used prior to the use of the instrument which was exhibited at the meeting of the American Medical Association at Baltimore in 1894.

2d. Dr. Howe's paper might lead to the impression that the method adopted by Stevens for securing and maintaining uniformity and fixation in the position of the head during the tropometric examinations is essentially in the use of a bit which was used by Helmholtz and others.

As a matter of fact, neither Helmholtz nor any one else, so far as we are informed, used any support, rest, or device so constructed as to insure the uniform position of different heads

during such an examination, nor even of the same head during any two succeeding examinations of the movements of the eyes.

The head-support of Stevens with its accessories was radically different from anything which had preceded it.

3d. Neither the essential elements of the tropometer nor of the head-support were simple modifications of or improvements on any preceding instruments. They were new devices for doing a thing which had not been done before.

DR. LUCIEN HOWE, Buffalo: It occurred to me that some question might arise concerning this point of priority, and therefore I brought in the references. They are in 1876: W. Nicati, "Ueber das Tropometer" (Instrument zur Messung der Augenbewegungen), Correspbl. f. Schweiz. Aerzte, vi, No. 15, S. 459; and in 1877: W. Nicati, "Methode pour mesurer le champ du regard," Gaz. Med. de Paris, p. 324, Gaz. des Hôpit., p. 556.

IMPROVED APPARATUS FOR LOCALIZING FOREIGN BODIES IN THE EYEBALL BY THE ROENTGEN RAYS.

WILLIAM M. SWEET, M.D.,

Philadelphia.

At the meeting of this Society in 1887 I exhibited and described my first apparatus for the localization of foreign bodies in the eyeball and orbit. With some slight modifications the same general form of instrument has been used by me since that time in the examination of over 700 cases of foreign body injuries. While the method of localization presents no great difficulties to the number of *x*-ray operators who have studied the principles and are using the apparatus, I have recognized for some time past, from experience in teaching student classes and in conversation with *x*-ray workers, that there was some trouble in knowing exactly what measurements were to be made from the radiographs and the manner of transferring them to the localization chart to find the lines of shadow of the foreign body at the two exposures. Therefore, I have had made the new form of apparatus here illustrated, which embodies exactly the same principles as the present localizer, but in which the construction of the instrument relieves the operator of the necessity of making measurements from the radiographs or of drawing any lines to represent the planes of shadow.

In the older form of apparatus the patient is in the recumbent posture, with the head firmly clamped, and the photographic plate to the side of the head corresponding to the injured eye. The two ball-pointed indicating rods, each parallel with the plate and at a definite distance apart, are adjusted until one of the balls is opposite the center of the cornea of the injured eye and

at a measured distance from it. Two negatives are made—one with the tube horizontal or nearly so with the plane of the two indicating rods, and the second plate at any distance below this plane.

The chart employed for localization contains circles to represent sections of the average normal eyeball of 24 mm., upon which are entered the positions occupied by the indicating balls at the time of making the two radiographs, one spot at the measured distance that the center ball was opposite the center of the cornea, and the other at the known distance the second ball was to the temporal side.

As the tube is placed anterior to the plane of the two corneal summits, and the rays pass obliquely through the head and the injured eye, the shadow of one of the balls is projected farther back on the plate than that of the other, the degree of displacement measuring the distance the tube is brought forward. Likewise the amount of separation of the shadows of the two indicating rods in the second exposure measures the degree to which the tube is carried below the horizontal plane of the eyeball. Measurement of these displacements of the indicating rods and balls upon the chart enables the operator easily to determine the precise spot from which the rays emanated at the time the exposures were made. After having determined the position of the anode of the tube at the two exposures, the operator has only to enter on his chart the several distances that the shadow of the foreign body on the two plates is above or below and posterior to the shadow of one of the balls, draw a line from each of these points to the known position of the tube, and these will indicate the planes of shadow of the foreign body at the two exposures. The point of crossing of the lines of shadow shows the position of the foreign body in reference to the center of the cornea. The greatest difficulty experienced by the student in working the method was to remember the different measurements that were to be made from the plates, the position on the chart to which they were to be transcribed, and the direc-

tion the lines were to be drawn to show the planes of shadow of the indicating balls and the foreign body.

THE NEW LOCALIZER.—In the new apparatus the planes of shadow of the foreign body are accurately determined by the instrument without the necessity on the part of the operator of taking measurements from the plates or in drawing lines on the chart. The tube-holder, indicating ball, and plate-holder are upon a movable stage, and therefore preserve a known relation to each other, which does not vary. The angle of the rays with the eyeball and the distance of the tube from the plate are always the same, so that one indicator is sufficient, and this consists of a small steel ball supported in a ring of transparent celluloid. The setting of this ball opposite the center of the cornea is made by means of adjusting screws conveniently placed

Fig. 3.—Image of cross-wire and cornea.

on the frame of the instrument. Accuracy in the measurement of the distance of the indicating ball from the center of the cornea is secured by means of a telescope and reflecting mirror. The mirror gives an image of a cross-wire and a lateral image of the cornea. Through the telescope the observer adjusts the instrument until the image of the cross-wire is in direct contact with the image of the summit of the cornea. (Fig. 3.) When the adjustment is made, the indicating ball is exactly 10 mm. from the center of the cornea. A miniature incandescent lamp, mounted in an adjustable shade, illuminates the side of the nose of the patient, insuring a well-lighted image of the cornea and cross-wire.

Instead of a ball of cotton or other object for fixation, as in the older method, a circular mirror is placed at a distance of

Fig. 1.

Fig. 2.

12 inches above the injured eye. The patient gazes in the mirror and sees a reflected image of the injured eye and the circular culluloid disc with the steel indicating ball in its center. After the ball has been adjusted to a point opposite the center of the cornea of the injured eye, the patient by fixing the ball with the seeing eye prevents any movement of the eye during the exposures and holds the visual line of the injured eye parallel with the plate.

In order to shorten the time of making the radiographs and lessen the possibility of any movement of the patient or apparatus in changing plates, the two exposures in the new apparatus are made upon one plate, metallic shutters protecting those portions of the plate which are not to be exposed to the rays.

The tube-holder contains the usual cylindrical lead-glass shield for protecting the operator from the action of the rays, with the customary lead diaphragm. The central orifice of the diaphragm is covered with aluminum, which offers little obstruction to the rays, but lessens the risk of any unfavorable action of the rays upon the patient and guards against possible damage to the eyes in the event of breakage of the tube. The tube-holder slides upon a graduated rod, and the first exposure is made with the indicator at zero, in which position the rays pass in a direction corresponding with the horizontal plane of the eyeball. The second exposure is made with the tube at its farthest point to the right or left of the first position, depending upon which eye is to be examined. The illustration (Fig. 1) gives a view of the complete apparatus.

Since the relative position of the tube in reference to the indicating ball and the photographic plate remains fixed and known, it is readily seen that the direction of the x-rays in passing through the eyeball must follow a definite course, which is always the same for the two separate exposures. It is, therefore, possible to indicate on the localization chart the direction of the rays at the two exposures, and this has been done in the chart, a copy of which is reproduced in Fig. 4,

reduced in size one-half. Only those lines representing rays 2 mm. apart are reproduced, but each line is drawn with the required amount of divergence to indicate the rays as coming

Fig. 4.—Localization chart, with lines representing course of the *x*-rays (one-half actual size).

from a point the distance of the tube from the photographic plate.

METHOD OF EMPLOYING THE NEW LOCALIZER.—The apparatus is arranged as shown in Fig. 2. The patient lies with the head on a platform of hard fiber, with a pillow beneath the

shoulders and a small sand-bag under the head and neck. The upright supports for holding the head are now adjusted by means of the wheel 1, and the jointed part of the apparatus, J, containing the indicator is brought down in position. The indicating ball, G, is now roughly adjusted until it is opposite the center of the cornea and about 12 or 15 mm. distant. The patient looks with the uninjured eye into the mirror, M, and fixes upon the iris or cornea of the injured eye, or, better, upon the indicating ball in the center of the celluloid disc. The indicating ball is now carefully adjusted directly over the corneal center by means of the wheels 2 and 3, and the correctness of the position verified by observation through an opening in the mirror, M. The operator then adjusts the light of the small electric lamp so that the side of the nose next the injured eye is illuminated, but the light is not thrown into the eye. With this area lighted it is possible to see clearly through the telescope, T, when the cross-wire is exactly tangent with the summit of the cornea. The movement necessary to secure this position of the wire is made by means of the adjusting wheel 4. When the image of the cross-wire touches the image of the corneal summit, the indicating ball is exactly 10 mm. from the eyeball.

The photographic plate is inserted beneath the spring clips, C. C., the shutters S S moved so that the center area is open (Fig. 1), and the tube-holder adjusted to the zero point on the sliding scale. The current is turned on, and one exposure made. The tube-carriage is then moved to the limit of the sliding rod, always in the direction of the chin of the recumbent patient (to the end marked R if the radiographs are made of the right eye, and to L if of the left eye). The upper shutter is moved to cover the exposed central portion of the plate and uncover the upper unexposed portion. The current is again turned on and the second exposure made. The time of exposure for the second picture should be about one and a half times that of the first, to allow for the increased distance of the tube from the eye.

After the plate is developed it is placed in the frame P (Fig. 1), containing the key plate or focal coördinates (Fig. 5), with the film side of the radiograph next to the key plate. The radiograph is moved until the shadow of the indicating ball of the first exposure is in apposition with the middle ball on the key plate and the heavy horizontal line of the radiograph parallel with the horizontal line on the plate. Holding the frame to the light,



Fig. 5.—Plate showing focal coördinates (three-fourths actual size).

there is noted the position occupied by the shadow of the foreign body with respect to the vertical lines of "C" and "D." A reading is made of the line or lines which pass through the body, and this is transferred to the corresponding lines of the "C" or "D" scale of the chart, to the right or left side, depending on which eye is under examination. Without moving the plate the "E" reading is similarly made and transferred to the chart.

To take the "A" or "B" reading the plate is shifted slightly until the image of the indicating ball on the second exposure coincides with the "Right" or "Left" ball of the vertical coördinates "A" or "B." The line or lines of the "A" or "B" coördinates which cross the shadow of the body are noted and indicated on the "A" or "B" lines of the chart. The horizontal coördinate "E" should be the same in both readings. If the focus point on the anode of the tube was accurately set by the cross-lines on the lead-glass shield of the tube-holder, the images

Fig. 6.—Radiograph of foreign body in eye (three-fourths actual size).

of the indicating ball on the plate will coincide simultaneously with those on the transparent key plate, and it will then not be necessary to reset the plate to read the position of the "A" and "B" coördinates.

After the three readings have been transferred to the chart, the point of crossing of the "A" or "B" and the "C" or "D" lines is found, which gives the location of the foreign body in reference to the front view of the eyeball, indicating its situation above or below the center of the cornea and to the nasal or

temporal side of the vertical plane. Where a vertical line from this point crosses the "E" reading on the horizontal section of the globe it gives the depth of the body in the eyeball or orbit. In bodies of large size both ends should be localized to give the position in which the body rests in the globe. The situation of the body on the side view is determined by transferring its measured depth from the horizontal section and its distance above or below the horizontal plane from the front view localization.

The new apparatus is based upon the same general principles as was the old, but its mechanical features eliminate some of the errors that may occur in the use of the present instrument through carelessness of the operator in making the measurements and transferring them to the chart. The inexperienced worker in eye localization is also relieved of the necessity of studying out the position of the tube and the direction of the lines of shadow at the two exposures. The construction of the new apparatus insures that these factors are positively determined and recorded. The accuracy of the localization depends only upon the care with which the operator adjusts the indicating ball opposite the center of the cornea and at the definite and fixed istance from it. After the exposures are made and the plated developed, the determination of the situation of the foreign body is simply a question of reading from a key plate and transcribing these readings to the chart.

I am indebted to the Roentgen Manufacturing Company, of Philadelphia, for the excellent manner in which the details of construction of the apparatus have been worked out.

DISCUSSION.

DR. E. E. HOLT, Portland, Me.: In this bottle are exhibited 24 pieces of metal of my first series of cases, ending some fifteen years ago, since which time I have not kept the metal, but have allowed the patients to carry it away. The eye which was injured by the largest triangular piece of metal was saved, with qualitative vision of that eye.

In 1891 the secretary of this Society, and now our President, began his paper as follows: "The extraction of foreign bodies from the interior of the eyeball equals if not excels in interest and difficulty any of the problems ever presented to the ophthalmologist." This being true, we are certainly indebted to our present secretary, Dr. Sweet, for his most valuable contributions upon this subject. Unfortunately for many of us, we do not have an expert in using the *x*-ray, and therefore are obliged to treat our cases without an *x*-ray examination. This has been my experience. In the first series of cases reported to this Society in 1891, and in the second series of cases in 1892, and in another series of cases reported and published elsewhere, in fully three-fourths of them the metal was not seen by the ophthalmoscope, and its probable location was determined from the position of the person at the time of the accident and the nature and extent of the wound of the eyeball. In by far the larger number of my cases the metal has been removed from an incision made in the inferior outer temporal quadrant by Bradford's or Johnson's electromagnet. It seems to me that the cases that come to me are better adapted to this method and I get better results than I would by using the large Haab magnet. I realize that each case must be studied by itself, and the aim should be to remove the metal with the least traumatism to the eye. The incision in the inferior temporal quadrant of the eye has always healed readily, and I am not aware of any bad after-effects from this wound.

IMPROVED LANTERN FOR TESTING THE COLOR-PERCEPTION. MODEL OF 1909.

CHARLES H. WILLIAMS, M.D.,
Boston, Mass.

The present lantern (model of 1909) is the result of a gradual evolution, extending over seventeen years, of a practical and reliable form of lantern for use as a necessary supplementary test in determining the acuteness of color-perception in persons employed or seeking employment in the railway or marine service.

Tests of the color-sense should determine:

1. The acuteness of the color-sense by a comparison test, without using color names.

2. The ability to recognize and name, quickly and accurately, the various colors, especially those used in service as signals.

The test which has been most generally used and found most serviceable for the first determination is that of Holmgren with the colored worsteds. It is based on the fact that those who are defective in their color perception, for either red or green, see in the green portion of the spectrum a neutral gray or brownish band, and when they are shown a test skein of the shade of green which corresponds to this neutral band, they pick out, as looking like it, greens, grays, or light browns, all of which look alike to them, and thus disclose their defect. To get the best result it is necessary that the shade of green of the test skein should be carefully selected.

The writer imported, some years ago, sets of worsteds from Upsala which had been made according to the personal directions of Professor Holmgren. The green test skein in these sets is of a darker shade than the green test skeins used in many American sets of these worsteds, some of which must have been

prepared by reference to the lithographic plate printed in Holmgren's book, rather than by reference to the color of the worsted which he actually selected for his test skein. Again, in the imported Holmgren sets there are 135 colors, but in some of the sets used in this country the number of skeins has been reduced to 40 colors, the result being that the test with the reduced sets is not so sure or reliable as when the larger number of colors is used. A person may sometimes pass the Holmgren test and at the same time be found to make mistakes with the colors of distant signals, and a sufficient number of such cases has been found to make it necessary to use a test with colored lights in addition to the worsteds. In cases of small, central, beginning scotoma, such as are sometimes found with excessive use of tobacco, or from other causes, the affected area may be so small that the retinal image of the skein of worsted will extend beyond it, and the color can be then easily recognized, but the image of the small, distant, signal light may be focused entirely within the affected area, so that its color may be mistaken.

Tests with the lantern in a dark room make an easy and reliable way of recognizing these defects, and one which corresponds very closely to the conditions of service. This test is also very convincing to the employer, to the employee and his friends, and to the examiner, for when three red lights of different shades are shown to a man at one time with this lantern, and he says that there are two greens and one red (as has happened in one of my cases), it demonstrates a condition which admits of no argument.

The present form of the lantern (model of 1909) is the fifth modification which experience in its use has led me to adopt. It differs from the model of 1903 only in being able to show one, two, or three colored lights at one time. This is, however, a valuable improvement, for defects in color-sense are more easily recognized, and the chances of guessing are less, when three contrasting colors are shown than when only one color is shown. In this lantern it is also possible to have the colored area of three

sizes; for instance, they may all be large, medium, or small, or one may be large and two small, etc. The intensity of the light can also be varied by fixed amounts by means of the rheostat in the base of the electric light in the lantern. An oil lamp is furnished where no electric current is available, but the electric incandescent illumination is preferred, as it can be better regulated and has no smell.

Improved lantern for testing color perception.

The cut shows the shape and arrangement of the lantern. On the front is a disc carrying eighteen colored glasses, most of them taken from roundels and signal glasses in common use. Under each glass is a small illuminated number, screened from the person examined, by which a record of the examination

can be made. At the top is a rod connecting with a shutter inside the lantern, by which either one or two lights of different sizes can be shown, and over the disc is a knob by which a second shutter can be moved to show a third light of either of the desired sizes.

In the disc the colors are placed as shown below, but they may be shown in any order desired by a different rotation of the disc. The number in parenthesis shows the number of the different combinations of colors which can be shown at one time, and the number over each color is the number of the illuminated color in the disc. There are seven of different shades, five greens, two blues, one purple, one yellow, one smoke, and one uncolored glass.

1 (1) Red	1 17 (19) Red and Red	1 9 17 (37) Red, Green, Red
2 (2) Green	2 18 (20) Green and Blue	2 10 18 (38) Green, White, Blue
11 (3) Red	11 9 (21) Red and Green	11 1 9 (39) Red, Red, Green
12 (4) Green	12 10 (22) Green and White	12 2 10 (40) Green, Green, White
3 (5) Red	3 1 (23) Red and Red	3 11 1 (41) Red, Red, Red
4 (6) Green	4 2 (24) Green and Green	4 12 2 (42) Green, Green, Green
13 (7) White	13 11 (25) White and Red	13 3 11 (43) White, Red, Red
14 (8) Red	14 12 (26) Red and Green	14 4 12 (44) Red, Green, Green
5 (9) Red	5 3 (27) Red and Red	5 13 3 (45) Red, White, Red
6 (10) Yellow	6 4 (28) Yellow and Green	6 14 4 (46) Yellow, Red, Green
15 (11) Green	15 13 (29) Green and White	15 5 13 (47) Green, Red, White
16 (12) Red or purple	16 14 (30) Red and Red	16 6 14 (48) Red, Yellow, Red
7 (13) Blue	7 5 (31) Blue and Red	7 15 5 (49) Blue, Green, Red
8 (14) Red	8 6 (32) Red and Yellow	8 16 6 (50) Red, Red, Yellow
17 (15) Red	17 15 (33) Red and Green	17 7 15 (51) Red, Blue, Green
18 (16) Blue	18 16 (34) Blue and Red	18 8 16 (52) Blue, Red, Red
9 (17) Green	9 7 (35) Green and Blue	9 17 7 (53) Green, Red, Blue
10 (18) Smoke or white	10 8 (36) White and Red	10 18 8 (54) White, Blue, Red

It must be understood that the red of No. 1, No. 8, No. 5, etc., is not a repetition of the same color, but quite a different shade. So also there is a variation in the greens, but not so marked as with the reds. By studying out the above combinations it will be found that there are fifty-four possible different color combinations, and that the area and the intensity of the colors can also be varied.

The previous model (1903), with the same number of colors in the same order, but showing only one or two colors at one time, has been in use for some years, as an addition to the Holmgren worsteds, on nine large railway systems in this country, and also on the Australian railways. It is also used in the examination of masters of vessels, pilots, etc., in the Boston district.

In using the lantern it is best to show the three lights at one time with the full or medium sized opening, then to show one or two lights with the medium or small area. The record of the name, or use, given to the light by the person examined, should be made as the examination proceeds, the name given being noted on the record in connection with the number of the color shown. As the glasses do not fade, the lantern gives a permanent record of the color examination which can be referred to at any time. In using the lantern no one should be rejected for such mistakes as calling a green blue, or vice versa, but the confusion of red and green shows a defect which is dangerous.

This lantern is made by Peter Gray & Sons, Third and Binney Streets, East Cambridge, Mass.

The record of the following typical case, sent to the writer a few days ago, shows the value of this lantern test. The man had been tested for color-perception originally by the railway examiner and rejected; later he was passed on another division and remained for some years in the railway service. Finally he was sent to me to determine whether or not he was fitted to be one of the *examiners* to test the vision and color-sense of men entering the service, or in the service.

His acuteness of vision was normal ($\frac{20}{20}$) in each eye without

glasses. With the tagged Holmgren worsteds he selected as similar to the green test skein Nos. 42, 41, 11, 55, 63, 59, 97, 99, 7, 57, 19, 13, 45, 17, and 5, and as similar to the rose test skein Nos. 87, 21, 33, 77, 29, 37, 89, 75, 31, 73, 23, and 85. In other words, with the worsteds he selected one confusion color and fourteen greens as similar to the green test skein, and made no mistakes with the rose test skein. His selection was hesitating, but not extremely so. With the lantern showing three lights at one time, with the largest openings and medium illumination, *he called three red lights green*, Nos. 3, 16, and 17; he called the following green lights yellow: No. 2 three times, No. 4 twice, No. 9 twice, No. 12 twice; he called the red No. 17 white once; he called the green lights Nos. 12 and 15 white; he called the red light No. 1 yellow twice, red No. 5 yellow once, and red No. 11 yellow once.

That is to say, in this one test he called a red danger-signal green three different times, a green light yellow nine times, a red light yellow four times, a green light white once, and a red light white once. This test was entirely convincing and sustained the test which was made by the first examiner with the colored Holmgren worsteds and a lantern of older pattern.

The details of many other cases might be given, but the above will serve as a typical case to show the value of the lantern test.

TRANSACTIONS

of the

American Ophthalmological Society

Forty-Sixth Annual Meeting

WASHINGTON, D. C., 1910

VOL. XII, PART II

Philadelphia
American Ophthalmological Society
1910

BOSTON MEDICAL
NOV 28 1910
LIBRARY.

CATALOGUED
NOV 28 1910
J. F. B.

PRESS OF WM. F. FELL CO.
PHILADELPHIA

TABLE OF CONTENTS.

PAGE

List of Officers and Members 341

Necrology 347

Minutes of the Proceedings 355

The Post-Operative History of Eighteen Cases of Magnetic Foreign Bodies Removed from the Eye by the Haab or Giant Magnet: Dr. Charles Stedman Bull 365

The Possible Influence of Racial and Other Characteristics in Accounting for the Success of the Smith-Indian Operation: Dr. C. F. Clark 385

Large Piece of Wood Embedded Deeply in Orbit of Child Twenty-five Months. Removed, with Preservation of Vision: Dr. C. A. Veasey .. 395

Conjunctival Flaps in Ophthalmic Surgery: Dr. W. Gordon M. Byers 398

Report of a Case of Leukosarcoma of the Iris Successfully Removed by Iridectomy and Useful Vision Retained: Dr. James Thorington 409

New-Growths of the Lacrimal Gland—A Case. Death: Dr. Edwin E. Jack. Pathologic Report by Dr. F. H. Verhoeff 414

Congenital Pigmentation of the Cornea: Dr. T. B. Holloway 423

Report of a Case of Epibulbar Sarcoma: Dr. C. A. Veasey 436

Cylindroma of the Orbit: Drs. J. Herbert Claiborne and E. L. Oatman 441

Tumor of the Adrenal Gland with Metastasis in the Orbit: Dr. Alexander Quackenboss. Pathologic Examination by Dr. F. H. Verhoeff 451

A Critical Study of the Ocular Asymmetry of the Formosan Savage: Dr. Charles A. Oliver 455

Some Impressions of Certain Eye Affections in the Negro as Compared with the White Race: Dr. James L. Minor 459

The Difficulty Sometimes met with in the Diagnosis of a Subretinal Mass: Dr. Robert L. Randolph 466

Glaucoma from Adhesion of the Lens Capsule to the Cornea: Dr. Arnold Knapp 472

Some Observations of the Ocular Manifestations of Sinus Disease; Dr. G. E. de Schweinitz 477

Implantation of a Metal Ball in Tenon's Capsule (The Frost-Lang Operation) with Report of 48 cases: Dr. William M. Sweet 492

Report of Two Cases of Chronic Cyanosis with Polycythemia, including Ophthalmoscopic Examination: Drs. Walter R. Parker and George Slocum (by invitation) 505

The Nerve-Head in Wood-Alcohol Amaurosis: Dr. Percy Fridenberg 513

PAGE

Ocular Signs Frequently Associated with Vasomotor Disturbances: Dr. Howard F. Hansell..... 526

A Case of Spasm of the Retinal Arteries: Dr. Henry Dickson Bruns..... 535

Some Observations on the Use of the Schiötz Tonometer: Dr. W. B. Marple..... 552

The Histologic Findings in a Case of Tuberculous Cyclitis, and a Theory as to the Origin of Tuberculous Scleritis and Keratitis: Dr. F. H. Verhoeff..... 566

Recurrent Tubercular Choroiditis: Dr. Carl Koller..... 586

Vaccine and Serum Therapy in Ophthalmology: Dr. John E. Weeks..... 598

Vaccine and Serum Therapy in Ocular Tuberculosis: Dr. George S. Derby..... 614

Suggestions Regarding the Nature of Visual Sensations: Dr. George T. Stevens..... 644

A Window Resection of the Nasal Duct in Cases of Stenosis: Dr. J. M. West (by invitation)..... 654

Illuminated Box Eye-Testing Chart: Dr. Harris G. Sherman..... 658

A Brief Note Concerning the Tropometer: Dr. George T. Stevens..... 667

On the Different Prism Tests, with Presentation of a Series of Prisms Arranged on a Circular Disc: Dr. Lucien Howe..... 669

Standardizing of Test-Types and Records of Visual Acuity: Dr. Edward Jackson..... 674

Colored Toric Glass for Use in Examining Cases of Ocular Paralysis..... 677

American Ophthalmological Society.

FOUNDED 1864.

OFFICERS.

1910—1911.

President,	DR. E. GRUENING,	New York, N. Y.
Vice-President,	DR. EDWARD JACKSON,	Denver, Col.
Secretary-Treasurer,	DR. WM. M. SWEET,	Philadelphia, Pa.
Corresponding Secretary,	DR. A. KNAPP,	New York, N. Y.

MEMBERS.

* Associate Members. O. M. Original Members.

ELECTED.	NAME.	RESIDENCE.	PLACE.
1896	DR. A. E. ADAMS,	44 Grand Street,	Newburg, N. Y.
1902	DR. J. L. ADAMS,	38 East 51st Street,	New York, N. Y.
1899	DR. A. N. ALLING,	257 Church Street,	New Haven, Conn.
1896	DR. G. W. ALLYN,	Empire Building,	Pittsburg, Pa.
1882	DR. A. ALT,	Metropolitan Bldg.,	St. Louis, Mo.
1883	DR. J. A. ANDREWS,	1229½ State Street,	Santa Barbara, Cal.
1881	DR. S. C. AYRES,	4 West 7th Street,	Cincinnati, Ohio.
1907	*DR. C. H. BEARD,	34 Washington Street,	Chicago, Ill.
1908	*DR. GEO. H. BELL,	12 West 46th Street,	New York, N. Y.
1905	*DR. JAS. H. BELL,	Moore Building,	San Antonio, Texas.
1909	*DR. JAMES BORDLEY, JR.,	330 N. Charles Street,	Baltimore, Md.
1881	DR. H. W. BRADFORD,		Wolfboro, N. H.
1908	*DR. E. V. L. BROWN,	100 State Street,	Chicago, Ill.
1903	*DR. GUSTAVE E. BRUÈRE,	Electric Building,	Portland, Oregon.
1907	*DR. WM. E. BRUNER,	New England Bldg.,	Cleveland, Ohio.
1901	*DR. H. D. BRUNS,	211 Camp Street,	New Orleans, La.
1910	*DR. E. U. BUCKMAN,	96 S. Franklin Street,	Wilkesbarre, Pa.
1871	DR. CHARLES S. BULL,	47 West 36th Street,	New York, N. Y.
1909	*DR. G. H. BURNHAM,		Toronto, Can.
1906	DR. W. K. BUTLER,	1207 M Street, N. W.,	Washington, D. C.
1906	DR. W. GORDON M. BYERS,	346 Mountain Street,	Montreal, Canada.
1909	*DR. L. W. CALLAN,	452 Fifth Avenue,	New York, N. Y.
1876	DR. PETER A. CALLAN,	452 Fifth Avenue,	New York, N. Y.
1885	DR. F. P. CAPRON,	118 Angell Street,	Providence, R. I.

Elected.	Name.	Residence.	Place.
O.M.	Dr. W. H. Carmalt,	87 Elm Street,	New Haven, Conn.
1898	Dr. J. T. Carpenter, Jr.,	1624 Walnut Street,	Philadelphia, Pa.
1904	Dr. Burton Chance,	235 So. 13th Street,	Philadelphia, Pa.
1893	Dr. H. B. Chandler,	34½ Beacon Street,	Boston, Mass.
1904	Dr. J. W. Charles,	509 Humboldt Bldg.,	St. Louis, Mo.
1893	Dr. Wm. Cheatham,	303 W. Chestnut Street,	Louisville, Ky.
1893	Dr. F. E. Cheney,	126 Commonw'th Ave.,	Boston, Mass.
1898	Dr. J. H. Claiborne,	34 West 36th Street,	New York, N. Y.
1891	Dr. C. F. Clark,	188 East State Street,	Columbus, Ohio.
1875	Dr. David Coggin,	7 Chestnut Street,	Salem, Mass.
1903	Dr. Wm. G. Craig,	15 Fuller Building,	Springfield, Mass.
1890	Dr. C. M. Culver,	36 Eagle Street,	Albany, N. Y.
1906	Dr. R. J. Curdy,	301 Keith & Perry Bldg.,	Kansas City, Mo.
1902	Dr. Colman W. Cutler,	8 East 54th Street,	New York, N. Y.
1908	*Dr. Jno. P. Davidson,	316 E. Franklin Street,	Richmond, Va.
1907	*Dr. A. E. Davis,	50 West 37th Street,	New York, N. Y.
1878	Dr. W. S. Dennett,	8 East 49th Street,	New York, N. Y.
1909	*Dr. George S. Derby,	7 Hereford Street	Boston, Mass.
O.M.	Dr. Hasket Derby,	Back Bay P. O.,	Boston, Mass.
1874	Dr. Lewis S. Dixon,	232 Clarendon Street,	Boston, Mass.
1902	Dr. Alexander Duane,	139 E. 37th Street,	New York, N. Y.
1908	*Dr. J. L. Duncan,	Jenkins Bldg.,	Pittsburgh, Pa.
1887	Dr. J. B. Emerson,	20 East 30th Street,	New York, N. Y.
1890	Dr. Arthur E. Ewing,	Metropolitan Bldg.,	St. Louis, Mo.
1896	Dr. T. H. Fenton,	1319 Spruce Street,	Philadelphia, Pa.
1893	Dr. George F. Fiske,	100 State Street,	Chicago, Ill.
1909	*Dr. M. L. Foster,	616 Madison Ave.,	New York, N. Y.
1904	Dr. W. H. Fox,	1826 Jefferson Place,	Washington, D. C.
1902	Dr. Percy Fridenberg,	60 East 58th Street,	New York, N. Y.
1894	Dr. H. Friedenwald,	1029 Madison Ave.,	Baltimore, Md.
1883	Dr. B. E. Fryer,	520 East 9th Street,	Kansas City, Mo.
1895	Dr. G. M. Gould,	Sentinels, Cayuga Hts.,	Ithaca, N. Y.
1896	Dr. H. Y. Grant,	Falls View,	Ontario, Canada.
1908	*Dr. L. S. Greene,	1610 I Street, N. W.,	Washington, D. C.
1905	Dr. Allen Greenwood,	101 Newbury Street,	Boston, Mass.
1875	Dr. Emil Gruening,	36 East 57th Street,	New York, N. Y.
1903	*Dr. C. W. Haddock,		Beverly, Mass.
1892	Dr. G. W. Hale,	214 Wilcox Building,	Nashville, Tenn.
1895	Dr. Wm. D. Hall,	416 Marlborough Street,	Boston, Mass.
1887	Dr. H. F. Hansell,	1528 Walnut Street,	Philadelphia, Pa.
1901	Dr. Herbert Harlan,	516 Cathedral Street,	Baltimore, Md.
1889	Dr. David Harrower,	9 Elm Street,	Worcester, Mass.
1896	Dr. N. D. Harvey,	119 Waterman Street,	Providence, R. I.
1904	Dr. H. H. Haskell,	34 Commonwealth Ave.,	Boston, Mass.

Elected.	Name.	Residence.	Place.
1890	Dr. Neil J. Hepburn,	317 West 23d Street,	New York, N. Y.
1896	Dr. Ward Holden,	43 West 48th Street,	New York, N. Y.
1909	*Dr. T. B. Holloway,	1819 Chestnut Street,	Philadelphia, Pa.
1906	*Dr. C. R. Holmes,	8 East 8th Street,	Cincinnati, Ohio.
1883	Dr. E. E. Holt,	723 Congress Street,	Portland, Me.
1878	Dr. Lucien Howe,	87 West Huron Street,	Buffalo, N. Y.
1895	Dr. A. A. Hubbell,	212 Franklin Street,	Buffalo, N. Y.
1891	Dr. D. W. Hunter,	80 West 40th Street,	New York, N. Y.
1898	Dr. J. W. Ingalls,	874 Lafayette Avenue,	Brooklyn, N. Y.
1895	Dr. E. E. Jack,	215 Beacon Street,	Boston, Mass.
1885	Dr. Edward Jackson,	1434 Glenarm Street,	Denver, Col.
O.M.	Dr. B. Joy Jeffries,	15 Chestnut Street,	Boston, Mass.
1892	Dr. W. B. Johnson,	170 Broadway,	Paterson, N. J.
1908	*Dr. B. R. Kennon,	Taylor Building,	Norfolk, Va.
1901	Dr. H. W. Kilburn,	192 Marlborough Street,	Boston, Mass.
1873	Dr. Charles J. Kipp,	560 Broad Street,	Newark, N. J.
1903	Dr. Arnold Knapp,	26 West 40th Street,	New York, N. Y.
1869	Dr. H. Knapp,	26 West 40th Street,	New York, N. Y.
1889	Dr. Carl Koller,	681 Madison Avenue,	New York, N. Y.
1888	Dr. Chas. W. Kollock,	Wentw'th & Com'. Sts.,	Charleston, S. C.
1891	Dr. W. E. Lambert,	47 West 38th Street,	New York, N. Y.
1902	*Dr. W. B. Lancaster,		Amherst, Mass.
1903	*Dr. J. C. Lester,	616 Madison Avenue,	New York, N. Y.
1898	Dr. F. N. Lewis,	616 Madison Avenue,	New York, N. Y.
1907	*Dr. G. F. Libby,	1434 Glenarm Street,	Denver, Col.
1883	Dr. J. A. Lippincott,	Jenkins Building,	Pittsburg, Pa.
1878	Dr. F. B. Loring,	1420 K Street,	Washington, D. C.
1909	*Dr. R. G. Loring,	2 Arlington Street,	Boston, Mass.
1899	Dr. D. B. Lovell,	32 Pearl Street,	Worcester, Mass.
1908	*Dr. J. B. Lynch,	148 West 22d Street,	New York, N. Y.
1891	Dr. F. W. Marlow,	731 University Block,	Syracuse, N. Y.
1878	Dr. W. V. Marmion,	1211 13th Street, N. W.,	Washington, D. C.
1896	Dr. W. B. Marple,	46 W. 53d Street,	New York, N. Y.
1868	Dr. Arthur Mathewson,	Cosmos Club,	Washington, D. C.
1905	Dr. S. C. Maxson,	225 Genesee Street,	Utica, N. Y.
1907	*Dr. C. H. May,	698 Madison Avenue,	New York, N. Y.
1887	Dr. Chas. H. McIlwaine,	703 6th Avenue,	Asbury Park, N. J.
1906	Dr. Jno. R. McIntosh,	40 Coburg Street,	St. John, N. B.
1874	Dr. C. S. Merrill,	21 Washington Avenue,	Albany, N. Y.
1908	*Dr. H. S. Miles,	417 State Street,	Bridgeport, Conn.
1888	Dr. B. L. Millikin,	1110 Euclid Avenue,	Cleveland, Ohio.
1883	Dr. J. Lancelot Minor,	Randolph Building,	Memphis, Tenn.
1881	Dr. W. F. Mittendorf,	140 Madison Avenue,	New York, N. Y.
1885	Dr. Charles A. Oliver,	1507 Locust Street,	Philadelphia, Pa.

Elected.	Name.	Residence.	Place.
1887	Dr. H. S. Oppenheimer,	11 East 43d Street,	New York, N. Y.
1910	*Dr. Frank J. Parker,	156 W. 58th Street,	New York, N. Y.
1908	*Dr. W. R. Parker,	Ch'mb'r. of Commerce,	Detroit, Mich.
1908	*Dr. S. McA. Payne,	542 Fifth Avenue,	New York, N. Y.
1895	Dr. R. J. Phillips,	123 So. 39th Street,	Philadelphia, Pa.
1869	Dr. Thomas R. Pooley,	109 Madison Avenue,	New York, N. Y.
1898	Dr. W. Campbell Posey,	2049 Chestnut Street,	Philadelphia, Pa.
1887	Dr. M. H. Post,	Metropolitan Bldg.,	St. Louis, Mo.
1895	Dr. H. R. Price,	435 Clinton Avenue,	Brooklyn, N. Y.
1868	Dr. J. S. Prout,	26 Schermerhorn Street,	Brooklyn, N. Y.
1906	*Dr. Brown Pusey,	72 Madison Street,	Chicago, Ill.
1902	Dr. Walter L. Pyle,	1913 Chestnut Street,	Philadelphia, Pa.
1901	Dr. Alex. Quackenboss,	277 Dartmouth Street,	Boston, Mass.
1906	Dr. McCluney Radcliffe,	1812 Chestnut Street,	Philadelphia, Pa.
1885	Dr. Alex'r Randall,	1717 Locust Street,	Philadelphia, Pa.
1892	Dr. R. L. Randolph,	816 Park Avenue,	Baltimore, Md.
1891	Dr. J. M. Ray,	Atherton Bldg.,	Louisville, Ky.
1901	Dr. R. G. Reese,	147 W. 57th Street,	New York, N. Y.
1889	Dr. R. A. Reeve,	48 Bloor Street East,	Toronto, Canada.
1899	Dr. H. O. Reik,	412 Cathedral Street,	Baltimore, Md.
1884	Dr. Stephen O. Richey,	732 17th Street,	Washington, D. C.
1891	Dr. Wheelock Rider,	26 Gibbs Street,	Rochester, N. Y.
1901	*Dr. G. O. Ring,	2014 Chestnut Street,	Philadelphia, Pa.
1895	Dr. H. W. Ring,	187 Church Street,	New Haven, Conn.
1908	*Dr. J. Norman Risley,	1728 Chestnut Street,	Philadelphia, Pa.
1880	Dr. Samuel D. Risley,	1728 Chestnut Street,	Philadelphia, Pa.
1887	Dr. Edmund C. Rivers,	1632 Welton Street,	Denver, Col.
1900	Dr. Wm. K. Rogers,	188 East State Street,	Columbus, Ohio.
1899	Dr. Dunbar Roy,	Gr. Opera House Blk.,	Atlanta, Ga.
1875	Dr. John D. Rushmore,	129 Montague Street,	Brooklyn, N. Y.
1880	Dr. Robert Sattler,	30, The Groton,	Cincinnati, Ohio.
1898	Dr. T. B. Schneideman,	1831 Chestnut Street,	Philadelphia, Pa.
1889	Dr. G. E. de Schweinitz,	1705 Walnut Street,	Philadelphia, Pa.
1895	Dr. P. N. K. Schwenk,	810 North 7th Street,	Philadelphia, Pa.
1909	*Dr. N. M. Semple,	Humboldt Building,	St. Louis, Mo.
1905	Dr. John R. Shannon,	25 W. 36th Street,	New York, N. Y.
1866	Dr. Henry L. Shaw,	19 Commonwealth Ave.,	Boston, Mass.
1906	Dr. H. G. Sherman,	736 Rose Building,	Cleveland, Ohio.
1902	Dr. Wm. A. Shoemaker,	1006 Carleton Bldg.,	St. Louis, Mo.
1902	Dr. Wm. T. Shoemaker,	2031 Chestnut Street,	Philadelphia, Pa.
1905	Dr. E. A. Shumway,	2007 Chestnut Street,	Philadelphia, Pa.
1896	Dr. F. D. Skeel,	147 West 57th Street,	New York, N. Y.
1910	*Dr. Albert C. Snell,	53 S. Fitzhugh St.,	Rochester, N. Y.

Elected.	Name.	Residence.	Place.
1909	*Dr. F. M. Spalding,	390 Commonw'lth Ave,	Boston, Mass.
1878	Dr. J. A. Spalding,	627 Congress Street,	Portland, Me.
1884	Dr. Myles Standish,	6 St. James Avenue,	Boston, Mass.
1901	*Dr. E. W. Stevens,	421 McPhee Building,	Denver, Col.
1873	Dr. George T. Stevens,	22 East 46th Street,	New York, N. Y.
1903	Dr. Edw. Stieren,	3603 Fifth Avenue,	Pittsburg, Pa.
1871	Dr. Geo. Strawbridge,	202 So. 15th Street,	Philadelphia, Pa.
1887	Dr. T. Y. Sutphen,	997 Broad Street,	Newark, N. J.
1900	Dr. Wm. M. Sweet,	1205 Spruce Street,	Philadelphia, Pa.
1888	Dr. Lewis H. Taylor,	83 So. Franklin Street,	Wilkes-Barre, Pa.
1880	Dr. Samuel Theobald,	Cathedral & How'd Sts.,	Baltimore, Md.
1893	Dr. Ch. Herman Thomas,	3634 Chestnut Street,	Philadelphia, Pa.
1898	Dr. A. G. Thomson,	1516 Locust Street,	Philadelphia, Pa.
1903	Dr. Edgar S. Thomson,	19 E. 44th Street,	New York, N. Y.
1898	Dr. Jas. Thorington,	120 So. 18th Street,	Philadelphia, Pa.
1908	*Dr. Andrew Timberman,	112 East Broad Street,	Columbus, Ohio.
1906	Dr. H. H. Tyson,	47 West 51st Street,	New York, N. Y.
1884	Dr. John Van Duyn,	318 James Street,	Syracuse, N. Y.
1898	Dr. C. A. Veasey,	Traders Bank Bldg.,	Spokane, Wash.
1905	Dr. F. H. Verhoeff,	95 Mountfort Street,	Boston, Mass.
1866	Dr. O. F. Wadsworth,	526 Beacon Street,	Boston, Mass.
1903	Dr. F. L. Waite,	68 Pratt Street,	Hartford, Conn.
1873	Dr. David Webster,	308 Madison Avenue,	New York, N. Y.
1893	Dr. J. E. Weeks,	46 East 57th Street,	New York, N. Y.
1900	*Dr. C. D. Westcott,	31 Washington Street,	Chicago, Ill.
1892	Dr. J. A. White,	200 E. Franklin Street,	Richmond, Va.
1895	Dr. W. H. Wilder,	1417 Peoples Gas Bldg.,	Chicago, Ill.
1910	*Dr. Carl Williams,	School L. & Greene St.,	Philadelphia, Pa.
1874	Dr. Chas. H. Williams,	1069 Boylston Street,	Boston, Mass.
1893	Dr. Wm. H. Wilmer,	1610 I Street, N. W.,	Washington, D. C.
1888	Dr. F. M. Wilson,	834 Myrtle Avenue,	Bridgeport, Conn.
1906	*Dr. J. Scott Wood,	172 Sixth Avenue,	Brooklyn, N. Y.
1898	*Dr. William L. Wood,	412 Oregonian Bldg.,	Portland; Oregon.
1900	Dr. Hiram Woods,	842 Park Avenue,	Baltimore, Md.
1881	Dr. J. P. Worrell,	20 South 7th Street,	Terre Haute, Ind.
1905	Dr. Wm. Zentmayer,	1819 Spruce Street,	Philadelphia, Pa.
1903	Dr. S. Lewis Ziegler,	1625 Walnut Street,	Philadelphia, Pa.
	Total		191

HONORARY MEMBERS.

1866	Dr. Jno. Green,	Metropolitan Bldg.,	St. Louis, Mo.
1869	Dr. H. Knapp,	26 W. 40th Street,	New York, N. Y.
O.M.	Dr. F. P. Sprague,	229 Commonw'lth Ave.,	Boston, Mass.
	Whole number		194

Dr. George Cuvier Harlan.

CAT.

NECROLOGY.

DR. GEORGE CUVIER HARLAN.

CHARLES A. OLIVER, M.D.,
Philadelphia.

Dr. George Cuvier Harlan, one of the most important and prominent members of our society, died on September 25, 1909.

Dr. Harlan was born in Philadelphia, Pennsylvania, on January 28, 1835. He was a son of the distinguished physician and scientist, Dr. Richard Harlan. In 1855 he received the degree of B.A. from Delaware College, obtaining the Master's degree three years later. He graduated in medicine from the University of Pennsylvania in 1858, his inaugural thesis being upon the subject of the "Iris."

On April 6, 1857, apparently several months before he graduated in medicine, he was appointed resident physician at Wills' Hospital. From March 4, 1861, to 1864, he enjoyed a full surgeoncy, returning to active work in the same capacity in 1868, and remaining uninterruptedly in office for twenty-three years, resigning on May 8, 1901. On the ninth of the following October he was made consulting surgeon to the institution, which position he occupied until the time of his death. He also held residencies in the Pennsylvania and St. Joseph's hospitals, occupying the latter position during the term of service of 1858–1859. Later, he became Attending Surgeon to the St. Mary's and the Children's hospitals.

On May 21, 1861 (at the beginning of the War of the Re-

bellion), he was appointed an Acting Assistant Surgeon in the United States Navy, being assigned to the gun-boat Union. He resigned on the fifteenth of August of the same year, and on the fourteenth of the following September was made Major and Surgeon in the Eleventh Pennsylvania Cavalry. During the war he was captured and sent to the well-known Libby Prison in Richmond, Virginia. He was honorably mustered out on September 28, 1864. In June of 1863 he received the appointment of Acting Medical Inspector, followed, in five years' time, by the position of Pension Examining Surgeon.

In 1875 he became ophthalmologist (afterward consulting ophthalmologist) to the Pennsylvania Institution for the Instruction of the Blind, at which place he made many scientific investigations and did much clinical work. His interest in the welfare of the eyes of the children there placed under his charge never lessened.

Four years later he became connected with the Eye and Ear Department of the Pennsylvania Hospital, which he raised to the high standard of efficiency that it at present maintains. He served in the same capacity at the Children's Hospital. At the time of his death he occupied the position of Emeritus Surgeon at the former institution.

His ophthalmic work, so cheerfully done at the Pennsylvania Institution for the Deaf and Dumb as consulting ophthalmologist, was commenced in 1883, and continued until the time of his death.

He had the honor of occupying the first chair of ophthalmology (later emeritus) at the Philadelphia Polyclinic and School for Graduates in Medicine. His remarkable teaching abilities will be long remembered by many of his students. His exposition of the subject was properly limited to practicalities, no attempt for self-laudation or exhibition of rapid and useless—and, as we have too often seen, destructive—operative procedure ever being made.

Among his most important memberships in societies may be mentioned: The College of Physicians of Philadelphia in 1865, the American Ophthalmological Society in 1873, the Wills' Hospital Ophthalmic Society from its foundation, the International Congress of Ophthalmology in 1876, the Philadelphia County Medical Society in 1876, the Medical Society of the State of Pennsylvania and the American Medical Association, and the American Otological Society in 1882.

He was a member of the University Club of Philadelphia, and a Companion of the First Class of the Military Order of the Loyal Legion of the United States.

He enjoyed many honors. In 1885 he was made a member of the Committee on Library of the College of Physicians of Philadelphia, acting as Chairman of the Committee for many years. In 1893 he was elected President of the American Ophthalmological Society, and in 1904 he was appointed Chairman of the Section on Ophthalmology at the Universal (Louisiana Purchase) Exposition, held in St. Louis, Missouri. He was President of the Association of Wills' Hospital Residents and Ex-residents, and had the honor of being dean of the active membership of a similar association connected with the St. Joseph's Hospital of Philadelphia. He was a member of the managerial board of the American Hospital for Diseases of the Stomach up to the time of his death.

His contributions to his special branch of medicine have been important and numerous. For a long period of time his little book, entitled "Eyesight and How to Care for It," published in 1879, enjoyed a large and useful circulation. His two articles on "Diseases of the Eyelids" and "Operations Performed upon the Eyelids," in the third volume of Norris and Oliver's "System of Diseases of the Eye," must be ranked among the highest and the most practical expositions of the subject that we have in ophthalmology. At

the time of his death he was associated with the editorial staff of the widely known journal, "Ophthalmology." His operation for symblepharon and his tests for malingering are broadly known and are extensively employed.

Dr. Harlan was a widower. One son and two daughters survive him.

Repeating what the memorialist once said:* "As an operator he stands *par excellence* as one of the most careful, the most conscientious, and the most successful of all special surgeons. This the memorialist well knows from a long personal experience, during which he had been personally associated with him in much of his operative work. He was ever eminent for all manner of important hints, judicious helps, and best methods of procedure. Always calm amid danger, sure as to action, and ofttimes turning an apparently disastrous result into an advantageous one, he was *facile princeps*. The cunning of his hands was constantly in absolute correlation with deliberate, and yet rapid, judgment. Many a time when, through some misadventure, an apparently smooth piece of operative work has necessitated an impromptu difference of action, has he quickly discussed the modification, and made the change in such a manner as to give the utmost good of result. It was a pleasure for any conscientious and progressive man to be near and with him under such circumstances (and now, when often alone, or in association with fellow colleagues, does the memorialist find this good and great man's advice and fine counsel come echoing back to him. For one, he is and shall be forever grateful for many acts of loving affection, help, and kindness).

"As a man he was gentlemanly, noble, and unassuming. He knew true friendship in all of its meanings. His greatest preferences were conversation with a few companions of the highest grade, culture, and refinement, perusal of a book

* The Ophthalmic Record, December, 1909.

Dr. Samuel Benedict St John

CAT.

of biography, ethics, or travel, or a ride along the country byways amid nature and all of her beauties.

"His death—an accidental one, occasioned by a fall from the back of his favorite horse a few days before—stopped his chosen work, took him from us, and ruined his hoped-for happiness of an undisturbed and unimpaired old age in a quiet home near those who cared for him and loved him."

Of him it can be truly said: The best and the most depended-upon men are those who are the most quiet in ordinary life and who possess the greatest calmness amid danger.

DR. SAMUEL BENEDICT ST. JOHN.

CHARLES STEDMAN BULL, M.D.,
New York.

Dr. Samuel Benedict St. John was born in Hudson, Ohio, July 24, 1845, the son of Samuel and Amelia Palmer Curtis St. John, and was of Revolutionary ancestry.

His father, Dr. Samuel St. John, was a professor in the Western Reserve College of Ohio, and later in the Cleveland Medical College. Subsequently he was Professor of Chemistry in the College of Physicians and Surgeons of New York for twenty years.

Samuel Benedict St. John received his early education in the public schools of Cleveland, Ohio, and New Canaan, Conn. He then entered Yale University, and graduated A.B. in the class of 1866. He then matriculated at the College of Physicians and Surgeons of New York, and graduated M.D. in 1870.

Dr. St. John served on the house staff of Bellevue Hospital, New York, from April, 1870, to October, 1871, and afterward was appointed the first house surgeon in the Manhattan Eye and Ear Hospital.

In 1871 he served as assistant demonstrator of anatomy and as instructor in chemistry in the College of Physicians and Surgeons. In 1872 he went to Europe, and spent two years in the study of ophthalmology in the clinics of Berlin, Vienna, Paris, and London.

In 1874 he returned to New York, and in 1876 was appointed assistant surgeon in the Ophthalmic Department of the New York Eye and Ear Infirmary, where he served most faithfully for two years and a half.

In 1878 he removed to Hartford, Conn., where he soon became a leading man in his profession, and practised ophthalmology continuously until his death, on December 21, 1909, a period of thirty-one years.

He became a member of the New York Ophthalmological Society in February, 1877, and was its president in 1890–91.

He was an original member of the New England Ophthalmological Society in 1884, and its president in 1896.

He was elected a member of the American Ophthalmological Society in 1879, and became its secretary in 1888. In this office he served until 1908, being elected continuously for a period of twenty years. He was president of the American Ophthalmological Society in 1908–09.

Dr. St. John was a member of the Hartford City Medical Society, and its president in 1900; of the Hartford County Medical Society; of the Connecticut State Medical Society, and president of the latter in 1904.

He was appointed ophthalmic surgeon to the Hartford Hospital in 1896, and retained the position till his death.

He was appointed consulting surgeon to St. Francis Hospital in 1897, and held it to the end of his life.

In 1882 he was appointed instructor in ophthalmology in the Yale Medical School, and held the position till 1905—a period of twenty-three years.

In 1909 he was a delegate to the International Congress of Ophthalmology which met at Naples, and was one of the

judges appointed to bestow medals for the six best papers presented to the Congress.

In 1882 Dr. St. John married Miss Mary Harris Morgan, the daughter of Nathaniel H. and Harriet Morgan, and two daughters were born of this marriage.

Dr. St. John has contributed many papers to medical literature, mainly on subjects pertaining to ophthalmology. In 1872 he contributed a paper to the American Journal of the Medical Sciences on Plastic Apparatus in Surgery, which established the fact that he was the first to use plaster apparatus for fracture of the clavicle and of the ribs and other bones. This proved to be the initial step toward the development of the plaster jacket. Another valuable paper, entitled Restoration of the Upper Lid by a Pedicle Flap Taken from Below the Lower Lid, was read before the American Ophthalmological Society in 1893.

Dr. St. John was a quiet, modest, undemonstrative man, but was capable of very strong and deep feeling. He possessed to a marked degree those virtues which go to make up the character of a good man and a true physician. He was a good citizen, having held many positions of trust in Hartford, among them that of director and president of the Hartford Public Library.

He had a manly, courageous nature, and was possessed of excellent judgment and tact. His intercourse with his colleagues was marked by a gentle dignity and unfailing courtesy and kindness. He was a man of but few words, but those who knew him well also understood the true value of those few words, the sincerity of his nature, and the goodness of his heart.

He always stood for the highest ideals, and being an unselfish man, was never induced, by any prospects of personal aggrandizement, to depart from the straight path of professional conduct.

He loved the practice of his profession, and ever gave the

best that was in him to the service of his patients; and all so quietly and modestly that only his intimate friends had any idea of the amount or variety of the work.

He led a life of conspicuous integrity and usefulness, and he had his earthly reward in honor, love, respect, and hosts of friends. He was a true gentleman in the best sense of the word.

His death was peaceful, painless, and ideal, in that he passed away from us in his sleep.

MINUTES OF THE PROCEEDINGS

FORTY-SIXTH ANNUAL MEETING.

THE ARLINGTON,
Washington, D. C., May 3, 1910.

The Forty-sixth Annual Meeting of the Society was called to order at 10 A. M. by President Dr. Samuel Theobald, and the following committees were announced:

On Membership for Next Year—Drs. D. W. HUNTER, M. H. POST, G. E. DE SCHWEINITZ, PETER A. CALLAN, and HIRAM WOODS.

On Bulletin—DRS. G. E. DE SCHWEINITZ, W. C. POSEY, and WILLIAM M. SWEET.

Auditing Committee—DR. CHARLES J. KIPP.

Publication Committee—DRS. W. S. DENNETT, D. W. HUNTER, and WILLIAM M. SWEET.

The following papers were read and discussed:

1. "The post-operative history of eighteen cases of magnetic foreign bodies removed from the eye by the Haab or giant magnet," Dr. Charles Stedman Bull.

Discussed by Drs. Callan, Holt, Lambert, Weeks, Randolph, Jackson, Marple, Sweet, de Schweinitz, Kipp and Bull.

2. "Large piece of wood embedded deeply in the orbit of a child twenty-five months. Removed with preservation of vision," Dr. C. A. Veasey.

Discussed by Drs. Taylor, Lambert, and Post.

3. "Conjunctival flaps in ophthalmic surgery," Dr. W. Gordon M. Byers.

Discussed by Drs. Kipp, Sweet, Reeve, Koller, Weeks, Oliver, de Schweinitz, Theobald.

4. "Report of a case of leukosarcoma of the iris. Successful removal by iridectomy with useful vision," Dr. J. Thorington.

Discussed by Drs. Veasey and Wilson.

5. "New-growths of the lacrimal gland. A case. Death," Dr. Edwin E. Jack. Pathologic report by Dr. F. H. Verhoeff.

Discussed by Drs. Verhoeff and Kipp.

6. "Congenital pigmentation of the cornea," Dr. T. B. Holloway.

7. "Report of a case of epibulbar sarcoma," Dr. C. A. Veasey.

Discussed by Drs. de Schweinitz, Sweet, Verhoeff.

8. "Cylindroma of orbit. Report of a case and pathologic findings," Drs. J. H. Claiborne and E. L. Oatman.

9. "Tumor of the adrenal gland, with metastasis in the orbit," Dr. Alexander Quackenboss. Pathologic report by Dr. F. H. Verhoeff.

10. "A critical study of the ocular asymmetry of the Formosan savage," Dr. Charles A. Oliver. (Read by title.)

11. "Some impressions of certain eye affections in the negro, as compared with the white race," Dr. J. L. Minor.

Discussed by Drs. Bruns, Kollock, Theobald, and Howe.

The President announced that the following were invited to sit with the Society and take part in its discussions: Drs. Charles Nelson Spratt, S. H. Dickson, J. King Love, W. P. Reeve, H. V. Tweedie, M. Buchanan, and J. W. West.

EXECUTIVE SESSION.

The President, Dr. Samuel Theobald, presiding.

The Committee on Membership recommended the following candidates for admission to the Society:

Dr. Carl Williams, Philadelphia.

Dr. Frank J. Parker, New York City.

Dr. Albert C. Snell, Rochester, N. Y.

Dr. E. U. Buckman, Wilkesbarre, Pa.

On motion, the candidates recommended by the Committee were declared elected as Associate Members.

The Committee also referred the names of a number of candidates to the Committee for 1911.

The Executive Committee reported the following nominations for officers of the Society:

President: Dr. Emil Gruening.

Vice-President: Dr. Edward Jackson.

Secretary and Treasurer: Dr. W. M. Sweet.

Corresponding Secretary: Dr. Arnold Knapp.

It was moved that the Secretary be empowered to cast the ballot for the nominees, which motion was carried, and the officers declared duly elected.

Dr. Ward Holden offered the following resolution, which was seconded and carried:

"*Resolved*, that the President appoint a Committee to consider the subject of the prevention of blindness from wood-alcohol and to make suggestions for the relief of present conditions." (Carried.)

The President appointed this Committee as follows: Drs. E. Gruening, G. E. de Schweinitz, W. H. Wilder, and Wm. H. Wilmer.

Dr. Lucien Howe presented the report of the committee on ophthalmia neonatorum, and offered the following resolution, which was seconded and carried:

"*Whereas*, it is often stated that ophthalmia neonatorum still produces 25 per cent. or more of all the blindness of childhood, and that this blindness occurs even when certain silver salts are used by physicians according to so-called approved methods, and,

"*Whereas*, of late years different writers have advocated different procedures supposed to be better than that advised by Credè, and, as a result, different plans have been adopted more or less officially in different countries or different States, and,

"*Whereas*, The American Ophthalmological Society hav-

ing been the first in this country to call attention to the importance of preventing this disease, considers now that a better knowledge of the facts would tend to more uniform methods and probably lead to better results, therefore,

"*Resolved*, that the Committee on Ophthalmia Neonatorum of this Society be hereby instructed to communicate with ophthalmologists and others whose opinions on this subject are authoritative, in order to compare different views and methods, and by associated effort to bring about better results, if possible, in the prevention and treatment of this disease."

The Secretary presented the resignation of Dr. Herman Knapp.

Dr. Oliver moved its acceptance.

Dr. Ziegler moved that Dr. Knapp's name be transferred to the list of Honorary Members.

Dr. Oliver stated that his idea in moving the acceptance of the resignation was that this might be done.

The motion of Dr. Ziegler was seconded and carried.

The President announced the death during the year of Dr. S. B. St. John and Dr. George C. Harlan.

Dr. Howe: Inasmuch as Dr. St. John was our Secretary for so many years, I move that some suitable memorial be spread upon the minutes in appreciation of his long services to the Society, that a committee be appointed to prepare memorials of both Dr. St. John and Dr. Harlan, and that these be printed in the Transactions of the Society. (Carried.)

The President appointed on this committee Dr. Charles Stedman Bull and Dr. Charles A. Oliver.

The Treasurer's report was read, and the Auditing Committee, having certified to its correctness, it was accepted and placed on file.

On motion of the Secretary it was voted that the assessment for next year be five dollars.

The Executive Session then adjourned.

EXECUTIVE SESSION, WEDNESDAY MORNING, MAY 4TH

The President, Dr. Samuel Theobald, presiding.

Dr. Theobald announced the following committee to consider the time and place of the next meeting of the Society:

Drs. Callan, Risley, and Jackson.

The following resolution was offered by Dr. R. G. Loring:

"*Whereas*, the American Ophthalmological Society is strongly opposed to the so-called 'optometry' bills which are now being brought before our state legislatures, and,

"*Whereas*, this legislation is unnecessary, unwise, and involves a lowering of medical standards, and,

"*Whereas*, there can be no compromise with its advocates from the medical profession,

"*Resolved*, that if opticians must be registered, it should be as opticians and not under the new name of 'optometrists.'

"That if there must be recognition, it should be legal only and not medical, and that the medical profession should not lend its sanction by serving on optometry boards, or by taking 'optometry' boards under the supervision of state boards of medical registration."

Dr. C. F. Clark offered the following resolution:

"*Resolved*, that it is the unanimous opinion of the members of the American Ophthalmological Society that if the 'optometry' bill now before Governor Harmon, of Ohio, for his consideration should become a law, great harm would result to the public and lead to the lowering of medical standards."

Both resolutions were adopted, and it was moved and carried that Dr. Clark telegraph his resolution to Governor Harmon. The Secretary was instructed to furnish a copy of the first resolution to the Journal of the American Medical Association.

The Secretary asked that he be directed to dispose of, by sale or otherwise, up to 25 copies each of the issues of the

Transactions prior to 1900, and 50 copies of the issues since that date. (Carried.)

It was further moved that the Secretary provide sufficient copies of the Transactions to supply every member of the Society with one copy, and have sufficient surplus to supply libraries and a certain number on hand for future use. (Seconded and carried.)

The Committee on Time and Place of Meeting announced the choice of New London; and an informal vote upon the time showed a preference for July. The Committee then decided on July 11 and 12, 1911.

The Executive Session then adjourned.

Exhibition of Instruments, etc.

Dr. W. B. Marple exhibited the Schiötz tonometer.

Dr. J. M. West (by invitation) exhibited cases showing the results of operation of window resection of the nasal duct.

Discussed by Dr. Randolph.

Dr. F. H. Verhoeff showed a new instrument, the sclerectome, for producing a subconjunctival fistula for the relief of glaucoma.

Dr. W. Gordon M. Byers, Montreal, showed a new design of colored disc for testing diplopia.

Dr. Lucien Howe exhibited a circular disc of prisms for testing muscle defects.

Dr. Edward Jackson exhibited cards for standardizing of test-types and records of visual acuity.

The reading of papers was resumed.

12. "Possible influence of racial and other characteristics in accounting for the success of Smith-Indian operation," Dr. C. F. Clark.

Discussed by Drs. Sattler, Randolph, Harlan.

13. "A case which illustrates the difficulty sometimes met with in the diagnosis of a subretinal mass," Dr. Robert L. Randolph.

Discussed by Drs. Koller, Johnson, Marple, Weeks, Clark, Knapp, Verhoeff, Fridenberg, and Randolph.

14. "Glaucoma from adhesion of the lens capsule to the cornea," Dr. Arnold Knapp.

Discussed by Drs. Ziegler and Gruening.

15. "Some observations of the ocular manifestations of sinus disease," Dr. George E. de Schweinitz. (Read by title.)

16. "Implantation of a metal ball in Tenon's capsule after enucleation (Frost-Lang operation). With report of cases," Dr. William M. Sweet.

Discussed by Drs. Randolph, Davis, de Schweinitz, Ziegler, Theobald, Brown, Risley, and Sweet.

17. "Report of two cases of chronic cyanosis with polycythemia," Drs. Walter R. Parker and George Slocum (by invitation). (Read by title.)

18. "The nerve-head in wood-alcohol amaurosis," Dr. Percy Fridenberg.

Discussed by Drs. Brown, Gruening, de Schweinitz, Wilder, Wilmer, Ziegler, and Fridenberg.

19. "Ocular signs frequently associated with vasomotor disturbances," Dr. Howard F. Hansell.

Discussed by Dr. Clark.

20. "A case of spasm of the retinal arteries," Dr. Henry Dickson Bruns.

Discussed by Drs. Marple, Hansell, and Bruns.

21. "Some observations on the Schiötz tonometer," Dr. Wilbur B. Marple.

Discussed by Dr. Kipp.

The Secretary read the following note from Dr. E. L. Trudeau, President of the Congress:

"News has just been received that Dr. Howard T. Ricketts, while engaged in an investigation of an outbreak of Mexican typhus fever, has died of the disease in the City of Mexico. Dr. Ricketts has recently been called from the

University of Chicago to the Chair of Pathology in the University of Pennsylvania. His death while engaged in investigations for the benefit of mankind calls for some appropriate action on the part of the Congress expressive of his service and heroism.

"The President of the Congress would like as many members as possible from each association to meet at 2 P. M. in order to take appropriate action on Dr. Rickett's death."

Afternoon Session.

22. "The histologic findings in a case of tuberculous cyclitis and a theory as to the origin of tuberculous scleritis and keratitis. With lantern demonstrations," Dr. F. H. Verhoeff.

Discussed by Drs. Brown and Verhoeff.

23. "Recurrent tubercular choroiditis," Dr. Carl Koller.

Discussed by Drs. Marple and Jack.

24. "Illuminated box eye-testing chart," Dr. Harris G. Sherman.

25. "Vaccine and serum therapy in ophthalmology," Dr. John E. Weeks.

26. "Vaccine and serum therapy in ocular tuberculosis," Dr. George S. Derby.

Discussed by Drs. Verhoeff, Wilder, Risley, Friedenwald, Weeks, and George S. Derby.

27. "Suggestions regarding the nature of visual sensations," Dr. G. T. Stevens.

Discussed by Dr. Howe.

28. "A brief note concerning the tropometer," Dr. G. T. Stevens.

Discussed by Dr. Howe.

29. "The different prism tests, with presentation of a series of prisms arranged on a circular disc," Dr. Lucien Howe. (Read by title.)

Adjourned.

Members present at the Forty-sixth Annual Meeting:

ADAMS, A. E.
ADAMS, JOHN L.
ALLYN, G. W.
BELL, GEO. H.
BROWN, E. V. L.
BRUNER, WM. EVANS
BRUNS, H. DICKSON
BULL, CHAS. STEDMAN
BUTLER, W. K.
BYERS, W. G. M.
CALLAN, PETER A.
CARMALT, W. H.
CHANCE, BURTON
CLAIBORNE, J. H.
CLARK, C. F.
CURDY, R. J.
DAVIDSON, JNO. P.
DAVIS, A. E.
DENNETT, WM. S.
DERBY, G. S.
FISKE, GEORGE F.
FOSTER, M. L.
FOX, WILLIAM H.
FRIDENBERG, PERCY
FRIEDENWALD, HARRY
GREENE, LOUIS S.
GRUENING, E.
HANSELL, HOWARD F.
HARLAN, HERBERT
HARROWER, DAVID, JR.
HASKELL, H. H.
HEPBURN, N. J.
HOLDEN, WARD
HOLLOWAY, T. B.
HOLT, E. E.
HOWE, LUCIEN
HUNTER, D. W.
JACK, EDWIN E.
JACKSON, EDWARD
JOHNSON, WALTER B.
KENNON, B. R.
KIPP, CHARLES J.
KNAPP, ARNOLD
KOLLER, CARL
KOLLOCK, CHARLES W.
LAMBERT, WALTER EYRE
LORING, FRANCIS B.
LORING, ROBERT G.
LOVELL, D. B.
MARMION, W. V.
MARPLE, W. B.
MATHEWSON, ARTHUR
MAXSON, S. C.
MAY, CHARLES H.
MCINTOSH, J. R.
MINOR, J. L.
OLIVER, CHARLES A.
PARKER, WALTER R.
PAYNE, S. M.
POSEY, WM. CAMPBELL
POST, M. H.
PRICE, H. R.
PUSEY, BROWN
PYLE, WALTER L.
RADCLIFFE, MCCLUNEY
RANDALL, B. ALEX.
RANDOLPH, R. L.
RAY, J. M.
REEVE, RICHARD A.
REIK, H. O.
RICHEY, S. O.
RIDER, WHEELOCK
RING, G. ORAM
RING, HENRY W.
RISLEY, J. NORMAN
RISLEY, SAMUEL D.
SCHNEIDEMAN, T. B.
DE SCHWEINITZ, G. E.
SEMPLE, N. M.
SHANNON, JOHN R.

SHERMAN, H. G.
SPALDING, FRED M.
SPALDING, JAMES A.
STEVENS, GEORGE T.
STIEREN, EDWARD
SUTPHEN, T. Y.
SWEET, WM. M.
TAYLOR, LEWIS H.
THEOBALD, SAMUEL
THORINGTON, JAMES
VEASEY, C. A.
VERHOEFF, F. H.
WAITE, FRANK L.
WEEKS, JOHN E.
WESTCOTT, CASSIUS D.
WHITE, J. A.
WILDER, WM. H.
WILMER, W. H.
WILSON, F. M.
WOODS, HIRAM
ZENTMAYER, W.
ZIEGLER, S. LEWIS

THE POST-OPERATIVE HISTORY OF EIGHTEEN CASES OF MAGNETIC FOREIGN BODIES REMOVED FROM THE EYE BY THE HAAB OR GIANT MAGNET.

CHARLES STEDMAN BULL, A.M., M.D.,
New York.

This paper is intended to apply only to the comparatively small number of cases in which the patients could be followed up, and the ultimate results tabulated. The great majority of the cases from which the foreign bodies were removed by the Haab magnet disappeared after discharge from the hospital, and could not be traced. Only such cases were considered in which the foreign body was located either in the vitreous or in the fundus.

The particle of iron or steel was successfully located by the *x*-ray apparatus in every case and a skiagram made.

The foreign body was successfully extracted by the Haab magnet in seventeen cases—all but one. The extraction was unsuccessful in one case.

The extraction occurred through the original wound in seven cases, and through another channel in ten cases.

The foreign body was located in the vitreous in eight cases and in the fundus in ten cases.

An iridectomy was done at the time of extraction in seven cases.

A cataract subsequently developed in eight cases.

Phthisis bulbi resulted in six cases, and sympathetic ophthalmia in eight cases, and enucleation was necessitated in ten cases.

The vision was permanently lost at the time of the accident in five cases.

There was immediate useful vision after the removal of the foreign body in two cases. Permanent useful vision was not gained in a single case.

From a careful examination of these eighteen cases, and of a large number of cases already published by various authors, it would seem that the following points are to be emphasized:

First: The foreign body should be located, and an attempt made for its extraction, as soon as possible after the accident, in order to lessen the dangers of infection.

Second: When the wound of entrance is in the anterior segment of the eye, and the foreign body has been located in the vitreous or fundus, no attempt should be made to draw it forward by the Haab magnet through the wound of entrance. It seems far wiser to make an incision through the sclera at the nearest point to the location of the foreign body, and extract it by means of the small magnet.

Third: These eyes are all suffering from the shock of the original accident, and we have not properly appreciated the severity of the second shock of applying the giant magnet and forcibly drawing the foreign body through delicate tissues already seriously injured.

Fourth: These eyes are all in a dangerous condition, and the prognosis must always be unfavorable, with the great danger of sympathetic ophthalmia developing.

Fifth: If infection has already begun, the eye should be enucleated at once.

Sixth: While the prognosis in these cases is always very grave, it is better when the foreign body is lodged in the vitreous than when it is lodged in the retina, or ciliary body.

Seventh: Great care should be exercised in the application of the giant magnet, for more injury may be done by the fragment of iron or steel being drawn through the

tissues by the magnet than was caused by the original accident.

Eighth: If the attempted extraction fail, it is better to enucleate the eye at once.

Ninth: Even after a successful extraction, useful vision will be permanently lost in the majority of the cases, and enucleation will be necessary in order to save the fellow eye. The danger of sympathetic inflammation is ever present, and a general insidious uveitis may develop months, and even years, afterward, and extend to the fellow eye.

CASE I.—Male, machinist, aged thirty-eight. First seen October 10, 1905. Two days ago the *right eye* was struck by a piece of steel flying from a lathe. Small wound in sclerocorneal margin, on temporal side; perforation of iris; partial opacity of lens. Skiagraph located foreign body in the fundus on nasal side of optic disc, and 5.5 mm. below the horizontal plane. Fragment of steel drawn forward by Haab magnet and entangled in iris near wound of entrance. Small incision in limbus in superotemporal quadrant, and fragment removed by Hirschberg magnet. Small iridectomy, with free pillars to incision. Atropin and bandage. Three days later signs of panophthalmitis; enucleation on fourth day on account of sympathetic irritation in fellow eye. Size of steel fragment, 1×2.5 mm.

CASE II.—Male, aged fifty, machinist. First seen October 31, 1905. *Left eye* injured ten days ago by chip flying from a hammer. Wound in corneal margin on temporal side in horizontal meridian. Hole through periphery of iris. Lens cloudy on temporal side. Ophthalmoscope shows what may be the foreign body in the vitreous on the nasal side, and just below the horizontal meridian. Skiagraph locates the fragment in the vitreous about in same locality marked by ophthalmoscope. Steel fragment drawn forward by Haab magnet into anterior chamber, but entangled in the iris opposite wound of entrance. Small iridectomy outward, and fragment of steel removed with iris tissue. Atropin and cocain and bandage. Size of fragment, 2×3.5 mm. V = finger. Three months later, phthisis bulbi. V = 0.

CASE III.—Male, aged thirty, carpenter. First seen November 6, 1905. *Right eye* injured this morning by a fragment of steel from a chisel. Small wound through center of cornea. Line of opacity through lens. Vitreous very cloudy, probably from intra-ocular hemorrhage. Fundus invisible. V = l. p. Skiagraph locates foreign body 25 mm. back and 12 mm. to temporal side. Haab magnet denotes the presence of steel, but fails to draw it forward after three attempts. Patient refuses to have any operation done on the eye, though told of danger. Probable size of iron fragment, 1 × 2 mm. Atropin three times a day. V = $\frac{5}{200}$. Was seen once a week for three months. At the end of that time lens was entirely opaque, and there was decided siderosis of the iris. V = l. p. Projection good. Since then patient not seen.

CASE IV.—Male, aged twenty-eight, machinist. First seen October 12, 1906. *Left eye* injured by piece of steel sixteen days before. Wound of entrance in ciliary region in superonasal quadrant. Vitreous cloudy, and anterior chamber half full of blood. V = counting fingers. Skiagraph locates foreign body in fundus, 5 mm. on temporal side and 6 mm. below. Apparent size, 1.5 × 3.5 mm. Haab magnet draws the fragment into the wound of entrance, from which it is extracted by forceps. Vitreous became filled with blood, and patient complains of great pain. General uveitis develops, but not of suppurative type. Three weeks later symptoms of sympathetic iridocyclitis, and enucleation at once performed. Sympathetic trouble subsided in four weeks under proper treatment, with V = $\frac{20}{30}$.

CASE V.—Male, aged sixty, machinist. First seen November 19, 1906. *Left eye* injured six weeks ago by fragment of steel watch-spring. Wound in inferotemporal corneal margin. Lens opaque; iritis with posterior synechiæ. V = l. p. Two skiagraphs made and foreign body located in the vitreous, 11.5 mm. back and 9.5 mm. above the horizontal. Haab magnet drew the foreign body, after three trials, into the anterior chamber, but entangled in iris. Iridectomy in inferotemporal quadrant, and fragment removed by Hirschberg. Clean coloboma made. No reaction. Hot applications. Atropin and cocain.

Patient discharged at end of third week. Eye quiet. V = l. p. Returned one month later with iritis sympathetic in *right* eye. Immediate enucleation. Ultimate V. in *right* eye, $\frac{10}{200}$.

CASE VI.—Male, aged twenty-four, carpenter. First seen on December 21, 1906. *Left eye* injured by piece of steel from a chisel the day before. Wound near center of cornea and through center of lens. Vitreous very hazy. Iris not wounded. Skiagraph locates the foreign body in the vitreous, 2.5 mm. to the nasal side and 8 mm. below. Haab magnet at first attempt drew the fragment of steel into the anterior chamber Corneal incision below and extraction by Hirschberg magnet. Very little reaction. No pain. Eye remained quiet for five days, and then panophthalmitis developed. Enucleation two weeks later on account of sympathetic irritation in fellow eye.

CASE VII.—Male, aged twenty, plumber. First seen February 6, 1907. *Right eye* injured three days ago by piece of iron flying from a hammer. Wound in ciliary region in inferotemporal quadrant. Prolapse of ciliary processes. Vitreous full of blood. V = l. p. Skiagraph locates foreign body in vitreous, 4 mm. below horizontal plane, and 9 mm. to nasal side. Haab magnet drew the fragment of iron to the wound, and it was removed with forceps. Patient discharged on fourteenth day. Lens clear; blood in vitreous largely absorbed. V = $\frac{20}{200}$. No iritis, and pupil dilated ad maximum. Seen at intervals of a week for two months, at which time vision was same, but the eye still tender in the ciliary region. Six months later patient appeared with advanced phthisis bulbi, due to the cyclitis. V = l. p.

CASE VIII.—Male, aged thirty, carpenter. First seen on March 18, 1907. *Right eye* perforated three days before by piece of steel from a wedge. Wound in ciliary region on temporal side, just above horizontal meridian. Vitreous full of blood. Skiagraph located foreign body in the vitreous, 8.5 mm. on nasal side, and 6 mm. below horizontal plane. Haab magnet drew the fragment into the iris, but not through it. An excision was made with keratome outward and upward in limbus, and an iridectomy was done and the piece of steel extracted with the iris.

Size, 1 × 3 mm. Iridocyclitis set in on eighth day, and the eye was enucleated on the twelfth day, because of sympathetic irritation. V. was reduced to l. p.

CASE IX.—Male, aged twenty-eight, machinist. First seen September 23, 1907. *Left eye* injured by piece of steel from lathe. Wound in temporal side of sclera, just posterior to sclerocorneal margin and above horizontal meridian. V = l. p. Vitreous full of blood. Skiagraph locates foreign body in the fundus, 18 mm. back, and 7.25 above, the horizontal. Haab magnet fails to dislodge fragment. Wound of entrance enlarged, and then Hirschberg magnet draws the fragment to the wound and extracts it. General uveitis with severe pain and gradual atrophy of eyeball. Enucleation eleven weeks after the extraction on account of severe pain. No suppuration or symptoms of sympathetic trouble. Size of steel fragment, 2.5 × 4 mm.

CASE X.—Male, aged forty-seven, carpenter. First seen September 27, 1907. *Left eye* injured by piece of steel from a hammer three days ago. Wound in sclerocorneal margin on temporal side. V = counting fingers. Vitreous very cloudy. Skiagraph locates the foreign body in the vitreous, 9 mm. back, 2.5 mm. on nasal side, and 2 mm. above. The Haab magnet draws the piece of steel into the bottom of the anterior chamber, from which it was extracted through a corneal incision. Size of particle, 5 × 2 mm. Patient discharged on twelfth day. Eye quiet. V = $\frac{10}{200}$.

This patient was seen four months later and vision remained the same. Has not been seen since and cannot be found.

CASE XI.—Male, aged forty-two, blacksmith. First seen November 18, 1907. *Right eye* injured by piece of iron from a horse-shoe nail nine weeks before. Eye very painful. Iridochoroiditis. Scar in cornea in inferior third and iris adherent in scar. V = l. p. T—1. Skiagraph locates foreign body in the fundus, 31 mm. back, 6 mm. above, and 5 mm. to temporal side. Haab magnet on third attempt drew the fragment of iron into anterior chamber, but entangled in iris. Corneal incision below, and fragment extracted by introduction of pole of small magnet. Size of iron fragment 1.75 × 10 mm. Enuclea-

tion five days later on account of sympathetic irritation in left eye.

CASE XII.—Male, aged twenty, plumber. First seen November 20, 1907. *Right eye* injured by piece of steel from hammer two days before. Wound just above the center of the cornea, but no incarceration of iris. Skiagraph locates foreign body in the fundus, 21 mm. back, 5 mm. on nasal side, and 3 mm. below the horizontal. Foreign body drawn into anterior chamber and extracted through corneal incision. Severe iritis followed, but adhesions prevented by atropin (3 % solution). Patient discharged at end of third week. Iritis cured; lens slightly cloudy. V = $\frac{20}{200}$. Three months later the lens was entirely opaque, but light perception and projection good.

CASE XIII.—Male, aged thirty-two, blacksmith. First seen December 11, 1907. *Right eye* injured by piece of steel from hammer ten days ago. Wound of entrance in ciliary region in inferotemporal quadrant. Vitreous full of blood or exudation. Lens cloudy. V = l. p. Skiagraph locates foreign body in the fundus, 15.75 mm. back, 2 mm. above, and 15 mm. to nasal side. Haab magnet fails to dislodge fragment after three trials. Incision made through sclera at point indicated by skiagraph; and after some difficulty the piece of iron was removed by Hirschberg magnet. Size of fragment, 5 × 1.5 mm. General uveitis followed, ending in phthisis bulbi. No sympathetic symptoms.

CASE XIV.—Male, aged forty, stevedore. First seen February 24, 1908. *Left eye* injured in removing an iron band from a box one week ago. Wound through center of cornea. Lens opaque. Sphincter margin of iris lacerated. No reflex from fundus. V = l. p. Skiagraph locates foreign body in the fundus, 20.5 mm. back, 3 mm. on temporal side, and 1.5 mm. above. Haab magnet at first trial draws particle of iron through the iris into the anterior chamber, causing very severe pain. Foreign body removed through corneal incision below, and measured 3 × 8 mm. Severe uveitis followed, with loss of light perception, and enucleation was done ten days later, on account of sympathetic irritation.

CASE XV.—Male, aged thirty-six, machinist. First

seen October 2, 1908. *Left eye* injured by piece of steel from a hammer two days ago. Wound in limbus, in infero-temporal quadrant; iris lacerated at periphery. Blood in anterior chamber and vitreous. Lens appears uninjured. Skiagraph locates foreign body in vitreous, 7.5 mm. back, 3.5 mm. to the nasal side, and 1 mm. below horizontal plane. Haab magnet on second trial withdraws the fragment of steel with considerable violence through the wound of entrance, from which it is removed by small magnet. Severe pain. Cold applications, atropin and cocain. One week later eye quiet, vitreous still cloudy. V = fingers at one foot. This patient was not seen again until February 18th. The *left* eye was then atrophied, with hazy cornea, closed pupil, subnormal tension, and no perception of light. Vision in *right* eye was normal.

CASE XVI.—Male, aged fifteen, school-boy. First seen October 19, 1908. *Left eye* injured by piece of iron from a nail six weeks ago. Iridocyclitis and traumatic cataract. Wound of entrance just above the center of the cornea. Skiagraph located foreign body in the vitreous, 8 mm. back and 1 mm. to nasal side. Haab magnet drew it into anterior chamber, from which it was extracted through incision in the limbus. The inflammation of the uveal tract continued, with grave symptoms, and on the fourteenth day the right eye showed ciliary injection and a sluggish iris. Atropin instilled at once and the left eye immediately enucleated. The irritation disappeared in a week under treatment.

CASE XVII.—Male, aged sixteen, school-boy. First seen February 22, 1909. *Right eye* injured by piece of steel from a hammer two days ago. Wound in sclero-corneal margin in superotemporal quadrant, and iris lacerated. Some blood in vitreous. Skiagraph locates the foreign body in the fundus to the right of the optic nerve: 20.5 mm. back, 2.5 mm. to the temporal side, and 6.5 mm. above horizontal plane. Steel fragment drawn forward by Haab magnet till it protruded through the iris at the wound of entrance, and removed. Small iridectomy done to remove the lacerated iris. Some blood in vitreous. On sixth day blood all absorbed; wound healed; V = $\frac{20}{40}$ and with + 1 D. ⌓ + 0.50 D. axis 90° V = $\frac{20}{20}$ +.

Patient insisted on leaving the hospital against advice, and did not appear again until March 30th. There was then a severe iridochoroiditis in the injured eye, and a well-marked sympathetic uveitis in the fellow eye. The family refused to permit enucleation of the right eye, and the inflammatory process went on rapidly and ended in very marked phthisis bulbi, with no light perception in either eye. Size of foreign body, 1.5 × 1.5 mm.

CASE XVIII.—Male, aged fifty-four, machinist. First seen April 6, 1909. *Left eye* wounded by piece of steel on March 1st. Wound in sclerocorneal margin in the infero-temporal quadrant. V = l. p. Skiagraph located the foreign body in the vitreous, which was full of blood. Steel fragment removed by Haab magnet through sclero-corneal wound of entrance. Iridectomy then done, and lacerated portion of iris removed. Remained in the hospital three weeks, and was then discharged, with V = $\frac{10}{200}$. Lens partially cloudy. Was last seen on October 4, 1909, when the lens had become entirely opaque, and V. was reduced to l. p. Projection was faulty, and eye somewhat below normal tension.

DISCUSSION

DR. CHARLES J. KIPP: I should like to ask Dr. Bull whether this is the total number of cases which he was able to trace?

DR. PETER A. CALLAN, New York: Since July, 1905, I have seen 30 cases with a foreign body in one eye. Twenty-eight were *x*-rayed by Dr. Dixon at the New York Eye and Ear Infirmary. In the two not *x*-rayed the body could be seen in the fundus with the ophthalmoscope.

Eight out of the 30 cases had the foreign body in the eye for periods ranging from six months to eighteen years. Five of these 8 cases had iridocyclitis, which in one instance caused sympathetic irritation, and the eye was enucleated. One phthisis bulbi after a small piece of a dynamite cartridge had been in the eye six months. One ulcer of the cornea of the injured eye seventeen years after the foreign body had entered the eye. One siderosis two years after the foreign body had gotten into the eye. Seven out of the 8 were blind, and no attempt was made to remove the foreign body, and only 1 case consented to enucleation.

In the 22 remaining cases the foreign body had been in the eye for periods varying from one day to four months. All except one had the foreign body removed, and in that one the steel had made its exit close to the optic nerve, having passed through the eye. Six out of the 22 cases were lost—3 by panophthalmitis, 2 from iridocyclitis, and 1 with phthisis bulbi which caused sympathetic irritation and was enucleated—27.3% total loss of the injured eye. Sixteen cases were discharged with the eye free from pain or irritation—the eye quiet. Twelve of the 16 cases had traumatic cataract.

In only 1 case was the wound of entrance entirely in the sclera. Most involved the sclerocorneal junction (the limbus), and, next in order, the cornea. One was in the lens, 1 in the ciliary processes, and 2 in exudate on the posterior surface of the ciliary body, 2 in the vitreous, and the remainder on the retina.

Three were extracted at the time of the removal of the opaque lens with the Johnson magnet. One through the enlarged point of entrance in the sclera with Haab magnet. Two through the partially opaque lens into the anterior chamber with the Haab magnet. Two through the original opening at the limbus with the Haab magnet. Eight were brought into the anterior chamber with the Haab magnet, and removed from there through a corneal incision with the Johnson magnet. One became entangled in the iris and could not be dislodged with the magnet, so I made an incision at the limbus nearest the foreign body, and removed that part of the ris and steel with forceps out of the eye; detached the steel with a Johnson magnet; then replaced the iris. This I had done previously in several cases and it has always acted satisfactorily.

The mode of using the Haab magnet was as follows: The patient was brought close to the magnet, within an inch of the center of the cornea. Then the current turned on; if no sign, no pain, the point was brought into contact and then gradually moved to the side of the eye, in as direct a line as possible with the foreign body, between ciliary processes and periphery of lens. Then there was a rapid make and break of the current until the foreign body was seen to bulge behind the iris. The point of the magnet

was then moved to the opposite side, against the outer or inner side of the cornea, as the case may be; then a make and break of the current, and sometimes reversing the pole of the magnet.

When the foreign body was brought into the anterior chamber, the patient was placed in a horizontal position, and the foreign body brought up to a point under the intended opening through the cornea, 3 mm. from limbus. An incision into the anterior chamber was then made, and when the Johnson magnet was applied over the opening, it came out readily.

The placing of the foreign body under the point of incision greatly facilitates its extraction, especially with the escape of the aqueous caused by the struggles of the patient.

RESULTS

1 case the vision with correction = 20/20
2 cases the vision with correction = 20/30
1 case the vision with correction = 20/50
1 case the vision = 20/70
1 case the vision = 20/100

1 patient recently wrote me, whose eye was injured four and one-half years ago, that he had very good vision in that eye.

2 cases for occluded pupil.

1 case Dr. Ard reports recently that had a thickened capsule which only needed an incision to get a useful eye.

6 cases I could not see or get information as to the condition of the injured eye at present.

When the foreign body has been in the eye long enough to be surrounded with fibrinous exudate or encysted, it requires patience and perseverance to dislodge the particle of steel from its lodgment. In one case in which the foreign body had been in the ciliary processes for four months it took nine successive daily trials before I succeeded. In two other cases it required two days to reach the same result.

As to the question of the route of extraction of the foreign body from the eye,—by the sclera or through the anterior chamber,—that is a point to be decided by the operator. By the former method it is less likely to damage the lens, but, from my experience, is more likely to be followed by retinal detachment.

No one more fully appreciates the gravity of the trauma caused by the entrance of a foreign body into the eye

than I do, especially in the deeper tissues, ciliary body, retina, or vitreous chamber. A particle weighing ½ grain is large, and the resulting traumatism is in inverse ratio to its size. At the same time if the foreign body is removed and the globe does not become infected at the time of injury or operation for its removal, the resulting traumatic inflammation subsides within a month or six weeks. The chances of retaining the globe are good, provided there is no incarceration of iris or ciliary processes.

DR. E. E. HOLT, Portland, Maine: Dr. Bull's experience in not getting a single case of useful vision after removing steel or iron from the vitreous does not correspond with mine. My first series of cases which I reported to this society in 1891, and my second series, which I reported in 1893, I was able to follow for years, and know that useful vision was maintained in a majority of the cases as then reported. In another series of cases reported elsewhere the results were equally as good. I only rise to say that, in my experience, if we get the case on the day of the accident and there is not too much traumatism caused either by the steel or iron entering the vitreous or in removing it, useful vision of the eye should be obtained permanently. I remember some of my first cases very distinctly, that normal, or nearly normal, vision was maintained for years afterward. They were to let me know if their vision failed them, and, as I have no record to the contrary, I have reasons to think they still enjoy useful vision. When the iron or steel could not be removed through the entrance wound readily, I usually have made an incision in the inferior temporal quadrant of the eye. Of course, in a certain proportion of the cases, the eye will have to be removed, but this fact should not deter us from making every effort to save the eye by first removing the steel or iron from the vitreous. If the eye manifests symptoms of infection from the accident, it had better be removed. My experience, however, is that useful vision can be saved in a large majority of these cases if the steel or iron is removed from the vitreous on or near the day of the accident.

DR. W. E. LAMBERT: I have had a number of cases of foreign bodies. I looked up as many of the records as I

could place and found ten. In all these cases except one the foreign body was removed through the anterior portion of the eye. In six of the cases fairly useful vision resulted, and, at last reports, had been retained. In none of my cases have I had sympathetic trouble. There were four out of the ten in which enucleation was done—three almost immediately and one three or four weeks afterward. In one of the cases in which enucleation was necessary the foreign body was removed through the posterior part of the globe. The localization was accurate, the incision satisfactorily made, and the foreign body removed with little traumatism. The eye, however, quickly went to pieces and had to be removed.

I am surprised at Dr. Bull's experience, because of the fortunate results obtained in the majority of those in my own. I cannot agree with him with regard to making the incision and removing the body through the posterior part of the globe.

I had rather an unusual experience with one of my recent cases, that of a man from South America who had been sent to New York with the history of an accident and injury. The only evidence of injury was a traumatic cataract. An *x*-ray examination by Dr. Dixon localized the foreign body in the posterior part of the eye, but he was unable to determine whether or not it had penetrated the globe. The first effort with the magnet failed, but after two days the foreign body was brought forward by the Haab magnet, so that it bulged the iris. It was then brought through the pupil into the anterior chamber by the small magnet, a linear incision made, and the foreign body removed. The process was so simple that it seemed wise at the time to remove the cataract, which was done by slightly enlarging the incision and washing out the lens. It looked as though the results would be very satisfactory, but in forty-eight hours a haziness of the cornea with turbidity of the aqueous was noticed—in short, a purulent iritis had developed. Hypopyon followed in a day or two, and, every effort to save the eye having failed, it was enucleated.

DR. JOHN E. WEEKS, New York: During the last five years I have removed foreign bodies from 17 eyes in which

the foreign body was located by means of the *x*-ray. In these 17 cases the removal was by the anterior route in 13. In the other cases extraction was through the sclera. Of these 17 eyes I have had to enucleate 2, and in 2 others I advised enucleation, but it was not consented to. In none of these cases have I seen sympathetic inflammations, and in only 1 or 2 have I seen sympathetic irritation. In at least 3 of the cases the vision has been good — = $\frac{20}{30}$ I believe in 1, and useful vision in the other 2. These are cases that I have been able to follow for a number of years. In the other cases I have not heard from the patients very recently, but the condition of the eyes was such that I have every reason to believe that they remained in good condition.

It seems to me that the anterior route is the preferable one in all cases in which the foreign body is small and in which it can be drawn into the posterior chamber with relative facility. The traumatism to the eye, I believe, is less than it is when we cut through sclera, choroid, and retina, and bring the foreign body out in that way. This is the route advocated by Haab, and his experience, as we know, has been very extensive. We know that by the process of siderosis eyes are lost almost without exception if the foreign body is retained, and if it has been in even a long number of years, in many of the cases the removal is relatively easy. I have in mind one case in which the foreign body was in the eye some fifteen years, and in which removal by the anterior route was perfectly easy. Siderosis had advanced markedly. The field of vision had become narrowed in the typical manner.

I am really quite surprised to hear the results of Dr. Bull's cases. They certainly do not coincide with those I have had.

DR. R. L. RANDOLPH, Baltimore: I think one of the most important points brought out by Dr. Bull is the question of enucleation, and I agree with him entirely in the positive and uncompromising way in which he advises the enucleation of such eyes as he has described. It seems to me that there has been, perhaps, a change of front within the last year or two on the part of many ophthalmologists toward enucleation. It is not an unusual thing to hear it said that so and so does not enucleate as much as formerly, and cer-

tainly I have seen statements to the same effect in literature. What is responsible for it I am unable to say, unless it be the introduction of large doses of salicylate of soda in the treatment of sympathetic ophthalmia. I am sure I have seen within the last few years reports of more cases of sympathetic ophthalmia than ever before in the same length of time, and there can be only one reason for this, and that is that the injured eye was not removed soon enough. And when it comes to the use of the salicylates in this disease, I find no brilliant record of what this drug has done when the patient is sent away with several synechiæ, and such has been the record of several of the cases of sympathetic ophthalmia recently reported as cured. Personally I do not believe in the permanency of such results. Such cases, I think, are almost certain to be heard from later.

I have seen, in the course of my work, nine cases of sympathetic ophthalmia. One of these was in my own practice, and he recovered with good vision, but with several synechiæ. He left the city a short time afterward, and I have never heard from or of him since, but I should not be surprised if he were blind. The other eight cases I saw in consultation—all children, and all went blind, and in two at least of these salicylate of soda was employed. I agree with Dr. Bull when he says that such eyes should be removed promptly, for sympathetic ophthalmia practically means a previous history of compromise. Unfortunately, we possess no infallible guide to tell us that such and such an eye is going to give rise to trouble in the other eye, but there is one sign which I have been in the habit of relying upon, and that is the intra-ocular tension, which, if persistently low at the end of the first week after the injury, I enucleate. Very seldom, I believe, do we see or hear of an eye the seat of a penetrating wound and with low tension which has persisted for a week return to usefulness, a fact which, by the way, has been noted by Schirmer in his recent contribution to the Leber Festschrift.

Fortunately, we are not often confronted with cases in which we are perplexed as to what to do, but when I am in doubt, I always enucleate, for it seems to me at least preferable to run the risk of removing a harmless eye, than of allowing to remain an eye that is going to give rise to a dis-

ease with which not even massive doses of salicylate of soda will tempt me to take any liberties.

DR. EDWARD JACKSON, Denver: I am heartily in accord with Dr. Bull's first conclusion. I have always felt that the giant magnet, with the Haab method of using it, furnished an easy, rather than a superior, method of extracting foreign bodies from the eye; that it left to magnetic force a good deal that might be done with care by the surgeon, with more advantage to the patient, and my limited experience with the Haab method bears this out. I have resorted to the giant magnet only when other magnets failed, and in the few cases in which I employed the giant magnet it failed also. It seemed plausible that if the foreign body entered through the lens, it would do no damage to draw it back through the lens, but I have a case in mind which I saw with our associate, Dr. E. W. Stevens, of Denver, in which the steel passed in through the lens. The small fragment of steel was suspended in the vitreous, in about the middle portion. Instead of attempting to draw that back through the injured lens, an incision was made through the sclera, and it was taken out, at the first trial, with the Johnson magnet. There was severe reaction, and the man was under mercury and salicylates for several weeks; but the eye was kept fully under atropin, and he now has a perfectly clear lens with full vision.

In those cases of small foreign body where the small magnet is at a disadvantage, I believe it is possible to extend the magnet so as to bring out these foreign bodies. Of course, the small magnet is at a disadvantage unless you can bring it into close proximity to the foreign body. A year ago I outlined a method of extending the magnet by placing its broad tip in contact with scissors, and, having magnetic traction as a guide, to bring the foreign body between the blades. The two cases which I reported then have continued to do well; that is, in one case the eye has $\frac{4}{5}$ vision; and in the other, vision is lowered to about $\frac{4}{12}$ by traumatic partial cataract. I have seen both cases recently. In one case the giant magnet had been skilfully used, and it was a large and powerful instrument. It was employed upon five successive days, and it hurt the patient each time more than extraction with scissors and the Johnson magnet.

I want to emphasize the first conclusion of Dr. Bull, that it is better, after locating the foreign body, to go in at the nearest point through the sclera and extract with the small magnet than to attempt persistently to extract with the giant magnet.

DR. W. B. MARPLE, New York: Some years ago Dr. Risley reported a few cases in which removal of the foreign body was made through the sclera. Up to that time I had always removed through the wound of entrance. Since that time I have removed a number through the sclera, and it seems to me that the conclusions that I reach are just the opposite to those cited by one gentleman to-day. That is, if the foreign body is small, and especially if the lens is not injured, I would select the scleral route, if the foreign body is in the vitreous, as the one by which to remove it. If, however, the foreign body were large and irregular in shape, and especially if the lens had been injured, it would seem to me much the better way, and this has been my practice, to remove the foreign body through the wound of entrance, rather than to make another large opening in the sclera to permit this foreign body to come out.

As to the possibility or likelihood of detachment of the retina, it seems to me that formerly this occurred when the foreign body was removed through the scleral incision and when we used small and less powerful magnets, and especially when the tip of the magnet was introduced into the vitreous. I inquired of Dr. Risley whether any of these cases which he reported showed detachment, and he said they did not. In the few cases I have had I have never seen detachment of the retina. The magnets that we now have are so powerful that it is not necessary to push the tip into the vitreous at all.

In regard to enucleation, it is somewhat interesting that I have had a case during this last winter in which the foreign body, a large irregular mass, was removed. The tonometer subsequently showed a diminution of tension to a very marked degree. These are the cases of cyclitis that subsequently produce sympathetic irritation. The eye was afterward enucleated.

DR. WILLIAM M. SWEET, Philadelphia: In a recent paper before this society I reported the results of operation in

a series of foreign body injuries, and stated that each foreign body injury must be studied as a separate and distinct condition, the ultimate result of operation being influenced not alone by the method of extraction, but depending upon the character of the injury, the extent to which the ocular structures have been injured, the length of time the foreign substance has been in the eye, and the ease with which it is removed. I have always believed that less traumatism is done if the foreign body is removed through a scleral incision in the vicinity of its indicated location than if the metal is drawn through the length of the vitreous into the anterior chamber. I have several cases in which a clear lens permits a study of the region of the scleral incision through which the body was removed, and in no instance is there retinal detachment. I think that the instances of retinal detachment that follow extraction are usually the result of the inflammatory changes that take place at the point where the embedded foreign body has injured the retina and choroid.

I have recently examined the records of 39 cases of successful extraction, all studied over three years after the injury, and find in 3 the vision equaled $\frac{6}{6}$; in 2, $\frac{6}{9}$; in 1, $\frac{6}{30}$; in 1, $\frac{6}{60}$; 5 with cataract, but having good light projection; 5 imperfect light projection; 7 partial retinal detachment; 6 shrunken eyeballs; and 9 in which the eyeballs were subsequently removed. In a number of these cases several days or weeks elapsed between the date of injury and the extraction, and the magnetic pull upon the foreign body surrounded by exudation was undoubtedly responsible for the subsequent inflammation that resulted in poor vision or loss of the eye.

DR. G. E. DE SCHWEINITZ, Philadelphia: Dr. de Schweinitz desired to reiterate his belief that, under most circumstances, the best method of removing metallic foreign bodies from the interior of the eye was by the direct route, that is to say, after localization by means of the *x*-rays, through a small incision made directly over the situation of the foreign body without the introduction of the instrument into the vitreous, although he was aware that each case presented a separate problem, and that no one positive rule could be formulated. Whether or not an eyeball should

be enucleated if infection was present depended, it seemed to him, upon the situation of the infection and its extent. If it was deep seated and the vitreous was involved, removal of the eyeball, or at least its evisceration, was probably imperative, but surely it must be the experience of all surgeons that, after foreign body injuries, even in the presence of infection in the anterior portion of the eyeball, the globe could often be saved by appropriate treatment, and even if such a globe is sightless, or practically sightless, it is in most instances better than an artificial eye. Dr. de Schweinitz had already put upon record his experience in this respect, and in a series of cases a fair percentage of saved eyeballs had been recorded, which had remained useful to the patient, and he had never observed a case of sympathetic ophthalmia under these circumstances. In some of these eyes, in addition to the infection of the wound entrance, there had been hypopyon with much exudate in the posterior chamber, as well as a cataractous lens, and the procedure had been the ordinary one, namely, washing out the anterior chamber, as well as the posterior chamber, breaking up the cataractous lens, and removing it with the exudate behind the iris. Dr. de Schweinitz was interested to know what Dr. Bull's experience was in this respect, because he did not suppose he was insistent that an enucleation of the eyeball should take place in the presence of such anterior infections. Dr. de Schweinitz doubted very much whether sympathetic ophthalmia was more prevalent at the present time than in former days, and he felt sure that not only was it not more prevalent, but that many eyes were now saved, and usefully saved, which formerly had been sacrificed.

DR. CHARLES J. KIPP, Newark: Ever since the introduction of the large magnet I have used the large one alone. In all cases in which the patient comes to me on the first day, or before the wound is closed, I do not resort to the examination by the *x*-ray, but immediately proceed to extract the foreign body through the wound of entrance, and have succeeded in all cases so far. The danger from the Haab magnet is magnified. The results depend largely upon how you manage the procedure. I gradually approach the eye with the magnet, and often the foreign body appears

before the point of the magnet touches the eye. In cases in which the wound is closed, I try to draw the foreign body into the anterior chamber, and then draw it through an incision in the cornea out of the eye by the large magnet. Failing to get the iron into the anterior chamber, I make an incision in the sclerotic, near the seat of the foreign body.

My fear of detachment of the retina dates back to the time before we had the Haab magnet, when we were obliged to introduce the magnet into the vitreous. I have seen a good many cases in which vision remained fairly good for some time, but was lost after a number of years.

There is no means of comparison as to results. Results depend so largely on the size of the fragment, the force with which it enters the eye, and the part of the eye entered, that it is almost impossible to compare results. I do not think that I have ever seen any harm done by the use of the giant magnet.

In the last year I have endeavored to learn whether the foreign body carried infectious material with it in the eye, by dropping the iron, after its removal from the eye, directly from the magnet into a culture-medium, and I may say that, in the few cases in which I have been able to have this done, no growth of bacteria was shown, and the cases all recovered without signs of infection.

DR. CHARLES STEDMAN BULL, New York: In speaking of infection, I meant infection of the interior of the eye, of the vitreous or choroid, or both. If the infection is confined to the superficial structures, that patient should have the chance to save his eye.

I agree absolutely with Dr. Sweet that each patient should be studied and acted upon for himself as an individual entity. It is not possible to make even a classification until we possess a very much larger number of cases than are now on record.

I would like the members of the society to remember that I stated in the beginning that these remarks were confined to those cases in which the foreign body was either in the vitreous or in the fundus, and had nothing to do with those in the anterior segment of the eye.

I am glad that Dr. Kipp spoke of the method of using the giant magnet. I had supposed that everybody used it

in that way, beginning a relatively long distance and gradually moving the magnet toward the patient, thus reducing the injurious effect of the magnet to a minimum.

I have seen a number of these cases of mine who had temporary useful vision, but they all gradually lost that temporary useful vision. I have seen in my office 6 cases in which the record had been useful vision at the time the foreign body was removed and the patient discharged from observation. These were not under my care, but under the care of other men, and in all of these cases vision, which had been more or less use ul, lasted for a period of nine months to two years, and then in all 6 cases it was lost. The patients were seen in my office after the vision had been lost.

THE POSSIBLE INFLUENCE OF RACIAL AND OTHER CHARACTERISTICS IN ACCOUNTING FOR THE SUCCESS OF THE SMITH-INDIAN OPERATION.

C. F. CLARK, M.D.,
Columbus, Ohio.

A practical question which many ophthalmic surgeons are endeavoring to answer might be expressed as follows: Are the conditions prevailing in India such that we are justified in employing, under the conditions of our own practice, a method of operating which has proved satisfactory in the hands of Major Smith and those who have worked with him?

It has often been suggested, by those who have discussed the Smith operation for the extraction of cataract in its capsule, that some racial or other peculiarities of the Indian patients may possibly account for the results obtained. That the results reported by Major Smith are excellent, challenging the admiration and exciting the interest of all who have enjoyed the privilege of visiting his clinic, is beyond question, and, whether we choose to

adopt his method or not, and whatever may be our final opinion of its limitations, we must all be interested in the study of an operation which yields good results by a procedure differing in so many respects from the method in general use.

Some careful observers, noting the great discrepancy between the results obtained by this operation in India and those reported in this country, have been disposed to give weight to the suggestion that racial peculiarities may make the Indian a better subject than the American for such an operation, and it is my object in this paper to briefly examine such evidence as may be found to have a bearing on this point.

After my return to America Major Smith kindly sent me the original records containing the detailed operative and after-treatment notes of all the cases on which I had operated, with the results, so far as they could be known at the time of leaving the hospital; and in studying these records I was surprised to discover that a very large proportion of his patients whom I had supposed came from a great distance were from his own or the immediately adjoining districts. Indeed, of the 78 patients on whom 121 extractions were performed, 33 (42%) were from his own district of Jullundur, 16 (20%) from Kapurthali, not more than 25 miles distant, and the remaining 29 (38%) were from 12 districts most of which were not far away. The patients, therefore, whom we treated, were, for the most part, drawn from among the people whose mode of life we were able to observe during our stay in the district, and were typical of the population of that part of India. The agricultural plain of northwestern India, in which Jullundur is situated, is peopled by men, for the most part, of Aryan race, and, while our patients were Mohammedans, Hindus, and Siekhs, with an occasional Kashmiri, Gurka, or Afghan, they were fairly uniform in their response to operative

measures and treatment. While some belonged to the merchant and artisan castes, they were largely what would be classed as agricultural peasants. With few exceptions they were thin, fairly muscular, and free from adipose tissue, giving one the impression of being somewhat underfed. Only very rarely was one found with full eyes, indicating the presence of any considerable quantity of orbital fat. This is a very significant point, and will be referred to later on.

The agricultural people of this northwestern country are, as an average, far superior in physique to the southern Indians. Especially is this true of the war-like Siekhs, who are often magnificent specimens of manhood, with broad, deep chests, strong limbs, and the bearing of kings. As a rule, they behaved fairly well when undergoing operation, but this was largely due to the skill with which they were managed by Major Smith. With the exception of a few stoical Siekhs, they would, I think, owing to their ignorance and a certain child-like inability to control the movements of their eyes in response to a request, have been difficult subjects to deal with in accordance with our methods. As long as they were let alone they did well, but they were sensitive and easily disconcerted, and, if requested to move the eye toward a given point, were rather more apt to move it in the opposite direction. Whether a racial characteristic or a manifestation of the nervousness of an ignorant peasant, this tendency is far worse with the Indian than with the American, and is so general and so difficult to deal with that it led to the development of what I regard as the most important contribution which Major Smith has made to our means of dealing with cataract patients, whether we employ his method of extraction or that with which we have all been familiar, namely, the means of so controlling the lids, orbicularis and recti muscles, that the patient no longer has the power to do mischief,

and the operator may proceed with the extraction, even though the eye turns upward into the position usually occupied during sleep.

As has been pointed out and emphasized by Dr. Vail, the presence or absence of a considerable amount of orbital fat, and the corresponding prominence of the eyeball or its recession within the orbit, is a very important factor in the successful performance of this operation.

Only those who have attempted to operate by this method in a considerable number of cases can fully appreciate the fact that when one removes the capsule with the lens and thus takes away the barrier which separates the vitreous from the aqueous chamber, he must adopt special precautions, both during the operation and in his later management, to avoid the escape of vitreous and adhesion of the iris in the wound. During the operation this is admirably guarded against by the ingenious and original method by which the trained assistant controls the lids and ocular muscles, and the skilful method by which the lens is kept constantly pressed upward so as to fill the whole wound, while pressure is being exerted to deliver it. After the operation and dressing loss of vitreous and prolapse are avoided by letting the eye absolutely alone for from six to ten days, a procedure far more easily practised with the Indian than with our nervous and exacting American patients, and this avoidance of disturbance of the wound is made possible by the remarkable freedom from iritis after the complete removal of the lens and capsule—at least this is true in the Jullunder clinic.

The success of this method of operating is in so large a measure dependent upon these two points, namely, the control of the lids and ocular muscles during the operation and the avoidance of disturbance of the eye during the healing process, that two very pertinent questions may naturally be asked at this point:

First: How far do racial and other characteristics peculiar to the Jullundur patients tend to facilitate this control?

Second: Is the Indian, or, more properly, the Jullundur patient, to any considerable degree immune so far as iritis is concerned?

Time and careful observation may be required to give a final answer to these questions, but the impressions of one who has enjoyed a brief experience in operating and studying cases in the Jullundur clinic may throw some light on the subject. These patients undoubtedly have an abiding faith in the skill and judgment of Major Smith. This faith is based on a knowledge of the results following his thousands of operations during a period of some seventeen years in a country in which, without the aid of newspapers, information of all matters that may concern any individual travels with miraculous rapidity among a people who have some mysterious power of learning every detail of your life without appearing to make an effort. This faith and confidence it is that makes them willing to sit on their haunches for hours on the floor of the operating room awaiting their turn while, not Major Smith, but any surgeon he may choose from among his guests, operates if it seems best, first on the right and then on the left eye. So long as the Major directs the operation they are satisfied. This unfaltering trust and a certain Oriental submissiveness on the table are valuable assets to a surgeon, and are undoubtedly favorable to a good result in the vast majority of cases, but, in the event of any emergency arising which demands intelligent coöperation on the part of the patient, he is apt to fall into a state of nervous panic, and become anything but satisfactory to deal with.

A large proportion of the patients have had more or less trachoma, which has run its course, or perhaps is in the third stage, but this seldom seems to interfere unless there

is pannus, leukoma, or marked shortening of the retrotarsal fold.

The fact that, as a general rule, they are spare and comparatively free from orbital fat is, I believe, a real advantage when we compare them with many of our cases with prominent eyes and firmly pressing lids. I do not think fullness of the orbit would deter Major Smith, but personally I should decidedly prefer the old operation in any case in which the eyes are pressed forward and made prominent by the orbital fat.

I regret that I am unable to state the frequency with which iritis occurs among patients from this portion of India *when operated by the old method*, in order to compare it with that occurring in those operated by the new method, but we should be able to obtain information bearing on this point from the hospitals in Amritsar and in Lahore. Certainly it may be said to almost *never* occur among the Jullundur patients when the lens is delivered in its capsule.

Whether or not the fragments of capsule and cortex remaining in the eye account for iritis in our cases, certain it is that some degree of this troublesome complication is of frequent occurrence after the old operation, and that it is a serious disadvantage, if for no other reason, because it requires the early dressing of the eye.

Our published statistics of the new operation in this country since the method has been really understood are too meager to allow us to draw conclusions, and it will be interesting to learn whether the same degree of immunity from iritis will be observed among Americans as is enjoyed by the Indians when operated by the new method.

It is my impression that environment, mode of life, and habits as to diet are of far greater importance than *race* in producing the almost uniformly spare face and sunken eye of the Jullundur patient, and it is very probable that a few

years of life spent under these conditions by other people of Aryan stock would develop the same characteristics.

A most important question has been raised, and one the solution of which will be awaited with the greatest interest, by the results of the investigations of Dr. W. E. Burge, of Johns Hopkins University, detailed in the Archives of Ophthalmology for September, 1909, into the chemistry of the American lens as compared with that of the Indian, finding 3.63 % of silicon in the ash of the Indian, and none in the American lens, but while this may have a bearing on the development of cataract, I have up to this time been able to discover no evidence that the difference in chemical composition exerts any influence upon the ease of delivery by the new method. There are many questions of the greatest interest which have been raised by this operation, and it is to be hoped that the histologists and pathologists will be able to give us some assistance in their solution. One of the most interesting of these concerns the variations which are noted at different ages and under varying pathologic conditions, in the ease with which the crystalline lens-capsule may be detached from the wall of the fossa in which it lies, and the suspensory ligament may be broken by a degree of pressure which is not sufficient to cause escape of vitreous.

It would seem natural to suppose that the prematurely old would make better subjects than others for such an operation, and, while I have seen nothing written on the subject nor have we had sufficient experience in cases of this kind to warrant a positive assertion, I venture a prediction that the age of thirty, which Major Smith gives as the minimum at which the lens will yield well to his method of delivery, will be found too young for our American patients.

During the after-treatment the Indian, while less intelligent, is, in my experience, more patient and more free

from nervous irritability than many of the patients we have to deal with in this country. Certainly our patients are far more exacting. This is a very important point for consideration in selecting the cases best adapted to the new method, as it is a well-established fact that after extraction in the capsule it is of great importance, if possible, to avoid opening the eye for from six to ten days after operation.

The Indian, as a rule, comes to operation for the extraction of cataract at an earlier age than the American, and, while prematurely old, his tissues do not impress one as having undergone the degenerative changes we often see in our cataract patients. Indeed, the evidence of the general degenerative diseases of age are far more common with Americans. Fluid vitreous was seldom seen, and I do not believe that vitreous opacities are as frequent, though on this point I cannot speak with certainty.

Both in the physical condition of the patients and the state of their eyes the Indians present far greater uniformity than Americans, and it is the rule, rather than the exception, to have the eyeball after delivery of the lens fall back into the depth of the orbit with the lips of the wound showing a tendency to gape until the eye is rendered more full by allowing the weight of the lids to again fall more or less upon it.

In the after-treatment there is also far greater uniformity among the Indians than among Americans, in the tendency quietly to accept slight discomforts and take them as a matter of course. This renders the long-continued closure of the eyes after operation, which is found to be so necessary, far more easily borne by the Indian.

When we recall the care with which, in many of our more exacting patients, we must avoid every source of possible discomfort, and the number of instances in which we must remove the dressing to relieve some slight annoying irritation, we will realize that there are many of our cases in

which this operation is impracticable if we are to secure the best results.

In conclusion, it may be said that, in some important respects, the average Indian, with his quiet and submissive manner of accepting what comes to him, his simple life, and his freedom from redundant flesh and orbital fat, may be regarded as a more favorable subject for cataract extraction than the average American, but when we consider the absence of preparation, the poverty, and caste prejudices of the patient, which hamper one at every turn, and the limited resources of the hospital, we realize that these advantages enjoyed by Major Smith are largely offset by serious disadvantages. When I state that of 450 patients under treatment at one time in the new hospital only two were fed by the hospital authorities, the remainder being cared for and fed in Indian fashion by their friends, it will be realized that the limitations of poverty and caste restrictions as to food are important factors in estimating the chances of obtaining good results.

Personally, I am proceeding cautiously in the study of this subject, and am by no means ready to give a final opinion on the merits and limitations of extraction in the capsule in our American practice, and, for the present, shall limit my employment of it to selected cases; nevertheless, it is my belief that in these selected cases it is as well adapted to the American as to the Indian eye.

DISCUSSION.

DR. ROBERT SATTLER, Cincinnati: Dr. Clark's paper refers to new points of interest of the Smith-Indian operation, the signal feature of which is the third movement or delivery of the lens in its intact capsule. The question remains an open one whether the average ophthalmic surgeon is justified in adopting this new method for our Anglo-Saxon, Teutonic, and Latin contingent of cataract cases even though in the hands of Major Smith and his followers it

has been proved, on numerical evidence which must astound us, to be safe and satisfactory for the mixed population of India which, racially, as we know and have been told, differs so widely from our own cases.

The technical execution of Major Smith's discovery of delivering the lens in its unbroken capsule differs from all former ones, and for this reason deserves an impartial and disinterested consideration of its merits. It deals with lens and capsule in one movement. If successful, the visual result remains unassailed and subsequent surgery is not necessary.

From my own experience with the Major Smith method as such, or in substituting intracapsular or joint removal of capsule and lens for the similar movement of the older or modified linear one, I am convinced that it will hold its place for a certain smaller number of our cases. For a larger number it may yet prove itself the long sought after and a most rational substitute for the similar one of the older perfected method, so long and successfully part of it, but open to so many admitted objections and dangers.

DR. R. L. RANDOLPH, Baltimore: I should like to ask what success has been obtained in operating upon negroes. My own experience is that, as a class, they are most difficult to deal with. Many of my cases have iritis and give me more or less trouble. I have never performed the intracapsular operation, and am perfectly satisfied with the old method, and I rather think that if I were to be operated upon I should prefer what looks like the height of conservatism, namely, a preliminary iridectomy and extraction later. I have never thought that the so-called Smith method would find any sure foothold in this country.

DR. HERBERT HARLAN, Baltimore: I have done the operation upon negroes, and with the same success. The negro is more difficult to control. He is nervous, and will often not look the direction you tell him to.

LARGE PIECE OF WOOD EMBEDDED DEEPLY IN ORBIT OF A CHILD TWENTY-FIVE MONTHS. REMOVED, WITH PRESERVATION OF VISION.

C. A. VEASEY, A.M., M.D.,
Spokane, Washington.

In October, 1907, A. P., a two-year-old baby, fell and injured his right eye. No one was with him at the time, and how it was injured or by what was not known. He was discovered crying and saying, "Stick, stick," but that was all that could be ascertained. A small spot of ecchymosis was observed beneath the ocular conjunctiva, and the child was taken to an ophthalmic surgeon. As there seemed to be only a small conjunctival wound and no definite history of the method of injury, only a cleansing lotion was ordered. The wound healed, according to the father, in a short time.

Twenty-five months later the patient, now four years of age, was brought for advice because of a mucopurulent discharge that had been present in the formerly injured eye for several months. During the few weeks immediately preceding his visit the discharge had become much worse. An examination of the eye showed the conjunctiva to be in a healthy condition. There was slight convergence, subsequently ascertained to be due to cicatricial tissue. To the nasal side of the cornea, about 5 mm. from the limbus, there was a small opening in the conjunctiva from which discharge was oozing. Believing that in all probability a foreign body had penetrated the orbital tissues, and that the discharge was emanating from a sinus thus created, the child was anesthetized for exploration and whatever operative procedure might be found neces-

sary. When the opening in the ocular conjunctiva was slightly enlarged, it was discovered that the internal rectus muscle had been entirely severed from its attachment to the eyeball and had become embedded in a mass of tissue adherent to the nasal wall of the orbit. An outer pocket had been formed, with the eyeball on one side, the severed internal rectus and a mass of conjunctival tissue on the other, and conjunctiva above and below, which communicated with the deeper orbital tissues by means of a very small sinus. Enlarging this opening and proceeding backward, we discovered a more or less pointed piece of wood, which was removed with some difficulty by means of a pair of hemostatic forceps. It was found to be 2.5 cm. in length, the larger end being about 3.5×2.5 mm., the pointed end somewhat smaller. As the anterior end of the stick was approximately as deep in the orbit as the posterior portion of the eyeball, and it pointed straight backward, the posterior end must have been very near to the sphenoidal fissure. The wound was closed, and firm primary union took place in a few days. The optic nerve at no time showed any involvement, though the foreign body had been lying in proximity to it for twenty-five months.

The case is of much interest because of the age of the patient, the size and shape of the foreign body, the length of time it remained embedded in the orbital tissues, the small amount of damage, the successful removal, and primary healing.

DISCUSSION.

DR. LEWIS H. TAYLOR, Wilkes-Barre: I reported, a number of years ago, an interesting case of foreign body in the orbit—interesting from the severity of the injury and subsequent recovery, and interesting in connection with the case reported by Dr. Veasey as showing a possible origin of the foreign body. A child, twenty months old, was brought to me with a history of injury three weeks

before. The tissues were greatly swollen and tense, and a mucopurulent discharge was forcing itself between the tightly closed lids. The mother stated that the child had been playing with a pen-holder, had fallen forward, and the pen-holder had entered the left side of the nose and had broken with the force of the fall. The family physician had removed three pieces of pen-holder, but the mother thought there was more left. I placed the child's head between my knees and forced the lids apart with great difficulty, and found a foreign body presenting in the lower part of the conjunctival sac. I removed this, and found it to be a piece of the pen-holder $1\frac{1}{16}$ inches long, $\frac{1}{8}$ inch in diameter at the small end, and $\frac{3}{16}$ inch in diameter at the larger end. This had been forced through the nose and into the tissues of the orbit. It would seem almost impossible that such an accident should occur. Under appropriate treatment the swelling subsided and useful vision was maintained.

DR. W. E. LAMBERT, New York: I recall a case similar to that reported by Dr. Veasey. A boy was brought to the New York Eye and Ear Infirmary with an orbital cellulitis and a small opening in the upper lid, just below the orbital margin. The history of the case was that some weeks previously the boy had fallen in the woods and a small branch had perforated the upper lid. This was pulled out by the mother, but the wound had never entirely healed. Recently the lid had become more swollen and the vision very poor.

The boy was taken into the hospital, and in probing the wound a small piece of stick was found. The wound was enlarged, the wood removed, and rapid recovery followed. It was found, however, on examination of the fundus, that there was optic atrophy with little more than perception of light.

DR. M. H. POST, St. Louis: A similar case occurred in my practice. Two operations were done, the first about seven months after the accident. A piece of wood, $\frac{1}{2}$ inch long by $\frac{3}{16}$ inch wide, was removed. The child was supposed to be cured, but twenty-eight months later a discharge occurred, and upon exploration still another piece

was discovered and removed, the second measuring nearly as large as the first. The accident occurred in the early part of 1890, and I last saw the patient in November, 1906, at which time vision was $\frac{20}{24}$ in each eye.

CONJUNCTIVAL FLAPS IN OPHTHALMIC SURGERY.

W. GORDON M. BYERS, M.D.,
Montreal, Can.

In perforating wounds of the cornea and sclerotic the danger of intra-ocular infection is heightened by peculiar local conditions. In the first place, as is well known, one has, even in the normal conjunctival sac, micro-organisms ever ready to pass through possible openings in the protective coats of the eye, and to produce intra-ocular inflammations of the most destructive character. Still greater is the danger of mischief within the eye in cases of inflammation of the conjunctiva, and especially in cases of obstruction of the lacrimal canal. Long before bacteriology had isolated the organisms present it was known clinically that to open the globe in the presence of these conditions was to court an almost certain panophthalmitis; and it has been for years an ophthalmic maxim never to enter the eyeball under these circumstances. A second predisposing factor is attributable to the density of the cornea and the sclerotic, and to the poor vascular supply of these structures. Because of the rigidity of the protective coats of the eye there is slow and imperfect coaptation of the lips of wounds of their tissue; and, because of the paucity of blood-vessels,—and this applies particularly to the cornea as being an entirely avascular structure,—fibrinous extravasation and cellular proliferation are tardy

and inefficient. Wounds of the cornea, as is well known, are permeable to bacteria for many days after their infliction. Lastly, one has the interior of the globe occupied by a culture-medium—the vitreous—eminently adapted to the growth of micro-organisms. Not infrequently in operative procedures, and very often in traumatic perforations of the globe, the vitreous is brought into direct contact with infective agencies, through rupture of its delicate hyaloid membrane, and prolapse of its substance into the wound. Here, in spite of our most painstaking efforts to free them, tags of vitreous will at times remain as fuses leading to the inflammable mass within.

To combat these inherent defects one has a valuable agent in the conjunctiva of the eyeball.* Unlike the sclerotic and the cornea, it is richly vascular; can deliver an abundant supply of agglutinating lymph, which quickly gums together the lips of the wound; can rapidly furnish a large force of protecting leukocytes; and lend from both its epithelial and subepithelial structures elements that early and materially assist in the repair of tissues with which they may be brought in contact. In a mechanical way, too, its anatomic peculiarities—its delicate scleral attachments, its elasticity, allowing of considerable lateral expansion, and, again, its abundant blood-supply—make of it a structure admirably adapted for plastic work.

The principle of conjunctival flaps, if I may use the expression, was first enunciated by one of my teachers, Professor Schoeler,[1] of Berlin, who published his valuable paper on the subject in 1877. This communication, however, appeared in a report which was not widely read, and the suggestions contained therein were, as a consequence, not immediately adopted by the profession. It remained for Professor Kuhnt, who had independently worked out

* The part played here by the conjunctiva is similar to that taken by the iris, acting within, in perforated wounds of the cornea. See paper by my colleague, F. Torke, Oph. Rec., August, 1908.

the same idea, to fix the matter as a distinct ophthalmic practice. In several valuable communications, with which every oculist should be familiar, Professor Kuhnt[2] has so elaborated the principle that, with the work of Professor Schoeler, really very little remains to be said on the subject. Much of what is presented in this short paper is already known to members of this society; but I am convinced, from my reading and from wide observation, that conjunctival flaps are still not so generally appreciated and employed by ophthalmic surgeons as they deserve to be. It is the object of this paper to once again emphasize the value of the suggestions of Professors Schoeler and Kuhnt, and, incidentally, to bring to your notice a few minor variations of the principles which have grown out of my own practice and experience.

In the first place, while not used here in the form of a true flap, the conjunctiva is of great protective value in so-called "needling" operations. Early influenced, while house-surgeon at "Moorfields," by a case of panophthalmitis which I saw develop after discission of a lamellar cataract through corneal tissue and entirely destroy the eye, I have always availed myself of a peripheral route in doing this operation. My practice has invariably been, starting a few millimeters from the corneoscleral margin, to puncture the conjunctiva, and, having passed the needle beneath the conjunctiva the distance mentioned, to enter the anterior chamber through the ring of sclerotic that forms its confine. The advantages of this procedure are so apparent that it is remarkable that so many operators still do their discissions through corneal tissue, and so many authors still describe the old corneal route.* In doing a

* See, for example, May, Diseases of the Eye, sixth edition, 1909, p. 206; Swanzy and Werner, Diseases of the Eye, ninth edition, 1907, p. 489; and Fox, A Practical Treatise on Ophthalmology, 1910, p. 421. I would go so far as to say that, in the light of the knowledge of the bacteriology of the conjunctiva which we now possess, needlings through corneal tissue are no longer justifiable.

needling in the way I have described so little aqueous is lost that one can, in clear view, make the repeated attempts which are often necessary to effect an opening in a tough capsule; and, on withdrawing the needle, the conjunctiva merely contains a wound which can be considered as practically sealed the moment the operation is ended, and is, under any circumstances, situated at a safe distance from the scleral opening. In needling through the cornea the aqueous almost invariably escapes, the globe becomes lax, and the cornea dull; clear vision during the procedure is difficult or impossible; the pupil often contracts and still further obscures the field; and, in the end, a track is left in the rigid corneal tissue which for days is permeable to pathogenic organisms.

In capsulotomies as generally performed, because one is obliged to puncture the hyaloid membrane, a certain amount of vitreous often escapes from the anterior chamber; and, though one carefully trims this away, one must necessarily have shreds which remain and are exposed to infection. To prevent this and to secure speedy union of the lips of the wound it has always been my practice to create a small conjunctival flap with the scissors before going through the corneoscleral junction, and to seal my wound by turning it back at the end of the operation. The ease with which this great protection can be obtained should make its application obligatory in every case of this kind.*

In the extraction of senile cataracts the preparation of a conjunctival flap has very generally formed a step in the operation, since attention was drawn to the matter by Professor Snellen,[3] at Edinburgh, in 1884. The method of carrying out the procedure and its great value are so well known that it would be quite superfluous on my part to dwell upon them at length at this time. I only wish to

* I find, on looking up the literature, that Professor Snellen advocated the same procedure in performing iridectomies for glaucoma.

point out here that the usefulness of the flap is, to a certain extent, limited by its incompleteness when made in the ordinary way, and to cite a case which illustrates this point, as well as an extreme application of the principle.

Mrs. T., aged seventy-one, consulted me on June 8, 1907, for loss of sight in both eyes. On examining the patient I found a mature cataract and chronic obstruction of the lacrimal canal on each side. Pressure over the lacrimal sacs caused a slight regurgitation of mucoid material, which, when examined by Doctor Klotz, was found to contain staphylococci and the bacillus mucosus capsulatus of Friedländer. The indications were clear, and I first excised both lacrimal sacs by the new subperiosteal method. Ten weeks later, when perfect healing had taken place, when the conjunctiva looked healthy, and smears and cultures showed only staphylococci in the conjunctival sac, I removed the cataract from the right eye. The operation in itself was perfect; a large conjunctival flap above brought about rapid closure of the wound, and on the following day the eye looked clear and bright. Twenty-four hours later, however, unmistakable signs of commencing panophthalmitis were present, apparently from infection through the lower inner end of the corneal incision; and six days later the eyeball was so completely disorganized and painful that an evisceration had to be done. The patient was, needless to say, greatly disappointed; but she consented, in the following November, to have me do the other eye. This time I decided to take no chances, and at the operation first prepared with scissors a large conjunctival flap which extended well back over the globe, and downward so far that, when replaced, it thoroughly covered the point of entrance and the point of exit of my knife on the outer and inner side of the globe respectively. Otherwise the operation was performed in the usual way, the only difficulty being slight hemorrhage and slight obscuration of the upper part of the cornea in making the section. Healing of the large flap was rapid and uneventful, and the result of the operation was satisfactory in every respect.*

* I have in mind now the case of an old man who is entirely blind from

In removing foreign bodies from the interior of the globe by the electromagnet I follow a rule of thumb which is very generally observed—if the foreign body is in front of the iris and ciliary body, extract from the anterior chamber; if behind, through the sclerotic. In the latter case it is generally the custom to enter the globe directly through the conjunctiva; but, as here again the vitreous cavity is directly opened up, I prefer to place the conjunctiva as an obstacle in the way of infection. I make an incision which runs parallel to the fornix and midway between this and the limbus, and then cuts which run from either end of the first incision toward the cornea. The flap, made of a size to suit requirements, is dissected up and turned back, and the sclerotic as now exposed is incised for the removal of the foreign body. When this has been removed and the flap replaced and fixed in position by a couple of sutures, one has perfect protection of the scleral opening and practical freedom from the danger of infecting the vitreous or tags of this substance leading to the interior of the eye. In all the cases I have operated upon in this way the result has left nothing to be desired.*

The use of the conjunctival flap in Mules' operation has always seemed to me of definite value. In the operation as originally described by Mules, sutures were passed directly through the conjunctiva and sclerotic to close the eyeball anteriorly after the removal of its contents and the insertion of the glass globe. A few unfavorable cases in which breaking down of the wound and extrusion of the globe occurred led the late Doctor Buller to think that infection along the deep sutures, with consequent suppuration, was the cause of his failures, and he modified

senile cataracts. Persistent and long-continued efforts have entirely failed to eliminate large numbers of colon bacilli from his conjunctival sacs, and I believe an operation along these lines offers the greatest chance of success.

* My confrère, Doctor George Matthewson, tells me that in Vienna Professor Fuchs employs the Kuhnt flap to close the wound in his cases of extraction of a foreign body from the globe by the electromagnet.

the operation in the following way: Instead of cutting directly into the eyeball, he first incised the conjunctiva immediately about the whole periphery of the cornea, and for some distance backward freed this membrane from its slight scleral attachments. He then removed the cornea, eviscerated the contents of the globe, and inserted the glass ball in the usual manner, but closed his wound in a manner somewhat different to that proposed by Mules. The edges of the scleral opening were brought together in a vertical direction by fine silk sutures which were allowed to remain and become embedded, while the edges of the conjunctival aperture were sewn together in a horizontal direction with silk sutures which were afterward removed. In this way not only was the wound strengthened, but the possibility of infection of the scleral stitches was entirely excluded.

The last point in connection with the operative phase of conjunctival flaps to which I wish to call your attention is a small one in connection with the repair of scleral wounds. It is a very general custom to cover the rupture in these cases by conjunctival flaps, but almost invariably the sutures are placed directly over the aperture leading to the vitreous or through which vitreous is protruding. A danger arising from this practice and a method of overcoming it are illustrated by the following cases:

A young man consulted me at my office for an injury which he had received but a few minutes previously, while cutting branches from a tree with a pen-knife, directed accidentally to his right eye. On examination I found an oblique wound of the cornea which extended from about the center of this structure to a point well beyond the ciliary region in the sclerotic coat. There was slight retraction of the pupil at a point corresponding to the wound, and the tension of the globe was reduced. Later on in the day, with the patient under general anesthesia, I completely freed the prolapsed iris and brought conjunctival flaps

over the wound, placing the sutures, however, directly over the wound in the usual way. At the first dressing on the following day everything looked perfectly satisfactory; but twenty-four hours later the eye presented the signs of an incipient panophthalmitis, which had apparently originated from an infection that had entered the globe along the tracks of the conjunctival sutures. In spite of everything that could be done, the eyeball was lost.

This experience suggested to me the advisability of placing the edges of the conjunctival flaps and their sutures at a safe distance from the scleral opening, and I have since always done this in the way described in the following case:

A young lad was injured by a stone while at play on the afternoon of September 2, 1902. On examining the right eye I found a horizontal wound which extended from a few millimeters in front of the corneoscleral margin to a point about one centimeter behind the limbus. Vitreous was presenting, the pupil was irregular from iridodialysis of its outer periphery, and there was a small hyphema in the anterior chamber. Under cocain I cut away the vitreous and prepared my flaps in the following manner: the upper one I dissected up so freely from the sclerotic that it readily lent itself to considerable stretching and displacement, while from the lower one I merely cut away a portion of its upper border. On bringing the edges of these flaps together I had a conjunctival wound the suture line of which extended somewhat obliquely, but well below the scleral aperture. It is virtually impossible to have contamination from the conjunctival sac under these circumstances, and the case made a perfect recovery, with $\frac{6}{5}$ vision.

Another case which I believe could not have been saved by any other means is as follows:

A little girl of thirteen was referred to me two years ago by Doctor Skeels, of St. Albans. She had been struck in the left eye by a piece of stone two days previously. On examination I found a large rupture in the lower outer quadrant of the sclerotic coat, a triangular flap of which was pressed back by the protruding ciliary body. There

was slight pericorneal injection, but the pupil was active and there was no intra-ocular hemorrhage. In spite of the apparently hopeless aspect of the case I decided to attempt to save the eyeball. Accordingly, under general anesthesia, I cut away the prolapse of uveal tissue, replaced the scleral flap, and fixed it in position by two fine China-silk sutures similar to those which I use in Mules' operation, and, finally, covered the whole field with conjunctival flaps prepared in the way described in connection with the preceding case. The eye quieted rapidly, and, though watched carefully by Doctor Skeels, has never shown any signs of recurring inflammation.

The use of conjunctival flaps as an aid to healing in inflammatory conditions of the cornea, and especially in perforations of this structure, is another aspect of this subject which does not, it seems to me, receive the serious attention to which it is entitled: but I have purposely avoided this topic to speak only of operative procedures at this time.

BIBLIOGRAPHY.

1. Schoeler, H.: Der Bindehautlappen, Jahresbericht über die Wirksamkeit der (früher Ewer'schen) Augen-Klinik, Berlin, 1877.
2. Kuhnt, H.: (*a*) Beiträge zur operativen Augenheilkunde, Jena, G. Fischer, 97 pages.
   (*b*) Vorschlag einer neuen Therapie bei gewissen Formen von Hornhautgeschwüren, Wiesbaden, T. F. Bergmann, 1884, 21 pages.
   (*c*) Über die Verwertbarkeit der Bindehaut in der praktischen und operativen Augenheilkunde, Wiesbaden, T. F. Bergmann, 1898, 149 pages.
3. Snellen, H.: On the Subconjunctival Treatment of Operative and Traumatic Wounds of the Cornea and Sclerotic, Trans. Eighth Int. Oph. Cong., Edinburgh, 1894, p. 9.

DISCUSSION.

DR. CHARLES J. KIPP, Newark: I have for years followed the method of covering large wounds in the cornea by a conjunctival flap. I use the method only in cases in which the wound is very large, extending almost across the entire cornea. In all cases the flap healed and the patient got well. I have many similar cases in which I did nothing at all, and they did just as well.

In regard to the conjunctival flap in operations on the

sclera or for foreign bodies, I suppose we all follow a similar method. I have also extracted cataract according to the subconjunctival method of Czermak. Results were good so far as healing was concerned; in some cases there was loss of vitreous, and here there was extreme difficulty in getting the lens out.

DR. WILLIAM M. SWEET, Philadelphia: I believe that most operators recognize the value of a conjunctival flap to cover the incision made in the sclera for the extraction of foreign bodies. In injuries of the sclera I have followed the usual practice in small wounds of dissecting away the conjunctiva from one side of the cut, so that the loosened membrane from the other side may be drawn over and entirely cover the opening. If the wound is extensive, I believe that closer apposition of the edges of the scleral cut is secured by passing the sutures some distance beneath the conjunctiva on each side of the wound, without removing any of the membrane. My experience with incised wounds at the limbus has been that, with the use of a bandage, the cut heals promptly, but later opens with the restoration of normal tension of the globe. This does not occur if the wound is covered by a conjunctival flap.

DR. CARL KOLLER, New York: I can recommend the method of making a small conjunctival flap in cases of extraction of soft cataract (letting out cortical masses from the anterior chamber). In the classic method of "linear extraction," as described in the text-books, the lance incision is made well within the clear corneal tissue. This sometimes occasions prolapse of vitreous, favorable to infection of the eyeball. Still more frequent with this method is enclosure of capsule strands in the wound, followed by the formation of adhesions of the sphincter to these contracting strands, thus producing a fine anterior adhesion of the iris. All this is avoided with a peripheral incision, going under the conjunctiva for a stretch of 2 mm., entering the ball at the sclerocorneal junction at such a slant that prolapse of the iris or capsule is an impossibility. The credit for first describing a number of related proceedings belongs to Kuhnt, who has thus enriched our operative technic. Without making any claims, I may say that I have practised

this method of linear extraction for many years before it was described, and am satisfied that the results are superior to the old classic method.

DR. J. E. WEEKS, New York: I have used the conjunctival flap in cataract extraction, and I have had some experience in closing fistulæ of the cornea by means of the conjunctival flap. The closure was effected and was successful in two cases.

DR. CHARLES A. OLIVER, Philadelphia: Dr. Oliver stated that he had also employed the flap made from both above and below, as recommended by Kuhnt, in centrally placed ulcers. He did it in such a way in each case, as to cover the affected corneal area to advantage. He made use of the method only in such cases in which he felt certain that there was absolute freedom from infection, believing, with Dr. Herman Knapp, that an aseptic corneal ulcer does not need a conjunctival flap, and that it is unwise to cover an infected ulcer. The peripherally placed exposed subepithelial surfaces he allowed to granulate.

DR. G. E. DE SCHWEINITZ, Philadelphia: Dr. de Schweinitz agreed with Dr. Byers in the value of conjunctival flaps, as he had described them, and recited the case history of a patient in his own care with severe injury of the lid, which directly overlay a transverse incision of the cornea from one side to the other, through the entire length of which the iris was prolapsed. The lid wound, when the patient came under his care, was already infected, and, therefore, after cleansing its margins and uniting them with sutures and removing the prolapsed iris, the entire cornea was covered with the conjunctiva which was dissected back to the insertion of the ocular muscles, and secured over the cornea with a purse-string suture, where it remained for eight days, when the stitch was cut, the conjunctiva put back into place, and the corneal wound found completely healed, without the least sign of infection. This method of covering extensive wounds of the cornea with the conjunctiva was in accord with the technic originally elaborated by the late Dr. de Wecker.

DR. R. A. REEVE, Toronto: I have had gratifying results in

saving the eyeball, not for vision, in cases of progressive ectasia in sloughing ulcer of gonorrheal ophthalmia. I made horizontal flaps above and below the cornea, then slit through the cornea, and stitched the flaps in place, thereby saving an eye which otherwise would have required enucleation.

DR. SAMUEL THEOBALD, Baltimore: I have had no experience with the operative procedures described in Dr. Byers' paper, but I cannot but think that it must result not infrequently in the formation of a pseudopterygium.

REPORT OF A CASE OF LEUKOSARCOMA OF THE IRIS SUCCESSFULLY REMOVED BY IRIDECTOMY AND USEFUL VISION RETAINED.

JAMES THORINGTON, A.M., M.D.,
Philadelphia.

(PATHOLOGIC FINDINGS BY HAROLD G. GOLDBERG, M.D.)

As sarcoma of the uveal tract is seldom observed as a primary disease of the iris, and still more rarely of the colorless variety, is my excuse for reporting this interesting case.

In reviewing the very complete "Statistical Study of Primary Sarcoma of the Iris" in the Annals of Ophthalmology, vol. vi, No. iv, October, 1897, by Dr. Clarence A. Veasey, I find that this case, which I herewith report, is unique as occurring in a female at the age when sarcoma of the iris is most rarely found, and the variety of the growth is of the mixed-celled class, which is also of the most unusual type.

Annie G., aged twenty-seven years, born in Ireland, waitress by occupation, came under observation in October, 1906, when twenty-four years of age, with the following history: Had never known what it was to be able to see as clearly as

her relatives and friends, and vision of right eye never as good as that of the left. Always had more or less headache, which she now attributes to her eyes. Says she has always been known as the weak or delicate one of eight children, being very thin and also pale of complexion. When six years of age, without any known reason, all her hair fell out and she was bald and compelled to wear a cap for about one year, when the hair gradually grew and has been full and strong ever since; in fact, she has more hair than she requires. Family physician at that time said that the falling of the hair was due to "weak nerves." No other member of the family was similarly afflicted. In fact, the members of her family are all of robust health. Her hair at present is dark brown in color and most abundant. Patient had the ordinary diseases of childhood, measles, whooping-cough, and chicken-pox. Never had scarlatina or diphtheria. Vaccination took normally. Menstruation commenced at thirteen and one-half years, regular and normal.

October, 1906, condition of eyes as follows: Right eye noticeably divergent; pupil 4 mm. in diameter and round. Iris blue in color, and reacts promptly to light, convergence, and accommodation. Left eye, the fixing eye. Iris also blue in color, and reacts normally. Pupil same as its fellow. R. E., $V = \frac{IV}{XXX}$; L. E. $V = \frac{IV}{XIISS}$. Ophthalmoscopic examination: R. E., media clear, disc vertically oval, axis 105°. No gross fundus changes. Refraction; mixed astigmatism. L. E., media clear, disc oval, axis 45°. Retinoscope reveals slight conicity of cornea. Refraction equals plus cylinder. Glasses ordered: R. E., −2.50 sph. ⊂ + 4.50 cyl. axis 105°. $V = \frac{IV}{XXV}$; L. E., + 1.50 cyl. axis 35°. $V = \frac{IV}{VIISS}$.

Patient returned three years later, namely, October, 1909, stating that the headaches of which she complained at her former visits had ceased since wearing the glasses, and that she returned at this time on account of a white spot in the lower outer quadrant of the left iris, which had first been noticed by her friends during the previous February. This white spot had gradually reached its present

Leukosarcoma of the Iris

size from a small beginning, about the size of a common pin-head. Its present size is about 3×4 mm., and is shown in accompanying colored sketch. It is more of a whitish-yellow cast, and at its summit has a pinkish color, as seen with magnifying glass, and some few vessels. The growth does not extend to the ciliary border of the iris. No history of any pain, soreness, or redness in or about the eye since this condition was first noticed. Vision with correcting glasses has remained unchanged. No fundus changes noted through a dilated pupil.

Diagnosis, leukosarcoma, for the following reasons: (*a*) Patient, a female—sarcoma of the iris occurs in females in 70% of the cases. (*b*) Lower outer quadrant of the iris the most common seat of the growth. (*c*) No history of injury and no history or evidence of syphilis or tuberculosis. (*d*) Growth did not resemble gumma, tubercle, or melanoma.

Taking advantage of the kind offer of Dr. deSchweinitz to see this patient at his clinic, I was pleased to have this most probable diagnosis confirmed.

In the consideration of treatment it was deemed advisable to remove the growth by iridectomy as promptly as possible. Patient was admitted to the Polyclinic Hospital the following day, October 20, 1909. Blood count normal; urine negative; lungs, heart, and liver normal. On October 21st ether was administered, and I removed the growth in situ, together with surrounding healthy iris tissue. First making a large corneal section with a broad Graefe cataract knife in the lower outer quadrant of the cornea, the iris and growth were permitted to prolapse from the corneal wound. With iris forceps the iris was drawn out at the temporal side of the growth and incised; then the iris was gradually torn from its root downward to the nasal side of the corneal wound and excised. There was no unusual amount of hemorrhage. However, the conic cor-

nea condition previously mentioned became a factor as soon as the corneal wound was made, as the cone immediately collapsed and for a few seconds obstructed the view. The corneal wound healed promptly and without any bad symptoms. Subsequent refraction: L. E., −1.00 sph. ⊂ + 3.00 cyl. axis 30°. $V = \frac{IV}{VI}$. The specimen was placed in a 5 % formalin solution, and given to Dr. Harold G. Goldberg, who prepared the section and reported as follows:

The main body of the growth is made up of small round sarcoma cells with a few spindle-cells, these possibly the result of sectioning. The stroma has been entirely replaced, and the retinal pigment is somewhat proliferated. There is almost complete atrophy of the muscle; only traces of the transverse fibers can be seen. The retinal surface is the most vascular, and here typical blood-spaces are found, some containing polynuclear leukocytes and some few with a modified endothelial lining. These last, however, are not perfect, but are made up of only one wall. On the anterior surface of the iris the growth is somewhat lobulated in appearance, and here the spindle-cells predominate. The lobules seem to extend through the limiting membrane to the surface in the form of plugs. These can best be observed in the longitudinal sections, and are undoubtedly growth extensions. There is a general proliferation of the endothelial elements throughout the entire mass.

April 30, 1901, the patient's eye is perfectly quiet and has good vision. The general health has never been better.

DISCUSSION.

DR. C. A. VEASEY, Spokane: Between fourteen and fifteen years ago I removed a primary melanotic sarcoma from the iris of a man forty-six years of age by iridectomy. Subsequently I extracted a cataractous lens from the same eye, the patient obtaining normal vision. There has been no recurrence, either local or metastatic, to date, nearly fifteen years later. A number of other cases of successful

removal by iridectomy have been reported, and it seems to me that the opinion I expressed in a monograph written thirteen years ago still holds good, viz., that in cases of small sarcomata of the iris in which the ciliary border is not involved an attempt should be made to remove the growth by iridectomy.

DR. F. M. WILSON, Bridgeport: A case of orbital sarcoma of mine has figured for some years in our Transactions as non-recurrent. I have here four photographs. Two of them are a front and side view of a large fibrosarcoma of the orbit which I removed some twelve years ago. The other two give a front and side view of a much larger fibrosarcoma of the same orbit, which has been growing three years. I kept the woman under observation for seven years. I showed the patient to the New York Ophthalmological Society, both before and after the operation. The specimen is now in the pathologic museum of the New York Eye and Ear Dispensary. I also reported the case to our society in New London in June, 1898, with specimen and full pathologic report. About three years after operation I again presented the patient to the New York Ophthalmological Society with a perfectly smooth orbit. About four or five years after operation I reported to a committee of this society that there had been no recurrence of the tumor. In 1904, or six years after operation, a picture of the case was put in a text-book on ophthalmology. I kept track of the case for one year more. Then for five years I did not see the case. It seems only fair that this subsequent history should go on record. The case has been a peculiarly discouraging one to me. She carried the original tumor twenty-three years. Here we have a case of very slight malignancy, probably starting as an absolutely benign tumor, and yet, after complete removal, nine years later, we have a return of the tumor.

NEW-GROWTHS OF THE LACRIMAL GLAND—A CASE. DEATH.

EDWIN E. JACK, M.D.,
Boston, Mass.

(PATHOLOGIC REPORT BY F. H. VERHOEFF, A.M., M.D.)

New-growths of the lacrimal gland are rare. I do not hesitate, therefore, to bring the subject to your attention, though I have but one case to report: that one, however, is interesting and instructive, illustrating well the form of growth which in recent years has been recognized as the most usual one attacking the gland, and exhibiting also the tendency of these growths to spread and the fatal issue which must surely follow imperfect removal. The weight of authority goes to prove that the most frequent of these new-growths, in fact, by far the great majority, are of a mixed variety, often containing cartilaginous, hyaline, and myxomatous tissue, entirely analogous to certain tumors of the salivary and parotid glands. It is easy to understand this similarity when we bear in mind that these glands, the lacrimal and salivary, are quite alike, both being serous and tubular; when we recall, too, that dacryo-adenitis occasionally occurs in parotitis, and, further, that simultaneous growths of both glands have been reported. These tumors have, in late years, been generally regarded as endotheliomata—not, however, without some protesf—having their origin from the endothelial lining of the lymph-spaces, the cells showing marked tendencies to become metaplastic, and changing to cartilaginous, hyaline, and myxomatous tissue, as before mentioned. The credit of calling attention to the essential similarity of these lacrimal gland tumors

and those of the salivary glands belongs to Warthin, who in 1901 reported 132 cases of lacrimal gland growths collected from the literature up to that time. To these tumors 45 different pathologic names had been given by the reporters —5 were not diagnosed. I will not weary you with a recital of these names, nor go into the details of how Warthin was led to the conclusion that the most, certainly, of these apparently very varied growths, were in all probability examples of one and the same thing, namely, the mixed tumors to which I have referred. It must be remembered that the conception of tumors has changed, and with this fact to modify older diagnoses, and from a careful résumé of the microscopic findings in those cases in which such were reported, Warthin came to this conclusion—a conclusion agreed with and verified by Verhoeff, whose work on these tumors, published in 1905, I shall refer to later. Warthin suggested that the term endothelioma should, in these cases, be modified, inasmuch as endotheliomata were, in other places, of the nature of sarcomata, and usually very malignant, while in the lacrimal gland they were more of the nature of connective-tissue tumors. Such a designation as myxochondroma endotheliale was advised.

The pathologic history of these lacrimal gland tumors has been repeated in those of the parotid largely through the studies of von Ohlen and Kelley. Less has been done on the submaxillary gland, but the same is held to be true there. Of the ten or twelve cases reported since Warthin's article, five are the basis of the monograph by Verhoeff, who goes thoroughly into the pathologic examination of the cases, reviews the work of others, and states as his conclusion that these tumors are really epithelial in character and not endothelial, "the stroma being produced by an atypical development of cells which ordinarily would have gone to form part of the stroma of the normal gland, and not derived from mesoblastic cells misplaced from other structures." It

is not my intention, however, to enter into the pathology of these tumors. Those interested will find much that is valuable on this subject in this monograph and in Warthin's article, published in Knapp's Archives in 1901. The five cases which Dr. Verhoeff has collected are all from the clinic of the Massachusetts Charitable Eye and Ear Infirmary, and comprise the only tumors of the lacrimal gland removed at the Infirmary during a period of ten years, four of them occurring in a consecutive series of 200,000 eye patients. These facts are in accord with the previous statement that these mixed tumors are by far the most frequent of lacrimal gland new-growths, and that, also, they are rare. It is in line, too, with Wood's statement that 95% of the new-growths of the salivary glands are of this type. I would add that Wood is an advocate of the epithelial origin of these growths in the salivary glands. Some of the more recently reported cases have been called cylindroma, sarcoma, and adenocarcinoma, but in at least one of these the diagnosis was attacked at the time the report was made. With these preliminary remarks I wish to add to the small list of published cases the report of one more case of mixed tumor of the lacrimal gland.

The patient was a man, aged thirty-six, a ship carpenter, strong, robust, and of exemplary habits. The history of the growth in point of time was rather indefinite. The sight of the eye was known to have been poorer than that of the other for fifteen years, but his wife noticed evidences of the growth only nine years before. After this the growth became more and more apparent. The left eye was very markedly pushed down and in, and there was considerable exophthalmos. The movements of the eye, except upward, were good. The fundus showed only a hazy red disc. Vision with a glass—the eye was hypermetropic—was $\frac{5}{12}$. Under the brow, in the region of the lacrimal gland, could be felt a mass as large as a hazel-nut. At times there was pain in the eye, and occasionally it became blood-shot

and felt irritated. The right eye was normal, and with correcting lens had normal vision.

An operation was advised at this time, December, 1904, but it was not till January, 1907, that it was accepted. The vision had fallen off during this time to $\frac{5}{27}$; the disc was hazy, and the retinal vessels were tortuous; the displacement of the eye and the exophthalmos had increased. The operation was easy, and the growth was removed apparently entire. The result of Dr. Verhoeff's examination is given in his report. Later the vision rose to $\frac{5}{12}$ again; the eye, however, did not readily assume a normal position. Things went on apparently favorably; the region of the wound bothered some by skin inflammation and itching, but there was no certainly recognizable return of the growth until late in that year, or the beginning of 1908. Early in March, 1908, I operated again. I was amazed to find the former site of operation packed with tumor; the growth had extended deep into the orbit, had penetrated the orbital roof, and spread outside along the malar bone, at the orbital edge of which a piece of bone a centimeter or more square had been eaten away, and there were evidences of extension in other directions. The mass in the orbit was, in parts at least, distinctly hard and cartilaginous. There was, of course, nothing to do except to leave matters as they were or attempt a very radical operation. The former was decided on, and Coley's serum was given, with, however, as could be expected, no effect. Before he left the hospital I asked Dr. Francis B. Harrington for advice. He had to depend, naturally, entirely on what I told him, and he, feeling that there was a chance, though a poor one, of success, most kindly took charge of the case, and operated in June, excising the lids, exenterating the orbit, removing a piece of the roof the size of a half-dollar, removing also part of the temporal muscle, and considerable bone about the outer wall of the orbit. The operation was most

thorough and awakened hope. I need not detail the course of events after that. The growth recurred locally, and at the time of his death, a year and a half later, it had spread to the side of the head and into the glands of the neck, compressing the trachea; down over the clavicular region and further up to the other side of the neck. The head on the affected side was double its natural size. The masses sloughed in places, requiring frequent dressings to subdue the foul odors. Deglutition was difficult, and latterly impossible. Brain development was evidenced by attacks of delusion, and at times of almost maniacal outbursts. Pain, up to within a few weeks of the end, was excessive.

One needs but this one experience to know that these mixed tumors can be malignant, not in the sense that they form metastases,—this they do not do unless, as is considered possible, they take on carcinomatous or sarcomatous changes,—but they are malignant in that they increase in size, press on surrounding structures, infiltrate bone, and finally kill. Wood states that many recurrences in the salivary tumors tend to sarcomatous changes, and he mentions two cases in which this took place, and in which purely sarcomatous metastases were formed. I am not aware that analogous cases of the lacrimal tumors have been reported. Imperfect removal hastens the growth. This is not an infrequent experience, for of the five cases reported by Verhoeff, three came later to exenteration of the orbit. Of the other two, one was lost sight of, and time had not been sufficient to judge of recurrence in the other. Death followed exenteration in one. The same is true of the analogous growths of the salivary glands. In Wood's series of 37 cases, in which notes of the condition after operation were at hand, 17, or 45 %, recurred, and 12 of these were checked by further operation.

From my experience I can fully agree with Verhoeff's conclusion that, if the tumor cannot be completely removed

or in case of recurrence, exenteration of the entire orbital contents should be done. There is one difficulty, however, which this advice does not suggest, that is, the inability to tell whether recurrence is actually taking place. In my own case, for example, the tumor probably began to grow rapidly toward the apex of the orbit, and had, I think, invaded the bone to a dangerous extent before exterior signs were certain. I can console myself only by the fact that even up to the time of the second operation such a radical interference as exenteration, though advised, had not been accepted.

PATHOLOGIC REPORT BY F. H. VERHOEFF.

The tumor is roughly ovoid in shape, firm, and measures 21 mm. × 21 mm. × 30 mm. It is surrounded by a thin fibrous capsule, to which more or less orbital tissue is attached. The capsule is apparently intact, except at one place, where the tumor was broken into during its removal. Nothing suggestive of the lacrimal gland can be found in relation with the tumor. On section, the cut surface presents a fairly uniform appearance. The stroma is very slight in amount, or at least does not occur in the form of septa easily visible to the naked eye. The parenchyma is partly translucent, partly opaque, and in places, especially near the periphery, shows a decided yellow color. Here and there a few minute cystic spaces can be seen. No definite cartilage or bone can be made out. There are no interstitial hemorrhages except at the periphery, where they are, no doubt, due to the trauma of the operation.

Histologic Examination.—Fixation in Zenker's fluid. The cells of the parenchyma of the tumor, which forms its greater part, occur chiefly in glandular formations and as solid cell masses. The former sometimes closely resemble the acini and tubules of a normal lacrimal gland, but much more often present atypical appearances. Frequently the acini are surrounded by definite basement membranes of connective tissue and fibroglia. Toward the lumina they show the fenestrated membrane and centrosomes characteristic of glandular epithelium. It sometimes seems

as if an acinus has been formed by the tumor-cells lining the walls of a tissue-space, but such acini, as well as all others, are filled with colloid material staining deeply with eosin and never with serum.

The solid cell masses in the parenchyma are composed of spindle-cells closely resembling those of a sarcoma. They may frequently be traced into continuity with the glandular formations. Careful examination of specially stained specimens also shows within the cell masses minute glandular lumina presenting internally the fenestrated membrane and centrosomes. These are not surrounded by basement membranes, but their columnar cells pass by transition into the spindle-cells, forming the masses in which they lie. Within the cell masses also occur numerous intercellular fibrils of Herxheimer (Mallory's phosphotungstic acid hematoxylin stain). In some places they are so numerous that they call to mind a glioma. Where the spindle-cells pass by transition into the columnar cells of a large glandular acinus, the spiral fibrils are sometimes seen between the second row of cells surrounding the lumen. Apparently they never pass in between the columnar cells immediately around the lumen.

In a few places the cell masses take on the character of epidermis and present prickle-cells and keratohyaline granules. Sometimes epithelial pearls similar to those of an epidermoid carcinoma are met. Mitotic figures are extremely few.

The stroma is relatively slight in amount for this general type of tumor. It is usually fibrous in character, but sometimes hyaline, and occasionally myxomatous. It never takes the form of adult cartilage, but the myxomatous areas sometimes strongly suggest embryonic cartilage. Where the stroma is hyaline, it is often invaded by the cells of the parenchyma, which separate it off into rounded bundles, such as are seen at the periphery of a cylindromatous area. A definite cylindromatous structure is, however, nowhere seen. In some places it is extremely difficult to distinguish stroma cells from those of the parenchyma.

The capsule of the tumor, composed of fibrous connective tissue, is sharply defined. In many places, however, it has been invaded by the parenchyma. This invasion

always takes place by continuity of growth. In fact, the tumor-cells nowhere show a tendency to infiltrate, and they are never found free in lymph-spaces or blood-channels. The capsule is most markedly invaded at the place where it was broken through at operation. The tumor is poorly supplied with blood-vessels, and these often show marked endovasculitis. They are always separated from the parenchyma by connective tissue. The tumor shows no areas of necrosis.

THE RECURRENT GROWTH.

The recurrent tumor presents an appearance distinctly different from that of the primary growth. Here the growth consists of a dense hyaline stroma pervaded with irregular clefts filled with tumor-cells. The latter occur as solid masses and also as isolated cells. The solid masses have shrunken away from the walls of the spaces as in a carcinoma. The cells are in the highest degree atypical. Some are of enormous size, and display great irregularity in shape. They contain unusually well-marked intracellular fibrils and networks, but seldom show prickles or keratohyaline granules. Mitotic figures are extremely abundant. The general appearance presented is similar to that often seen at the advancing margin of an epidermoid carcinoma.

PATHOLOGIC DIAGNOSIS.—Congenital epithelial tumor of lacrimal gland. Recurrence, with great local malignancy.

DISCUSSION.

DR. CHARLES J. KIPP, Newark: I remember operating upon a woman of about fifty years of age who came to me with a large tumor of the lacrimal gland which I thought was completely removed. After eight years there was a relapse from which she died. The pathologic report was fibrosarcoma. This shows that these cases may go on for years without any relapse, as in the case reported by Dr. Holt. I have seen quite a number of sarcomata of the orbit, especially in children, and my experience is not very different from others. In every one of these cases the patient has died. I have tried to completely remove a number and succeeded, as I thought, but in every one the disease returned

with greater virulence and killed the patient in a very short time.

DR. F. H. VERHOEFF, Boston: In speaking of these tumors as tumors of the lacrimal gland, we are apt to overlook the fact that they do not necessarily arise in connection with the lacrimal gland proper. As is well known, glands of the same nature may occur in relation with any part of the conjunctival sac, those in the upper lid, known as the glands of Krause, being the most constant. It is obvious, therefore, that these tumors may arise from any part of the conjunctival sac, or even deep in the orbit, though, of course, they are most frequent where the differentiation into glands is most extensive, that is, in the vicinity of the lacrimal gland proper. They probably seldom arise directly from the adult gland, but from separate anlages formed before the differentiation of the gland is complete. Similar tumors occur not only in connection with the salivary glands, but also with other epithelial structures. Certain tumors of the teeth, adamantinoma, and of the hypophysis cerebri, and even of the breast, are undoubtedly of the same general nature. Since a suitable term embracing this whole group of tumors is apparently lacking, I suggest the term congenital epithelioma, which emphasizes their two important features, namely, their congenital origin and their essentially epithelial nature.

CONGENITAL PIGMENTATION OF THE CORNEA.

T. B. HOLLOWAY, M.D.,
Philadelphia.

While all cases of congenital pigmentation of the cornea are unusual, those cases conforming to the type first reported by Krukenberg in 1899 may be regarded as rare. Since that time several similar case histories have been reported in foreign journals, but to the best of my knowledge the following three histories are the first to be published from American clinics:

CASE I.—M. G., female, single, aged thirty-two, no occupation aside from household duties. The patient first came to the Eye Clinic of the University Hospital November 14, 1906, complaining of constant, dull, aching pain in each eye, aggravated by near work. Her family history was negative, and her own health had always been good except for an attack of intermittent fever eighteen years ago. Her eyes were first examined for glasses eight years ago, when she consulted an oculist concerning the pain above referred to. There was no history of any ocular trauma or other inflammatory processes and no muscæ.

The pupils were equal and round, while the pupillary reactions were prompt and normal; the ocular rotations were full in all directions.

Right eye: With the ophthalmoscope one could note an exceedingly faint, central, vertical linear opacity, and with a suitable lens a faintly granular condition of the streak. When examined by oblique illumination and the naked eye, this streak assumed a brownish tinge, and was about 2.5 mm. in length and 0.5 to 1 mm. in width. With a loupe it was seen to be spindle shaped, and made up of an accumulation of very fine, quite uniform, golden-brown pigment dots, which were situated in the stroma of the cornea in the deeper layers, but their exact depth could not be accurately

determined. About the periphery of the spindle the pigment dots were more isolated than centrally, where they were more compact. The overlying and adjacent portions of the cornea were perfectly clear, and the anterior chamber was of normal depth and free from any remnants of a pupillary membrane. The iris was dark brown in color and normal in every way, while the lids, lens, vitreous, and fundus were likewise normal. $V = \frac{6}{6}$.

Left eye: This was similar in every respect to its fellow, except that the pigment line was slightly more pronounced, and was just external to the center of the cornea. $V = \frac{6}{12}$.

V. R. E. = .25 s. ⊂ + .50 c. axis 30° = $\frac{6}{4}$
V. L. E. = .25 s. ⊂ + 1.25 c. axis 180° = $\frac{6}{5}$

I again examined this patient in July, 1909, and found the ocular conditions unchanged.

CASE II.—B. C., female, single, aged thirty-two; housemaid. Owing to asthenopic symptoms the patient first came to the Eye Clinic of the University Hospital in 1907. Her family history and past medical history were negative. As a child she was subject to styes, but there was no history of any ocular trauma. The first refraction of the patient was ten years ago, and she had been wearing glasses constantly since that time. She has four brothers and two sisters, and but two of these are wearing glasses.

On the nasal side of each cornea a pinguecula could be noted, but there were no evidences of pigmentation of this structure. The pupils were equal, and the iris normal in character and responded freely to light; the ocular excursions were normal.

Right eye: With the ophthalmoscope one could note a vertical, centrally placed, spindle-shaped opacity which presented a faintly granular appearance. With oblique illumination and the loupe the streak was seen to be of a golden-brown color, and the punctate condition was best noted about the periphery of the pigmented area, as in Case I. The opacity measured 3 mm. in length and 1 mm. in width, and was slightly more pronounced than in the above case. The pigmentation was observed to be in the deeper layers of the stroma of the cornea, but here also it was difficult to determine its exact depth. The other por-

Congenital Pigmentation of the Cornea

tions of the cornea were perfectly clear; the anterior chamber was of normal depth, and no visible remains of the pupillary membrane could be seen. The iris was blue-gray in color, and, as above intimated, free from any synechiæ. The lids, lens, vitreous, and fundus were normal. $V = \frac{6}{9}$.

Left eye: This presented conditions similar to those found in the right eye. $V = \frac{6}{7.5}$.

V. R. E. — 1 s. ⊂ — .50 c. axis 120 = $\frac{6}{6}$.
V. L. E. — 1.25 s. ⊂ — .25 c. axis 60 = $\frac{6}{6}$.

Since the above examination this patient has been examined a number of times, and as recently as one month ago, and no change has been noted from the conditions as described. (See colored sketch.)

CASE III.—P. L., female, single, aged forty. This patient first consulted Dr. G. E. de Schweinitz in February, 1901. She stated that she had always been myopic, and had worn glasses for the past twenty-five years. Her past medical history and family history were negative. She denied any previous ocular inflammations or trauma.

Right eye: Here, as in the two preceding cases, there was noted in the stroma of the cornea a brownish, linear area which, upon careful examination, was seen to be finely granular. Its position was just to the inner side of the center of the cornea and vertical in direction. The remaining portions of the cornea were perfectly normal. The pupillary reactions were prompt, and no abnormalities were noted in the anterior chamber, iris, lens, vitreous, or fundus. $V = \frac{6}{22}$.

Left eye: Similar in all respects to the right eye. $V = \frac{6}{45}$.

V. R. E. — 3.50 s. ⊂ — 1 c. axis 165 = $\frac{6}{6}$.
V. L. E. — 5. s. ⊂ — 1.50 c. axis 15 = $\frac{6}{5}$.

This patient was again seen by Dr. de Schweinitz in 1905 and in June, 1909. It was upon this last visit that I had the privilege of seeing her, and was told by Dr. de Schweinitz that the condition had remained unchanged. The stripe measured 3 by 1 mm., and the pigmentation was slightly diffused along the lateral borders, and more concentrated centrally. As in Case II, the iris was blue-gray in color.

Krukenberg* reported his first observation of this condi-

* Klin. Monatsbl. f. Augenheilk., vol. xxxvii, 1899, S. 254.

tion in 1899, and this was followed a few months later by two similar observations.* In 1901 Stock† reported a similar case, and in 1903 Thomson and Ballantyne,‡ a like observation, which was followed in 1906 by a further case by Kraemer.§ If we analyze the three case histories cited by the writer and the six histories previously reported and above mentioned, it will be found that in all the cases the pigmented area was bilateral, central in position, and occupied the deeper layers of the cornea, in contradistinction to some forms of acquired and congenital pigmentations of this structure that are superficial in type. In all cases the pigmented area was granular and the granules brown in color, although several of the reporters have seen fit to use qualifying terms. Thus, Stock referred to the color as reddish-brown; Thomson and Ballantyne have described the dots as chocolate-colored; and the writer has used the term golden-brown, and in doing so refers to the appearance of the more isolated peripheral dots, as seen by oblique illumination. In all the cases the lesions were practically symmetric, although in Stock's case the position of the spindle in the left eye was very slightly more external than in the right eye, and the same was true in Case I, reported by the writer. With the exception of the case reported by Thomson and Ballantyne, who describe the lower portion of the streak as spread out like the tail of a comet, all the pigmented areas were referred to as oval or spindle shaped. Kraemer's case, in which the spindle was horizontal, was the only one that failed to show a vertical direction, and likewise the only one in which a haze was noted about the granules. Two of the cases had associated congenital defects. Thus, Krukenberg's third case had a congenital cupping of the discs, while a partial coloboma of each disc

* Ibid., S. 478.

† Ibid., vol. xxxix, 1901, 2, S. 770.

‡ Trans. Ophth. Soc. U. K., vol. xxiii, 1903, p. 274.

§ Annals of Ophthalmology, vol. xv, 1906, p. 390.

was present in the case examined by Thomson and Ballantyne. Two of the cases were associated with acquired conditions: Stock reports that his patient had incipient cataracts, vitreous opacities, and extensive myopic fundus changes, while the right disc was pale and the field was contracted on the nasal side. Kraemer's case had bilateral optic atrophy, with contraction of the fields for form and colors, for which no cause could be determined.

The size of the pigmented areas varied but slightly, the smallest mentioned being 2.5 by 1 mm. (Holloway), and the largest 4.5 by 3.5 mm. (Krukenberg). The exact size was not mentioned in Krukenberg's second case, or in those reported by Kraemer and Thomson and Ballantyne.

In view of the possible origin of the pigmented area, the color of the iris is of some interest. The first 4 cases reported (Krukenberg, 3, Stock) all had brown irides, while in 4 of the remaining cases (Thomson and Ballantyne, Kraemer, Holloway, 2 and 3) the irides were of lighter color. Thomson and Ballantyne state that the irides were light colored throughout. Kraemer described this membrane as having a dark steel-gray color, while in the writer's cases the first had dark-brown irides and dark-brown hair, the second blue-gray irides and sandy red hair, while in the third case this structure was also blue-gray in color, while the hair was auburn. It is thus seen that this pigmentation has been associated with the lighter shades about as frequently as it has with the darker shades of irides.

Finally, it seems well worth while to call attention to the refraction in these cases. Of the 9 cases above referred to, 2 (Krukenberg, 1, Stock) had high degrees of myopia, 2 (Krukenberg, 3, Holloway, 3) were moderately myopic, 2 (Krukenberg, 2, Holloway, 2) had a low myopic error, while in 1 (Thomson and Ballantyne) the refraction was stated to be myopic, but the amount was not mentioned. In Kraemer's case there existed a hyperopic astigmatism,

while in the writer's first case the refractive error was approximately of the same character. In none of the cases was there a moderate amount of hyperopia, and in the 9 eyes in which an astigmatism existed the axis was oblique in all but one eye. The vision obtained in these cases seems to be as good as one would expect to obtain in similar eyes without the pigmentation. After refraction all of the writer's cases had $\frac{6}{6}$ or better, and none of them was aware of the existence of the lesion until it was commented on by the examiner.

As to sex, 7 of the patients were females and 2 were males. Five of the patients were between twenty-two and forty-five years of age, 2 were over sixty, while the remaining 2 patients were adults, but the ages were not stated.

Since the first case of this type was reported all the observers have regarded the condition as congenital. The history, position, and general characteristics of this pigmentation would exclude the possibility of an acquired condition, such as might follow the accidental application of certain chemicals or drugs or the staining from foreign bodies. So, too, could be excluded the possibility of any acquired inflammation of this structure after birth, or a pigmentation resulting from pathologic processes elsewhere in the eye. Finally, in the absence of any lenticular changes, the pigmentation recently described by Goldberg as occurring on the posterior corneal surface can also be eliminated. Thomson and Ballantyne, in the report of their case, based their opinion of the congenital character of the lesion upon the following conditions: (1) The symmetry was perfect; (2) the dots were all of the same size; (3) the dots were interstitial and not on the posterior surface of the cornea; (4) there were no indications of former inflammations; (5) the eyes were myopic and presented a congenital anomaly of the discs.

This summary, with certain modifications already re-

ferred to in the above analyses, is applicable to all the cases as a type, but it may be added that in the cases observed by the writer there was some variation in the size of the dots, and still further, Krukenberg and Stock were inclined to regard the pigmentation as occurring on the posterior corneal surface.

Up to the present time no definite and certain cause for the pigmentation has been determined. Krukenberg suggested the possibility that uveal pigment passed over into the corneal tissue at that time of fetal life when the pupillary membrane lies in close proximity to the cornea, but stated that it was difficult to explain that after the separation of these structures no trace of a pupillary membrane remained. At this point it may be well to refer to the early development of the cornea.

Kollicker* and Hertwig† state that after the closing off of the lens vesicle the thin layer of mesodermal tissue separating it from the corneal extoderm quickly thickens, and subsequently divides into two layers: the external one develops into the cornea proper, and the inner layer becomes the so-called pupillary membrane. It will be recalled that the more peripheral portion of the latter structure subsequently develops into the stroma of the iris. As the result of this cleavage of the mesodermal tissue the anterior chamber is formed. Parsons,‡ in citing Jeannulatos, states that this cleavage begins as early as the sixth week. Lange§ states that pigment-granules are already present in the anterior part of the proximal layer of the optic vesicle at the end of the fourth week.

Krukenberg felt that the similarity in color between the pigmented area and the iris stroma would tend to show some

* Entwicklungs-Geschichte des Menschen.

† Lehrbuch der Entwicklungs-Geschichte, 1906.

‡ Pathology of the Eye, vol. iii, p. 904.

§ Einblick in die embryonale Anatomie und Entwicklung des Menschenauges, 1908.

connection between the lesion and the anterior uveal tract, but offered no explanation for the vertical position of the spindle. Stock, while he accepted Krukenberg's suggestion as to the mode of origin, regarded the pigmentation as only an interesting anomaly, and in support of this cited the history of a forty-year-old woman, with high myopia and gray irides, whose eyes revealed gray spots on the anterior capsule of each lens and a gray, spindle-shaped opacity in the deeper layer of the cornea, which, under oblique illumination, was seen to be made up of fine dots.

Thomson and Ballantyne regarded the etiology as obscure, but stated that, owing to the similarity of the cases, the underlying cause was a definite and constant one. Kramer fully accepted Krukenberg's suggestion, and thought it satisfactorily explained the condition, and further stated that, with the assumption of a firm union between the membranes, which could take place in any direction, the variable position of the spindle (in his case horizontal) could be explained.

Wüstefeld,* in referring to cases of this type, thought it possible that the separation of the pupillary membrane had been completely consummated, only leaving behind the pigment remains, and cited as a probable example of this his case of persistent pupillary membrane with adherence to the cornea, which showed a fine, curved, brownish pigmented line situated between and separated from the two pigment dots in the cornea, to which were attached the fibers proceeding to the iris.

Brückner, in his admirable and classic article on the pupillary membrane, states that if we think of the connection of the fibers with the posterior corneal surface (*i. e.*, persistent pupillary membrane with adherence to the cornea) as broken and the fibers additionally absorbed, we have

* Zeitschr. f. Augenheilk., vol. iv, 1900, S. 590.

remaining the condition, such as Krukenberg describes as melanosis of the cornea.

Parsons believes this anomaly is due to intra-uterine inflammation, with transference of uveal pigment to the cornea.

This brings us to the interesting group of cases described as persistent pupillary membrane with adherence to the cornea. It will be remembered that two theories have been advanced in explanation of this condition, one of these being based upon an imperfect differentiation of the mesoblast, while the second attributes the condition to some form of keratitis, with or without perforation of the cornea. As to the latter theory, it is needless to say that in those cases where a purulent conjunctivitis had existed in early infancy the etiology of the adherence has prompted less discussion than those attributed to intra-uterine inflammation. It is not my intention to enter into this discussion, but it may be well to refer to some data obtained from the reports of some 23 cases,* taken from the literature on this subject, including the case observed in a cat and reported by Collins.

The cases so far reported have been differently classified according to the views of the various authors contributing to the literature of this subject, especially the congenital cases. The cases that have been classified as due to defective development have been those of Makrocki,† Vossius (2),‡ Collins,§ Wüstefeld (2),|| Rumschewitsch,¶ Schoute,**

* The cases of Silcox (Trans. Ophth. Soc. U. K., xv, 1895, p. 193) and Grimsdale, cited by Ballantyne, have not been reported in detail and are not included.

† Arch. f. Augenheilk., vol. xiv, 1884–85, S. 83.

‡ Deutschmann's Beiträge, vol. i, S. 717.

§ Lancet, vol. ii, 1894, p. 1463.

|| Zeitschr. f. Augenheilk., vol. iv, 1900, S. 599.

¶ Archives of Ophthalmology, vol. xxxvii, 1908, p. 595, translated by M. L. Foster, Arch. f. Augenheilk., vol. xlvi.

** Zeitschr. f. Augenheilk., vol. iii, 1900, S. 230.

zur Nedden,* Polte,† von Hippel, ‡and Collins'§ case, that occurred in a cat.

Those classified as most likely due to inflammatory processes have been the cases of Beck, cited by Arlt,|| Samelson,¶ Wintersteiner (4),** Gesang,†† Zirm,‡‡ Schapringer,§§ van Duyse,|| || and Ballantyne.¶¶

Of these cases, those reported by van Duyse, Wintersteiner, Gesang, and Polte all gave a history of a purulent conjunctivitis within a few days after birth. In Samelson's case a history of a severe ocular inflammation at the age of one month was elicited, while Arlt, in citing Beck's case, thought the condition was due to a perforation of the cornea, as accurate inquiry made it probable that the patient had had an ophthalmia neonatorum; Beck himself mistook the pupillary membrane for a vessel. The case reported by Ballantyne was a seven- to eight-months-old fetus whose eyes were studied microscopically, and probably in a thoroughly literal sense should not be included here as a persistent pupillary membrane. This observer thinks Collins' case could also be best explained by the inflammatory theory, and intimates a similar possibility in several other cases usually regarded as due to faulty development.

Von Hippel, in Graefe-Saemisch Handbuch, 1900, stated that he believed all these cases were dependent upon a

* Klin. Monatsbl. f. Augenheilk., vol. xli, 2, S. 342.

† Arch. f. Augenheilk., vol. xlviii, 1903, S. 80.

‡ Arch. f. Ophth., vol. lx, 1905, S. 444.

§ Trans. Ophth. Soc. U. K., vol. xxvii, 1907, p. 203.

|| Die Krankheiten des Auges, i, S. 235.

¶ Centralbl. f. prakt. Augenheilk., 1880, S. 215.

** Wien. klin. Wochenschr., vol. vi, 1893, S. 508; Arch. f. Ophth., lvii, 1903, S. 53.

†† Deutschmann's Beiträge, 1904, S. 42.

‡‡ Klin. Monatsbl. f. Augenheilk., vol. xxviii, 1890, S. 288.

§§ New Yorker med. Monatsschr., vol. xii, 1900, S. 591.

|||| Annales d'Oculistique, vol. xcv, 1886, p. 24.

¶¶ Trans. Ophth. Soc. U. K., vol. xxv, 1905, p. 319.

keratitis, either intra-uterine or post-fetal, and in 1901* published the case history of an infant six days old whose right cornea showed a parenchymatous opacity with a dull surface, but without loss of substance. The anterior chamber was shallow, and the anterior synechia extended from the pupillary margin to the posterior surface of the corneal opacity. Fluorescin produced a distinct discoloration of the affected corneal area. Two months later the corneal surface was smooth, and the anterior synechia had disappeared. Associated with the conditions above mentioned there existed bilateral symmetrical colobomata of the choroid. The author pointed out the possibility of mistaking such a case, if seen at an appropriate time, for one due to a congenital defect. The infant had symptoms suggesting hereditary syphilis.

Schweigger,† however, was probably the first to point out the possibility of the development of an anterior synechia in interstitial keratitis, and without perforation of the cornea, due to swelling of the iris and narrowing of the anterior chamber. Later, in 1905, von Hippel‡ published the history of a case with microscopic examination in which he concluded that the condition was dependent upon a defective separation of the mesodermal layer. This case had numerous other congenital defects, such as bilateral microphthalmos, irideremia, cataract, hairlip, cleft-palate, polydactylism, and defective skull formation. While he stated that an internal ulcer of the cornea could not be definitely excluded, he thought such an explanation highly improbable, in view of the absence of other inflammatory features, and in the presence of the associated anomalies.

Taking this group of cases as a whole, we find, as would be expected, that the majority of the cases came under

* Arch. f. Ophth., vol. lii, 1901, S. 473.
† Arch. f. Augenheilk., vol. xvii, 1886–87, S. 403.
‡ Arch. f. Ophth., vol. lx, 1905, S. 444.

observation in infancy or childhood. Only six were over nineteen years of age, the oldest being the case reported by zur Nedden, who was fifty-seven, and the next oldest case being Wüstefeld's patient, who was thirty-six years of age. Ballantyne's case was a fetus, while von Hippel's patient was but three days old, and an ocular examination prior to death could not be made. Half of the cases had anterior lenticular opacities, while a fewer number had associated congenital ocular defects, notably, the cases of von Hippel, Schapringer, Polte, and Collins. About one-third of the cases had nystagmus, and this condition was associated with allied movements of the head in the case reported by Samelson; while in the four cases cited by van Duyse, Wintersteiner (2), and Makrocki strabismus coexisted.

The fibers varied in number from 1 to 20, and in the majority of the cases were pigmented. The course of these fibers was from the corneal opacity to the minor circle of the iris. In the cases of Zirm and zur Nedden, the fibers contained dark pigment, while the iris was of light color, and in Gesang's case there were pigment dots on the cornea, although the fibers were stated to be of the same color as the iris, which was blue-gray. Zirm's case, aside from the attached fibers, had four fibers projecting from the iris that terminated in free points in the anterior chamber, while Gesang's patient had one free-ending fiber projecting from the cornea, aside from several attached filaments. These cases suggest a condition reported by Brückner,* which he regards as an intermediate stage between persistent pupillary membrane with adherence to the cornea and the type of pigmentation of the cornea described by Krukenberg. In this case a pigmented fiber projected from the iris, and floated freely in the anterior chamber upon movements of the globe. Centrally, on the posterior surface of the cornea, were two small pigment dots, and from one of

* Arch. f. Augenheilk., vol. lvi, 1907, S. 5.

these a delicate gray fiber could be traced to the corneal border. The reporter thought that at an earlier period the pigmented fiber had been connected with the cornea. In this case there was no history of any preceding ocular inflammation.

Perhaps the most interesting feature is the pigmentation of the cornea that existed in some of these cases. The histories published by van Duyse, Vossius, Wintersteiner, Wüstefeld, zur Nedden, Gesang, Polte, and Collins, as well as the case of Brückner, just referred to, all revealed some pigmentation of the cornea, which was usually in the form of a few discrete dots, or in small, irregular patches. The pigmentation in Collins' case was described as irregularly circular in form, while in Wüstefeld's case there was a pigment stripe along the under border of the corneal opacity. However, in none of these cases, whether the origin was attributed to defective development or to the results of inflammation, was the pigmentation analogous to that seen in the cases observed by the writer.

Four of the cases of pupillary membrane with adherence to the cornea above cited have been examined microscopically—those of Wintersteiner, Collins, von Hippel, and Ballantyne; to these may be added Collins' case that occurred in a cat.

In conclusion I can only state that I have no new theory to present to account for the origin of the pigmented spindle in the three cases above reported, but believe that microscopic studies will be necessary to throw additional light on the obscure etiology of this condition.

Finally, I desire to express my appreciation of the courtesy extended by Dr. G. E. de Schweinitz for the privilege of reporting these cases, and especially for his generosity in placing at my disposal the clinical data of the third case.

REPORT OF A CASE OF EPIBULBAR SARCOMA.

C. A. VEASEY, A.M., M.D.,
Spokane, Wash.

At the meeting of this society three years ago I reported a case of primary melanotic sarcoma of the corneal limbus in a male aged forty-seven years. In my paper I reviewed some of the previously recorded cases, and discussed the question as to whether it is better to attempt removal by abscission or to resort to immediate enucleation. To quote from that paper, I said: "That some of the tumors grow slowly, that there is but little tendency to involve the sclera or deeper layers of the cornea, that when they recur they usually recur locally, that there is but little tendency to extend by metastasis—are offered by some surgeons as reasons for an attempt at removal by abscission. On the other hand, as some cases do grow rapidly and involve the deeper layers of the cornea and sclera, even to perforation, as very many cases repeatedly recur, sometimes recurring at distant points, and finally have to be enucleated, as there are occasional metastases to other portions of the body, the patients' lives being lost, it is urged by other surgeons that enucleation should be advised as soon as the diagnosis is made." The conclusions reached were that, "unless the growth be seen at a very early stage, when it is yet small and not firmly adherent, this (enucleation) seems to the writer the safest and best advice that can be offered the patient." Bearing on this question, the following report is of some interest.

Mrs. H., a married woman with healthy children, aged forty years, was seen first in November, 1908. The family history was bad. An aunt, her mother's twin sister, had

died of cancer of the breast at about forty years of age. An uncle on the maternal side had one eye removed for a condition said to have been cancer, though he was still living, aged about eighty years.

The health of the patient herself had always been fairly good. Though not robust in appearance, she was by no means delicate. At ten years of age she had stuck the point of a slate-pencil through the ciliary region of the right eye, 3 mm. to the temporal side of the corneoscleral junction. Since this accident a dark spot was always observable at the point of injury. About six years before my examination,—twenty-four years after the injury,—a small growth was discovered developing on the site. It grew very slowly, was dark in color, and at the time of first consulting an ophthalmic surgeon, two years later, was about the size of a small green-pea. It was removed under cocain anesthesia. Eight months later a recurrence was observed. Again it grew slowly, and, one and one-half years after the first operation, was again removed. The second operation was performed by another ophthalmic surgeon under ether anesthesia.

After a period of two months, during which the eye remained quiet, recurrence was again noted. The growth was now somewhat more rapid than before, and a third operation for removal was performed by the second surgeon eight months after the preceding operation had been performed.

Six months after the third removal the growth recurred, and five months later the patient was seen by me for the first time. Her general appearance was good. On the right eye, extending outward from a point 2 mm. from the corneoscleral junction, was a dark colored growth, apparently firmly attached by a broad base to the underlying sclera. The conjunctiva was freely mobile over the growth, the latter being about 12 mm. x 9 mm. in size and elevated from the sclera about 6 mm. The vision of the eye was normal, and so far as could be determined by ophthalmoscopic examination through a dilated pupil, the interior of the eyeball was not involved.

No microscopic examination of the growth having been made at any time, though three operations had been performed for its removal, it was thought best to excise a portion for such examination, and if it were found advisable at the time of such excision, to attempt the removal of the whole growth. Under ether anesthesia it was found that the tumor separated readily from the sclera at all portions excepting at the point of early injury. Here it seemed to be firmly adherent. It was excised, and there seemed to be a small scleral opening, less than 1 mm. in diameter, through which the dark uvea was visible. This was apparently the dark spot to which the patient referred as having been present since the accident from the slate-pencil at ten years of age. The whole area of the sclera that had been covered by the growth, and especially the site of the early injury, which seemed to be the point of origin, were thoroughly cauterized with the actual cautery. The specimen was hardened in formalin and sent to Dr. E. A. Shumway, of Philadelphia, for examination. Dr. Shumway submitted the following report:

PATHOLOGIC REPORT.

The growth consisted of a soft, irregular mass, measuring approximately 10 x 6 x 8 mm., which contained several firmer nodules. One of the nodules was removed and embedded in paraffin, and the remainder of the tissue was embedded in celloidin. Sections of the various portions show that it is composed of three different kinds of tissue:

1. A narrow portion, composed of fibrous tissue, with a few nuclei, which has the appearance of scleral tissue, and is probably a portion of sclera excised with the growth. In one place it shows an infiltration, with the same cellular elements described in the nodules below.

2. Small nodules, varying in size, but averaging on section 2.5 x 4.5 mm. These are composed of densely massed, small round and spindle-shaped cells, with deeply staining nuclei, which occupy almost the entire cell-bodies. There

is a small amount of homogeneous intercellular matrix, and a number of small capillary vessels, running in the nodules, the walls of which are composed of a single layer of endothelial cells. There is no pigment, except a small amount of light yellow blood-pigment, evidently the remains of an old hemorrhage. The structure is a typical small round-cell and spindle-cell sarcoma. As stated before, some of the sarcoma cells have invaded the scleral tissue.

3. Surrounding the nodules is a very loose meshed, edematous tissue, which is infiltrated with polymorphonuclear and mononuclear cells. This portion is apparently inflammatory tissue produced by the irritation caused by the presence of the growth.

Diagnosis.—The important parts of the growth are the nodules; their structure is that of *mixed small round and spindle-cell sarcoma.*

The above report having been received, immediate enucleation of the eyeball was advised. Inasmuch, however, as normal vision was preserved and the eyeball looked so well and quiet since the last (fourth) operation, the patient decided to take the chance of metastasis and await developments. In less than three months there was a suspicious spot at the site of the penetrating wound, where all former recurrences had been first observed, and in another month recurrence was positive. Immediate enucleation was then performed, and to date, a period of sixteen months, there has been no local recurrence nor have there been any symptoms indicating metastatic involvement.

The chief points of interest in this report are:

1. The appearance of an epibulbar sarcoma in a woman aged forty at the site of a penetrating injury from a slate-pencil received twenty-four years before.

2. The removal, by excision, upon four different occasions, each time followed by recurrence.

3. Enucleation six years after the first appearance of the growth, and no symptoms of recurrence, either local or metastatic, after a period of sixteen months.

DISCUSSION.

DR. G. E. DE SCHWEINITZ, Philadelphia: Dr. de Schweinitz, discussing Dr. Veasey's interesting paper, referred to two cases of his own and illustrated his remarks with glycerin-jelly preparations: the one an epibulbar sarcoma, which had been removed on several different occasions before it came under his and Dr. Sweet's care. All such removals had been followed by recurrence, and at the time that he enucleated the eyeball there were several sarcomatous nodules in the neck. The subsequent history of this patient he was not acquainted with, but thought that probably Dr. Sweet knew more of her ultimate history than he did. The other patient, a woman aged thirty-eight, from whose eye he had removed a densely pigmented epibulbar sarcoma, suffered a recurrence at the expiration of a few months, when, with the help of Dr. Veasey, he had removed the entire eyeball, and up to the present time there had been no sign of recurrence or metastasis, nine years having elapsed since the operation. Pathologically, the growth was a small-celled sarcoma, and microscopic examination indicated, as had been shown to be the case in other epibulbar sarcomata, that it seemed to develop from a collection of pigmented cells on the conjunctiva, and in this, as in some other similar sarcomata, a nevoid spot may have been the starting-point of its growth.

DR. WILLIAM M. SWEET: The woman alluded to by Dr. de Schweinitz died about a year after the operation. Her physician advised me that there had been no recurrence of the growth in the orbit.

DR. F. H. VERHOEFF, Boston: In the text-books it is commonly stated that epibulbar sarcomata often arise from nevi. I am much inclined to doubt this. During the past ten years I have had occasion to examine a large number of epibulbar tumors, and not one of them showed the typical structure of a nevus. Now, if epibulbar sarcomata arise from nevi, the nevi ought to be more frequent than the sarcomata. Certainly this is so in the case of nevi of the skin. If the tumor in Dr. de Schweinitz's case was a nevus, we can readily understand why it did not recur.

CYLINDROMA OF THE ORBIT.

J. HERBERT CLAIBORNE, M.D., AND E. L. OATMAN, M.D.,
New York.

On February 10, 1910, Mrs. B. O. presented herself at Cornell Clinic for treatment. She gave the following history: Age, forty-six; six children—four living and two dead. One child died of enlargement of the heart at eight years; the other, subsequent to a fall, from a condition not well described. Husband well. One miscarriage at the age of thirty-nine at the third month. Mother and father both died of heart trouble; had a brother and sister, both of whom are living. She has had headaches all her life. Two years ago she noticed that her left eye was getting lower than the right. At the same time her headaches became worse.

Status Præsens.—Badly nourished woman, pale, intellectual perceptions dull. Hand grip equal on both sides and good. No difference in sensations on either side—face or limbs. Gait is good; no Romberg; knee-jerks on both sides intensely exaggerated. No Babinski symptoms; tongue well projected. Arteries soft; heart-sounds normal. No sickness in her life except nineteen years ago, after the birth of one of her children, she had a sore knee, which the doctor said was erysipelas, but from her statements it would seem there was some kind of swelling on her knee which discharged for several months and then healed.

Condition of Eyes.—Eyes not on the same plane. Left eye displaced downward—about 13 mm. lower than the right. Excursions of left eyeball normal except upward, which is considerably modified. There is marked ptosis, and eye is divergent. The media are clear, and there is no fundus change, unless possibly a slight blurring of the disc. The field is normal; no scotomata; no diplopia; slight anesthesia of cornea. Vision, R. E. = $\frac{20}{30}$, with cyl. +

1 D, axis 75°; L. E. = $\frac{20}{200}$; no improvement. Pupillary reflexes—Left eye: Direct and accommodative, fair, consensual about normal; pupil same size as right; both moderately small. Right eye: Direct and accommodative normal; consensual, modified, as is to be expected.

Underneath the left orbital ridge a tumor can be felt, but not seen. The tumor is about the size, feel, and consistency of a large mulberry; it is apparently attached to some structure immediately under the orbital ridge; is slightly movable, and its lower border stops just short of the eyeball. Its median end starts about the center of the supra-orbital ridge, and the outer end stops a little short of the external canthus. Its length is about 22 mm., and its width, 8 mm. She has no pain in the region of the tumor, and the headache from which she suffers is not localized in this area. The eye runs tears constantly, and has been doing so for about two years, the time when she first noticed anything unusual about it.

It appears then that the headache, the lacrimation, and the displacement of the eye all commenced about the same time—two years ago. The displacement and the lacrimation have kept pace with each other, but the headache, while intermittent, has gradually grown worse and worse. It is remarkable that the field of vision should be so good when the vision is so poor. Iodid of potassium, 30 grains t. i. d., was given; in a week the headache disappeared. This led me to have the Wasserman, Noguchi, and cobra venom tests made. All three proved negative. I advised removal of the tumor.

Operation.—The eyebrow having been shaved, an incision was made through the center of the eyebrow, commencing at a point which corresponds with the supra-orbital notch, in a curvilinear direction, and terminated downward toward the outer canthus. As soon as the first cut was made the tissues were picked up and slit with a scissors. When the soft parts had been divided down to the tumor, the anterior aspect of it presented in the lips of the wound. In a few

moments it could be seen that the lacrimal gland lay upon the tumor and did not constitute a part of it. But the soft parts having been completely cut away throughout the length of the incision, the little finger of the left hand was inserted and thrust backward between the ball and the roof of the orbit, in order to determine the character and extent of the tumor. This, of course, forced the eyeball down strongly, and the tumor was found at its posterior tip, fitting tightly in the apex of the orbit. It was apparently immovable upward, but slightly movable downward and at its tip.

A pair of enucleation scissors were entered alongside of the little finger, and the soft parts were divided toward the apex by introducing the scissors closed and alternately shutting and opening them, in the manner suggested by my assistant, Dr. Eisenberg. In a few moments the tumor became more easily movable, and it was found that the little finger could be slipped between the posterior tip of the tumor and the upper wall of the orbit until it met an obstruction forward. It was then found that the tumor was growing from the under surface of the orbital roof. By working toward this point with scissors and knife the tumor was dissected from the under surface of the orbit and finally made to lie loose in the orbital cavity. I was able to feel the rough surface of an area about the size of the nail of my middle finger, from which the tumor had evidently grown. When the tumor had been completely loosened above, the little finger was again introduced into the wound and slipped downward and inward between the inner wall of the orbit; it seemed to be densely attached to the soft parts, and, I thought at first, to the eyeball itself.

By introducing the enucleation scissors again and working in the manner before described I was able to loosen the tumor still more. A pair of artery forceps was now thrust down between the tumor and the inner orbital wall, and what

appeared to be another root was grasped. By pulling the artery forceps upward the tumor was made to bulge toward the outer side of the wound. Hugging the posterior surface of the eyeball carefully and inclining the scissors toward the tumor, guided by my finger, I was able to detach the mass, which was grasped by the artery forceps. It was only necessary now to cut away the remaining attachments.

The time occupied in removing the entire mass was twenty minutes. The little finger was now pushed again into the orbit, in order to assure myself that there was nothing remaining. I was able to thrust my finger back to the apex, feel the optic nerve, and also the roof of the orbit, to which the tumor had been attached.

As the tumor came away it presented the appearance of a hard, glazed mass, apparently in a tight capsule and somewhat constricted irregularly. On the anterior aspect of the tumor there was a mass which appeared to me to be partly connective tissue, partly fat, and partly lacrimal gland. A piece of fat protruding from the orbit into the wound was cut away.

The wound was thoroughly cleansed with 1 : 3000 bichlorid, and closed with interrupted sutures. A small opening at the outer and inferior point was left for drainage. It healed by first intention in twenty-four hours. There was ptosis, but no swelling of the lid. In fifty-four hours it was observed that the right eyelid of the patient had swelled, likewise the soft parts of the bridge of the nose. The bandage was removed, and the left lid was found to be intensely swollen, more or less edematous, and ecchymotic. The wound was clean and the eye completely shut.

This condition, it is well known, happens within twenty-four hours to three days after most operations upon the orbit. It produced no alarm, as there were no evidences whatever of suppuration. Temperature was normal. Patient was dismissed from the hospital at the end of ten days,

Before operation.

After operation.

with the wound neatly healed, but with the left lid in a condition of complete ptosis. There was anesthesia of outer side of the brow, extending up into the hair, the anatomic limitation of the temporal branches of the supra-orbital nerve.

The skin about the inner side of the supra-orbital notch was sensitive. By starting the incision just a little to the outer side of the supra-orbital notch, and by dissecting the soft parts slowly with the scissors instead of cutting them with a knife, I was able to avoid not only the supra-orbital artery, but likewise the supra-orbital nerve.

When I undertook this operation I anticipated that at least one hour would be necessary to finish it. I was perhaps more surprised than any one else present at the short space of time necessary to remove this tumor.

The photographs here shown represent the appearance of the patient before and after the operation. At this writing the ptosis is still present, but is lifting gradually. The anesthesia of the brow is becoming better. The movements of the eyeball in all directions are perfect, whereas they were much limited upward before the operation. The function of the eye is still $\frac{20}{200}$, the same as before. Pupillary reactions normal.

The following histologic report of the tumor was made by Dr. E. L. Oatman:

"The specimen is an ovoid tumor, 28 mm. in length and 18 mm. in its greatest diameter. Its external surface is fibrous and slightly nodular. The point of attachment to the orbital walls is indicated by a broad, denuded area, measuring 12 x 20 mm.; the cut surface is white, smooth, and firm.

"*Microscopic Examination.*—The unattached portion of the tumor is inclosed in a fibrous connective-tissue capsule. A small section of the normal lacrimal gland is attached to the external surface of the capsule, which entirely separates the gland from the tumor. At this point the capsule and

gland stroma are infiltrated by an old extravasation of blood, evidently of traumatic origin. The neoplasm is an endothelioma, apparently originating in the lymph-channels of the orbital periosteum. It is nearly non-vascular, only a few insignificant blood-cells being demonstrable. Histologically, it is composed of epithelioid cells situated in a stroma of fibrous connective tissue. In a general way, the cells are arranged in strings and columns which, in some areas, present a fenestrated appearance. As a rule, however, the cells which occupied the center of the columns have undergone mucoid, hyaloid, or some analogous degeneration, leaving round, tubular cavities inclosed by cells, which, in cross-sections, present a picture remarkably gland like. The cells immediately around the cavities, being relieved from pressure, appear larger than where closely packed. The tubular spaces contain cylinders of the homogeneous material produced by cellular degeneration. Hence the name, *cylindroma*, has been applied to these growths. In the center of the tumor a few irregular spaces have formed, containing a granular material, probably coagulated fluid. This appearance indicates commencing cystic degeneration. The stroma is undergoing a degenerative process, whereby it is rarefied and converted into a myxomatoid tissue. Weigert's stain shows it to be richly supplied with elastic fibers.

"These growths are not actively malignant, and when once removed, do not recur. If neglected, they may infiltrate and destroy the surrounding tissues, and even cause death through metastases. In most cases rapid degenerative changes result in the formation of a gelatinous cyst, which exhibits little or none of the original tumor structure. Diagnosis, cylindroma orbita (endothelioma)."

In concluding the description of this case I desire to submit a few remarks in regard to the best method of operating upon tumors of the orbit.

As a rule, we operate for these tumors through the region of the brow, more or less in the manner I have described. Incision is made by some through the brow itself, by others

Fig. 1.—Cylindroma of orbit. Showing arrangement of endothelial cells in a stroma of fibrous connective tissue. Strings of massed cells are seen cut both longitudinally and transversely. The picture as a whole closely resembles that of adenoma. Van Giesen's stain, Leitz 3, Oc. ii

Fig. 2.—Showing two cellular columns cut transversely. In one the central cells have been converted into a homogeneous material In the other the cells remain intact At this point the stroma has undergone myxomatoid degeneration. Dark lines in the stroma are elastic tissue fibers. Weigert's elastic tissue stain and carmin. Leitz, 6, Oc. iv.

just beneath the brow. The length and position of the incision seem to vary at times according to the location of the tumor.

Some surgeons, however, prefer the so-called Krönlein operation for the removal of deep-seated tumors, particularly those which grow from or are attached to the optic nerve. In 1886 Wagner suggested an operation which has subsequently borne the name of Krönlein. In 1887 Krönlein published a report of the removal of a dumb-bell-shaped dermoid cyst of the orbit by the method suggested by Wagner.

This operation was suggested by Wagner, and performed by Krönlein, under the assumption that, by removing the outer wall of the orbit, tumors in this region may be more easily manipulated and removed.

My own experience comprises two cases: one in which the tumor was situated 6 or 7 mm. back of the supra-orbital ridge, and to the outer side. It was removed with considerable hemorrhage and difficulty by an incision through the brow. The other is the case herein described.

I have never done the Krönlein operation, but, from my experience, I am inclined to think it is an unnecessary one. In a skull which I have in my possession the frontal sinus extends from the median line outward 30 to 32 mm., and, as it approaches its termination toward the temple, the depth of the cavity becomes narrower and narrower. Those measurements will bring the termination of the frontal sinus to a point which corresponds to, or is 4 or 5 mm. beyond, the orbital notch. It would, therefore, be quite possible to remove a portion of the orbit which lies between this point and the temporal suture of the orbital wall without opening the sinus or entering the cerebral cavity. In the skull to which I have referred I have outlined with ink a semilunar area 20 mm. in length, and about 5 to 7 mm. in width (Fig. 3). By cutting down on the edge of

the orbit and carefully reflecting the periosteum, it will be possible to remove the bone and leave the periosteum. If the periosteal wound be stitched together, post-operative formation of bone might be achieved.

Just at the points suggested by Wagner and Krönlein for the removal of the orbital walls the wall of the orbit inclines inward and is almost flush with the edge; whereas in the region I have described, there is between 10 and 15

Showing portion of outer wall of supra-orbital ridge to be removed.

mm. of depth from the edge of the orbit to the point where the wall passes into the roof. It is this overhanging brow, rather than the outer wall of the orbit, which interferes with manipulation in the depth of the orbit. I suggest, therefore, in substitution for the Wagner and Krönlein operation, that an elliptic piece of bone, approximately of the size mentioned, be removed subperiosteally from the region outlined. Whatever deformity might follow this

operation, it is quite clear it could be no worse than that following the Krönlein procedure. Moreover, the orbit is attacked at a point which lies half-way between the superior and the external rectus muscle; consequently the possibility of restriction of muscular movements afterward is not so great as in the Krönlein operation, which is frequently followed by restriction of the movements of the eyeball outward.

The Krönlein operation involves cutting through a very thick portion of bone below, where the orbital pillar rises from the zygoma; likewise, it is necessary to cut through a considerable thickness of bone above. It is simply impossible to return this flap and make it coapt accurately with the opposing bony surfaces. This is largely the reason for the deformity which exists after the operation.

It is true that, in the method which I suggest, the bone is completely sacrificed, but I believe if the periosteum is properly reflected and sewed up, new bone will be formed.

It is well known that, in all operations for orbital tumors in which incision is made through or beneath the brow and the levator palpebræ superioris is cut, there is more or less ptosis afterward. The ptosis in the case which I have described was very great. Nevertheless, the eyelid is lifting. This is usually the case. I believe, however, that we can improve our technic in this matter by stitching together, as nearly as possible, the cut ends of the levator palpebræ superioris by subcutaneous sutures of catgut, and I suggest that procedure in all operations in which incision is made through the brow.

The tumor which was removed in this case was 28 mm. in length and 18 mm. in its greatest diameter. The orbit in the skull which I have in my possession is 40 mm. long; therefore there were but 12 mm. of space unoccupied by the tumor. By following with my little finger I was able to determine the fact that the tumor grew from the roof of

the orbit and commenced at a point where the vertical wall emerges into the flat roof. That was about 10 mm. from the edge of the supra-orbital ridge. Therefore, this tumor was jammed in the very apex of the orbit. When I demonstrated this case before the Section of the New York Academy of Medicine, several surgeons suggested the operation through the brow, and another one expressed the opinion that it was a typical case for the Krönlein operation.

It is obvious that the Krönlein operation was unnecessary in this case, and the ease with which this tumor was removed has led me to form the opinion which I have herein expressed.

As shown by the skiagraph, the orbit on the left side was larger than the orbit on the right, though the difference was very slight; this fact may have assisted me somewhat in removing the tumor so easily and so quickly. I believe that, in the great majority of cases, if the brow incision is made and carried from the inner to the outer canthus, most tumors, however deep seated, may be removed. If, however, any difficulty is experienced, I think the suggestion which I have made here in regard to removing the outer third of the supra-orbital ridge, if followed, will surely result in success. This procedure is peculiarly applicable for tumors which appear to grow from the upper and outer wall of the orbit, or from the optic nerve on its outer side or near the apex.

TUMOR OF THE ADRENAL GLAND WITH METASTASIS IN THE ORBIT.

ALEX. QUACKENBOSS, M.D.,

Boston, Mass.

(PATHOLOGIC EXAMINATION BY F. H. VERHOEFF, M.D., BOSTON.)

During the past three years two cases of tumor of the adrenal gland with metastasis in and about the orbit have come under my care at the Massachusetts Charitable Eye and Ear Infirmary. The first case, a male infant, aged sixteen months, was seen in September, 1906, and was reported in the American Journal of the Medical Sciences, June, 1908, by Drs. Tileston and Wolbach.

The second case, and the one which I wish to report, is that of a little boy, three years of age, of French-Canadian parentage. He was brought to the Infirmary in November, 1909, with the story that, about one month before, the lids of the left eye became discolored and the eyeball prominent. There was no history of injury, and so far as we were able to make out from the parents, the child had always been well.

The upper and lower lids of the left eye are discolored and have the appearance of an ordinary hemorrhage into the lids, there is moderate exophthalmos, the eye being pushed forward and upward. Motion is somewhat limited. The pupil reacts, the vision is apparently good, and the fundus is normal. In the lower outer part of the orbit a distinct tumor is felt, which seems to be adherent to the bone, and just below a round bony growth is made out, as if the antrum was involved. The right eye is normal.

Dr. Tileston kindly looked the case over and made the

following report: In the right side of the abdomen is a large mass reaching from the margin of the ribs to 2 cm. below the navel, and from the extreme flank to the median line. The mass in places is quite hard and nodular. Toward the median line the mass is indurated. The spleen is not enlarged. The heart and lungs are negative. The testes are normal. The preauricular glands are not involved; the glands of the neck are enlarged to about the size of a large pea; both anterior and posterior triangles are involved. The glands are more numerous on the left side. The glands in the axilla and groin are slightly enlarged. The reflexes are normal.

To establish the diagnosis a piece of tissue was removed from the orbit, and at the same time Dr. F. L. Jack removed portions of the growth from the antrum.

This case belongs clinically to that class of adrenal tumors in children in which there is metastasis to the skull—the so-called Hutchison type. The symptoms which are usually found only in infants and young children are very characteristic. Ecchymosis of the eyelids, accompanied by exophthalmos, suddenly appears; it may be followed by growths about the orbit. It is usually confined to one side. The glands throughout the body are apt to be enlarged. Examination of the abdomen may reveal a tumor in the region of the kidney, or a mass may be felt in other parts of the abdomen. The blood shows secondary anemia. The urine is usually free from blood and albumin. Most of the reported cases have been under four years of age. The course of the disease is rapid, death resulting from cachexia and anemia.

In briefly reporting this case we wish to call attention to the following facts:

(1) Tumors of the orbit in young children, especially if accompanied with ecchymosis of the lid, should arouse suspicion of metastasis from an adrenal growth.

Metastatic neuroma malignum, showing rosettes which represent atypical embryonic ganglia. Photo. × 126.

(2) The microscopic examination of specimens shows a characteristic rosette formation of cells.

(3) This form of tumor arises from embryonic nerve-cells of the adrenal gland.

PATHOLOGIC EXAMINATION.

The specimens submitted for examination consist of curetings from the antrum of Highmore and a small piece of tissue removed from the orbit. Fixation in Zenker's fluid.

On microscopic examination the curetings are found to consist chiefly of bone. The medulla shows an overgrowth of fibrous connective tissue and is invaded by tumor-cells. The bone in places is also attacked by osteoclasts. The tissue has been so severely traumatized that, for the most part, the exact character of the tumor-cells is obscured. They usually occur in bundles of elongated cells which stain with great intensity, the individual cells giving the appearance of nucleated fibrils. This appearance, no doubt, is partly or wholly artefact. In a few places, however, where the tissue has, fortunately, escaped injury, cell structures occur which at once reveal the nature of the tumor. These are groups of cells arranged in the form of so-called rosettes. The typical ones are almost perfectly round, with nuclei at the periphery arranged circularly about a central area of eosinophile material. This material on superficial examination appears to be finely granular, but more careful examination shows that it consists of fine fibrils cut across. In favorable sections the origin of the fibrils from the peripheral cells which abruptly taper into them can be made out. The nuclei are round, have chromatin nets not unlike those of lymphocytes, well-marked nuclear membranes, and show definite nucleoli. They are similar in appearance to the nuclei of the so-called glioma retinæ. These rosettes, however, are entirely different from the

rosettes of retinal tumors, because in the latter the cells show a limiting membrane bordering on a lumen.

Mitotic figures are not encountered, owing, no doubt, to the limited amount of material available for examination.

The small piece of orbital tissue removed is also badly traumatized, but shows invasion with cells similar to those in the malar bone. No rosettes are found here.

DIAGNOSIS.—Metastatic neuroma malignum of malar bone and orbit, probably primary in adrenal gland.

REMARKS.

The histologic diagnosis in this case rests chiefly on the presence of the rosettes, which, fortunately enough, are present in some of the specimens. These are identical in every way with those in the tumor of the adrenal gland, metastatic in the orbit, described by Tileston and Wolbach, sections of which I have at hand. This tumor was regarded by Wolbach as a sarcoma. J. H. Wright, however, in a communication which will soon be published, pointed out that this tumor undoubtedly arose from embryonic nerve-cells of the adrenal gland, the rosettes representing atypical embryonic ganglia, and he has reported other cases of his own which he formerly regarded as sarcomata. He finds that two other cases reported in the literature as gliomata are really of this same nature. As a designation for these tumors he has adopted the term *neurocytoma*. This, I think, is too restrictive.

While differing in details, these tumors are similar in general nature to the so-called gliomata of the retina, for which I have suggested the name *neuroma retinæ malignum*.* My reason for selecting the general term *neuroma malignum* was that it would be applicable to analogous tumors which might occur elsewhere in the nervous system. The selection of this term has thus been justified. The occurrence

* American Ophthalmological Transactions, 1904.

of these tumors of the adrenal gland lends support to the view, which I have also advanced, that the cells usually predominating in the retinal tumors correspond to the bipolar cells of the inner nuclear layer, which cells are believed by many to be analogues of the cells of spinal ganglia.

A CRITICAL STUDY OF THE OCULAR ASYMMETRY OF THE FORMOSAN SAVAGE.

CHARLES A. OLIVER, A.M., M.D.,
Philadelphia.

Through the kindness of Dr. William P. Wilson, Sc.D., Director of the Philadelphia Museums, I have been given the opportunity of critically studying an official and gold-medal, prize-obtaining series of life-sized, full-faced and profile photographs of a large number of Formosan savages, which formed a part of the ethnologic exhibit of the Formosan Government at the Louisiana Purchase Exposition, held in St. Louis, Missouri, in 1904.*

All the subjects were of Malay origin. They were representatives of seven of the eight tribes now in existence, and were expressive of those who are scattered over the northern and the central mountainous portions and the eastern plains of the main island.† Their total population, six years ago, did not quite reach 100,000.

These aboriginal Formosans are probably "the most

* The thanks of the writer are also due to Mr. Charles R. Toothaker, the curator of the Museums, for his many courtesies, and to Dr. Bernard Samuels, of Philadelphia, for much clerical assistance.

† The Yami grouping, which occupies the small island of Kotosho or Botel Tobago, situated some 35 miles off of the southeast coast of Formosa, has not, for several sufficient reasons, been used.

The Peipo tribe has so assimilated with the invading Chinese that it has practically become so much a part of them, in, both customs and language, that it is almost impossible for foreigners to differentiate between the two.

primitive specimens of the human race that can be found anywhere." They have but little, if anything, to do with the present Japanese administration, being judiciously allowed to practically decimate themselves. Their customs and habits; their strict observance of tribal hatreds and want of groupal interrelationship; their ever-present activity and aggressiveness in head-hunting*; their proper gauge of age, dependent upon ability and strength, without regard to years; their faithfulness in marriage; their family preservation and common protection (a true brotherhood, as it were); their freedom from coarse blood dyscrasia and comparative immunity from gross microbic disease; and their peculiar rites of burial—are all of intense interest, and tend to illustrate the purity of the stock, and demonstrate its usefulness in the particular phase of investigation to which the writer has subjected it.

The special work made from a study of all the mixed tribes (particularly with the immigrant Chinese) and the unmixed native groupings has been limited in this contribution to the as yet uncontaminated hostile savage "head-hunters" among the isolated northern tribes—particularly the Atayals, with a limited number of the Vonums and the Tsous, and a few of the Tsaliens. In consequence, this latter particular grouping of subjects, evenly divided among young adult males and females, embraces some extremely interesting and valuable material for a critical and a scientific (as far as yet possible) study of the external abnormalities and peculiarities of the ocular apparatus of the true savages of Formosa from an anthropologic standpoint.

The observations, which were carefully made by means of protractors, line measures, and gauged and ruled screens, upon a number of typical healthy specimens, taken at random from the excellent, large, and official collection

* Six special reasons for the practice are given. "Like fierce tigers, they range the woods and pounce on human heads."

at the writer's command, showed some ocular characteristics which may be conveniently noted as follows:

1. The skull formation, particularly among the Tsou grouping, was dolichocephalic in type and of good configuration.

2. The supra-orbital ridges were strongly marked, rather straight, and with a tendency for the right ridge to an upward and outward deviation.

3. The infra-orbital margins were well curved, properly shaped, and more evenly situated than the supra-orbital.

4. The left eyeball was somewhat the higher in the majority of instances.

5. The right eyeball was nearer the median line in the greater number of cases.

6. The left eyeball was, as a rule, the more deeply set.

7. The corneæ were oval, their long axes, which were directed about five degrees downwardly and inwardly from the vertical meridians, averaging about 10 to 11 mm. in length.

8. The pupils were oval, their long axes, which were 3 to 3½ mm. in length, being directed about three to five degrees downward and inward from the vertical meridians.

9. The interpupillary space averaged 61 to 63 mm. in length; the distance from the right pupil to the middle of the nasal bridge being the lesser on the right side.

10. The palpebral fissure was, ordinarily, from 2 to 3 mm. shorter on the right side than on the left, the right one averaging from 25 to 27 mm.

11. The palpebral fissure was 8 mm. at its broadest portion, that of the right fissure being a trifle narrower.

12. The intercommissural distance equaled 33 to 35 mm.; the lesser of the two portions from the inner commissures to the nasal median line being on the right side.

13. The commissural angles inclined some five to ten degrees down and in from the horizontal meridian.

14. The primary folds of the eyelids were well marked, though shallow.

15. The secondary folds of the eyelids were very slight and extremely faint.

16. The eyebrows, as a rule, were not pronounced, the supercilia, like the hairs of the scalp, being coarse and straight.

17. The cilia were abundant, well curved, and properly formed.

In general, the malar ridges, as a rule, were quite prominent; the supramaxillary prominences were rather flat; the nasal bridge was broad and depressed; the nasal alæ were thick; the nostrils were well dilated, inequalities of the apertures being quite frequently noticed; the mouth was long; the lips were full, particularly the lower one; the oral fissure was partly open, showing the filed teeth in some instances; the chin was strong, though in a few subjects, particularly in the women, the inferior dental arch was somewhat depressed; the forehead was well shaped and high in angle. The ears, especially the size of the pinna, its slant, the character of the helix and the lobe, which in the Atayals was pierced to admit of the insertion of a section of bamboo rod fully one centimeter in diameter and ten centimeters long, were most excellent.

In not a few instances, particularly among the women, the left thyroid gland seemed somewhat enlarged, without any evidences of proptosis. The ornamentation of the head, which consisted mainly in crowns of flowers and grass among the Tsaliens, was quite characteristic and appeared to advantage.

The tattooing,* the character of which had its tribal significance of puberty, station, etc., was seen among the Atayals and a few of the Tsaliens.

* The author is making a study of the colors employed and the designs used in tattooing, the latter of which, in all the instances seen, were geometric.

SOME IMPRESSIONS OF CERTAIN EYE AFFECTIONS IN THE NEGRO AS COMPARED WITH THE WHITE RACE.

JAMES L. MINOR, M.D.,
Memphis, Tenn.

I have been engaged in the practice of ophthalmology in Memphis for nearly twenty-five years, and, in spite of the fact that I have never desired them, I have had to treat a number of negro patients—estimated at about 3000—at my office, in addition to which I have seen an appreciable number at the Memphis City Hospital and at the Eye Clinic at the Memphis Hospital Medical College.

When I first began, notes were made and preserved of all patients seen, but I soon found that the negro was so unreliable in carrying out directions and reporting for further treatment that I dropped the habit, so far as he was concerned. Hence I make no pretense to scientific exactness, and simply give impressions which have been made salient points in my experience with certain diseases of the two races.

The negro, as a rule, is an irresponsible creature, and makes an undesirable patient, because he rarely follows directions unless their effects are immediate and pronounced. He acts as the spirit moves him, and is as apt to follow the advice of a casual passer-by as his physician.

Some interesting results bearing upon the subjects which I wish to discuss were obtained through the examination of the eyes of the pupils of the public schools of Memphis, made under my supervision in 1896, and published in the New York Medical Journal August, 1907.

Refractive Errors.—Among other things, it showed that

refractive errors were found just one-half as frequently in the negro as in the white; that no case of myopia was found; that hyperopes grew more rapidly less in the higher classes of the blacks than in the corresponding grades of the whites; and, further, it showed that the proportion of normally seeing blacks was two and one-half times greater than the whites, *i. e.*, badly seeing negroes 1 to 15, badly seeing whites, 1 to 6. This is partially explained by the uncorrected myopic whites; but when they are left out, the badly seeing whites were 1 to 10 only. The comparative absence of the higher degrees of astigmatism and hyperopia in the negro doubtless accounts for their better average normal vision. (Number of white pupils, 3181; number of negro pupils, 1849.)

Coming back to the impressions and experiences from my own practice, I will begin by referring to—

Myopia.—I have examined only two cases of myopia in the negro; one of these was in a teacher and the other a seamstress, and both were mulattoes.

Astigmatism.—I recall only three cases of astigmatism. In each the amount was slight, and of the hyperopic variety, and all patients were mulattoes.

Hyperopia.—Hyperopia has been infrequently observed, and I have never seen a high degree of it in a negro.

Presbyopia.—Cases of presbyopia rarely present themselves. The fact that the negro, as a rule, does little close eye-work is certainly a factor in the non-occurrence of myopia, and will explain the infrequent complaints, though it does not prove necessarily the non-existence of other refractive errors, as well as presbyopia.

Muscular Insufficiency.—I recall only one case of muscular insufficiency (exophoria) in the negro, and that was in the person of a mulatto seamstress, generally run down, and weak from overwork and bad hygienic surroundings.

Strabismus.—I never examined a single case of strabismus

in the negro, though I have seen two cases of convergent squint—one in the person of a bootblack at my hotel, who, when told that he could have his eyes straightened, said, as God had made him that way, he "'lowed" he "would make no change"; and another, in a child recently brought to the office, but, coming at a late hour, was told to return the next morning for examination, who dropped the matter, and never sought relief.

Glaucoma.—My experience has been that glaucoma is more frequently seen in the negro than in the white. Statistics* show that about 3 cases of glaucoma occur in every 1000 eye patients seen. This proportion would entitle me to 9 cases all told,—one case every two and one-half years,—and yet I will average three or four cases a year. I recall one winter operating on four cases of glaucoma in the negro.

Trachoma.—My experience has been that trachoma is seen as frequently in the negro as in the white, and probably more frequently. I see five or six negro patients a year with trachoma, which is fully double the number I would be entitled to if the disease existed in the blacks in the same proportion that it does in the white, *i. e.*, about 2½%.†

Tolerance of Disease.—Another thing which has impressed me is that in the gonorrheal ophthalmias of the adult and the new-born the disease is less severe, and the corneal ravages less in the negro than in the white—this in spite of the fact that treatment is often unsought and, when attempted, is usually most imperfectly carried out.

Iritis.—That iritis, to which the negro is very prone, on account of treatment, does not seem to be so severe during the attack nor so serious in its after-effects, is a fact that has often impressed me. They often continue at work regardless of the disease, and not infrequently, when examined for other troubles, it will be found that extensive posterior

* Eye Diseases, Nomenclature and Statistics of, Ref. Hand-book of Med. Sci., Supplement, 1893, J. L. Minor.

† *Ibid.*

synechia and even exclusion of the pupil have existed for years without ill effects.

DISCUSSION.

DR. H. D. BRUNS, New Orleans: I am fortunately able to deal in actual figures. You may remember that in 1903 I read a paper on this subject before this society. I had then a total of 17,311 tabulated cases, of which 6290, or 36%, were persons of color; now, in 1910, I have 31,178 tabulated cases, of which 12,972 cases, or 41%, were persons of color. In 1903, of refractive errors, only 19% were in persons of color. In 1910, of 6098 refraction cases, 1686 cases, or 27%, were persons of color. But, while of all refraction cases among whites only 29% were cases of simple hyperopia, among persons of color with refractive errors 49% were cases of simple hyperopia. All refraction cases except those of middle age (say, fifty) or over were examined under full atropinization.

Tropias: In 1903 only 19% of all tropia cases were found in persons of color. In 1910 there were, among the 31,178 cases, 470 tropia cases, of which only 56 cases, or 11%, were persons of color. True squint is seen but rarely among the real blacks, but I have seen it, and several times associated with absolute emmetropia.

Glaucoma: In 1903 43% of all cases of glaucoma were persons of color; of the inflammatory type, 39%, of the non-inflammatory type, 46%. In 1910 there were, among the tabulated cases, 268 of glaucoma, of which 133, or 49%, were persons of color; of these 133 cases, 40% were of the inflammatory and 58% of the non-inflammatory type, showing the liability of the negro race to simple glaucoma.

Trachoma: In 1903 there were among my 17,311 tabulated cases, 324 cases of trachoma, of which only 9% were persons of color; or, of 3050 whites with conjunctival disease, there were 9% with trachoma; while of 2002 persons of color with conjunctival disease, only 1½% had trachoma. In 1910, out of the 31,178 cases, there were 478 cases of trachoma, of which 45, or 9%, were persons of color. My belief is that trachoma is much more common in those of mixed blood than in real blacks.

Taking only the subacute and chronic forms, so as to

exclude traumatisms, acute infections, and phlyctenular ophthalmia, I have among the tabulated cases in 1910, 1072 cases of subacute and chronic conjunctivitis; of these, only 316 cases, or 29%, were persons of color. This would seem to indicate a certain insusceptibility to conjunctival disease on the part of the black race, and this perhaps may be the source of their lack of liability to trachoma.

The negro has gonorrheal ophthalmia often, and there is no doubt in my mind that he shows marked resistance to the disease.

CHAS. W. KOLLOCK, Charleston, S. C.—I have for many years been much interested in the diseases and conditions of the eyes of colored people, and especially in those of the pure-blooded negro. The mulatto partakes of the nature of the white according to the admixture of blood, and the conditions are much the same in the two—that is, we see in the mulatto all the diseases that are common to the white (though corneal affections are more frequent with the former), as well as errors of refraction and the accompanying results. Dr. Minor has mentioned that the vision of the negro is better, as a general thing, than that of the white, and that errors of refraction are less common, and my experience has been the same as his. I wish, however, to emphasize the fact that affections of the cornea are much more frequent among the blacks and mulattoes than the whites, which is doubtless due to their being more generally tainted with syphilis and to their unhygienic and unsanitary ways of living. At the Shirras Dispensary, in Charleston, where I have a service for six months each year, I have looked over the records for ten years and find that, among the blacks and the mulattoes for that period, over 40% of all the cases were affections of the cornea, while among the whites, for the same period, the percentage of corneal affections was a little more than 13%. Chalazion, pterygium, and hemeralopia are very much more frequently seen in the negro and mulatto than in the white. Trachoma, like all other chronic affections of the conjunctiva among them, is rare, while acute catarral conjunctivitis and the purulent ophthalmias are seen about as often as among the whites. My experience with glaucoma is not that of Dr. Minor, as I have seen it occur as often among the whites as the

Alternating convergent squint in pure-blooded negro. Reported by C. W. Kollock, M.D.

colored. Cataract is met with the same frequency. Refractive errors are much less common with the black than with the mulatto and white. Hyperopia is not uncommon in the black, and I had one case of 8 D. Myopia is very infrequent, and during my twenty-five years of practice in Charleston I have known of but eight cases. One was myopic astigmatism and seven were simple myopia. Two were of unusual degree, one having 12 D. and the other 16 D. and 18 D. in the two eyes. Albinism is also more common among the negroes than among the whites, and one of these, a pure negro, had alternating convergent squint. Squint is extremely rare in the pure-blooded negro, and I have seen but two or three cases—the photograph of one I show. He was a boy of about twelve years of age, with alternating convergent squint. The vision in each eye was $\frac{20}{20}$, and under atropin with + 2 D. he saw the same. In the hospital he passed from my care to another, who divided the internal recti, but, as would be supposed, with no good result.

DR. SAMUEL THEOBALD, Baltimore: Certainly, in Baltimore, trachoma is extremely rare in either the mulatto or negro. On the other hand, there are many cases of high myopia among the negroes. I have seen this condition, with marked choroidoretinal changes, as often, I should say, in the black as in the white race. My experience has convinced me, further, that glaucoma is not so rare in the young of the negro race as it is in the young of the whites.

DR. LUCIEN HOWE, Buffalo: Anatomic peculiarities of the eye of the typical negro and of the white man may be of interest. Shortly after Dr. Burnett brought up this subject several years ago an almost perfect type of negro happened to come into our dissection room. Sections were made of his eyelids and of the lids of a white subject, but absolutely no difference between them could be discovered.

THE DIFFICULTY SOMETIMES MET WITH IN THE DIAGNOSIS OF A SUBRETINAL MASS.

ROBERT L. RANDOLPH, M.D.,
Baltimore, Md.

The following case came under my observation the first day of September, 1909:

F. W. M., twenty-eight years old, apparently in fine health, and leading an outdoor life on the farm. He had been gradually losing his sight in the left eye for over a year, and had been under constant treatment all this time. His vision in the affected eye was $\frac{20}{100}$, with a very slight amount of hyperopia. His vision in the right eye was $\frac{20}{20}$, with an equal amount of hyperopia and a little astigmatism, according to the rule. His pupillary reactions were all perfect; his media were clear. The accompanying drawing shows accurately the condition of his eye-ground. The area in the picture does not take in quite a large portion of the lower and outer side of the retina, in which location there are numerous patches of choroiditis of the characteristic disseminated type. The pigment changes seen at the base of the mass, and which are also present on the sides of the latter, are situated in the retina. One will note, just above the mass, a circular area somewhat larger than the disc. This area suggests that possibly we have here the commencement of just such a mass as is seen below. It has no elevation as yet, but it is evidently a choroidal process which has thus far not made much headway into the overlying retina. That we have an unmistakable choroiditis is clear from the numerous patches seen, as has just been said, to the lower and temporal side of the mass. The pigmentary changes in the retina seen near the mass are secondary to what, I think, is a protracted disease of the choroid. As to the exact nature of this disease, I am in doubt, though I am rather disposed to regard it as the so-called pigmentary chorioretinitis described by Pope, Förster, Rudnew, and Iwanoff.

Fundus view, showing subretinal mass.

It is not difficult to conclude from what I have said that I regard the mass as inflammatory in its nature—that is to say, a variety of choroiditis. When first seen, I thought of a tuberculous process, and the patient was subjected to the usual tests for tuberculosis, with the exception of the Calmette test. The most sensitive of the three tests, the cutaneous test, was repeated for fear perhaps that some blunder had been made in the technic of the first trial, but it resulted negatively, just as in the first instance. The subcutaneous test showed neither the slightest systemic nor local reaction. This would at least seem to exclude tuberculosis, and he was at once put on iodid of potash, running up to 30 grains three times a day. This treatment was kept up for five weeks, when I began to think strongly of leukosarcoma of the choroid, a possibility which I have kept before me throughout my acquaintance with my patient, but which I think at the present writing to be less likely. I sent him to three colleagues in neighboring cities, with the statement that I was in favor of a diagnosis of leukosarcoma. One said that "it is more than likely that it is a leukosarcoma, but I should advise keeping him under observation for some time before proceeding to radical measures." Another said that "the diagnosis lies between tubercle and leukosarcoma," while the third was in favor of an inflammatory process. If I remember rightly, none of the gentlemen had seen a similar condition. About this time a Wasserman test was made, with negative result, though it must be said that he had been taking iodid of potash and small doses of the biniodid of mercury for some weeks. He has now been taking iodid of potash pretty steadily all the autumn, and during January, February, and March he was taking 100 grains three times a day. Since the first of April he has been on tuberculin injections, starting with $\frac{1}{10000}$ milligram, and increasing gradually, until he is now getting $\frac{1}{100}$ milligram twice weekly.

He has been subjected to frequent ophthalmoscopic examinations, and before he was put on the tuberculin injections I noted some shrinkage of the mass at its lower and inner side, also at its upper and inner aspect. This was determined by the position of certain vessels which had, so to speak, parted company with the "tumor," and now lay somewhat away from the latter. I see no recession of the mass, which seems to me to measure, as it always has done, about 2 mm. in height. I have determined to keep him on tuberculin injections for another month, and longer if there seems to be improvement; if not, my intention is to return to large doses of iodid of potash. I see him once a month, and careful measurements are made of the state of the growth with the ophthalmoscope and perimeter.

The difficulty alluded to in the title of this communication is that of deciding whether we are dealing with an eye which should be removed or with an eye which is comparatively harmless.

DISCUSSION.

DR. PERCY FRIDENBERG, New York: I should like to ask whether, in the course of the tuberculin injections, there were any changes in the appearance of the mass, whether any fresh deposits or reaction could be seen in the retina, and whether the growth was sufficiently far forward for transillumination; also whether there was any evidence of a solid mass?

DR. R. L. RANDOLPH, Baltimore: There was not the slightest local reaction as the result of the subcutaneous injection of tuberculin, and this was searched for on several occasions. I am, of course, a believer in the value of transillumination as an aid in the diagnosis of intra-ocular tumors, but I have never gained anything from the use of the method where the intra-ocular mass was situated as far back as this one.

DR. CARL KOLLER, New York: From a cursory examination, I have the impression that the source of the tumor is

in the sclera. As to its nature, nothing definite can be concluded from the appearance, but the absence of precipitates on Descemet's membrane and of opacities of the vitreous at any time speaks against both tubercle and gumma of the choroid.

DR. W. B. JOHNSON, Paterson: I was also of the opinion that the tumor came from the sclera. I did not think it was tuberculosis or syphilis. I thought possibly it might be a massing of colloid material. I have seen such a massing around the nerve. I never saw it separated from the nerve. I feel quite positive, from the appearance of the tumor, especially on the nasal side, that it comes from the sclera. There is a dipping down of the tumor mass and a gliding of the retina over the surface of the tumor at the edge which gives an appearance of considerable depth between the sclera and the retina. The choroidal tissue is apparently entirely destroyed. The length of time that the tumor has existed without producing marked symptoms I do not think would be positive as an indication of it not being a sarcomatous tumor. I do believe, however, that the apparent comfort which the patient has had with the eye is an evidence of some other condition than tuberculosis or syphilis. There is, I believe, no increase of tension in the eye and no symptoms of pain.

DR. W. B. MARPLE, New York: Through the courtesy of Dr. Randolph I saw this case in January last, and have been very much interested in seeing it to-day and learning of its subsequent course. I could not think that it was a sarcoma; there was no mottling or nodular appearance of its surface, nor have I ever seen any neoplasms of this nature so brilliantly white. But of greater significance was the disturbance or thinning of the choroid in the immediate vicinity of the growth, which seemed to indicate that the growth was smaller than formerly. Such retrogression in a sarcoma I have never seen.

The numerous spots of choroidal atrophy below were like what we see in disseminated choroiditis. The negative Wasserman and the negative results produced by the iodids would seem to exclude a specific etiology. Notwithstanding the negative reaction from the injection of tuberculin, it

seemed to me worth while to put the patient on tuberculin. One of my cases of tubercular iritis never showed any reaction, but recovered entirely on increasing doses of tuberculin. Haab has an illustration and makes some remarks on conglobate tubercle of the choroid (Graefe's Arch., vol. xxv) which seem to have some bearing on this case. He refers to the areas of choroidal disturbance in the vicinity of the growth as differentiating it from sarcoma.

DR. JOHN E. WEEKS, New York: I had the opportunity of seeing this patient about six months ago. I made careful measurements and drawings, and I wrote to Dr. Randolph saying that, in my opinion, the affection was either syphilitic, tuberculous, or leukosarcoma, and advised the administration of iodid of potassium in large doses. In three months from the first observation I saw the patient again, and made charts of the field and again studied the condition of the tumor. The scotoma in the field of vision was a trifle less after the lapse of three months, and the relation of the blood-vessels to the mass seemed to be in favor of a slight recession in its size. The second observation led me to exclude sarcoma.

DR. C. F. CLARK, Columbus: I should like to ask Dr. Randolph whether any attempt was made to obtain an *x*-ray picture of this mass? It would seem like a hopeless undertaking, but I remember that a number of years ago, when *x*-ray work was first introduced in this country, I found that, by passing a little film up into the nose beyond the ethmoid as high as it would go, a picture could be taken from the side with only the intervening ethmoidal cells, which presented only a small amount of bony tissue in the course of the rays. Possibly if the growth were a tumor of the sclera, such a picture might give some information.

DR. JOHN E. WEEKS, New York: I think there was very slight vision, and this was only obtained by rotating the eye upward.

DR. ARNOLD KNAPP, New York: I think the temporary improvement under iodid of potash does not rule out sarcoma. I remember having seen a case in my father's

practice which improved under the temporary administration of this drug. Later the eye was removed and the growth proved to be a leukosarcoma.

DR. F. H. VERHOEFF, Boston: I think the changes in the choroid adjoining the tumor indicate either an old inflammatory condition or a sarcomatous invasion. That the tumor is a cyst is suggested by its smooth outline. It may have developed upon an old inflammatory basis, the cyst being due to splitting of the retina in the layer of Henley. Whether it is a cyst or a solid tumor, it seems to me, could be determined by introducing a hypodermic needle and ascertaining if fluid is present or not.

DR. PERCY FRIDENBERG, New York: It may seem rather rash to venture a suggestion upon the strength of a single examination when other gentlemen have made several, but as there seems to be no consensus as to the diagnosis, I may be pardoned. The suggestion which I make is that of a possible gumma in the sclera going on to connective-tissue formation sufficient to cause some bulging. There is no doubt in my mind that the entire choroid is gone over the area occupied by the new formation, and that the sclera itself shows through. There is decided thickening of this coat, and I think the ophthalmoscopic picture would be explained by a thickened scar following gummatous scleritis. If I remember Dr. Randolph's account of the history correctly, the assumption of a previous luetic infection seems justified. The fact that the present ophthalmoscopic picture has now persisted for some time would indicate that we have to deal not with an active process, but with the residua of a morbid condition having both inflammatory and neoplastic characteristics.

DR. R. L. RANDOLPH, Baltimore: The Wasserman test was negative. I think the view of Dr. Fridenberg a tenable one, and this I had in mind when I kept him on the iodids in spite of the negative Wasserman.

GLAUCOMA FROM ADHESION OF THE LENS CAPSULE TO THE CORNEA.

ARNOLD KNAPP, M.D.,
New York.

The lens capsule is apt to become adherent to the cornea after a penetrating injury to the eyeball, where the cornea and lens have been wounded, or after the extraction of cataract. In some cases this is followed by glaucoma, which is very difficult to control and is often followed by blindness. In the first or traumatic variety I should like to report on three cases.

CASE I.—*Traumatic Irideremia. Broad Adhesion of Capsule to Transverse Corneal Wound. Glaucoma.*—D. G., twenty-four years old, while riding in an open surface car, received a severe blow in the left eye one week before her first visit, on August 12, 1904. The eye was congested, there was a transverse wound across the center of the cornea, the anterior chamber contained cataractous lens material, and no iris was to be seen. Tension normal. Field normal. Vision: m. h. After two months, October 8th, the eye was quiet, the lens completely absorbed, and the capsule was broadly adherent to the corneal scar. Tension +. November 7th: The capsular adhesion was divided with the pince-ciseaux. No reaction. Vision with correcting glass $= \frac{20}{30}$. January 14, 1905: The inferior capsule had again become united to the corneal scar. Tension normal. April 5, 1905: Vision $= \frac{20}{40}$. The upper opening has become partly filled in with new tissue. Tension + $\frac{1}{2}$. April 23, 1906: The operation was repeated, as the tension was increased. A round opening remained in the capsule. Tension normal. Is using pilocarpin drops. Vision $= \frac{20}{40}$. October 12, 1907: Tension has been again elevated for some time. At another operation it was attempted to resect a

V-shaped piece of capsule; this failed. The tension again became raised. It has been kept somewhat in check by miotics, though now it is slightly raised and vision is only $\frac{20}{70}$. Field and fundus are normal.

CASE II.—*Traumatic Irideremia. Broad Adhesion of Capsule to Cornea. Glaucoma. Enucleation. Pathologic Examination.*—A. C., thirty years old. After a severe blow to the right eye on December 2, 1907, the eye three weeks later presented a transverse scar in the center of the cornea, with absence of iris, absorption of lens, and a thickened capsule adherent to the corneal scar. The tension is increased. On January 20, 1908, the glaucoma has been severe and the eye painful; cyclodialysis was performed, as from the experience in the previous case division of the capsular adhesion was not promising. A quadrant of the ciliary body was detached. This was followed by hemorrhage into the anterior chamber, with no reduction in tension and continuance of pain. Pilocarpin sweats and miotics were of no avail. Enucleation was refused, and the patient disappeared from view until January, 1910. On her return she stated that the eye had quieted down until quite recently; now it was blind, inflamed, and painful. The eye was excised and prepared for *microscopic examination.*

This showed that there was no iris. The ciliary processes were drawn forward anterior to the pectinate ligament and flattened out, occluding the angle of the anterior chamber. The apices of the ciliary processes were distinctly to be seen drawn forward by the zonular fibers in the direction of the corneal scar. Both capsules are adherent to the corneal scar. There is a narrow space between the capsular layers filled with degenerated lens fibers, vesicular cells, lenticular débris, and organized connective tissue. The place of adhesion to the cornea is a somewhat thickened area, comprising cicatricial tissue and convoluted Descemet's membrane.

CASE III.—*Broad Adhesion of Capsule to Cornea. Glaucoma.*—A boy, aged twelve years, on being examined for a refractive condition, was found to be blind in one eye. There was a broad adhesion of iris and capsule to the cornea, no lens, the eye was hard and somewhat enlarged. There was an indefinite history of an injury several years ago.

After cataract extraction I have observed three cases of glaucoma where the lens capsule was adherent to the corneal incision.

CASE I.—*Combined Extraction. Anterior Capsular Adhesion. Glaucoma. Enucleation. Pathologic Examination.*—D., fifty-six years old. Opacities of cornea from interstitial keratitis, posterior cortical cataract. After an extraction with iridectomy the eye developed glaucoma and the capsule was observed adherent to the corneal section, which was rather more corneal than usual. Repeated division of this adhesion was performed without lasting effect; the regeneration of the capsule started from the angles, and the interval was soon bridged over again, and glaucoma returned. The eye was finally enucleated on account of the constant discomfort.

Microscopic Examination.—At site of iridectomy the iris stump is bulbous and turned back (entropion uveæ); the ciliary processes on this side are flattened and pushed forward to the anterior margin of the iris stump. Both layers of the capsule are drawn to and adherent to the corneal scar, where the corneal stroma is thickened with scar tissue and convoluted Descemet's membrane. On the opposite side, the side away from the corneal section, the ciliary processes are drawn directly inward in the direction of the scar. The ciliary body is retracted, the iris is atrophied at its root and broadly adherent to the cornea, effacing the angle; the free end of the iris is directed inward.

CASE II.—*Combined Extraction. Anterior Capsular Adhesion. Glaucoma. Cyclodialysis.*—B., fifty-eight years old. Extraction of cataract with iridectomy in a very small, hypermetropic eye. The healing was delayed; the anterior chamber remained unformed for some days. Subsequently the eye showed a tendency to increased tension. There was an anterior adhesion of the lens capsule to the section, which was rather corneal. Glaucoma developed, which was not influenced by miotics. Broad division of the capsular adhesion failed to have any lasting effect. Cyclodialysis was performed in November, 1909. This has kept the tension down to the present date (April, 1910), though there is some diminution in vision.

CASE III.—*Combined Extraction. Glaucoma from Capsular Adhesion. Cured by Operation.*—A. G., seventy-five years old. Extraction with iridectomy. Normal healing and good visual result. Two months later the eye was found to be hard. On careful examination a narrow band of capsule at outer column of iris coloboma was found to be attached to the corneal incision. This was divided with a knife-needle, and the tension became normal. One month later the eye was again hard and the band of capsular adhesion had reformed. The strand was then drawn out with a Tyrrel's hook and divided; the adjoining capsule was cut with pince-ciseaux, causing slight prolapse of vitreous. The band has not reformed, the tension is normal, and vision undisturbed.

The cause for the glaucoma seems to be the obliteration of the angle of anterior chamber by the ciliary processes or iris displaced forward by traction of the capsule adherent to the corneal scar, as Treacher Collins (Trans. Ophthal. Soc. United Kingdom, 1890, Royal London Ophthalmic Reports, vol. xvi, part iii) has shown. This at least is the condition found on microscopic examination. The mere mechanical obstruction of the angle of the anterior chamber cannot be the only or the primary cause, as the cases, where only a small part of the capsule is adherent, show. The traction is greater the more central the corneal scar, and the glaucoma is proportionately more severe. The total absence of the iris in the first two cases had no effect in counteracting the glaucomatous process. It also shows the uselessness of an iridectomy as a remedial agent. When the scar is central and occupies the greater part of the corneal diameter, we are powerless to prevent the progress of the glaucoma. Operations to divide the capsular adhesion seem to even make matters worse, as the regeneration is so active and the resulting capsular adhesion is denser than before.

In the cases following cataract operation preventive treatment is most important. This condition occurs when

the extraction has been performed with iridectomy, and is facilitated by certain methods of opening the capsule. The avoidance of capsular complications is the greatest advantage of the simple operation. The importance of recognizing the dangers of capsular adhesions is accepted by all operators, and it is common practice to stroke back any capsular tags in the region of the iris coloboma. This cannot be done with certainty, as the capsule is invisible. Delayed union with unrestored anterior chamber naturally predisposes to this accident. The treatment after the condition has occurred and the eye is hard is to divide the adhesion. If the adhesion is broad, it is difficult and unsatisfactory; when the adherent band is narrow, it can be readily divided in a manner to prevent its reuniting, and the glaucoma is cured.

DISCUSSION.

DR. S. LEWIS ZIEGLER, Philadelphia: This is a somewhat hopeless condition, which is rather difficult to handle. I have had such a case recently which was the result of a severe injury. There was total rupture of the cornea from periphery to periphery, somewhat similar to the case described yesterday by Dr. de Schweinitz, which he covered with a conjunctival flap. Upon union there was adhesion of the lens capsule to the cornea, almost directly in the center. There was also some prolapse of the iris, which was excised at the time of the injury. The corneal wound was held in approximation by conjunctival sutures extending across its front. The union of the capsule to the cornea occurred in the center, and there was a slight adhesion just beyond what would be the margin of the pupil. Probably a month after healing glaucoma set in and I was compelled to make a severance of the adhesions, which I did with a little knife I have devised for this purpose, which I call a synechiotome. Instead of the blade being made on a curve, it is set at an angle of 45 degrees, so that the movement in the line of the shaft will give a cutting action in the line of the knife. By passing this in through a corneal incision, cutting through the adhesions, and following it up by the

introduction of the silver iris spatula, I was able completely to loosen the point of attachment. As the wound healed very promptly afterward, the formation of the aqueous held the capsule and iris back far enough to prevent new adhesions from forming. The tension is now practically normal, or possibly a trifle below normal, and the eye is perfectly quiet..

DR. EMIL GRUENING, New York: I have seen a number of cases of this kind. I think that if we have a capsule adherent to the cornea and succeed in dividing the adhesion without emptying the anterior chamber, we do well. The knife devised by Dr. H. Knapp has served me well. I introduce the knife, closing the wound by the shank of the knife, and divide the adhesion without emptying the anterior chamber. I have a number of cases in which I have succeeded in this way.

SOME OBSERVATIONS OF THE OCULAR MANIFESTATIONS OF SINUS DISEASE.

G. E. DE SCHWEINITZ, M.D.,
Philadelphia.

In the present communication it is not necessary to analyze the extensive literature of the ocular manifestations of sinus disease which has accumulated within the last few years, inasmuch as its only purpose is to record briefly a few observations of my own which confirm and elaborate those which have been made by other clinicians. I have no intention of reverting to what may be called the gross interpretations of nasal accessory sinus disease in ocular manifestations—that is, to those which exhibit obvious external signs of orbital cellulitis, abscess formation, tumor, proptosis, displacement of the eyeball, etc., but desire to speak of certain manifestations which, while they are common enough in various types of sinus affection, are not infrequently misinterpreted.

(1) *Recurrent or Fugitive Edema and Ecchymosis of the Eyelids.*—This manifestation, which varies from a slight edema of the lid and flushing of the palpebral skin surface and surrounding area to a marked edematous swelling of red or brawny red color, usually is associated with intense headache, and differs somewhat from the common edema of the lids, which is so conspicuously present in acute ethmoiditis, antral and frontal sinus disease, in that it comes and goes—that is to say, presents itself in the form of attacks separated by intervals of time, it may be of days, weeks, or even months, of entire or comparative comfort; in other words, it is a typical recurring or fugitive edema and may be the only notable symptom of the affection. This is a common enough condition, although not always correctly interpreted, and hence is briefly described.

Occasionally, in place of the edematous manifestation, there is an actual blackening suggesting an *ecchymosis of the lid*, which, like the other, recurs from time to time. During the intervals, pain and discomfort of all kinds are absent. In illustration of the last-named phenomenon I may recite a case history:

A woman, aged fifty-five, consulted me some years ago because of attacks of intense eye pain and burning on the right side of the face, always accompanied with swelling, redness, and transient edema of the right eyelids. The pain under these circumstances passed over the eye, along the brow, and down behind the ear, and had lasted for several years. Prior to the period at which I saw her, and for some time afterward, she had been the subject of attacks of what were known as "black eye," that is to say, in place of the redness and edema to which I have made reference, the skin presented the characteristics of a subcutaneous ecchymosis. Although she had been constantly under the charge of physicians and had received some intranasal treatment, and one physician had suspected orbital disease, according to the letter which he wrote me, both he and his patient ultimately concluded that the attacks of pain

might in some way be due to her eyes, largely because the refraction of one eye was a high mixed astigmatism, and of the other, a compound hyperopic astigmatism. The eye-grounds were normal, the visual fields unaffected, and no relief had followed the most accurate correction of the refractive error. Examination, made at my request by Dr. Freeman, revealed a small polyp at the opening of the nasofrontal duct, and the presence of frontal sinus as well as antrum-disease. The operation which he performed exposed the sinus filled with polypoid masses, pus in the ethmoid, and some slight purulent material in the antrum.

Some years after Dr. Freeman's operation there was some recurrence of the trouble, and in another city another operation, in which the sinus was again opened and some areas of necrosed bone found, finally produced ultimate and persisting cure.

A case of this character seems to me important from the standpoint of diagnosis. This woman was, for a number of years, the subject of sinus disease, and apparently the only notable manifestation of it was a fugitive edema and fugitive ecchymosis of the lids. The attacks were attributed by some to rheumatism, by others to gout, and were believed by one observer to be expressions of an angioneurotic edema,* and because of these errors in diagnosis suitable treatment was long delayed.

In the last few years a number of similar cases have come under my observation, of a somewhat milder type, although with similar symptoms, usually in the form of a moderate edema of the lid, associated with intense eye pain and supra-orbital neuralgia, and, curiously enough, all the patients were positive in their statements that their discomfort was aggravated by eye use, if not actually brought about by it, and therefore they sought relief in various oculists' offices.

* In true angioneurotic edema pain is absent, and, according to some clinicians (J. C. Wilson), itching and burning are also absent.

A young lawyer, aged thirty-five, with divergent strabismus following an overcorrection after a tenotomy for internal strabismus in childhood, had traveled far for relief of these recurring attacks of lid edema. He gave no particular account of what in general terms may be called nasal difficulties, and yet the discovery of frontal sinus disease, which was relieved by intranasal methods, produced a permanent cure after a number of years of discomfort.

Three other patients, a young man aged twenty, a woman aged forty-five, and a clerk aged twenty-six, presented these transient edemas in even less marked manifestation, but also associated with violent pain, and all came in the belief that, because of the localization of the pain and its apparent aggravation by eye-work, ocular treatment would be of service to them. In each instance examination revealed sinus disease: two of the patients had frontal sinusitis and one ethmoiditis, and all were promptly and permanently cured by suitable treatment directed toward the relief of these conditions.

All of us are familiar with so-called "fugitive edema" of the eyelids associated with headache, such, for example, as Robinson* describes, and concerning which he remarks: "Such cases are not uncommon. We often find those who are the victims of periodic headaches presenting a condition of fugitive edema of the eyelids. We also find many women during the menopause who have localized swellings of the hands and arms, swellings which are tender, pit on pressure, and are preceded by pain, but pass away after a few hours of exercise." Now I suspect that in a certain number of these cases of fugitive lid edema, and others like them, such, for instance, which I myself have described a good many years ago,† unsuspected sinus disease was the real etiologic factor, and it would seem that part of the examination of every such case of periodic

* Brit. Med. Jour., May 12, 1888.

† Amer. Jour. Ophthalmology, June, 1888.

headache with fugitive edema of the eyelids, associated with pain of the character already described, with or without redness of the lids, and with or without the appearances suggesting a subcutaneous ecchymosis, as well as those varieties of edema of the lid which are known as arthritic edema, according to the French designation, and which, indeed, are often rheumatic in character, should include a thorough investigation of the sinuses. It is, of course, easy to explain the recurrent character of these edemas. Evidently spontaneous drainage of the sinus affected takes place at the moment of relief, and the edema may occur again when the drainage ceases. It is well known that the smallest quantity of purulent material in the sinuses is capable of originating such edema.

A brief account of recurrent edema of the upper eyelid as a symptom of nasal polypus has been put upon record by John Dunn,* which contains the reproduction of a photograph taken at the time that the edema was manifest. This was attributed to a vasomotor paresis of the vessels of the upper eyelid, as the result of a reflex from the area irritated by the myxomatous middle turbinate, which was removed, with relief of the condition. Polypi also extended some distance below the middle turbinates. There is no reference to the sinuses and what their condition was, but one may well believe that they also were diseased, and that drainage was secured by this amputation of the turbinates.

(2) *Fugitive Episcleral Congestion.*—As is well known, the term *fugacious periodic episcleritis* was applied by Fuchs to a variety of relapsing episcleritis characterized by the appearance of one or more patches of episcleral injection or edema, of violaceous hue, lasting from two to eight days, and reappearing again at intervals of several weeks or months, and that the same affection was described by Swan M. Burnett years ago, under the name of *vasomotor dilata-*

* Amer. Jour. Ophthalmology, ix, 1892, p. 134.

tion of the vessels, and by Jonathan Hutchinson, with the title "*hot eye*," and that usually in this disease gout and rheumatism are associated dyscrasias. Now there is a manifestation of sinus disease which is not unlike this. It is, in a certain sense, a variety of episcleritis, or rather a form of episcleral congestion, with deep-seated subconjunctival overfilling of the vessels, which are dilated and tortuous, and the area under which they course of violaceous tint. The patch of congestion is not bleached by adrenalin. It has seemed to me, in some cases which I have studied, notably one, that this condition of affairs was always more pronounced in the outer half of the eyeball, although not entirely confined to it.

It must at once be distinguished from the well-known congested conjunctiva and watery eye, which is frequently, if not constantly, present in sinus disease, and which is one of its well-known signs. Like the fugitive edema of the lid to which I have made reference, this episcleral congestion comes and goes, and differs from ordinary episcleritis in the deeper hue of the dilated and tortuous vessels, and in the association of *violent* headache, not merely local discomfort. In one notable instance of this affection in the person of a young woman in the early twenties, these attacks lasted for a number of months, with intervals of comparative quiet—that is to say, intervals lasting for weeks and even months at a time, when the eyes were practically free from congestion. This patient knew she had, in general terms, nasal difficulties, and was addicted to the bad practice of using a spray at night, generally, I think glycothymol, to relieve, as she supposed, her nasal congestions. Ordinary examination of the nasal fossa revealed nothing except intense redness; these was no pus, no polypus, no positive sign of sinus trouble, and yet, as events showed, a most serious condition of affairs was present.

In another patient, a woman in the early forties, the

attacks, which have always occurred in the left eye,—and it may be said that these patches of fugacious episcleral congestion may be unilateral or bilateral, according as the sinus trouble is on one or both sides,—were accompanied by a patch of deeply tinted episcleral congestion at the upper and inner portion of the sclera, and on one occasion associated with a really stubborn hyperemia of the iris, which resisted the action of the mydriatic for a number of days —so much so that I did not suspect what the etiologic factor was, supposing I was dealing with an ordinary attack of episcleritis. It was not until an examination, made after some days of ineffectual ordinary treatment, revealed the presence of a left sinusitis, the relief of which was followed by the prompt disappearance of the episcleral patch, which, however, has recurred again, with a recurrence of the sinusitis. Radical operation has not been performed.

It is, of course, the practice of every careful ophthalmologist, if he is not himself expert in intranasal examination, to refer all cases of recurring congestion of the eye at once to a competent rhinologist, because of the well-known association between nasal disease and conjunctival congestion, but I want to eliminate these cases from the classification at present under discussion because the appearances are totally different from those ordinarily seen, as far as my own experience goes, with sinus affection. They may, I think, be perfectly well mistaken, even by a careful observer, for ordinary types of episcleritis, and, furthermore, in the more violent type, which I have a few times observed in association with sinusitis, there has been a distinct *edema of the corneal epithelium* at the height of the attack, and when the pain was most severe, producing an appearance not unlike that seen when cocain has been too freely used in the conjunctival culdesac. Now, because these manifestations are closely similar to the episcleritis or episcleral

congestions which are so common in young women, and which are often associated with pelvic disorders, disturbance of metabolism, rheumatic or gouty diathesis, or even a tuberculous taint, it is not an unnatural mistake to forget the sinuses, especially if routine intranasal examination has not revealed, as, indeed, it may not reveal, positive evidence of sinus disease. My only object in reverting to these fugacious episcleral congestions is to point out that in some instances they are the signs of sinus affection, and that there can be no possible harm in investigating the sinuses under these circumstances, even if they do not prove to be diseased, and even if other causes are subsequently shown to be the etiologic factor.

(3) *Some Unusual Forms of Scotomas as the Result of Sinus Disease.*—It is so well known that sinusitis may exist without external signs of orbital inflammation, but be associated with ophthalmoscopic lesions, namely, optic neuritis, neuroretinitis, thrombosis of the retinal vessels; and the like, that it is unnecessary to burden the paper with the recitation of cases similar to those which all of us have seen and studied. That an optic neuritis otherwise unexplained indicates thorough examination of the sinuses goes without saying; that it may manifest itself as an ordinary edema of the nerve-head, the so-called papilledema, or as an inflammatory optic neuritis, is well known, and that in many instances it is accompanied by central scotoma, as in Knapp's well-reported case of optic neuritis after ethmoiditis, and that all the symptoms will subside, and that vision may be restored to the normal standard after suitable treatment of the diseased sinuses, are facts with which all rhinologists and ophthalmologists are well acquainted. That in a certain number of cases the manifestation is that of a retrobulbar neuritis, with its well-known symptoms of obscuration of vision, beginning in the central field and

rapidly progressing to complete or nearly complete blindness, with at first negative ophthalmoscopic appearances and later blurring of the margins of the disc, diminution of the caliber of the retinal arteries, and pain on movement of the eyeball, is also well understood, and yet it is curious that, in the study of these affections, not infrequently the sinuses have been neglected. I am not speaking now in any criticism of our rhinologic confrères, but I am sure that every ophthalmologist present here today will testify that even after rhinologic examination has failed to detect sinus infection later investigations, or later results, have demonstrated in a certain number of these instances well-marked disease of the ethmoid or the sphenoid, and that sometimes this discovery has come too late to reach satisfactory therapeutic results.

It is not to these well-known cases that I wish to refer, but to those to which much attention has been paid in recent times, notably by Jessop, Fuchs, Birch-Hirschfield, Posey, Arnold Knapp, and a number of other observers, where, both with or without limitation of the peripheral visual field, there has been a scotoma, which may be relative, that is, present only for colored light, or more advanced and present for white light, while the ophthalmoscopic examination is practically negative, or at most there is a little blurring of the margins of the disc and pallor of its temporal surface. Now, as Mackay, in his well-known classification of sinus disease,* has said, further information in regard to the behavior of these scotomas is desirable, and, therefore, in illustration of what I am about to say I will put on record briefly the summary of the case history which follows:

A young woman, after a number of attacks of fugacious episcleral congestion over the external recti, with intense headache, during most of which time she was not under

* Archives of Ophthalmology, xxxvii, 1908, p. 720.

observation, reported to me during the height of one of these attacks with failing vision, $\frac{6}{30}$ in each eye, unrelieved and unimproved by glasses. The eye-grounds were normal. Searching general examination by her physician, Dr. Branson, and by Dr. John H. Musser failed to discover any constitutional cause for this condition of affairs. Vision continuing to fail, on December, 1907, the field presented ~~the character~~istics depicted in Fig. 1, namely, a delicate ring scotoma surrounding the fixing point in the left field, and a triangular paracentral scotoma in the right field. Some years

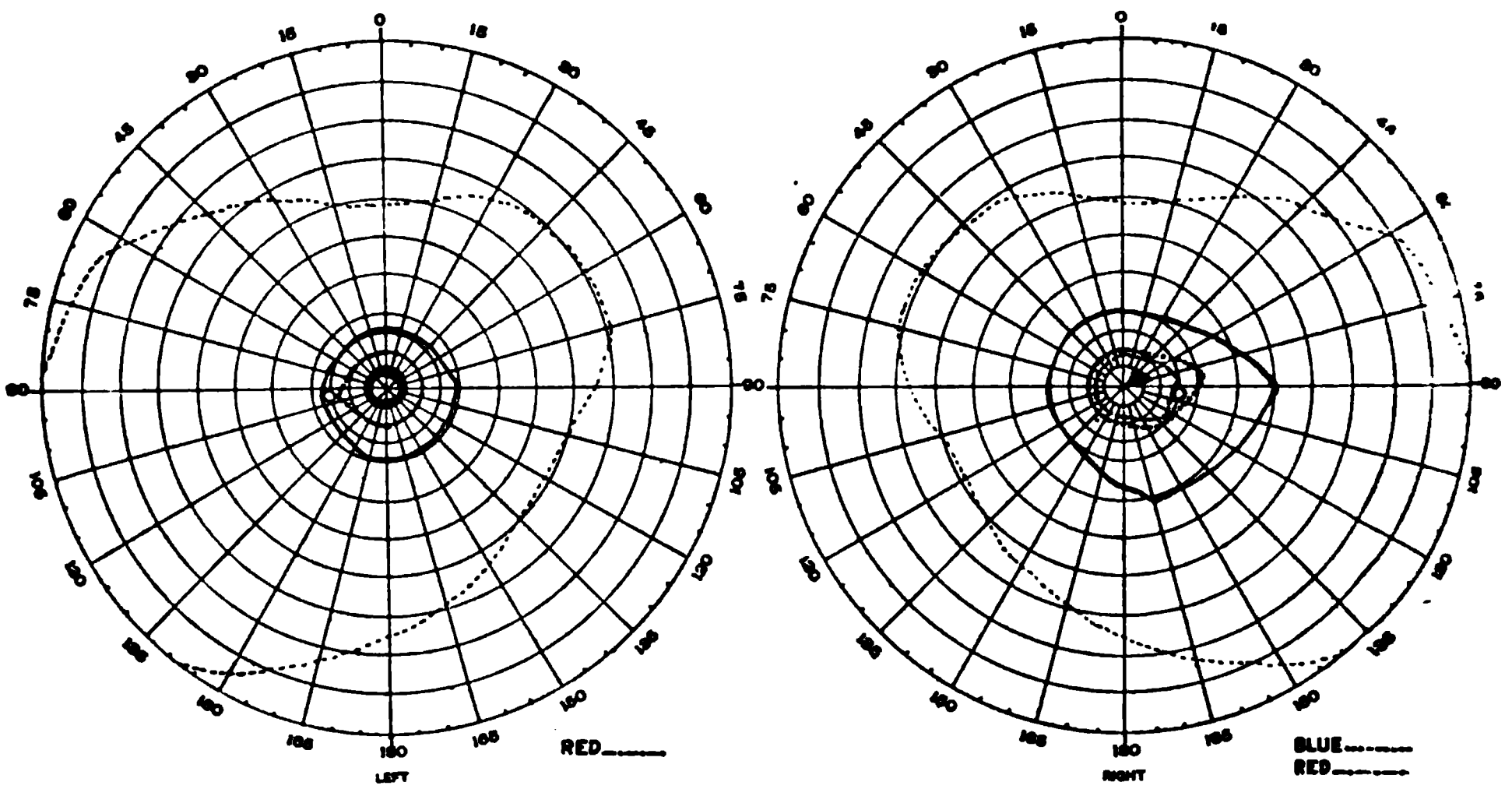

Fig. 1.— Left eye, ring scotoma. Right eye, triangular paracentral scotoma.

prior to these disturbances the patient had been treated by Dr. B. Alexander Randall for mastoiditis, which, however, had never reached a condition requiring operation. (At this period careful intranasal examinations were made by Drs. Randall and Risley, who were called in consultation, without discovering anything except a universal congestion, that is to say, there was no pus, no polypus, or no definite lesion indicating sinus disease, and yet all of us felt sure that some sinus affection was at the bottom of her difficulties. (The *x*-ray examinations did not positively give us the information which we desired. At my request the

sphenoid was catheterized, first by Dr. Randall and later by Dr. Freeman, who also saw the patient in consultation, and a small quantity of pus was withdrawn from the left sphenoid sinus, which gave us the first definite confirmation of the presence of deep-seated disease in this region.

Vision was now reduced to the ability to distinguish the largest type letters at a few centimeters from her eye, and the scotomas had increased in size and assumed a more central position. They, moreover, were distinctly better produced to the temporal side than elsewhere; in fact,

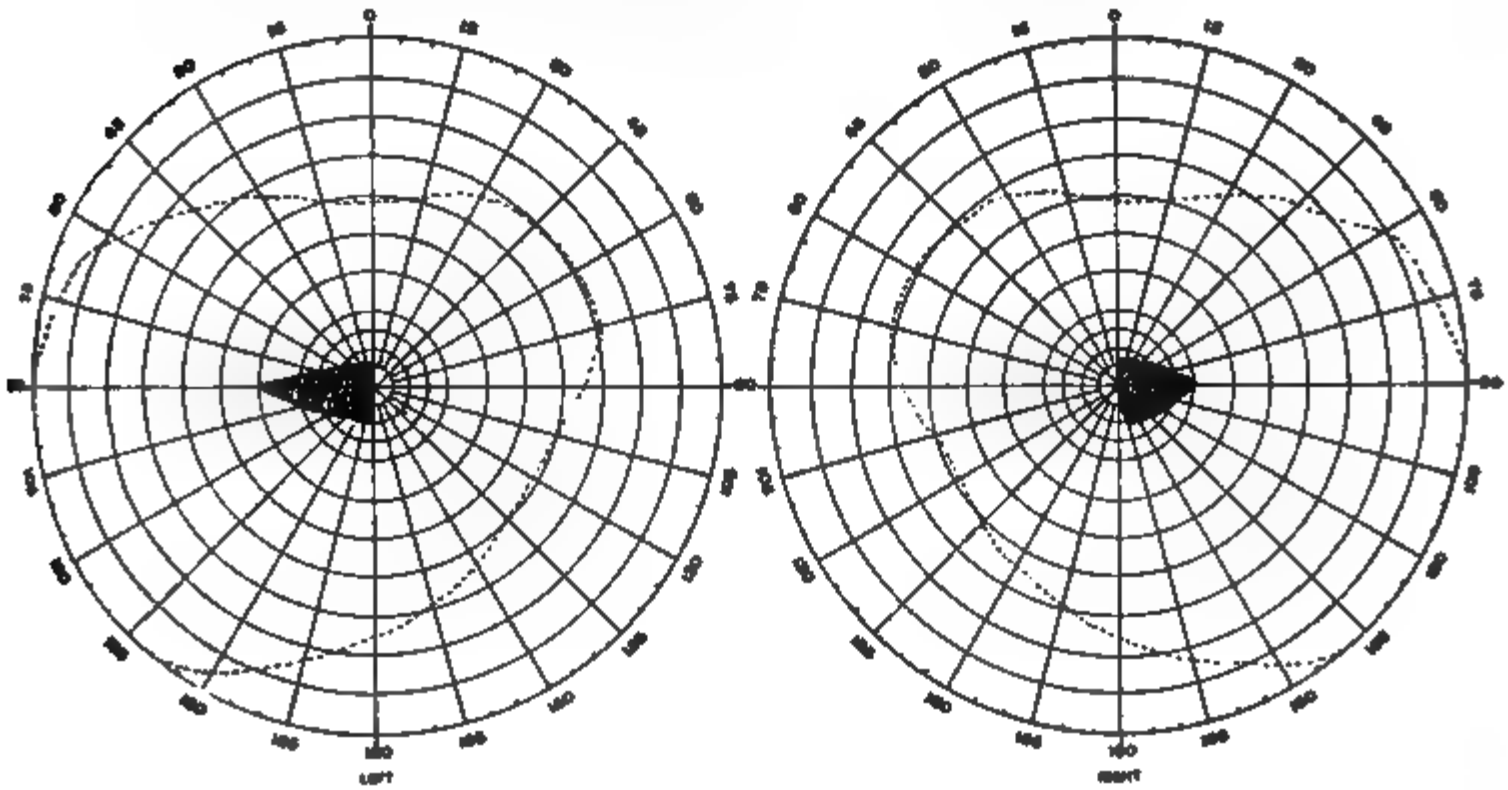

Fig. 2.—Hemianopic scotomas.

they appeared to be quite sharply limited to an area which is represented in Fig. 2. It was extremely difficult accurately to map the limits of these scotomas, owing to the patient's intense discomfort when she sat up or endeavored to fix her eyes on any given object. As far as could be ascertained, this wedge-shaped hemiopic scotoma was present for red and green and probably for blue. Over the scotomatous area a white test-object was recognized, but blurred in appearance. Exactly how long this type of scotoma lasted I cannot say, as the patient's condition was such that examinations of this character could only be made with

great difficulty and with great discomfort, but it probably lasted for a week or ten days—it may be longer. Vigorous treatment, consisting of hot vapor baths, the administration of small, repeated doses of protiodid of mercury, and suitable intranasal treatment, together with washing out of the sphenoid sinus at stated intervals, was followed by a measure of relief and by a slight improvement in vision, with a slight widening of the field of vision, so that the appearances were those which are depicted in Fig. 3; also scotomas in which there was not quite an obliteration of the white light sense, although it was markedly dulled.

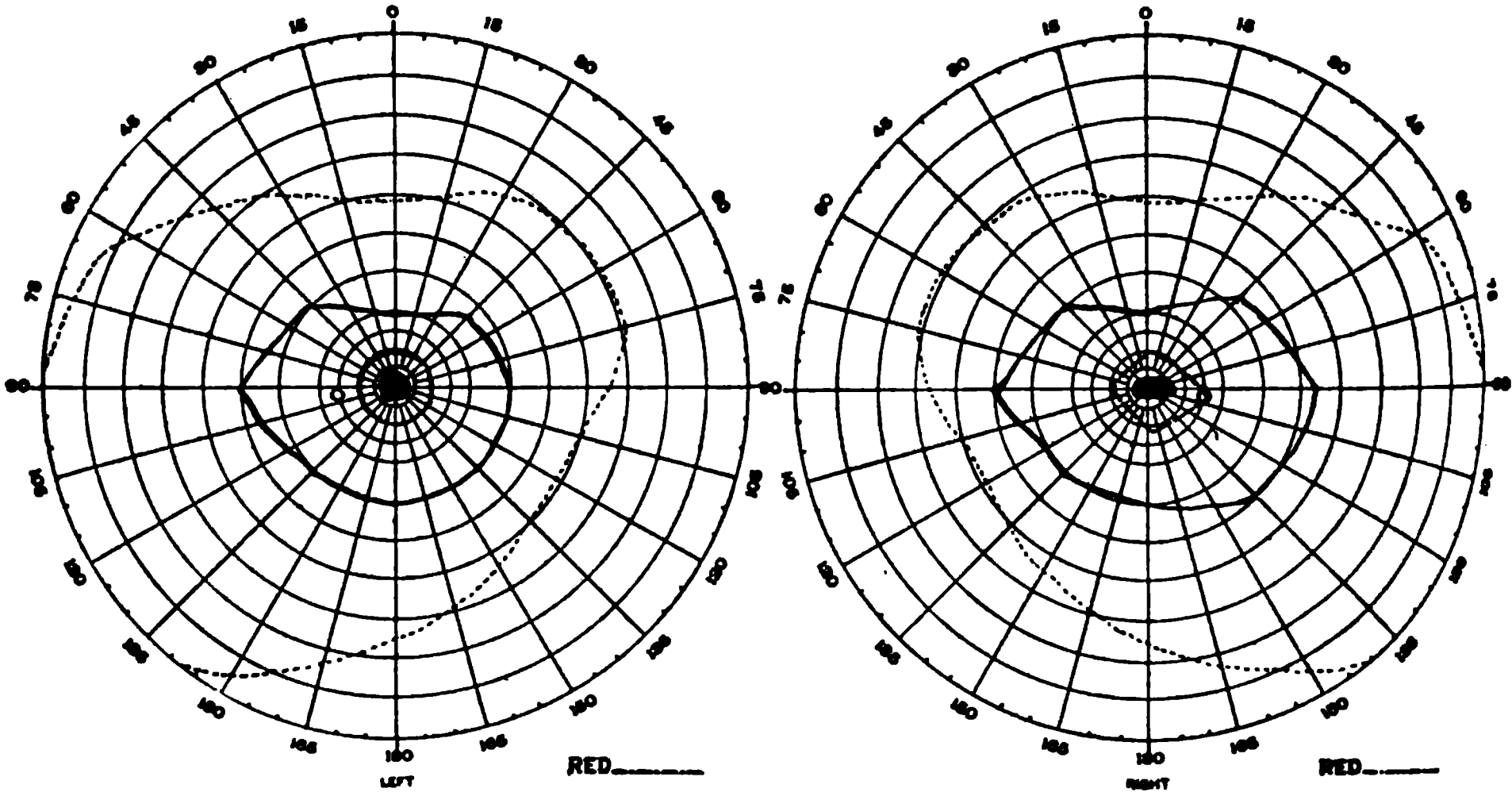

Fig. 3.—Central scotomas, nearly round in left field and oval in right field.

Gradually there was general improvement, the headaches subsided, and ultimately, after a residence of some months in Florida, the patient's general physical condition returned practically to the normal standard, but the vision, although improved, being now $\frac{6}{60}$, could not be raised beyond this standard; and a careful map of the field of vision, as shown in Fig. 4, indicated that there were large oval scotomas, still more produced to the temporal side than elsewhere, and not unlike those seen in toxic amblyopia. These scotomas were present for red and green, but the perception of white

light over the area seemed to be normal; that for blue, a little uncertain, but not lost. The field of vision was contracted, although its extent was wider than it had been when the first visual field was mapped. Headache had entirely disappeared, as had also the intense episcleral congestions, which were so marked a feature before the scotomas developed, and which continued during the earlier days of the patient's serious illness. Ultimately, after a year's residence in Egypt and other warm climates, the patient returned, apparently perfectly restored to health. The field of vision

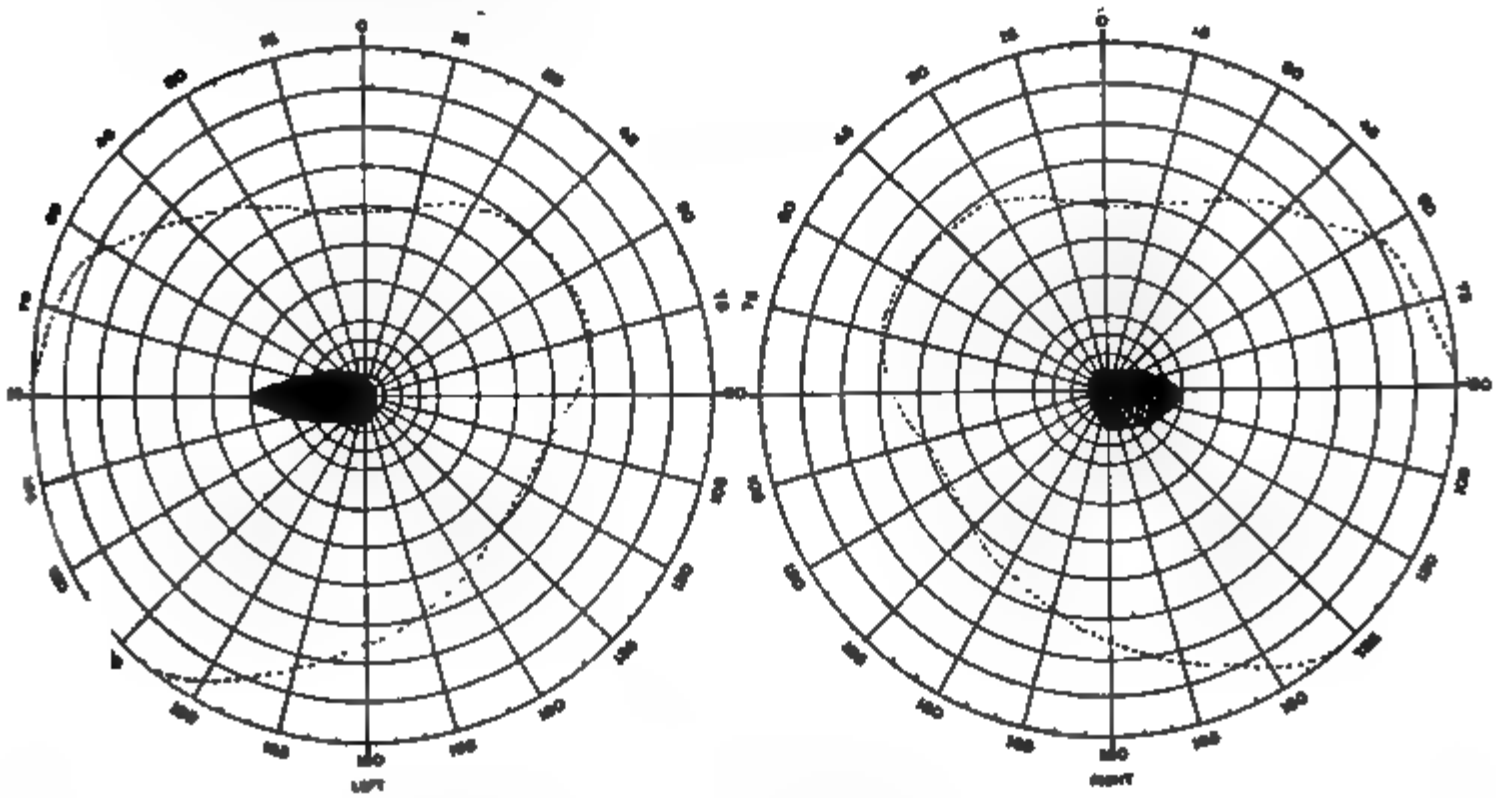

Fig. 4.—Oval central scotomas resembling those seen in toxic amblyopia.

is practically normal in size, although just at the fixing point there is a faint dulling of the perception for red and green, and the patient's vision has risen to $\frac{6}{2\frac{0}{5}}$ with suitable correction, and ordinary print is read without difficulty, the book being slightly tilted on one side. At no time during the period which has been described was there any positive alteration in the nerve-heads or in the retinal circulation, except that the retinal veins were somewhat fuller than normal, and that, during the period of intense headache and patchy episcleral congestion, there was the curious wrinkling of the corneal epithelium to which I have

made reference, and which was one of the reasons why an accurate map of the scotomas was difficult to make.

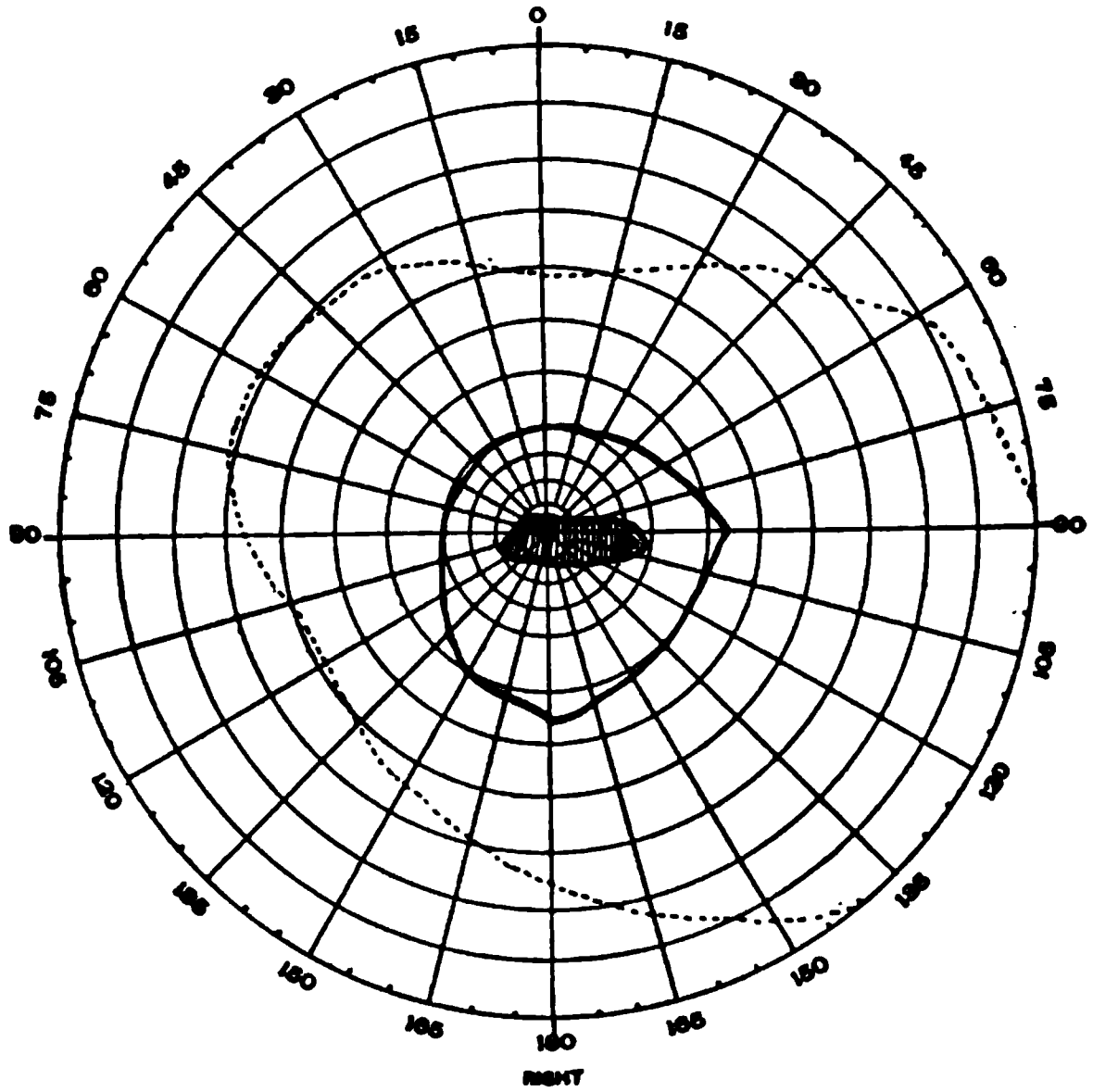

Fig. 5.—Oval scotoma in right field.

I suspect that the series of events in this case was as follows: A marked tendency to catarrhal inflammations of the nasal mucous membrane, aggravated on one occasion prior to the serious turn of affairs which preceded the sphenoid sinusitis by exposure during a mountain climb in the Adirondack region, and by the bad practice, already referred to, of nightly nasal sprays of some antiseptic solution, usually glycothymol. Later there was infection, probably, of the ethmoid, and certainly of the sphenoid sinus, and transference of this infection to the optic nerves. The earliest manifestation of this seemed to be—and I think this map of the field of vision may be regarded as fairly accurate—a ring-shaped scotoma in the left field and a wedge-shaped one in the right field, succeeded not long

afterward by the formation of the hemiopic type of scotoma, which somewhat resembles the field which has been depicted by Treitel.* In Treitel's field, however, the long axis of the scotomatous area is vertical, and not horizontal, as it is in the present field. Such paracentral or hemiopic scotomas have been thought to indicate a lesion confined to that point on the dorsal surface of the chiasm where the papillomacular bundles of the crossed fasciculus are interwoven, and it was this scotoma in my patient that made those in charge of her for a time believe that they might be dealing with something other than a sphenoid sinus affection, and that the chiasm itself was being involved. Indeed, chiasmal central amblyopia is, as we know, one of the symptoms of tumor of the chiasm, as, for example, in Nettleship's† patient, whose chiasm was incorporated in a cyst. These central scotomas in chiasm disease resemble in many particulars the toxic amblyopia scotomas. The distinguishing points, according to Nettleship, are that the loss of the central field in the earlier stages is more abruptly defined than in tobacco amblyopia, and the symmetry is less precise both in time and degree than in the latter disease.

If there was in this patient a patch of meningitis or other lesion that so pressed that temporarily it produced a paracentral or hemiopic scotoma, evidently it must have passed away, and ultimately the axis of the optic nerve was affected and the scotoma assumed the type which one finds under such circumstances, that is, nearly central, or central in the sense in which we use that term when describing the scotomas of intoxication amblyopia. That these changes were really due, in part, if not entirely, to sphenoid sinus disease seems definitely proved by the results of treatment, intranasal and irrigation of the sphenoid sinus, together with residence in a warm climate.

* Centralbl. f. prakt. Augenheilk., 1881, p. 320.

† Ophthalmic Review, xv, 1896, p. 309.

IMPLANTATION OF A METAL BALL IN TENON'S CAPSULE (THE FROST-LANG OPERATION), WITH REPORT OF 48 CASES.

WILLIAM M. SWEET, M.D.,
Philadelphia.

During the past six years I have performed the Frost-Lang operation of implanting a ball in Tenon's capsule in every instance in which removal of an eyeball was required, when no contraindication existed. The total number of cases was 48, with loss of the ball in 2 cases.

The reasons for the removal of the eyeball may be thus classified:

Twenty-two cases of injuries from foreign bodies: in 6 extraction failed, and the eye was at once removed; in 5 extraction was successful, but blindness with shrinkage of the globe ensued; and in 11 extraction was successful, but immediate or remote iridocyclitis developed.

Ten cases of punctured or incised wounds of the eyeball by sharp instruments or large pieces of glass or other materials.

Two cases of ruptured eyeball from blows.

Four cases of blindness with painful glaucoma, in one of which, a woman aged forty-nine years, a small choroidal sarcoma was found.

Four cases of corneal staphyloma, 2 in adults following gonorrheal infection, and 2 in babies, one eight months and the other twenty months old.

Four cases of dense corneal leukoma, the enucleation being performed for cosmetic purposes.

Two cases of necrosis of the cornea, 1 a man aged fifty, and the other a woman aged fifty-eight.

In 5 of the cases of injury there was evidence of sympathetic irritation at the time of the enucleation, with the injured eye tender upon pressure, and in 2 cases considerable photophobia. In every instance there was subsidence of the symptoms following the enucleation, and no reaction occurred from the insertion of the gold ball.

In 42 cases gold balls were implanted, the ball varying in size from 13 to 15 mm. The 14 mm. ball was the size most often adapted for adults. In 6 instances platinum instead of gold balls of the above sizes were substituted.

In the 2 cases in which the ball was lost an excellent stump was obtained, with considerable movement of the artificial shell.

The recognized advantages of the operation of implantation over that of simple enucleation are:

First: The stump in practically every case gives a more movable artificial eye than ordinarily follows simple enucleation. In some cases of enucleation in which the muscles have been sutured to the conjunctiva and care exercised to preserve all conjunctival tissue, an excellent movable prosthesis is secured, but the operator is not certain that this result will be obtained.

Second: The depression of the tissues immediately beneath the brow and the tendency to enophthalmos of the artificial eye are less marked.

Third: The floor of the orbit after healing is flat, with occasionally a slightly raised portion in the center where the implanted ball projects forward, a condition superior to the deep, furrowed, and often irregular socket for the retention of secretion that so often follows simple enucleation.

With the exception of eyes with malignant growths and those purulently inflamed, there is no contraindication to the operation of implantation. I do not feel, however, that the insertion of a gold ball after the removal of an atrophic stump is a satisfactory procedure, because all the tissues are

shrunken and even a small sphere must exert more pressure upon the orbital tissues than is the case after the removal of a full-sized eyeball. In the latter the capsule contracts and forms a firm envelop around the sphere, and the nerves are retracted beyond the reach of dangerous pressure. In the severe types of traumatic iridocyclitis requiring enucleation, even though the other eye has become irritated, there is, in my opinion, no greater danger of sympathetic ophthalmitis than if the ordinary enucleation was performed without a gold-ball implantation. I believe that should sympathetic ophthalmitis appear, it would have occurred no matter what operative procedure had been followed.

In 6 of the recent cases platinum balls, and in the other 42 gold balls, were implanted. Although it does not seem possible that the gold ball can be affected by the secretions of the orbit, I feared that they might become so, therefore a number of platinum balls were made with the intention of using this metal in future operations. As yet, however, I have not been able to secure balls of platinum as light in weight as those of gold. An *x*-ray plate of a case in which the gold ball was implanted six years ago shows the sphere intact and free from erosion. Most of the earlier gold balls used were composed of two half spheres soldered together, and the work was so perfectly done that it was impossible to see the point of joining. Recently the makers have cast the full ball around a central core, and the latter is removed through a small opening which is subsequently closed. In both instances the high heat to which the metal is subjected insures perfect sterility of the interior of the ball.

The method of operation followed does not differ in any important particulars from the usual methods that have been described.

After the conjunctiva has been dissected loose at the limbus, and the usual precautions to preserve all the structure have been observed, the four straight muscles are picked up

on the hook and stitched to the conjunctiva in the normal position or brought forward to the edges of the cut conjunctiva. After the nerve has been separated and the eyeball removed, hemorrhage is stopped by pressure of dry sterile gauze pads, and the upper and lower border of Tenon's capsule picked up with forceps, and the ball dropped into the cavity exposed. A stitch is inserted through the upper and lower edges of the center of the capsule and tied, one end of the thread cut off while the other is used to raise the capsule, in order that the sutures may be more readily inserted. From 6 to 8 will usually be required to join the edges of the capsule. Should any portion of the capsule be so thin that the ball shows through, a tuck of the adjoining tissues should be made and the thinned portion covered. The conjunctival edges are now brought together by interrupted sutures placed horizontally. A binocular bandage is applied, but no iced compresses are employed. At the dressing the following day the monocular bandage is used, and the patient allowed to get up. Should edema of the lids be present, cold formalin applications may be made through the light bandage.

The complications of the operation of implantation are claimed to be: (1) Swelling and ecchymosis of the lids; (2) escape of the ball; (3) displacement of the ball after healing; (4) sympathetic trouble.

(1) *Protracted Convalescence.*—The reaction following the operation of implantation is usually no greater than after simple enucleation. There is somewhat more edema of the conjunctiva, but this is to be expected, since the gold ball occupies a position in the orbit that would be taken up in the simple enucleation by the swollen conjunctiva. In the majority of instances the patients will have left the hospital within a week of the operation. In 5 cases of the series there was edema of the conjunctiva and swelling of the lids, but this was plainly the result of effusion of blood into the

orbital tissues. In these cases there was some difficulty in cutting the optic nerve, so that the blood from the severed orbital vessels probably percolated into the tissues before egress was permitted by removal of the eyeball. In none of these cases, however, was the gold ball lost, although the convalescence was protracted.

(2) *Escape of the Ball.*—In four of the earlier cases the central portion of the wound failed to unite, and the edges separated, exposing the ball. In the first, the exposed portion of the ball measured 8 mm. in diameter, and was first noticed on the sixth day. Believing that the ball would ultimately be lost, and in order to shorten the period of healing, an attempt was made to remove the ball by means of a hook, but the band of tissue surrounding the ball held so firmly and the patient complained so much of the pain that the attempt was abandoned. The edges of the wound were then touched with the mitigated silver stick, and this was repeated every second day for a week, at the end of which time the conjunctiva and capsule had granulated and completely covered in the ball. In the second case of separation of two of the central sutures, a like procedure was followed by the same gratifying result. Restitching of the conjunctiva over the exposed ball is useless, as the sutures cut out. Lang, in a case of threatened escape of the sphere, removed it, inserted one of smaller size, and brought the wound-edges together successfully.

In the two cases in which the ball was lost one was due to infection of the entire wound-edges and the sphere escaped on the third day. In the second the three central stitches cut out, and although attempts were made to stimulate granulations along the edges of the wound, the tissues would not cover in the ball, and it was removed on the nineteenth day.

(3) *Displacement of the Ball.*—In none of the cases has the ball shown an appreciable change in position. This complication is not so likely to occur in implantation at the time

of enucleation as in the operation of remote implantation, since the shrinkage of the capsule forms a firm envelop about the ball and holds it in the central position.

The tying of the severed ends of the four recti muscles in a bunch over the ball, as recommended by some operators, would appear to favor displacement of the ball by the subsequent contraction of the tissues and the forcing of the ball obliquely out of the muscle cone.

(4) *Sympathetic Disease.*—The most important consideration in the substitution of a method for the simple enucleation is the possibility that the introduction of a foreign substance in the scleral cavity, or in Tenon's capsule after the complete removal of the eyeball, may place the good eye in danger. In a majority of reported cases of sympathetic trouble following one of the substitute procedures for ordinary enucleation the operation was done upon injured eyes which, at the time, were the seat of an acute inflammation, and it is impossible to know whether the sympathetic disease would not have arisen irrespective of the nature of operative procedure. The published reports of sympathetic disease following Mules' operation would indicate that this operation is not without risk, and the same may be said to a less degree of evisceration in which the sclera remains, but no sphere is inserted. In the operation of implantation of a sphere in Tenon's capsule the entire eyeball is removed, and presumably all the structures concerned in the causation of sympathetic disease are absent.

Notwithstanding the several instances of sympathetic trouble in cases in which the operation of implantation of a ball in Tenon's capsule was performed, I do not think that in a single instance we can positively point to the implanted ball as the primary and exciting cause of the symptoms in the good eye. So far as I have been able to find, 5 cases of this character have been reported. The detailed history of these cases is as follows:

CASE I.—Reported by Cant.* Man, aged thirty, injured in outer ciliary region by a chip of steel. Extraction attempted ten days later, but failed. Patient refused enucleation until a month after injury, then globe removed and a glass ball inserted in Tenon's capsule. Other eye strong and healthy. Three days after operation the glass ball came out, owing to slight suppuration. The same day the good eye was weak and watery, and the next day slight iritis was manifested. This was followed by typical sympathetic ophthalmitis.

CASE II.—Reported by Lang.† Girl, aged seven, entered Moorfield's with right eyeball much shrunken, and had been so since birth. There were general pinkish injection, complete posterior synechia, atrophy of iris, and the lens opaque and shrunken. T.n. No. l.p. L. E., healthy. Excision and implantation of a glass ball in Tenon's capsule the day after admission to hospital. Pathologic examination of removed eyeball revealed considerable infiltration throughout uveal tract, increase of cells in optic nerve, and some inflammatory tissue in its sheath. No reaction after operation, and patient discharged eleven days later. Returned eight weeks after operation with iritis of L. E., total posterior synechia, *no keratitis punctata*. T.+2. Under treatment eye improved, but pupil excluded and occluded. In three years linear extraction. Examination six years later, V = fingers at 4 feet. J. 1 at 9 inches. T.n. R. E., socket healthy. Implanted ball displaced up and out.

In a consideration of the possibility of the implanted ball being responsible for the sympathetic disease in the above two cases, the English committee says: "In the first case the interval between the operation and the onset of the inflammation in the sympathizing eye, three days, is so short that we do not think it had anything to do with the onset of the mischief."

In reference to the second case, the committee says: "As the inflammation in the excised eye was apparently spontaneous and not the result of a perforating injury, that of the

*Report of Committee on Excision, Oph. Soc., United King., 1897.
†Ibid.

second eye may have been of a like nature." That the implanted ball was not regarded as the cause of the inflammation in the left eye would seem to be borne out by the fact that the glass ball was not removed, the history showing that it was still in the right socket, although displaced up and out at the examination six years later. I have given the history of these two cases in detail, as they have been quoted for years past as evidences of the danger of the implantation operation.

CASE III.—Reported by Suker. Sympathetic irritation developed after implantation, but was "cured by removal of the implanted globe."

This was the only case of sympathetic trouble in de-Schweinitz's* report of 72 implantation operations by 15 American operators, with the escape of the ball in 15 cases. No detailed history of this case is given, and presumably the operator attached little importance to it, as in a subsequent paper† on the value of the Frost-Lang operation he makes no mention of this case, and says: "It will be found that in these cases, where sympathetic irritation follows either scleral or capsule implantation, the wearing of a shell is frequently a sufficient cause for the reaction."

Since the summary of deSchweinitz, I have found only two instances of sympathetic trouble occurring in cases in which the implantation operation was performed, and this agrees with Gifford's analysis of the cases of sympathetic disease following the various substitute operations for enucleation.

CASE IV.—Reported by Sattler.‡ Injury from bird-shot, followed by a low-grade, painful iridocyclitis with recurrent hemorrhages. Enucleation and glass-ball implantation fif-

*Comparative Value of Enucleation and the Operations which have been Substituted for it. deSchweinitz, XIII. Internat. Oph. Cong., 1900.

†Trans. Amer. Acad. Ophth. and Oto-laryng., 1907.

‡Trans. Amer. Ophth. Soc., vol. x, 1904.

teen days after injury. Left hospital twenty-five days after operation. Shortly afterward complained of transitory dimness of vision, at first at long intervals, but becoming more and more frequent, finally resulting in complete helplessness sixty-two days after the original injury. The ophthalmoscope showed hazy aqueous and vitreous, deposits on Descemet's membrane, and typical papilloretinitis. The glass ball was removed and 2½ cm. of the optic nerve resected, the cut nerve being found firmly surrounded and embedded in dense cicatricial tissue. Forty days after resection of the nerve the papilloretinitis of the eye subsided and vision was restored to 0.6.

In Gifford's analyses* of the cases of sympathetic disease following the various substitute operations for enucleation he refers to the case of Sattler, but excludes it from a group of 7 cases to which he states that it does not seem reasonable to apply the explanation that the sympathetic ophthalmia might have occurred just the same even if a simple enucleation had been performed. It is difficult in this case to indicate the exact factor causing the sympathetic trouble. Whatever it was, the process was extremely slow, the attacks of dimness of vision not being accompanied by external inflammatory phenomena. It may be that the dense cicatricial tissue in which the cut optic nerve-trunk was surrounded and embedded may have been a factor causing the disease, or it is not impossible that the sympathetic disease may have started before the eyeball was removed, and slowly developed during the twenty-five days the patient was in the hospital after the enucleation, and in the three weeks following his discharge to the time his sight failed. It is hardly possible that the glass ball could have exerted pressure on the nerve.

CASE V.—Reported by Davis.† Implantation of a paraffin ball in Tenon's capsule one year before examination by

*Trans. Amer. Acad. of Ophth. and Oto-laryng., 1908.
†Section on Ophthalmology, Amer. Med. Assoc., 1907.

Davis. Comfort for ten months until the artificial eye began to turn in and the other eye became congested and painful and continued so for six weeks. Operation showed the paraffin to have escaped from Tenon's capsule and lodged in a solid mass at the posterior end of orbit. Upon its removal the symptoms disappeared.

The sympathetic irritation in this case was due, in the opinion of Davis, to the pressure on the optic nerve of the mass of paraffin which had escaped through an opening in the capsule made by faulty technic on the part of the original operator. It is possible that the irregular pressure and dragging on the orbital tissues by the displaced artificial shell was also a factor in the cause of the symptoms, the irritation being of a character similar to that which occurs in the sound eye from the wearing of a badly fitting artificial shell.

One case included in the series reported in this paper is of sufficient interest to warrant an extended notice:

Dr. J., while treating a patient in September, 1906, became infected in the left eye with gonorrheal pus. There was the usual intense conjunctival chemosis, with extensive corneal ulceration, and, after subsidence of the inflammation, dense scarring of the cornea. In December, 1906, staphyloma of the cornea appeared, with secondary glaucoma and perforation of the cornea. The globe was removed at that time, and a 13 mm. gold ball implanted in Tenon's capsule. No reaction after operation; the wound healed by primary union, and in three weeks the patient commenced to wear a reform artificial eye. There was no irritation of the stump, and he had perfect comfort in the use of the right eye until December, 1909, at which time he broke the artificial eye which he had worn for three years. He then secured a new prosthesis, and later two additional shells were made to order, but he found that any prolonged reading or close work was followed by pain in his right eye and considerable palpebral injection. Under rest of the eyes and local applications the irritation disappeared, to again return with the use of the eyes at close range. The artificial eye was as comfortable as the one previously worn; there was no discharge from the

socket nor congestion due to the wearing of any of the three new eyes, nor was there any tenderness upon pressure upon the implanted ball. The right eye was perfectly healthy, and vision equaled $\frac{6}{6}$. The irritation presented the characteristics of a catarrhal inflammation, with congestion of the lids and of the superficial conjunctival vessels, particularly over the external rectus and slightly over the internus, and extending to the limbus. The man's general health is good, although he is under a heavy strain with his private work and in operative work in a large general hospital connected with a big steel works.

I did not believe that the irritation of the right eye was in any way due to the presence of the implanted ball, nor did it seem possible that the comfortably fitting reform eye could cause the trouble. This was also the opinion of Dr. de-Schweinitz and Dr. Hansell, who examined him. It was recognized that the depression in the man's general nervous system through inability to do his close work, and the fear of serious disease to his remaining eye, would compel removal of the gold ball unless the cause of the trouble could be located and the symptoms relieved. Examination of the nose and throat and accessory sinuses was negative. Internal remedies were given to correct a possible rheumatic condition, a slight change was made in the axis of his astigmatic glass, and a weak convex lens was given in addition for near work to lessen accommodative strain, but little if any relief followed these measures. Two reform eyes were made of slightly less width and breadth than those previously worn, so as to relieve any possible pressure at the periphery of the socket, and, while he has been in much better health, and has gained in weight since his return home, there is congestion of the eye, but no pain, the morning following late hours the night before, particularly after smoking one or two cigars or reading fine print. The eye is not affected at all by operative work or general office work during the day. This is the latest report I have had, dated one week ago.

Measurements were made in many of the cases of the amount of movement of the artificial shell, and the average in 12 cases showed rotation upward of 23°, downward of 40°, inward of 21°, and outward of 19°. Little value can be placed upon measurements of rotation, as they depend so largely upon the shape and fit of the artificial eye. In several instances there was marked movement of the conjunctival bed and yet only moderate rotation of the artificial shell. In one case there was a difference of from 3° to 4° in the extreme excursion of two shells that were both comfortable and yet were slightly different in shape.

DISCUSSION.

DR. R. L. RANDOLPH, Baltimore: I agree with Dr. Sweet if I understood him to say that he would not introduce a ball after removal of eye for intra-ocular sarcoma. While we know that recurrence is a rare thing, if there happened to be any sarcoma cells in the orbit, anything in the slightest degree irritating might tend to the recurrence of the growth.

DR. A. E. DAVIS, New York: In the case of sympathetic irritation which I reported the eye had been enucleated following an injury, and a paraffin ball inserted into Tenon's capsule. The paraffin escaped from the capsule into the apex of the orbit, and pressed on the stump of the optic nerve, causing the trouble in the sound eye. All inflammatory symptoms in the sympathizing eye subsided after the removal of the ball of paraffin from the apex of the orbit.

DR. G. E. DE SCHWEINITZ, Philadelphia: Dr. de Schweinitz agreed with Dr. Sweet in his estimate of the value of this operation, which he had performed many times, and always with satisfaction, if he had used a gold ball, but not always with satisfaction if glass balls were used, a few of which had been extruded and one of which had become displaced. He regarded with skepticism the belief that after a proper operation of this kind there was danger of sympathetic ophthalmia, nor would he feel that it was improper to introduce a gold ball after an injury to an eye, especially in a child, for fear that such a ball might produce

sympathetic ophthalmia. If the modern views of sympathetic ophthalmia were correct, particularly the investigations of Professor Fuchs, he did not believe that the mere introduction of the artificial vitreous in the form of a gold ball was more likely to bring about a sympathetic ophthalmia than if such a ball had not been introduced, and certainly the cosmetic result was a far better one. This referred, of course, entirely to the introduction of a gold ball in Tenon's capsule and not to Mules' operation, and to such cases in which, although there had been injury, there was no complication in the operation or prior to its performance. He agreed with Dr. Randolph that, after a removal of an eyeball containing a malignant growth, it would be better not to introduce a gold ball in Tenon's capsule.

DR. S. LEWIS ZIEGLER, Philadelphia: There seems to be a great fear of sympathetic ophthalmitis after implantation, although but few such cases have been reported. I have seen one case in the service of a colleague, but I cannot now recall the details, as the case occurred several years ago, and I had charge only during the summer months, when this attack occurred. I recollect that I used massive doses of salicylate, and was able to gain control of the sympathetic disturbance. The subsequent history I do not know.

DR. THEOBALD: Was the ball removed?

DR. ZIEGLER: The implanted ball was not removed by me, owing to the prompt response to treatment and the simultaneous transfer of the case to the attending surgeon.

DR. E. V. L. BROWN, Chicago: I think Dr. de Schweinitz's statement that after enucleation there is no tissue left that can cause sympathetic inflammation should be modified. Fuchs reports that large episcleral nodes of cell infiltration extend along the vessels and nerves through the sclera from the choroidea. If this tissue is left in the orbit after the eye is removed, part of it would bear the same relation to recurrence that it does in sarcoma. The irritation of the ball might produce further proliferation of this tissue.

DR. S. D. RISLEY, Philadelphia: It seems to me that the case referred to by Dr. Sweet in his closing remarks

should not be put upon record as a definite case of sympathetic irritation.

DR. WILLIAM M. SWEET, Philadelphia: In reply to Dr. Randolph, time did not permit the reading of the entire paper, and the presence of intra-ocular growths is one of the contraindications to the operation mentioned. In the one case of choroidal tumor in which a gold ball was implanted the growth was extremely small, and was only found after the eyeball had been removed. There has been no orbital symptoms since the operation, over a year ago.

I agree with Dr. Risley that the one case in the series in which some irritation has been experienced in the use of the eye following the operation cannot be regarded as an instance of sympathetic trouble due to the implanted ball.

REPORT OF TWO CASES OF CHRONIC CYANOSIS WITH POLYCYTHEMIA, INCLUDING OPHTHALMOSCOPIC EXAMINATION.

WALTER R. PARKER, B.S., M.D.,

AND

GEORGE SLOCUM, M.D. (BY INVITATION).

Detroit, Mich.

The comparative infrequency of reports of cases of chronic cyanosis with polycythemia, accompanied by a detailed description of the fundus, has led the authors to report a case that has been under observation for the past three years, together with a second case that has been under observation only during the past two weeks. The first case occurred in the service of Dr. George Dock, in the medical clinic of the University of Michigan, and was reported by Dr. Smithies in a paper entitled "The Clinical Aspect of Tumors of the Mediastina,"* and we are indebted to this report for notes on Case I, with the exception of those on the eyes, which were made in the ophthalmologic

* Jour. Amer. Med. Assoc., September 12, 1908.

clinic. Case II presents itself in the ophthalmologic clinic for relief of intense frontal and occipital headaches, accompanied by difficulty in use of eyes.

CASE I.—This case presents the clinical picture of chronic cyanosis, with variable polycythemia; splenic enlargement; attacks of asthmatic dyspnea; albuminuria; involvement of the mediastinal tissues, as shown by symptomatic, physical, and radiographic examination.

Patient, male, aged forty-three, American laborer. Entered the Medical Clinic in January, 1907. He complained of difficulty in breathing, palpitation, frontal and occipital headaches, chronic cyanosis, dropsy, and general weakness.

Family History.—Negative.

Personal History.—Up to the age of thirty the patient had enjoyed good health. At this time he began to have asthmatic attacks, coming on at irregular intervals, usually at night. The patient's habits were good, and there was no history of specific disease. About six years before entering the hospital he had what he termed a severe attack of "asthma," which lasted for a few moments, during which he became unconscious. About four years ago he noticed blueness of the face, hands, and feet, with variable swelling. He took medicine at this time and believed that the blueness had about disappeared. It did not again become marked until September, 1906. At this time the blueness increased, becoming especially marked when he worked or when he was excited, while palpitation with dyspnea became a prominent symptom. He began also to suffer from severe frontal headaches and dizziness, and his eyes became prominent.

Examination.—This revealed a man of medium build, with no pronounced evidences of emaciation. Over the face and neck, particularly the nose, chin, lips, and ears, there existed a startling degree of cyanosis. The hands and feet were moderately blue, particularly when the patient stood or allowed his arms to hang down. The cyanosis was less marked when he was in the recumbent position. Exercise and psychic disturbances deepened the color perceptibly. The palate and tongue were deep purple. The eyes were prominent, especially the right eye, which protruded 6 mm. further forward than the left. The con-

junctivæ were suffused—the right more than the left. The pupils were of moderate size, an anterior synechia in the left eye making comparison difficult. Over the trunk the skin had a bluish cast. The respiration became rapidly accelerated on even slight exertion. The heart-beat was faintly visible on the fifth interspace, well inside the nipple. Its rate was not increased. The lungs showed signs of emphysema.

Auscultation of the Heart.—All sounds were heard with difficulty. The first sound at the apex was heard best two finger-breadths inside the midclavicular line, in the sixth intercostal space. The sounds over the base were best heard in the fourth left space and beneath the adjacent sternum. The first sound at the apex was soft and somewhat impure; the pulmonic second sound was moderately accentuated. The radial pulse was slow, of moderate size, and fuller on the left than on the right. There was moderate sclerosis of the radials. The blood-pressure varied with the side tested. On the left the pressure was—systolic, 156 mm. Hg; and the diastolic, 109 mm. On the right, the systolic pressure 146, the diastolic 98, with the Erlanger apparatus 12 cm. cuff.[1]

The liver was felt with difficulty at the end of inspiration. The spleen was not palpable in whatever position the patient lay. (Later the spleen became enlarged.)

Blood Examination.—At time of entry the red-cell count was 6,540,000. The hemoglobin was 100 per cent. plus. The white cells were about 6500. The blood was very deep red, flowed slowly, and was extremely viscous. It was spread on a slide with great difficulty. There was nothing peculiar about the shape or the size of the red cells. The differential white count was as follows: Small lymphocytes, 14.8 per cent; large lymphocytes, 3.8 per cent; polynuclears, 67.6 per cent; eosinophile polynuclears, 3.8 per cent; mast cells, 1.6 per cent; and degenerates, 8.4 per cent. Recently an estimation of the specific gravity of the blood by Hammerschlag's method was 1062, when the red-cell count was 7,400,000. The coagulation time was difficult to estimate with the pipet method, because of the extreme viscosity of the blood. By the slide method coagulation was frequently complete at the end of a minute

in an ordinarily warm room. It was often less than this. Unfortunately, no estimation of relations between corpuscles and plasma was made.

Urine.—This contained a moderate amount of albumin, with many small, finely and coarsely granular casts and numerous cylindroids.

Fluoroscopic examination and radiogram revealed a non-pulsating shadow, evidently filling the mediastinum, that was thought might be a tumor.

In the summary of his report Dr. Smithies states: "It is not quite determined that the two conditions (referring to mediastinal growth and chronic cyanosis with polycythemia) do not exist, but in view of the rather marked variations in the cyanosis and the red-cell count, it is probable that much of the polycythemia is due to extensive pressure in the thorax on the great vessels." The subsequent history, however, has made this less probable than at first appeared to be the case.

Subsequent History.—Under rest and treatment he improved and was soon up and about. Part of the time the cyanosis diminished, when the patient would be fairly comfortable and able to do light work. If he worked hard or became excited, the cyanosis became more pronounced, and he complained of feelings of fullness in the chest, with difficult breathing. Occasionally the cyanosis became extreme and was associated with unconsciousness, stupor, or apathy; disturbances in vision; paroxysmal headaches; albuminuria, and gastro-intestinal symptoms. In all, 17 such attacks were noted. At times the color of the face and extremities was a dusky, slaty purple, while over the trunk the skin had a bluish cast. With the occurrence of the cyanosis the patient suffered extreme dyspnea, which sometimes lasted for but a few minutes, then again persisted for half an hour or longer. During the attacks the heart-rate was accelerated, going as high as 130. The peripheral vessels were greatly injected.

Disturbances in Vision.—At times there were merely spots before the eyes, with blurring of vision. On one occasion there was diplopia.

Eye Examination.—Vision, O. D., $\frac{20}{100}$; O. S., $\frac{20}{50}$. Both eyes prominent and injected, more marked in right. Pupil

O. D. moderately dilated and active. Scar at inner limbus, O. S., to which iris was attached.

Description of Fundus.—Ophthalmoscopic examination erect image. Media clear; connective-tissue ring present, broadest on temporal side; all somewhat blurred. The general color of the disc is a shining, yellowish red. Deep, cone-shaped physiologic cup. The nasal half of disc is veiled and edematous, over which numerous minute vessels trace. The ascending artery to nasal retina divides at the disc margin into two branches, the upper being slightly tortuous. Where this branch crosses the ascending nasal vein it is slightly blurred, and the vein beneath appears blurred in the edematous retina. The ascending temporal artery has three or four fusiform dilatations between the disc margin and the first branch. It is not tortuous in its outer portion. The inferior temporal artery at its origin passes well above its corresponding vein, and pursues a slightly tortuous course outward and a little downward.

All the veins are markedly tortuous and dilated. The descending nasal is nearly hidden at its origin in the swollen disc margin. The inferior temporal vein is similarly blurred, both on the disc and at a bend nearly a papilla's breadth below, where it dips down into the retina. On a branch of the superior temporal vein, well without the macula, is a small aneurysm of globular form and pedunculated. Many of the smaller veins are exceedingly tortuous, and many are unusually abrupt as they come into view. The arteries pulsate distinctly. Venous pulsation is absent.

The general color of the retina is of a deeper red than is usual in a blonde, and the usual details are absent, owing to the edematous condition present.

The macular region is edematous and slightly deeper in color than the surrounding retina. The foveal reflex is present.

One of us (Dr. Slocum), when examining the fundus one week after noting the presence of the small aneurysm, observed that it had ruptured, and in its place was seen a small, rounded hemorrhage, having about four times the area of the aneurysm. This absorbed in a few days, leaving no trace behind. A second small venous hemorrhage

was noted, three discs in diameter, up and out, on a small branch of the superior temporal, which enters from above.

Since leaving the hospital in January, 1908, the patient has been more comfortable than for two years previously to that time. He has had no periods of unconsciousness. While subject to attacks of increased cyanosis with dyspnea and general weakness, he has been able to run a peanut wagon about half the time. The fundus of the eye has all the characteristics seen in the drawing, but not to so great a degree. April 26, 1910, the vision in each eye was $\frac{6}{9}$ pt. The fusiform dilatations on the arteries had nearly disappeared. Exophthalmos: O. D., 21 mm.; O. S., 19 mm. Tension: O. D., 25 mm. Hg; O. S., 17 mm. Hg.

We are indebted to Professor Hewlett for the following report (April 28, 1910): "Heart is enormously dilated. Lower portion of the chest is retracted and immobile. The abdomen is prominent, but there is no ascites. The spleen is just palpable. The lungs show signs of emphysema, with very little bronchitis at the present time. There is moderate edema of the legs. *Blood:* Red blood-corpuscles, 7,200,000; white blood-cells, 10,320; hemoglobin, 120, per cent. Dare; blood-pressure, 136."

CASE II.—This case presents the clinical picture of chronic cyanosis with polycythemia, enlargement of the spleen, severe headaches, marked dyspnea, and general weakness.

Patient, male, aged thirty-one, American farmer. Entered the ophthalmologic clinic of the University Hospital April 24, 1910. He complained of severe frontal headache, blurring of vision, and diplopia, associated with extreme general weakness.

Family History.—Father deaf and subject to attacks of vertigo. Otherwise negative.

Personal History.—Always well until one year ago, when he suffered from severe frontal headaches, numbness in the fingers, tinnitus aurium both ears, and great general weakness. Has dyspnea most of the time, and an occasional attack of diplopia and blurred vision, accompanied by vertigo. One year ago first noticed blueness of skin, most marked on ears, nose, lips, and finger-tips.

We are indebted to Professor Hewlett for the following report:



Chronic Cyanosis with Polycythæmia

Patient shows ordinary distribution of a general cyanosis. Lungs negative. Heart moderately enlarged, but no signs of valvular disease. Blood-pressure, 165. The spleen is easily felt one inch below costal margin on deep inspiration. Liver not enlarged. There is a slight general glandular enlargement. Red blood-corpuscles, 8,000,000 to 9,000,000; white blood-corpuscles, 14,000; hemoglobin, 110 per cent.

Differential blood count: Small lymphocytes, 2.2 per cent.; large lymphocytes, 3.2 per cent.; transitional and polynuclear, 87 per cent.; eosinophile-polynuclear and mononuclear, 1.6 per cent.; myelocytes, 1.4 per cent.; mast-cells, 0.8 per cent.; degenerates, 3.8 per cent. One normoblast and one megaloblast seen. Some irregularity in reds, but not marked.

Eye Examination.—Vision, O. D., $\frac{6}{7.5}$; O. S., $\frac{6}{9}$. Pupils equal and active. Reflexes normal. Muscle excursion normal. Esophoria for distance 6°, orthophoria for near.

Ophthalmoscopic examination: O. D., media clear; margin of disc blurred. Hyperemia of retina, and edema around disc. Veins much engorged, tortuous and dark in color. Slight arteriovenous compression. O. S., media clear. Margin of disc more blurred, but retina not so hyperemic as in O. D. Veins much engorged, tortuous, and dark in color. Arteries not increased in size, but slightly tortuous.

The history of these two cases is quite similar to those heretofore reported. In the year 1892 Vaquez* reported a typical case, but without an ophthalmoscopic examination. Osler,† in 1903, reported four cases, and added five cases from the literature. He emphasizes the statement of Soundby and Russell, to the effect that in this group of cases we have "a definite clinical entity, and one which is new to medical science."

The condition is sometimes spoken of as the Osler-Vaquez disease.

Three years ago Jackson‡ presented before this society

* Bulletin Med., 1892, vi, p. 849.

† Amer. Jour. Med. Sci., August, 1903.

‡ Ophthalmology, October, 1907.

the report of a case with the ophthalmoscopic appearance. He also reviewed the findings in all the published cases in which an ophthalmoscopic examination had been made.

According to Glaesner,* the three symptoms that go to make up the symptom-complex of chronic cyanosis with polycythemia are cyanosis, polycythemia, and enlarged spleen. The cyanosis is the symptom that attracts most attention. It is most marked about the face and hands, although the whole body may be of a bluish cast. The color of the lips and tongue is well described by Jackson, who compared it to that of a ripe Concord grape. All observers have noted not only the dark color, but the thick and sticky character of the blood. The reds are greatly increased in number; the maximum blood-count is reported by Cabot† —12,000,000 per c.mm. The percentage of hemoglobin in the majority of cases varies from 120 to 165, although in Koster's‡ case it showed 240 %.

The enlargement of the spleen is present, as a rule, but may be wanting.

In all cases where the fundus findings are reported the change appears to be limited to the engorgement of the veins, with its consequent edema of the retina, with occasional hemorrhages.

Uthoff, who reported a case before the Heidelberg Congress in 1906, emphasized the importance of an ophthalmic examination in every case, believing that this disease in its milder forms is much more common than is generally supposed.

The pathology is still obscure.

* Wien. klin. Woch., 1906.
† Boston Med. and Surg. Jour., March, 1900.
‡ Wien. med. Woch., 1904.

THE NERVE-HEAD IN WOOD-ALCOHOL AMAUROSIS.

PERCY FRIDENBERG,
New York.

Blindness, sudden and complete, from the ingestion, inhalation, or even external application of methyl-alcohol is become increasingly familiar to the ophthalmologist. Cheap whiskies are largely adulterated with, and many fluids used in the household and in useful arts, such as essences, tinctures, varnishes, are composed more or less of this poison. Repeated indulgence is not required, as in ordinary spirits, and even a single dose may cause total loss of sight. The history is not always clear. In the acute stage an account of "spoiled stomach," vomiting, delirium, and sudden, complete and bilateral blindness, may aid us. The factor of drinking is often suppressed completely. If we can recognize a characteristic fundus condition as pathognomonic of changes in the nerve due to wood-alcohol, the diagnosis would be assured. Study of the nerve-head in a series of proved cases has convinced me that we have, at least in the later atrophic stage, a picture which is produced by no other agency. The nerve-head shows a deep excavation, extending almost to the scleral ring, and, at times, including it so as to simulate a glaucomatous cup. The color is never of the gray-green seen in the latter condition, but pure white, and at times silvery or glistening. The excavation shows distinctly the mottled markings of the lamina cribrosa, and there is generally no trace of connective tissue in the depth. This is the more striking as the atrophy in wood-alcohol amaurosis is undoubtedly a post-neuritic atrophy, and there is

always evidence of a previous neuroretinitis about the central vessels and in the retina immediately surrounding the nerve-head. This consists of fine perivascular striæ, irregular accumulations of pigment adjoining the choroidal ring, and, not infrequently, an atrophic ring or crescent somewhat like the glaucomatous halo. This combination of deep excavation, white atrophy, unobstructed cup, and extrapapillary connective-tissue changes is found in no other condition. From what we know of the clinical history and the probable histo-pathology of wood-alcohol amaurosis, we may infer that the acute neuroretinitis goes on to atrophy so rapidly that there is no time for connective tissue to block up the lamina cribrosa and fill the cup, while nerve degeneration is so marked and complete as to cause not only a saucer-like atrophic excavation, but a deep, pseudo-glaucomatous cupping. Occasionally perivascular connective tissue or pigment may be seen at the bottom of the cup, but this is exceptional. The picture is so striking and peculiar that it enables us, I am convinced, to make a positive diagnosis without depending on the patient for anamnestic corroboration. This typical appearance has not been hitherto described, as far as I am aware.

Two points may still be referred to. They concern the appearance of the disc in the early stage of wood-alcohol poisoning, and a suggestion as to the chemical constitution of the toxic agent which is active in methyl-alcohol. In the acute stage the discs may appear intensely red and somewhat blurred. This appearance has been observed repeatedly. The condition of neuritis is, however, transient and very soon passes over into a marked papilledema in which the disc appears swollen, prominent, soggy, and white, the veins large and tortuous, and the arteries rather narrow. This appearance, also, I believe to be characteristic of the early stage of optic-nerve degeneration with strangulation. Other pathologic conditions which cause marked papillitis

are invariably attended by symptoms of increased intracranial pressure, which in wood-alcohol poisoning is absent. I know of no other toxic agent which produces intense edema of the optic nerve followed by rapid and complete degeneration, so that the picture of choked disc *with sudden and complete blindness*, which again is rarely seen in the ordinary "transferred" papillitis of intracranial disease, unaccompanied by signs of increased intracranial pressure, seems significant of poisoning with wood-alcohol.

As to the nature of the poison actually concerned, I wish to venture the suggestion that it is not alcohol itself, at all, but a decomposition product of incomplete oxidation, in the form of an aldehyd, as formalin or formaldehyd. This idea suggested itself to me by association of the clinical facts of formalin action and my memory of the chemistry of this aldehyd, and of the lecture-room experiment in which it is produced from alcohol by incomplete combustion. This is accomplished by lighting an alcohol lamp and having a coil of copper or platinum wire heated red hot wound about the neck, so that the alcohol fumes pass through the incandescent ring. We know that formalin produces intense edema, even in very weak solutions, that it is a virulent protoplasmic poison, destroying microbic and cellular life in solutions of 1 : 2000 or less, and that it has a most marked astringent action. It is for the latter action, indeed, that formalin is used in pathologic laboratories, preserving and markedly shrinking tissues. That this agent or some other agent than some one of the alcohols was involved in wood-alcohol amblyopia was further suggested by the marked difference, clinically and ophthalmoscopically, between poisoning after ingestion of this agent and that observed in the ordinary amblyopia *ex abusu* or toxic alcohol amblyopia, the evident virulence of the poison, and the marked effect, after even a single small dose, on the optic nerve. It was hard to believe that an ordinary

alcohol could produce such marked edema, and be followed by such rapid and complete destruction of nerve tissue. It is not at all improbable that some, at least, of the toxic effects of *unadulterated* ethyl alcohol are due, not to direct toxic action, but to the action of alcohol as a food, causing a reduced metabolism and elimination of other food factors and so disturbing nitrogen balance as to cause a decided autointoxication. This is borne out by the therapeutic experience of De Schweinitz and others whose cases of toxic amblyopia due to tobacco and alcohol improved rapidly and regained good vision without medication when alcohol and tobacco were withdrawn and the gastro-intestinal tract cleaned out. This rapid and beneficial effect of diet and metabolic hygiene is a further distinguishing feature as against wood-alcohol poisoning which appears to be quite independent of any actual gastro-intestinal or metabolic disturbance. This view is in no way invalidated by the fact that there is frequently, in fact almost invariably, a history of acute gastritis and vomiting in the first stage of wood-alcohol poisoning. This shows quite clearly, I think, that the real poison in these cases is an actually corrosive one. Ordinary alcohol, even in concentration and in large quantity, does not usually cause vomiting, especially in habitués. My hypothesis, then, is that so-called "wood-alcohol amaurosis" is due to intense edema with some neuritis, followed rapidly by optic nerve atrophy, and due to formalin or formic acid circulating in the blood as a result of incomplete combustion of methyl-alcohol ingested, inhaled, or otherwise introduced into the system.

As to the possibility of such vital or biologic production of formalin in animal tissue by so-called alcoholase, I find a number of references in recent chemical literature. Battelli and Stern,* at the physiologic laboratory in Geneva,

* Production d'aldehyde dans l'oxydation de l'alcool par l'alcoolase des tissus animaux. Comptes Rendus d. l. Soc. d. Biol., tome lxviii, No. 1, 5, 1910.

showed that the liver of various animals contains a ferment, which they named alcoholase, with the property of oxidizing ethyl alcohol into acetic acid. Following up this observation they found that ethyl aldehyd was also produced in the course of this chemical change. The quantity of aldehyd varied according to the animal species, being great in horses, cattle, and sheep, but small in man, dogs, and rabbits, and, according to the alkalinity of the medium, being greatest at a concentration of 1: 1000 NaOH. Aldehyd is formed, similarly, if the alkaline solution is replaced by blood or serum. It is a question whether the further reduction of aldehyde is due to continued action of the hepato-alcoholase of Battelli and Stern, or whether there is a second ferment, an aldehydase, concerned, which decomposes this substance into acetic acid. The authors call attention to the fact that these observations are in accordance with the original theory of Liebig that alcohol passed through the stage of aldehyd in its oxidation within the organism. This was doubted mainly because aldehyd could never be found in the expired air, nor in the tissues after the administration of pure ethyl alcohol. In man and in health, most pure ethyl alcohol is oxidized by a still unknown process, but undoubtedly part is converted into aldehyd. It is not at all improbable that methyl-alcohol may be more rapidly and easily convertible into formic aldehyd or formalin, especially in the presence of an acute gastritis, with the coincident disturbances of metabolism and gastro-intestinal chemism.

DISCUSSION.

DR. E. V. L. BROWN, Chicago: At a meeting of the Chicago Ophthalmological Society, held March 21, 1910, I reported a case of this type under the heading "Glaucomatous Cupping of Both Discs, with Amaurosis, Possibly from Methyl-alcohol." The form of the excavation was unmistakable, and the history of poisoning clear, yet I

feared that the cupping might be due to simple glaucoma and the poisoning merely coincident. I therefore studied the tension with special care for nearly a year, without ever finding it increased, and in connection with the discussion of the subject I would like to rereport my case:

F. P., age fifty-six, consulted me February 16, 1909. For three years part of the patient's work had been to draw 5 or 10 gallons of wood-alcohol from a large barrel each week. One day, two years before entrance, he spilled a gallon or so of alcohol down his leg, soaking his clothes and filling his shoe. He allowed the clothes to dry without changing them, but soon became dizzy and went home. He returned to work the next day, but again had to leave for home and go to bed on account of dizziness. Four hours later he awoke to find himself completely blind. Vision, however, gradually improved from day to day, so that four months later he considered returning to work, but his vision again got worse in the fifth, sixth, and seventh month, and has practically not changed since then.

Two years after the onset one finds vision in each eye reduced to light perception, and light from any direction projected into the temporal fields. The anterior chambers are of normal depth. The pupils are 5 mm. and almost fixed to light, although eserin narrows them to 2 mm.

The *right disc* is surrounded by a narrow ring of exposed sclera, which is completely bared of its pigment epithelium and choroidea; this atrophy is narrowest nasal and widest temporal, where it measures about $\frac{1}{6}$ of a P. D.; here (temporal) the border between bared sclera and choroidea is not sharp, because some large vessels have escaped atrophy. The entire nasal half and the upper outer quadrant of the disc, between axis 115° and 270°, shows an ampulliform excavation, in the sense of the word used by Fuchs (Lehrbuch d. Augenheilkunde, 11te Auf., p. 452, 1907), namely, a deep excavation, which is total, *i. e.*, extends to the very edge of the disc. All the large vessels are found in the upper nasal one-third of the disc, and disappear behind the overhanging edge of the scleral ring, to reappear upon the surface below. The difference in level between the scleral ring and the floor adjacent is $3\frac{1}{2}$ D. The disc is markedly concave forward from a very uniform backward

vaulting. Its surface slopes up gradually to the scleral ring in the temporal and temporo-inferior quadrant, and the transition to the level of the scleral ring is everywhere to be seen. The disc is clear bluish and white in color; blue predominates, but is everywhere crossed and checked by an almost equal amount of irregular screening of white; no physiologic excavation or vessel funnel can be made out.

The *left disc* shows the same narrow ring of circumpapillary atrophy. Here, too, in the nasal half and in the outer upper quadrant, between axis 60° and 270°, the nerve-head shows a total and deep (ampulliform) excavation; all the vessels except a few small branches are displaced into the nasosuperior two-fifths, and disappear beneath an undermined scleral ring, to reappear on the floor of the disc. The difference in level between the scleral ring and the floor is 2 D. In the temporal half the disc slopes gradually forward to the level of the scleral ring. The color of the left disc is the same as that of the right, although the white markings are only found in the nasocentral one-half of the cup, and are larger and longer. No central physiologic excavation or vessel crater is present.

Both fundi outside the disc regions are normal; no atrophy of the retinal pigment epithelium or change in the choroidea is to be made out. In particular, no perivascular striæ or white lines of new-formed connective tissue are found along any of the vessels, either just off or on the disc. The main arteries are slightly narrowed, and the veins appreciably widened, so that the relation between the width of the veins and arteries is 3 to 1 in comparison with a normal relation of 3 to 2.

As stated, the tension has been studied with special care. To the touch it has always been at the lowest border of the physiologic limit, both to me and to my colleagues, Drs. Wilder and Beard. For 75 consecutive days it was taken with the Schiötz tonometer, and two weights always used. This instrument, which I consider most valuable, never registered more than $14\frac{1}{2}$ mm. of the mercury column (manometric) pressure. At times the reading was as low as $8\frac{1}{2}$ mm., but the two eyes were always of the same tension. Following Meller's practice, I tried repeatedly to bring about a condition of the eye favorable to the ele-

vation of tension and to render manifest any latent glaucoma, by dilating the pupils for days at a time by homatropin, but without any result.

I contend that this is a bona fide case of wood-alcohol amaurosis, because—(1) The history of the poisoning followed by the sudden blindness is clear; (2) the fundi are normal outside the disc; and (3) glaucoma was excluded by the tonometer.

A comparison with the cases of Dr. Fridenberg becomes of interest. First, the discs were distinctly blue in my case, white in Dr. Fridenberg's cases. This difference is not surprising, but rather in keeping with what we know of the color variations in other forms of atrophy. According to Fuchs, any form of atrophy—simple, post-neuritic (pp. 596, 597), or glaucomatous (p. 452)—may be either blue or white. Elschnig, in commenting on the fact that "the various forms of atrophy often show a somewhat peculiar nuance of the white," adds, "one should not lay too great weight upon this" (Lehrbuch d. Augenheilkunde, Axenfeld, 1909, p. 69). Second, there were no perivascular striæ in my case. I cannot, therefore, agree with the essayist that either white atrophy or extrapapillary connective tissue constitutes an invariable or an essential part of the fundus picture of wood-alcohol poisoning. My case agrees, on the other hand, with those reported by Dr. Fridenberg, which had pseudoglaucomatous cupping of the disc, and I would strongly emphasize this unusual, peculiar, indeed, remarkable feature of the cases, although it is not pathognomonic. If I understand him correctly, the cup was a deep one, and extended to the very edge, but did not involve the entire circumference of the disc. Exactly this form of cup was present in my case. It included a little more than the nasal half of each disc, and differed in no way from the nasal half of an ordinary glaucoma cup, except that it was limited to this half. I, too, have been unable to find record of glaucoma-like cupping after wood-alcohol poisoning, but I find that Elschnig (Encyclopædie d. Augenheilkunde, Lief 7, p. 291, Vogel, Leipzig, 1904) has described just such a partial excavation in glaucoma in the following words: "Relatively seldom one encounters partial glaucomatous excavations; the vessels in one quadrant or half bend

sharply at the margin of the disc; the rest of the papilla is unchanged, or the wall of nerve-fibers bordering the excavation is only flatter and narrower, so that, at most, only one or two vessels suffer a slight bending backward in their course from the retina on to the disc. In these cases the excavation makes known its glaucomatous character by its extension to the edge of the disc and its steep border, but the excavation is not total." A partial ampulliform excavation does, therefore, occur in glaucoma, and, if our observations are to be credited, in wood-alcohol poisoning. As to the genesis of such a partial cupping, I naturally have no theory to offer on the basis of a single clinical observation. I can, however, see no reason why the retrobulbar neuritis from wood-alcohol should not produce a simple atrophy of the disc, such as frequently occurs in other forms of toxic retrobulbar neuritis (ethyl alcohol, tobacco, quinin, lead-poisoning, diabetes). Possibly this is a form of the cavernous atrophy described by Schnabel, and akin to the so-called "genuine glaucomatous optic-nerve disease," which is said to be independent of the tension in glaucoma. Schreiber and Wengler have lately produced such a lacunar atrophy of the disc head, though with increase of tension, by the injection of scarlet red into the anterior chamber of rabbits. Again, we must remember that such a cup may be only apparent, and really due to abnormal transparency of the disc tissue, as held to be the case, even in some complete cups, by Mauthner. Recently von Hippel reported a case anatomically which he thought was of this type, because all the vessels were thrown to the nasal side; the level of the disc was almost normal, but the tissue in front of the lamina was very spongy and rarefied by lacunar atrophy, so that it may well have looked like a glaucomatous disc. No proliferated new tissue was present. In any case I cannot agree with Dr. Fridenberg that the rapid atrophy in any way prevents the filling up of such a cup with new tissue.

DR. EMIL GRUENING, New York: The material upon which Dr. Fridenberg made his observations has also been seen by me. Most of it was in my clinic, and I think we can make the diagnosis of wood-alcohol poisoning without

even looking at the disc. There is the usual history. I had only one case which resembled glaucoma and that Dr. Fridenberg drew for me, and it is a case in which every one would make the diagnosis of glaucoma; but there is no thickening of the vascular coat.

There are cases in which neuritis is absent. We do not know that such slight neuritis causes absolute blindness, but we know that when the ganglion-cells are affected, and, as Dr. de Schweinitz has found in cases of toxic amblyopia and Dr. Holden found in his first experiments upon dogs, the prolongation of the ganglion-cells, the optic-nerve fibers, are also affected. Then there are other ophthalmoscopic pictures in this disease. I have seen cases in which the blindness was caused by inhalation. The blindness was complete, but the cases recovered. The ophthalmoscopic picture was negative. Dr. Fridenberg said "so-called wood-alcohol poisoning." When the people took the wood-alcohol and became blind, we called it blindness due to wood-alcohol.

I would say this: Wood-alcohol poisoning is very common—it is very common in New York; very common throughout the States. Wood-alcohol is used in many beverages. Not only the soft drinks given to babies are poisoned, but the strong drinks are poisoned. We as a society—as a representative society of America—should do something to stop that. We should communicate with the Department of Agriculture, if that is the department doing such work for the United States, and ask them to put this matter under the Pure Food law. The Pure Food law does not contain the words "wood-alcohol." It is not printed on the labels what kind of alcohol is contained in the drugs and beverages covered by the Pure Food law.

DR. G. E. DE SCHWEINITZ, Philadelphia: Dr. de Schweinitz added two observations of his own to the subject discussed by Dr. Fridenberg, namely, the case history of a patient absolutely blind as the result of a prolonged spree in which he consumed incredible quantities of Jamaica ginger in which there was much methyl-alcohol. The nerve-heads presented, although not in a perfectly typical degree, the appearances depicted by Dr. Fridenberg. A

second case was that of a man, a shellacer by trade, who worked in a closed place with Columbian spirits, which contains about 95 per cent. of methyl-alcohol, and who became rapidly and permanently blind, the poison evidently having been introduced into the system by inhalation, but the nerves did not show, at least at the time of the examination shortly after the poisoning occurred, any of the characteristic signs described by Dr. Fridenberg, although evidently this must be regarded as a perfectly pure case of rapid methyl-alcohol blindness. Whether this patient's discs at the present time, now some years after the poisoning, would show this type of cupping, Dr. de Schweinitz was unable to say.

DR. W. H. WILDER, Chicago: Some years ago we in Chicago had an opportunity of seeing several interesting cases of wood-alcohol poisoning that were quite similar to the ones which Dr. de Schweinitz mentioned. These were put on record as cases in which, in all probability, the alcohol was absorbed by inhalation. A certain degree of sight returned a few days after the original blindness, but this was followed by total blindness. Within two weeks I have had the opportunity of seeing one of these cases. The man remains totally blind, and I was interested to observe that there was a marked glaucomatous cupping, but apparently no increase of tension. I think if this observation of Dr. Fridenberg should prove to be correct, it would certainly furnish us with a very helpful means of diagnosis in this class of cases.

DR. E. V. L. BROWN, Chicago: In one case there was apparently some tension, but the man absolutely refused to have the eye studied by the tonometer.

DR. WILLIAM H. WILMER, Washington: I recall a case, interesting from a medicolegal standpoint—one which I saw in 1898. It is interesting also because I know the exact amount of alcohol taken. The man was a soldier in the medical service during the war with Spain. He took four drams of wood-alcohol, thinking it was pure whisky. The next morning he was nauseated upon waking, and his sight was poor. The next day it was still poorer, and the fourth

day still worse. I saw him on the fourth day, and he was practically absolutely blind. There was faint perception of motion of objects in the temporal field. There was nothing in the literature of the subject at that time. I gave a guarded prognosis, and put him under the treatment of strychnin. For a while he had vision in the temporal fields in each eye over an area of 10 degrees. At first there were no visible ophthalmoscopic changes. Later the nerve was white, vessels small, no cupping. There might have been slight perivascular changes, but at that time my attention was not called to this feature. An interesting point in connection with the case is that he is receiving $75 a month for blindness contracted during service. From a legal standpoint the case is of special interest. Perhaps he deserves the pension. Personally, I should do nothing to prevent his receiving it. I told him that I was morally certain that his blindness was due to wood-alcohol.

DR. S. LEWIS ZIEGLER, Philadelphia: I should like to ask Dr. Fridenberg if he has accurate information as to the length of time that had elapsed between the ingestion of wood-alcohol and the appearance of the optic-nerve lesions he describes. I have a case under observation at the present time that shows none of these conditions, possibly because it is a more recent case. It followed a Christmas celebration, and was seen by me about a month later. The blindness was immediate and total. About two months after the ingestion, under the use of negative galvanism, she began to see light. She now has a vision of $\frac{20}{200}$ with J. No. 12 in the right eye, and $\frac{10}{200}$ with J. No. 20 in the left. The nerve-head has not shrunken, but, on the contrary, is slightly prominent. Whether this is actual swelling which will later undergo shrinkage it is difficult to say. I would think not, for the reason that the vision is steadily improving and the fields are gradually widening out.

DR. PERCY FRIDENBERG, New York: I am much interested in the positive corroboration of some of my observations. The cases of sudden, complete blindness cited by Drs. Brown and de Schweinitz were ophthalmoscopically quite like mine. It may be necessary for me to modify my views, at least, to the extent of saying that where we

do find the conditions I have described we have undoubtedly a case of fulminant wood-alcohol amaurosis, but that there are probably cases in which these typical conditions are not found. That, however, does not invalidate the possibility of determining pathognomonic, characteristic features, but limits application. Typical symptoms may be wanting in many cases of disease. The same is found throughout medicine. I do think, however, that, with the deep cup simulating glaucoma, without clinical history or evidence of increased tension, and slight perivascular striation and evidence of neuritis, we can say that the patient has been blinded by wood-alcohol. That some patients have taken wood-alcohol and do not have these typical symptoms I shall have to admit, and there is no reason why this should not be. Possibly the intoxication from inhalation causes less marked degeneration.

Dr. Gruening says that he can make a diagnosis without looking into the eye. My paper was intended for those who cannot. I have heard of absent treatment, but not of absent examination. The degeneration of the nerve, not the mild neuritis, is, of course, the cause of blindness. The sketch I made for Dr. Gruening was merely a rough suggestion of the picture seen. While there has been a mild neuritis present in most of the cases, the blindness is due to the complete nerve degeneration. In my paper I mention that there may be found, as a concomitant, a little connective tissue at the bottom of the cupping, although this is rarely observed.

I know little about the dangers from inhalation. My cases were instances of actual ingestion of the wood-alcohol.

In answer to Dr. Ziegler, the degeneration and the atrophic picture came on comparatively early—within a few weeks.

OCULAR SIGNS FREQUENTLY ASSOCIATED WITH VASOMOTOR DISTURBANCES.

HOWARD F. HANSELL, M.D.,
Philadelphia.

The ocular signs referred to in the title of this paper are not structural, and depend for their presence and association with each other upon causes unconnected with the function of sight. They are significant of an excitation or apathy of the sympathetic, or, as it has been more recently named, the autonomic nervous system, and are probably directly due to abnormal action of the unstriped muscular tissue of the lids and orbit, and of that in the coats of the blood-vessels. Normal rotation of the eyes in any direction, or concentration of both eyes upon a near or distant object, is accomplished with associated contraction or relaxation of the unstriped muscle radiating forward and backward from the orbital fascia, and forming no unimportant part of the muscular apparatus of the eyes. Moreover, all movement, as well as all variations in the act of seeing, contribute to momentary changes in the caliber of the vessels and to momentary retardation of the venous blood in its passage out from the eye and orbit, and, while the action of the straight and oblique muscles, the ciliary body, and the iris is directly controlled by the cranial nerves and is well understood, the rôle of the autonomic system in its healthy or diseased state should also be considered.

The fundamental disorders or affections underlying the disturbances of function of the autonomic system cannot be accurately designated. They may be described rather as peculiarities or idiosyncrasies inherited or acquired than as

actual diseases, and yet they are more than these words convey. Our present classification of disease, according to pathology and symptoms, aims at separating definite maladies having distinct manifestations, reproduced with significant frequency in a sufficient number of individuals to entitle the various groups of symptoms to characteristic titles. Underlying the symptom-groups known as nephritis, diabetes, glandular affections, tuberculosis, and many other so-called definite diseases, of which the pathology may be known or unknown, is a condition or a tendency toward the development of the various, or one of the various, specific diseases. It is this predisposition or susceptibility, manifested differently in different individuals, which may be responsible, and its discovery or determination would be a most important factor in preventive and curative medicine. The borderland of many diseases is not clearly defined, overlapping of symptoms and pathology is common, and even here the primal etiology may be identical. Much more commonly those disturbances that have no unchangeable symptom-groups and are recognized by one or more distinguishing features, and by little that is characteristic in their pathology, have many features in common. They are separately classified according to prevalent dominant symptoms or other special features, a classification which is correct, no doubt, according to present knowledge. A deeper study into a larger mass of material than has been hitherto collected may demonstrate that while differences may be found in the manifestations of each affection, these dissimilarities may be less dependent upon the etiology than upon personal idiosyncrasies or responsiveness in the individuals attacked, or, in other words, upon the state of the cerebrospinal and sympathetic nervous system and the circulatory apparatus. Disturbance of the function of one or all these systems increases receptiveness, and, according to the character or intensity of the disturbance, is the development of a series

of symptoms designated more or less accurately as a particular disease.

Vasomotor instability or ataxia, the latter name originating with Dr. S. Solis Cohen (Amer. Jour. Med. Sci., Feb., 1894), is a fundamental condition from which many of the so-called specific diseases arise. He thus defines it: "By the term vasomotor incoördination or ataxia it is proposed to designate not a disease, but a fundamental disorder, out of which, through the incidence of various exciting causes, varying syndrome groups may be developed."

The signs are not constant, although they occur in association so often that they may be said to indicate the affection. The most characteristic and frequent signs as described by Cohen are as follows:

1. An unusual degree of responsiveness of the skin to small irritations, such as a distinct red or blanched line persisting for several minutes, after gentle scratching with a pencil or other partially blunt object, dermographism, and, in marked cases, factitious urticaria.

2. An exaggerated tendency to blushing.

3. Minute cutaneous angiomata.

4. The "patriotic nails," or cyanosis of the nails changing the uniform normal pink color into blue or violet at the base, a whitish broad area in the middle, and a crescentic line of red at the tip.

5. Moist and cold or hot hands and bodies abnormally sensitive to temperature changes.

6. Tachycardia, occasionally enlargement of the thyroid, gastro-enteric neuroses, headache, nervousness, irritability, excitability, exaggeration or perversion of any of the normal functions.

7. A tendency to hemorrhages.

The presence of all or most of the symptoms in one patient indicates, in positive terms, a disturbance in the vasomotor control. The nature of the disturbed function

may not, in the first stages of the affection, be determined either as irritative or paretic, and only later, by further development and consistency of the symptom-group, is its character definitely known.

The collective eye signs to which I desire to call attention include those indicative of irritation of the sympathetic system, and, frequently associated with them, indications, also, of relaxation. They may be explained by disturbed function of the unstriped muscular fiber in the orbit, which modifies the voluntary muscular action, as well as the caliber of the vessels. The ring or cuff of unstriped muscle which almost completely surrounds the anterior part of the ball may be regarded as the origin, and the soft tissue of the lids and the inner commissure as the insertion, of the anterior part of the muscles. The fibers which run backward through the orbital fat, and also those which, to a limited extent, constrict the openings near the orbital apex, must also be considered in their effect upon the action of the voluntary muscles and upon the caliber of the blood-vessels. The venous system of the orbit is most complex. The veins are numerous and large. They anastomose freely, and discharge their contents through three different outlets—posteriorly in the cavernous sinus, temporalward into the facial vein, and medianly by a large vein which passes over the root of the nose.

The ocular signs of vasomotor ataxia are:

1. *Venous Hyperemia of the Retina.*—The hyperemia of vasomotor ataxia is difficult of diagnosis. Pulsation of the veins, contrast between the color of the arteries and veins, an excessive amount of deficiency of choroidal pigment, or other absolutely normal findings must be considered carefully in making a diagnosis. The absence of all ocular effects which might be considered a cause, such as visual dulness, limitation of field, or organic changes, retinal edema, pigment hypertrophies, or exudation, is consistent

with venous hyperemia, physiologic as concerns the eyes, but pathologic in its indication of a systemic disturbance. Dr. Cohen has referred many cases to me for an eye report, and I have found, in the majority of patients, hyperemia so constant as to warrant the acceptance of its presence as confirmatory of general vascular disturbance. In no case has the hyperemia been marked enough to warrant the suspicion that we were dealing with any form of ocular disease or any form of eye-strain which might account for it.

In these patients I have almost invariably found tortuosity and a slight increase in diameter of the veins, most noticeable in the largest veins. The smaller veins and the disc capillaries are not more numerous, and the disc itself has the pinkish color of the healthy eye.

Unless one is on the lookout for modifications in the usual venous appearance in the retina, these changes might easily be passed without note, or, if noticed, not considered as abnormal or beyond physiologic limits. The cause for the dilatation of the veins is obscure. It is undoubtedly a systemic one, and responsible as well for the superficial vascular disturbances, such as the "patriotic nails" and the skin reactions to gentle irritations, dermographism, factitious urticaria, and blushing.

2. *Stellwag's sign*, or a permanent increase in the vertical diameter of the commissure, is common in exophthalmic goiter, but it is, as Michel says, not pathognomonic of the disease. It is an early and constant sign of vasomotor ataxia in persons in whom the thyroid gland is not enlarged. Yet its frequency in Basedow's disease, which is looked upon as a combination of a constitutional nervous affection and glandular disease, and its presence in vasomotor disturbance in which there is neither enlargement of the thyroid nor exophthalmos, would point to a common origin of the two affections. Momentary or transient widening

of the commissure accompanies psychic excitation, such as intense emotion, astonishment, or fear, and is also found in individuals who, on account of defect in vision, make conscious effort to see more clearly, and in neurasthenia and hysteria. These latter affections and vasomotor ataxia may have a common etiology, namely, a disordered sympathetic nervous system. In those individuals in which no organic lesion is known to exist, the widening of the commissure may be traced to an irritation of the sympathetic ganglia in the neck, and consequent contraction of the unstriped fibers situated in the superior-anterior portion of the orbit, and terminating in the tarsus of the upper lid. Clinically, irritation of the smooth muscle causes a widening of the commissure, and paresis a moderate ptosis, which, in contrast to third-nerve paralysis, is known as "ptosis sympathetica" (V. Michel).

Cohen says, in describing the sign (Trans. Assoc. Amer. Physicians, 1902): "There is usually a tendency to contraction of the upper eyelid, exposing the sclera above the cornea. When not spontaneous, it may be developed by having the subject fix his eyes upon a point at the normal level of the pupil, and telling him to open his eyes as widely as possible. I have looked upon it as a larval condition of the palpebral contraction known as Stellwag's sign of exophthalmic goiter."

Risley reported before this society in 1896 a case of vasomotor ataxia in which Stellwag's sign was well marked. The right upper lid was strongly drawn backward. The patient was a highly nervous woman of forty-two, with slight exophthalmos, enlarged thyroid, and marked tachycardia, an example of Graves' disease, yet with the stronger probability of belonging to the category of vasomotor ataxia.

3. *Von Graefe's Sign.*—Lagging of the lid as the ball is rotated downward, or a modification noted by Cohen—a

jerky descent of the lid. This sign may be monocular or binocular, may be difficult to detect at the time of examination, and present in exaggerated forms on other occasions. It is frequently associated with Stellwag's sign, but may exist independently. Its presence as a sign of vasomotor incoordination and of exophthalmic goiter should be carefully differentiated from a similar imperfect descent of the lid found in high myopia, anterior scleral staphyloma, or tumor of the orbit, all of which affections, by the mechanical alterations of the relations of the lid to the ball, will produce it. Also from the pseudo-Graefe lid, described by Michel as an intermittent or rather a rhythmic or periodic jerking backward of the upper lid, in consequence of paresis or chronic spasm of the levator palpebræ, two apparently opposite conditions, which, however, at some stage of their existence give rise to the same symptom. While the Graefe lid sign is a common one in exophthalmic goiter, it is also to be frequently found in individuals who have neither an enlarged thyroid gland nor other symptom of Graves' disease. Late in the history of some patients exophthalmic goiter and tachycardia may be developed, and in them it may be regarded as one of the prodromes. Other and more fortunate patients, in whom the affection is early recognized, recover entirely, and never show any symptom of Graves' disease. Closely allied in etiology to Graefe's sign is the Gifford sign. The upper lid can be turned only with the greatest difficulty, and then, at the expense of so great a strain on the tarsal conjunctiva, that the latter is entirely blanched in the center by pressure (Oph. Rec., June 2, 1906). The voluntary resistance of the upper lid to eversion Gifford believes to be due to irritability of Müller's muscle, the unstriped muscular fiber above referred to.

4. *Tremulousness of the Lids.*—This sign is less frequent

than the foregoing, but is quite common. It is binocular, more marked in the lower than in the upper lids, and developed when the lids are lightly closed. Like the other eye signs, it is subject to variations in degree. It may disappear, to occur at irregular intervals. It may be associated with nystagmus and with tremor in other parts of the body.

5. *Pigmentation of the Skin of the Lids.*—Jackson and Mead (Ophthalmology, v, 4, p. 695), Teillars (Arch. d'Oph., May, 1905), and Cohen (N. Y. Med. Jour., February 19, 26, March 3, 1910) refer to sharply defined and symmetric pigmentation around and beneath the lids as occasionally present. Cohen says it is not exceptional. In the cases that have come under my observation it has not been noticed in any instance. Changes in pigmentation of the skin in patches in other parts of the body both increased in amount beyond the normal, and decreased or absorbed, so that the skin becomes white and sharply outlined from the adjacent healthy colored skin, are common, and that changes in the amount of pigment in the lids have not been noticed by me is simply accidental.

6. *Pupillary Inequalities.*—Individuals with vasomotor ataxia are emotional, and in a more or less constant state of exaggeration of normal conditions. The pupils are, as a rule, in conformity with the supersensitiveness of the nervous system controlling the muscles and the vessels, dilated and responsive to light and accommodation, bilaterally and equally or unilaterally or unequally. Cohen says that "the contractility of the muscular fibers of the iris seems to be soon exhausted, and vacillation of the pupil (almost a condition of hippus) is developed by repeated or prolonged testing."

Other ocular signs occasionally seen, but not frequently enough to warrant their enumeration among the constant signs, are drooping of the lids of one or both eyes, partial

and intermittent narrowing of the commissure, sometimes monocular partial loss of convergence, and Moebius' sign (loss of convergence), not to be mistaken for functional exophoria or exotropia, but manifest only upon efforts at extreme convergence.

In determining the presence and importance of the eye signs as contributing factors in the diagnosis of vasomotor incoördination, the state of the refraction and the health of the eye should be considered.

High myopia will often produce widening of the commissure, hyperopia, and astigmatism, amblyopia of one eye, disease of the orbit or of the ball, will interfere with normal muscular action and will give rise to inequality of the pupils. The eye signs are significant and dependable only in the absence of local causes.

DISCUSSION.

DR. C. F. CLARK, Columbus: I have been convinced, in examining patients referred to me with the supposition that they have evidence in the eye of thyroid disease, that the description of these symptoms as eye symptoms is misleading. Dr. Hansell's paper points to a plan of study which, if properly carried out, will enable us to differentiate more accurately than heretofore.

A CASE OF SPASM OF THE RETINAL ARTERIES.

HENRY DICKSON BRUNS, M.D.,
New Orleans, La.

History.—On April 15, 1908, H. B. came to the Eye Department of the Eye, Ear, Nose, and Throat Hospital, complaining that vision had been failing for two weeks. She had had no important illness except a convulsion about three weeks ago. The girl was rather tall for her age, slim, sandy haired, a little pale, with delicate, freckled skin and blue eyes. Nothing abnormal was observed about the eyes, *facies*, or figure on simple inspection. The vision in each eye was fingers at 15 feet. The pupils were dilated with homatropin, and the ophthalmoscope showed the arteries extremely small, the veins enlarged and dark, in some places almost chocolate colored. Besides their notable pallor, there was about the discs a bluish-white halo (edema) extending for at least one diameter over the retina all around. Pressure upon the eyeballs produced strong pulsations, and finally almost total exsanguination of the retina. The appearance resembled embolism of the central artery, for which, had it been monocular, it might have been mistaken. To encourage the patient, and not to interfere with the natural course of the disease, $\frac{1}{120}$ grain of strychnin sulphate, to be taken twice a day in a little water, was prescribed. In a day or two we sent the patient to Dr. E. M. Dupaquier, our colleague of the chair of Clinical Therapeutics in the Polyclinic. After an examination he wrote that he could elicit nothing of *interest* except that the girl flushed easily and that, under the fire of the examination, he noted little choreiform movements. She came of a neurotic family; her sister often had attacks of hysteria major (?) and the patient herself had had other convulsions at two years of age. He was inclined to believe that the sudden interruption of the circulation in the optic nerves and retina owned a nervous origin. "Dan ces cas de névroses sans lésions," to quote from his report, "ces phénomènes

sont transitoires et parraissent due communément à une intoxication alimentaire, sans, arterio-sclèrose marquée—Ils guérissent." Upon the patient's second visit the diagnosis of spasm of the retinal arteries was made. At this visit, April 24, V = R. E., fingers at two feet; L. E., $\frac{20}{lxx}$.

April 27, 1908: V = R. E., fingers at four feet; L. E., $\frac{20}{xxx}$. In the left eye edema in and about the papilla had diminished, and the disc showed an excavation and a pallor of the portion corresponding to the papillomacular bundle. This was in twelve days without treatment. The patient was seen again on May 4, 13, and 27, June 17, and July 22 without anything but steady gradual improvement being noted. July 29, V = R. E., $-\frac{20}{xl}$; L. E. $-\frac{20}{xx}$. In the left eye the ophthalmoscope showed nothing that could be called abnormal, but there was a central physiologic excavation of the disc. In the right eye there was indubitably pallor of the whole disc. The excavation looked much larger than in the fellow eye, and the lamina was too distinct. I thought this right nerve slightly atrophic. Again the patient came on August 25, September 30, and October 30, but again nothing was noted but slow steady improvement in vision, until November 20, 1908, when V = R. E., $\frac{20}{xxx}$; L. E., $\frac{20}{xv}$. The ophthalmoscope showed "convolvulus disc" in each eye.

During this whole time the fields of vision had been carefully taken. On April 24 the field of the left eye, with V = $\frac{20}{lxx}$, was quite normal. It was impossible to take a field of the right eye, but the candle-flame field seemed to be somewhat contracted. By June 17, V being R. E., $\frac{20}{lxx}$, and L. E., $\frac{20}{xv}$, both fields were normal. On January 20, 1909, when V was R. E., $\frac{20}{xxx}$; L. E., $\frac{20}{xx}$, our note reads: Fields are perfectly normal and color perception for red and green good in all parts of the fields. At no time were the fields suggestive of hysteria.

On March 30, 1909, nearly a year after her first visit, the patient came again. Dr. Joseph Weiss had been appointed visiting internist to the hospital, and Dr. E. M. Hummel, visiting neurologist, and I sent the patient to consult both. The neurologist reported on April 4: Examination negative.

No stigmata of hysteria; the history, however, is somewhat suggestive of this condition. The internist kindly furnished the following notes: April '7: A white school-girl, born in New Orleans fourteen years ago; mother, German; father, Spanish. A year ago had a convulsion followed by disturbed vision. Return of headache every month. No menstruation. Sister had hysterics with first menstruation. Has had measles (?); previous history otherwise negative. Good appetite. No night urination. Weight, 70 pounds six months ago; improved since. No color—always pale, but flushes. Hemoglobin, 70%. Urinalysis, albumin, slight trace, sp. gr., 1010. The sediment was not examined at this time, but subsequent examinations discovered no casts or anything noteworthy. April 28, doing well. Urine shows a slight trace of albumin, sp. gr., 1002. Urine shows effects of too much water; pulse also; tension high. Advise less fluid. May 5, doing well. Urine, slight trace of albumin, sp. gr., 1008. Pulse, high tension. In August, Dr. Weiss being absent, Dr. C. L. Eshleman, who filled his place, noted albumin still present. Pulse, high tension. Feeling well, however. On August 26: Looks much better, and feels better. Urine shows about 1% of albumin. Pulse, low tension and generally seems to be doing well. Previous examination showed only a trace of albumin.

September 30, 1909, urine negative; pulse still shows tension; occasional headaches. No medicine now. Simply dietetics and attention to excretions.

On December 3, 1909, almost twenty months after her first visit, Dr. Weiss and I saw the patient again for the first time in several months. Her general appearance was much improved. She had menstruated for the first time on November 18 just past; urine acid; no albumin, no casts, sp. gr., 1015. Hemoglobin, 80%. Tension of vessels seems less. Reflexes slightly exaggerated. V = R. E. and L. E., $\frac{20}{xv}$ for the first time.

Such reading as I have been able to do indicates that the condition is rare. Though mentioned in our texts, the literature is widely scattered through many periodicals, almost entirely unavailable to me. However, enough has been quoted, I hope, to serve as the basis of my argument.

Soelberg Wells (Diseases of the Eye, edited by Bull, 1883), under the heading Epilepsy of the Retina (Ophthalmic Migraine, B., p. 539), quotes Hughlings Jackson's observation during epileptic unconsciousness with dilated pupils. "Once the vessels disappeared. After a while, however, they reappeared, and were found to vary with the respiration. When the patient inspired, the vessels disappeared, returning again on expiration, like lines of red ink on white paper." This, Wells thought, was "dependent in all probability upon a contraction of the retinal vessels," but nothing like it took place in my case, or, as far as I know, in any of the best established cases. It would seem more likely to have been a phenomenon of extreme ischemia, in which the empty vessels refilled upon expiration, than a spasm synchronous with inhalation.

Under the title of Spasm of the Retinal Arteries, Megrims, Epilepsy of the Retina, Noyes (Diseases of the Eye, 1890) says: In consequence of vasomotor irritation, the retinal arteries may be firmly contracted and arrest completely the circulation, and he cites these cases:

Mrs. W., widow, forty-three years of age, was brought to me by Dr. Burchard. She seems well nourished, but is said to have lately lost flesh. Has an anxious expression; been greatly worried by business cares, and been under much excitement. Three months ago she began to have obscuration of sight in the right eye. In a little time the sight would go out, as she said, every twenty-four hours, and everything be dark for fifteen to thirty minutes. This condition affected the right eye only until a few evenings since. Then, while at the opera, she became totally blind for about one-half hour, and, as she says, was in total darkness. Since then the same thing has happened every evening, and lasted from a few minutes to a half-hour. At my interview with her in my office she exclaimed that sight was leaving the left eye. Her vision had been previously examined and found to be $\frac{20}{20}$ in each eye. While the dimness existed, I inspected the left eye with the ophthal-

moscope. The arteries were reduced in size; the veins were normal; no other notable appearances. The attack passed in a few minutes, and then the arteries grew larger and more like those of the other eye. There were no signs of effusion or inflammation. My advice was to use bromid of ammonium, to take nourishing food, and try to secure exemption from anxiety and care.

In another instance in a man the blindness was complete in both eyes for sixteen hours and then perception of light began to return. I saw the man twenty-four hours after the beginning of the attack, and by the ophthalmoscope recognized great pallor of the optic nerve, tenuity of the arteries, the veins about normal. No effusion or swelling of the nerve or retina; tension normal; pupils active. Could count fingers at six feet. By inhalation of nitrite of amyl, vision was restored in twenty minutes to the normal degree and the intra-ocular circulation was resumed.

Dr. de Schweinitz, writing of embolism of the central artery of the retina (Diseases of the Eye, 1906, p. 573), says:

"The ophthalmoscopic picture just detailed indicates that there has been an interruption in the arterial circulation, but does not prove that stoppage has been due to embolism. Similar appearances occur, . . . according to A. Hugh Thompson, with spasm of the muscular walls of the central artery . . . . Some cases appear to be due to collapse of the arterial walls, so that they come in contact (Hoppe). Cases of this character may recover spontaneously or yield to treatment."

In Wilbrand and Saenger, 1909, vol. iv, p. 137, we find, under Spasm of the Retinal Arteries: *

A. In Migraine.—Parisotti (Ann. de ocul., t. cxix, p. 321) had the opportunity, in a case of ophthalmic migraine, to examine ophthalmoscopically. The lower half of the field was gone; the arteries of the upper half of the retina were narrowed; those of the lower half, normal. After

* I am indebted to Dr. H. F. Hansell, of Philadelphia, for the abstract.

the disappearance of the hemianopsia the arterial spasm was gone.

Quaglino (Ann. de ocul., t. lxv, p. 129): A thirty-four-year-old teacher, who, as a child, suffered from scrofulous keratitis and later from asthenopia, had attacks of "Flimmer-scotom," especially if the meal-times were unduly postponed. The attack lasted from five to fifteen minutes, with transitory blindness, during which elliptic light figures with brighter rays were seen above. During the attacks the retinal arteries were narrowed.

In Siegrist's cases of hemicrania (Mittheil. aus Kliniken der S., Reihe, Heft 10, 1894) the eye-grounds were twice examined and the retinal arteries on the side of the pain were markedly contracted.

B. Helminthiasis.—Faravelli (Ann. di Ottal., xvi, p. 63, 1887) reports the case of a baker, thirty years old, who, while at work, was attacked with violent photopsia, followed by veiling of the sight of the right eye. Throughout a week the phenomenon was repeated each night two or three times; then a rest of a few months was followed by a more violent recurrence. The dimness increased to momentary blindness of the right eye, with lesser obscuration of the left, passing off completely in ten minutes. The ophthalmoscope showed anemia of the retinal arteries and congested and pulsating veins, the appearances being more marked on the right side. During the intervals between attacks the vision was normal. After a tape-worm, without the head, had been evacuated, the patient was free from attacks for two months, but with the reappearance of segments of the worm the eye symptoms recurred. The head having been expelled, the patient remained well.

C. Unknown Etiology.—Alexander reports (Deut. med. Woch., 1881, No. 40, 41) the case of a nineteen-year-old girl who complained for eight days of increasing dimness of vision (R. E. = $\frac{18}{200}$). There was concentric narrowing

of the field, but the color perception was normal. The pupils were sluggish; eye-grounds normal. The diagnosis of retrobulbar neuritis was made. After fourteen days vision had sunk to $\frac{3}{200}$. All the retinal vessels were now found to be much narrower, the arteries hair-like, and hard to differentiate from the veins. Arterial pulsation could be produced by slight pressure. The macula was intact. The conclusion was reached that the case was not one of embolus, but, on the contrary, one of vasomotor cramp of the vessel-walls, and amyl nitrite was given. In four months all the phenomena had disappeared and vision was normal.

Reynard (Arch. Gén. de Med., January and February, 1874) claims to have seen cramp of a part of the retinal vessels, manifested by contraction of the vessels in small isolated sections; but Panas denies the correctness of the observation.

After Contusion.—Hirschberg (Berlin. klin. Woch., 1894, B. 22), Pearse (Albany Med. Annals), June, 1901, and Bäck (Arch. f. Ophthal., xlviii, 1).

E. After Infection.—Two cases of Ramorino (Ann. di. Optal., vi, 1, p. 25) of spasm of the retinal vessels in malaria. The principal symptoms were periodic amblyopia, with, during the attack, white papillæ, thread-like, almost bloodless, arteries, and scarcely perceptible veins. Cure by quinin.

F. After Intoxication.—With antifebrin: Hilbert (Memorabilien, Heft 2, p. 5, 1895); with bromid of potassium: Rübel (Centralbl. f. Augenheilk., October, 1884); with quinin, large number of cases; with lead, chronic poisoning.

G. Arteriosclerosis.—Wagemann (Arch. f. Ophth., xliv, p. 219).

In the above cases the cramp affected all the branches of the central artery, but a spasm in the form of a ring-like advancing peristaltic contraction is said to have been ob-

served also with the ophthalmoscope. Reiner (Arch. f. Aug., xxxviii, p. 25) says that this worm-like contraction, earlier described by Liebreich, may be an incorrect interpretation of an ophthalmoscopic appearance due to a granule-containing blood-stream—like sand and water—flowing through the veins.

In a paper on obstructions in the retinal arteries, read before the Ophthalmic Section of the American Medical Association at the meeting in June, 1904 (Jour. Amer. Med. Assoc., March 11, 1905), Dr. Allen Greenwood considers obstruction due to arteriosclerosis, to embolism, and to spasm, and gives a number of valuable references. Of spasm he writes: That spasm of the retinal arteries may occur, of sufficient degree to cause a temporary partial or complete obstruction to the flow of blood, seems proved beyond a doubt. It has been the good fortune of several observers to see patients during an attack of spasm of the retinal vessels, where, for a few moments, the arteries were reduced to yellow streaks, with subsequent restoration of the circulation. Such patients give a history of more or less frequent attacks of complete or partial blindness of one eye, lasting from several minutes to an hour or two. Case III described above gives such a history, and there were evidently attacks of spasm preceding the final complete obliteration of the inferior temporal artery. It is my belief that spasm occurs most frequently in early stages of arteriosclerosis, and should be looked upon as a warning of future obliterating arteritis. Wageman's* classic and frequently observed case of repeated spasm finally had a spasm that was not relieved, and, the arteries remaining closed, the picture of embolus was produced. I doubt if more than very temporary spasm occurs in healthy vessels with normal blood, but that patients with retinal arteriosclerosis complicated by recurrent attacks of spasm are in special danger

* Dr. Greenwood refers to Trans. Heidelberg Ophth. Soc., 1897.

of blindness is evident. Virchow, many years ago, pointed out the fact that the arterial walls would close around an embolus, thus making an obstruction more complete. This contraction or spasm was only temporary, and it is only rational to expect that it would be a frequent and a recurrent accompaniment of endarteritis. Zehender was the first, according to Ole Bull, to call attention to arterial spasm, and in 1866 he published a case of repeated spasm of the retinal arteries following the repeated use of an ice-bag.

Ischemia of the Retina.—"Those rare cases in which ischemia occurs as a more or less independent affection" is the condition described by competent observers, which most closely resembles that which others equally trustworthy have satisfied themselves is due to spasm of the central arteries. Soelberg Wells, under the heading Ischemia of the Retina, after recounting the symptoms and referring to the cases of Alfred von Graefe (Arch. f. Ophth., viii, 1, 143), Rothmund (Klin. Monatsbl., 1866, p. 106), and Heddäus (*ibid.*, 1865, p. 285), says:

"In von Graefe's case the patient, a little girl, five and a half years of age, suddenly overnight became totally blind in both eyes, so that not the faintest perception of light remained. On examination the eyes presented the following appearance: The tension of the eyes normal, conjunctivæ very pale, the eyeballs of marble whiteness, pupils much dilated, without any reaction on the stimulus of light, but a faint uniform contraction on the application of laudanum; only slight increase in dilatation on the application of atropin. With the ophthalmoscope the dioptric media were found transparent, the retinal arteries extremely attenuated, the veins tortuous and dilated. The retina and optic nerve were normal, the outline of the latter being, however, slightly indistinct. The color of the skin, but especially of the mucous membranes, was extremely pale.

The child was otherwise perfectly well, the only peculiar symptom being extreme rapidity of the pulse, which was very small and numbered 160 beats to the minute. Von Graefe considered that the probable cause of the blindness was an insufficient supply of blood to the retina, the faint and rapid contractions of the heart not being sufficient to overcome the normal, but proportionately too considerable, intra-ocular tension; he, therefore, gave the name of ischemia retinæ to this affection. The correctness of this view of the cause is strengthened by the fact that, after all other remedies, such as mercury, suppurating blisters behind the ears, artificial leeches to the temples, etc., had failed, an iridectomy, made upon the right eye ten days after the complete loss of sight, proved successful.

"Rothmund mentions two similar cases of ischemia of the retina in which paracentesis proved effectual, having, however, to be repeated in the second case."

Noyes (*loc. cit.*, p. 548) writes: "In a case which I saw in consultation with Dr. Knapp (Arch. of Ophth. and Otology, iv, p. 448, 1875) the child, three years of age, had been much prostrated by whooping-cough, and when convalescing, suddenly became totally blind, losing perception of light in both eyes. The optic nerves were white; in the left eye some arteries as fine as threads could be discerned; in the right none could be found. In both eyes the veins were of extreme tenuity. There were no other lesions. We have, therefore, seriously diminished heart action and an impoverished state of the blood." This child died of lobular pneumonia. Knapp says that once before he performed paracentesis in a like condition in a boy, ten years of age, but without benefit. He quotes Mauthner's opinion that Secundi's case was undoubtedly one of neuroretinitis. Stellwag (third edition) advocates retrobulbar neuritis in such cases, but in a fourth edition, 1870, he explains them by spasm of vessels.

In the Transactions of this Society for 1880 Dr. Knapp has recorded the case of Laura M., aged thirty. She had been well and strong until lately. Her father had a severe illness, which, during the past seven months, required constant care and night nursing, all devolving upon her and her younger sister. He died a few weeks ago. She grieved very much, and during his illness had fallen away and become feeble and pale. She had noticed flashes and scintillations of light in the right eye. Five days ago she noticed that, without assignable cause, the sight of the left eye was obscured from above downward, so that in the course of several minutes complete darkness occupied the upper half of her visual field. This lasted unchangeably for four days, when, yesterday, the lower half was as suddenly and completely obscured as the upper. She had felt no pain or any uneasiness in any part of her body, but could not see a ray of light with her left eye. On examination I (Dr. Knapp) found the external appearances and motions of both eyes quite normal, with the exception of the pupils. The right pupil was small and moved briskly with changes of light. The left pupil was over medium size and did not move at all with changes of light. When both eyes were left open and the right shaded, both pupils dilated promptly and contracted just as readily when the right was exposed to light, but when the left alone was shaded or exposed to light, both pupils remained completely unchanged. Several tests for simulation were negative. Tn. Both discs pale; arteries and veins smaller than normal. My diagnosis was insufficient nutrition of both retinæ, which in the left eye had been of such degree as completely to suspend vision. Lactate of iron, generous diet, and exercise were prescribed. In the evening of the same day she could distinguish between light and darkness. Her sight returned from above downward, just as she had lost it, and grew a little better

every day. In twenty-two days V = $\frac{20}{xx}$; field complete; pupil normal.

Diagnosis.—In my case the primary condition was evidently one of severe ischemia. Although the look of the fundus was quite enough to make one think of embolism, the bilateral nature of the affection caused instant rejection of the supposition. The possibility of simultaneous bilateral plugging of the central arteries will have to be admitted, but to justify such a diagnosis one would do well to bring anatomic findings to his support. If such a view needs reinforcement by another opinion, I may quote Dr. Allen Greenwood (*loc. cit.*), who says: "E. Stoke (Med. Wochenbl.), in December, 1903, published a case of simultaneous bilateral embolism of the central arteries, with complete recovery in a few days, occurring in a man of eighty who had marked atheroma. One, I think, is justified in hesitating to accept such a diagnosis at the present time, and feeling that some disturbance in the blood or circulation may have precipitated a temporary spasm, causing the sudden loss of vision."

Embolism having been at once rejected, my imagination, guided probably by the history of convulsions, the appearance of the patient, and the absence of other suggestive symptoms, turned promptly to the supposition of arterial spasm as a cause of the ophthalmoscopic picture. Further consideration tends to confirm belief in the correctness of this *apercu.* Writing of embolism of the central artery, Panas (Traite des Maladies des Yeux, Paris, 1894, p. 625) asserts that, "thanks to characteristic symptoms . . . . the diagnosis of embolism of the arteria centralis cannot be doubtful; except compression of the optic nerve by a tumor, apoplexy of the sheath, which has been established by Magnus, or an acute retrobulbar neuritis, there is nothing

* I owe the abstract to Dr. H. F. Hansell. The case is referred to by Schöble, Norris and Oliver's System.

which might deceive us. But by remembering that in the first case there is exophthalmos, and that in the other two the blindness is usually bilateral, we can arrive at certainty." In the present case the absence of all symptoms and the integrity of the fields deny the presence of retrobulbar neuritis, while the lack of etiologic factors, injuries, diseased vessels, hemorrhagic meningitis (Noyes, *loc. cit.*), and of the red optic disc, extended retinal haze, and small veins, make unlikely the presence of hemorrhage into the nerve-sheath.

It is clear that but thin partitions divide the diagnosis of essential ischemia of the retina, the remaining possibility, from that of arterial spasm. The subjects of ischemia, says Noyes (*loc. cit.*), have always been persons who have been much prostrated by illness, and we have seen that this was true of von Graefe's case, in the case of Dr. Knapp, cited by Noyes, and in Dr. Knapp's second case, abstracted on page 545.* But while these distinguished observers have lent their weight, and though Professor Jos. Schöbl, in his article in Norris and Oliver's System (vol. iii, p. 413),† speaks of "those rare instances in which ischemia occurs as a more or less independent affection," expressions of doubt as to the reality of the condition are not lacking. Von Graefe (Noyes, *loc. cit.*) examined the retinal circulation of cholera patients "when they were in the last stages of prostration, and never failed to find blood in the vessels; and they had correct vision as far as could be ascertained. He, therefore, thought that some obstructive cause was to be assumed in cases of ischæmia, and that it was likely to be found in the optic sheath. It seems likely that we have a partial thrombosis behind the eyeball, and that these cases are to

* A Case of Ischæmia Retinæ, published in the Transactions of the Medical Society of New York, 1878, I have been unable to see.

† Professor Schöbl refers to Alfred von Graefe, Arch. f. Ophth., Bd. viii, S. 143; Heddeus, Klin. Monat. f. prak. Aug., 1865; Rothmund, *ibid.*, 1866; Secondi, Caso di Anaurose per Ischemiam, Turin, 1866, and Knapp, Trans. Amer. Ophth. Soc., 1880.

be referred to this head." De Wecker, in his Ocular Therapeutics (ed. Linton Forbes, London, 1879), writes: "Anæmia or ischæmia of the retina, when it is not the consequence of direct compression of the vessels in the optic nerve or in the orbit, is the result of an excessive and prolonged condition of general anæmia. I must remark, however, that chlorosis has but little tendency to affect the caliber of the vessels or the color of the disc, and this because of the constant point at which the intra-ocular tension is maintained." In cases of malarial anemia, with hemorrhages into the retina and profound syphilitic anemia, I have never observed a condition of retinal ischemia at all comparable to that seen in the case under consideration. Now, the reality of spasm of the retinal arteries rests upon a firmer foundation. It seems impossible to think that anything but a spasm of the arterial muscle-walls could have caused the phenomena in the cases of migraine and hemicrania, in the case of helminthiasis (Wilbrand and Saenger), in the two cases of Noyes, the ice-bag case of Zehender (Greenwood), not to mention poisoning by quinin and other drugs. The only question seems to be as to the length of time such a spasm may last. In Quaglino's case (Wilbrand and Saenger) the phenomena lasted from five to fifteen minutes; in Faravelli's case, ten minutes (W. & S.); in Noyes' first case, from a few moments to thirty minutes; in his second, twenty-four hours, when amyl nitrite was given. Alexander's case (W. & S.), which most closely resembles mine, from the length of time it was carefully observed and the complete absence of all suggestive symptoms, seems inexplicable upon any other hypothesis than that of arterial spasm. His patient grew worse for twenty-two days, when amyl nitrite was given, and recovery was completed in four months. In my case, without treatment, improvement began in twelve days, was far advanced in three and one-half months, but

could not be called completed until nineteen months had passed.

Etiology.—Consideration of the etiology of the case makes more likely than other the diagnosis of arterial spasm. Arteriosclerosis is out of the question, and all the ordinary poisons can be safely excluded. The patient was not conspicuously anemic, and the hemoglobin never fell below 70 %; she had not been prostrated either by illness or fatigue. Here is a rather delicate girl of thirteen, in whom two internists and a neurologist can find nothing markedly abnormal—no stigmata of hysteria; yet all agree that she comes of a neurotic family and shows plain signs of an unstable nervous constitution. Her sister, in whom menstruation was delayed, had convulsions. She herself had convulsions at two years of age, and again at thirteen, just before the loss of sight, and has albuminuria for more than a year, and then, after her first menstruation, delayed, even in this warm climate, until past fifteen, all these derangements vanish. Is it not likely that the convulsions, the amenorrhea, the albuminuria, and the retinal ischemia were all dependent upon vasomotor disturbances in the corresponding organs? Shall we suppose that an altered state of the blood, due to the retention of the unknown constituents which should have been eliminated by the kidneys and in the menses, affected in this evil way the nervous elements? Or, is it not more probable that we had here a nervous system faulty from the first through inheritance, unable to regulate nicely the blood-supply to every portion of the body, and that in the imperfection of excretion by means of the kidneys and the menstrual flow we see merely the closure of a vicious circle. "Does it not greatly help to define our views of hysteria and neurasthenia, or of the condition that is now fashionably termed psychasthenia," says Dr. Edsall, "to know that every conceivable symptom of these states occurs in carbon-bisulphid poisoning,

and that hysteric laughter and tears are common in chronic manganese poisoning?"* We should remember, then, whenever we solace ourselves with the adjective *neuropathic*, that in most cases it serves but to carry us back one link further along the chain of etiologic explanation toward the dim-lighted labyrinths of physiologic chemistry.

DISCUSSION.

DR. W. B. MARPLE, New York: The case that Dr. Bruns reports, if due to spasm of the retinal arteries, lasted longer than any similar case which I can recall. The members will recall a case which Wagemann reported in 1897 (Graefe's Arch., vol. xliv, p. 219), of a patient, aged sixty-nine, with marked arteriosclerosis, who suffered from transitory attacks of visual impairment. During one attack the patient was absolutely blind, with widely dilated pupil (O. D.). An ophthalmoscopic examination revealed arteries reduced to fine, bright yellowish threads with no blood visible in them, and there was a round reddish spot at the macula. Wagemann could observe the gradual refilling of the vessels, and in one-half hour the vision was again normal. These attacks had been recurring for two months. An iridectomy subsequently performed put an end to the attacks. Hughlings Jackson called the condition epilepsy of the retina, and speaks of a female patient who had transitory visual obscuration, expressing the opinion that she had suffered from an attack of retinal epilepsy.

Is not one year a rather long duration for spasm of the retinal arteries to last, and was the condition of the retinal arteries marked enough to be called a spasm?

DR. H. F. HANSELL, Philadelphia: I think the diagnosis is justified by the symptoms and strengthened by the recovery. In two cases of monocular blindness under my own care the diagnoses differed entirely from that of Dr. Bruns. In my cases the only symptom in both was sudden and complete monocular loss of sight. The cause in the first case was probably an embolism of a branch of the central

* Dr. David Edsall, Phila., Jour. Amer. Med. Assoc., December 4, 1909, p. 1873.

artery of the retina in the optic nerve. The second case was probably due to hemorrhage and edema in the sheath of the optic nerve. There was absolute loss of light perception in all parts of the field. Partial recovery ensued, but central vision remained dull. There was only slight edema of the nerve, without other ophthalmoscopic changes, so that the pressure on the nerve must have been behind the entrance of the retinal blood-vessels. Cure might have taken place without medicine, as in Dr. Bruns' case, but I did not feel justified in withholding treatment, and gave ascending doses of potassium iodid. She took enormous doses—500 grains daily for nearly three weeks—without symptoms of iodism.

DR. H. D. BRUNS, New Orleans: Leaving out of consideration scientific precision, it seems to me quite important whether we decide in a given case that we are dealing with an arterial spasm or with ischemia. In one case we will do all we can to build up the patient and relieve the anemia; in the other, we simply give amyl nitrite. The weak point in this case is the length of time it lasted, but it will be seen, in even the few excerpts from the literature I have been able to make, that the length of time spasm may last extends from a few moments into months, as in Alexander's case. We see, too, that in this case improvement soon took place, although it was long before vision became normal.

SOME OBSERVATIONS ON THE USE OF THE SCHIÖTZ TONOMETER.

W. B. MARPLE, M.D.,
New York City.

For years ophthalmologists have appreciated the desirability of having a more accurate method of estimating the intra-ocular tension than by digital palpation, and we have had numerous tonometers devised by ingenious confrères at various times in the past twenty years; among them have been those of Fick, Maklakoff, Priestley Smith, and others. Those who are interested in the history of tonometry will find the subject discussed in the second edition of Graefe-Sæmisch, vol. iv, p. 606, and in the third volume of Parson's Pathology, p. 1043. But while some of these instruments have registered the intra-ocular tension pretty accurately, none of them has ever come into general use either because of their complicated construction or else because to use them required too much time. We have, therefore, continued to employ the tactus eruditus in the estimation of tension, and have continued to express the latter in terms of T + 1, + 2, + 3, etc., although we have all appreciated the inexactness of this method, and how largely the personal equation entered into the result. In fact, the very name "tonometer" has almost become synonymous in the minds of most of us with some impractical, time-consuming laboratory device; so much so that if you mentioned tonometer to a confrère, the suggestion would be received with an incredulous shrug of the shoulders. I must confess that my mental attitude in reference to the matter was a similar one, so that when Schiötz published

his articles on his tonometer in 1905 and 1908 (Arch. f. Augenh., vol. lii, p. 401; vol. lxiii, p. 317), they made little impression on me, and I thought of it as probably one more addition to the large list of such devices which would never be of any practical value. Something more than a year ago, however, when my friend, Dr. E. V. L. Brown, of Chicago, en route home from Vienna, told me that Schiötz's instrument was in constant use in Fuchs' clinic and was giving good results, I determined to get one and give it a trial. I have been so much pleased with my observations with it during the last year that I venture to present them briefly, hoping thereby to induce some who have not as yet used the instrument to give it a trial. In my opinion it is a most valuable addition to our ophthalmologic armamentarium, especially in everything which pertains to glaucoma.

Description of the Instrument.—The long rod (3 mm. in diameter) "*a*" slips easily up and down in the cylinder "*b*." The lower end, which is to rest on the cornea, is concave (15 mm. radius); the upper end is pointed; a little below the point on one side is a little projection. The pointed end of the rod slips through a hole in the weight "*e*"; at one side of the hole is a groove for the projection on the rod, and the weight is fastened to the latter by a slight turn, so that the rod will not fall out when the instrument is held up. The cylinder "*b*" has at its lower end a foot-piece 9 mm. in diameter, the bottom of which forms a concave surface with a radius of curvature of 15 mm. Upon the upper end of the rod, when the apparatus is in use, rests the curved arm which is the short arm of a lever; by its weight it always follows the movements of the rod up and down. The point of contact of the rod is 4 mm. from the fulcrum of the lever. The long arm is formed by the vertical indicator, 80 mm. long. The relation between the two arms is, therefore, as 1 is to 20; that is, the excursion of the indicator is 20 times that of the movement of the rod. When the lower end of the rod stands on a level with the concave surface of the foot-piece below, the indicator stands at the 0 point of the millimeter scale above;

if the rod moves down 1 mm., then the indicator makes an excursion of 20 mm. Around the cylinder "*b*" is attached a cuff "*c*," by the two arms of which, bent upward, the apparatus is firmly held when in use. In the walls of this cuff are little roller wheels which diminish the friction. (These have been found to be unnecessary.)

The foot-piece of the cylinder "*b*," which is to rest on the middle of the cornea, is concave on the lower surface, with a radius of curvature of 15 mm. Schiötz selected so high

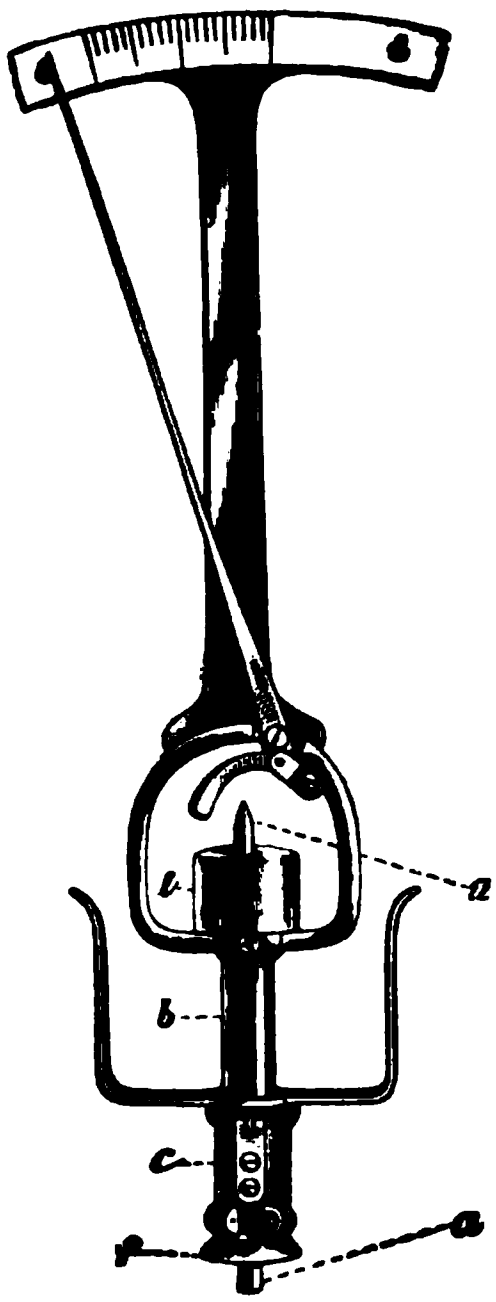

a radius of curvature so as to be sure that in all cases the curvature of the cornea was greater than the concavity of the foot-piece; for if the cornea is flatter than the concavity of the foot-piece and rod, it would have to descend a little before it touched the cornea, and thus the indicator would make a movement along the scale without any corresponding impression and the measurement would be inaccurate. The apparatus as at present constructed registers somewhat

too low, but this is a constant small error, and, therefore, without significance as to the relative value. The apparatus can also be so constructed that the cylinder "*b*" can be unscrewed and replaced by others with different concavity, as, for example, with a radius of 12 or 10.

When the instrument is used, the patient can either lie on a table or sit in a reclining chair with the head thrown back. In my office I have no difficulty with the patient reclining in a chair and the head thrown back, so that the eyes are directed upward. In fact, I have used it with the patient sitting up in a straight-back chair and head tipped back, though this is a rather tiresome position. Schiötz uses a 2% holocain solution, as this does not dilate the pupil, but I have found that with a solution of cocain as weak as 2% the procedure was much less disagreeable than with holocain. When tension is present, he instils a miotic afterward. The patient is directed to look directly upward, while the observer separates the upper and lower lids with the fingers of one hand, being careful in doing this to make no pressure upon the eye. With the other hand the observer takes the instrument, holding it by one or both of the two arms attached to the cuff, which slips up and down the hollow cylinder. The foot-piece is brought so as to rest exactly on the cornea when the cuff is slid down, so as to stand about the middle of the cylinder. In this position the apparatus stands freely, and should be held exactly vertical and exactly on the center of the cornea. The system (including the small rod, the lever, and weight if one is on at the time) then presses upon the center of the cornea, and one reads off from the scale what the indicator registers. Occasionally a speculum is necessary. Three measurements are made, and the average of these three readings is taken.

Different weights are used, marked 5.5, 7.5, 10, and 15. In the first, 5.5 represents the weight of the little rod (2 gm.), plus that of the lever (2 gm.), plus that of the weight (1.5 gm.)—total, 5.5. The weight 7.5 likewise represents the weight of the rod, lever, and weight (2, 2, and 3.5), etc. When no weight is used, we have simply the rod and the lever, or 4 gm. in all, which is used in cases of marked hypotony. If the intra-ocular tension is high, the indicator would make no excursion with a certain weight, which,

when employed in measuring a normal eye, would give a definite reading. The instrument itself weighs 12 gm.

In taking the tension of an eye, we usually begin by putting on the first weight marked 5.5 gm., with which, if the tension is normal, we get a measurement of about 5 mm. If the tension is high, the indicator may stand at 0 on the millimeter scale above, or even to the left of this. In this case we put on the next weight, or 7.5. Readings on the scale somewhere between 3 and 6 or 7 are the most accurate. For example, if with weight 5.5 the instrument registers 1, while with 7.5 it registers 5, the latter is a safer number to take.

By means of the table of curves accompanying the instrument in which the abscissæ represent the reading of the tonometer, and the ordinates the number of millimeters of mercury, we quickly find the intra-ocular tension. For example, if with the weight 7.5 the instrument registers 5, we find that this corresponds to 35 mm. of mercury.

The four upper curves on the diagram correspond to the weights 5.5, 7.5, 10, and 15. In many instruments there is a lower curve, marked 4, which represents the tension in hypotony when we use no weight. Here the 4 represents the combined weights of the little rod and the lever alone (each weighing 2 gm.).

With the apparatus comes a little metal model to test the instrument before using it. When the foot-plate is rested upon the model, the curvature of the latter is such that the indicator stands at the null point of the scale.

So much for the instrument. It is made by N. Jacobsen, Pilestraedet 25, Christiana, Norway. Professor Schiötz states in his article that its cost is 45 Kroner, but those I have imported have cost 65 Kroner, or $17.50 in Christiana. Delivered to me in New York one cost me $20.00, no duty; the other, $28.00 (duty of $8.00). As to the possibility of their manufacture in this country, in a letter from Professor Schiötz he states that the only difficulty would be the testing of them. At present each instrument is most carefully tested before being put into stock, which, of course, is a most important matter.

The reader is referred to Schiötz's article for a fuller description of his method of making the curves accompanying the instruments showing the equivalent in millimeters of mercury of any reading on the tonometer. Suffice it here to say that his experiments were made with fresh pig's and human eyes, into the anterior chamber of which he would introduce a cannula connected with an Esmarch irrigator filled with water. This was hung on the wall and raised 10 cm. at a time, until the pressure reached a height of 170 cm. He then took the tension of the dead eye with the varying weights, and knowing the equivalent in millimeters of mercury to the varying number of centimeters of water, constructed the curves. He had the assistance of his brother, who is Professor of Physics in Christiana, and the curves are marked out with the greatest mathematic accuracy.

Fearing injury to the cornea, Schiötz at first rested the instrument upon the sclera below, between the inferior and external rectus muscles. Finding, however, that his fears as to the cornea were unfounded, he later placed the instrument upon the cornea, and in my examinations I have always done this.

Now as to its practicability. Is it difficult to use or does its use take a long time, or will its appearance alarm a patient? Is it difficult to become expert in its use? To all of these questions I would answer no. Two drops of holocain, instilled at intervals of two minutes, or preferably 2% solution of cocain (if the eye is not glaucomatous), and the eye is ready. Three observations on each eye can be taken in five minutes. On the part of intelligent patients in my office I never have had the least objection to its employment. Occasionally it tries one's soul to take the tension of some of the stupid people we run across at the clinic, but I have never yet failed altogether. In a very short time one becomes expert in its use.

Are its observations accurate? Over and over again I have taken the tension of a patient, written down my result, and then had the tension taken by two or three of my assistants, who would write down their observations, and frequently our determinations have been exactly the same, and never has the variation been a considerable one—possibly 1 or 2 mm. of mercury at the most.

One frequently sees movements of the indicator synchronous with the pulse, and in normal eyes, as well as in those with increased tension. These pulsations cause an oscillation of the indicator of 0.5 to 1 mm. on the scale.

Again, if the same eye is experimented on for some time, the tension seems to diminish slightly, as some fluid is evidently pressed out of the eye by the continued experiments. This observation was repeatedly made.

Normal Tension.—What is the range of tension in normal eyes? Schiötz, in his first report, stated that the normal tension varied between 24 mm. and 31, averaging about 26. Further use of the instrument for four years, however, led him to modify this, and he now gives it as from 15.5 to 25. Stock put the lowest limit in normal eyes as 12, but found only two cases with so low a tension. He also met with 7 cases out of 100 with tension of 26. In a considerable number of observations by ourselves on normal eyes the tension has varied from 15 to 24. (Table follows.)

TABLE A.—94 NORMAL EYES.

13	mm.	Hg	2	eyes (keratoconus).
14	"	"	2	"
15	"	"	3	"
16	"	"	5	"
17	"	"	8	"
18	"	"	11	"
19	"	"	12	"
20	"	"	17	"
21	"	"	19	"
22	"	"	2	"
23	"	"	11	"
24	"	"	2	"

I have never met with a tension above 25 in a normal eye, and should be inclined to look upon anything above 25 (certainly above 30) as suspicious.

That is, out of 94 eyes, 80 had tension between 17 and 23. The average tension of these 94 eyes was 19.5 mm. of mercury.

Since our paper was finished, an article by Stock on the Schiötz tonometer has appeared (April, 1910) in a supplementary number of the Klin. Monatsbl., which I have just read. In it he gives the history of a case of chronic simple glaucoma of both eyes in a woman aged sixty. There were deep excavation of both nerves, narrow nasal fields, impaired vision, and the tension of the right eye was 22 mm. and of the left 25 mm. Stock concludes that these eyes must have been originally physiologically soft; that is, it is possible to have glaucoma where the tension seems to be within safe limits. The observation is an interesting one, and Stock has seen only one such case. I myself have never seen a case of glaucoma where the tension was not above 30.

TENSION IN DIFFERENT REFRACTIVE CONDITIONS.

Observations were made on a considerable number of hyperopic and myopic eyes, but no significant difference in tension could be noted. In emmetropic cases the lowest tension observed was 18 mm., the highest, 23. In hyperopia the lowest noted was 18 mm., the highest, 21. In myopia the lowest was 17.4, the highest, 24, except in one case of detachment, which had been under treatment, without any improvement, for six weeks in bed, and with subconjunctival injections of chlorid of sodium and dionin. The tension of the eye with detachment was 13½, and of the other eye (high myopia), 20. The tension of another patient (—5 D.) with very recent detachment was 13 + in the eye with detachment, and 15 in the other eye—that is, the tension

is apt to be lower in cases of old detachment than in recent ones.

Nor have I been able to observe any uniform difference in the tension of normal eyes in a patient of different ages, that is, from childhood up to fifty or sixty.

The tonometer is of the greatest value in establishing the early diagnosis of glaucoma. May I cite briefly two cases?

Mr. S., aged thirty. O. D., marked excavation. Vision, fingers at 5 feet. Field contracted to nasal side. O. S., $\frac{20}{20}$. Fundus and field O. K. Tension, O. D., 50 mm.; O. S., 33 mm. After pilocarpin in O. D. tension fell to 37. The tension in the left eye is high, and should be kept under close observation. Three months after iridectomy in the right eye the tension had fallen to 18.

Another patient, female, aged forty-eight. Has marked physiologic excavation O. D., with vision $\frac{20}{15}$ and normal field. O. S., glaucomatous excavation; vision, $\frac{20}{20}$. Nasal half of field contracted. The tension in each eye was just the same, viz., 37½ mm.; that is, way above the danger-point. In harmony with this was the examination with the Bjerrum field. In neither eye did this field reach to the blind spot, going to 9° to the temporal side of the fixing point in the left or apparently glaucomatous eye, and only to 11° in the right or apparently normal eye. That is, in this case there was not a suggestion of glaucoma in the right eye by ordinary methods of examination, the vision and field and fundus normal. But the tonometer shows the tension of both eyes the same, viz., 37½, or pathologic, and the Bjerrum field is characteristic in both eyes, and there could be no doubt but that the patient had glaucoma in both eyes. In fact, if I meet with a patient with glaucoma in one eye I almost invariably find the tension of the other eye above 30, or what might be called the danger-point.

The tension in glaucoma cases has ranged from 35 or 40 up to 134 in one case of absolute glaucoma. In one case of acute glaucoma it was 65, and two hours afterward, during which pilocarpin was instilled, with resulting miosis, fell to 33. These cases were met with repeatedly, and were

interesting not because the tension fell, but because we could measure exactly how much it fell. In one case of chronic glaucoma the tension was 55 before operating, and three weeks after iridectomy it had fallen to 26. In another case, where an acute attack had been untreated for five weeks, the tension before iridectomy was 93.5; three weeks after operation it was 32.5. In all these cases the tension of the other eye was considerably above the danger-point of 30.

Schiötz reports one very suggestive case in his first article (1905). In a patient with chronic simple glaucoma the useful effect of pilocarpin was measured with the tonometer, and in one eye the tension fell from 77 mm. to 36, and was kept there for some time with pilocarpin. Then an iridectomy was made, and afterward the lowest point to which the tension could be brought was 43, even with pilocarpin. It was evident that the pressure conditions were not as favorable following the iridectomy as with the use of pilocarpin alone, an observation which should make us consider very carefully the question of operating in these cases.

Low Tensions.—As instances of low tension was one of 10 mm. in a case of cyclitis following extraction, and one of 12 mm. in a case of cyclitis following removal of foreign body which entered in the ciliary region. This eye was subsequently enucleated. In a case of cataract seen recently, where the projection was a little uncertain in one quadrant, the tonometer showed a tension of only 8, and it was very apparent that we were dealing with a case of detachment. It occurs to me that from its use we can get a hint as to the likelihood of a detachment ever occurring in the second eye. I have referred to a patient met with in my private practice with a recent detachment in the left eye. Tension here was 13, and in the good eye 15. This latter is a very low tension, and I think it very much more

likely that a detachment may some day occur in the other eye than if its tension was 20 or 25.

EFFECT ON TENSION OF DRUGS.

Appended is a table (B) showing the tension in eight patients in whose eyes were instilled drops of 4% solution of cocain, 1% atropin, 1% pilocarpin, 2% pilocarpin, and 0.25% eserin. In each case the tension was first taken (first test), then a drop was instilled. In one-quarter of an hour the tension was again taken (second test), and another drop instilled. In three-quarters of an hour the tension was again taken (third test), and another drop instilled. In one and one-half hours another drop; in one and three-quarters, final tension (fourth test).

The tables speak for themselves, and simply corroborate the results of Schiötz's observation. In *normal* eyes none of these solutions appeared to have any effect on the tension. Pilocarpin appears to raise the tension slightly at first. The cocain cases, where great dilatation of the pupil took place, did not show any tendency to increase of tension more than those where the pupil dilatation was slight or not at all.

I have several times been asked by my colleagues to translate millimeters of mercury as registered by the tonometer into terms of T + 1, etc. While, of course, it is not possible to do this accurately, one might provisionally suggest the following: Tension from 25—40 mm., as T + ; from 40—60 mm., as T + 1; 60—90 mm., as T + 2, and anything above 90, as T + 3, as in cases of absolute glaucoma.

Stock states that cocain is useless in tonometry. Accordingly, we took the tension of five cases first with holocain and then with cocain. In three of the cases the pupils were dilated and in two the pupils were not affected. The tension after cocain was just the same as after holocain.

This is true where the eye shows no disposition to increase of tension. In one of Schiötz's cases, however, where there was a tendency to increased tension, the use of cocain dilated the pupil and increased the tension very markedly, so that pilocarpin had to be used energetically to reduce it.

TABLE B.

DRUGS.	First.	Second.	Third.	Fourth Test.
Cocain, 4%	20.0	18.0	21.0	18.0
	20.0	18.0	21.0	18.0
	21.0	19.5	21.0	21.0
	18.0	18.0	19.5	21.0
	21.0	21.0	23.0	21.0
	21.0	21.0	19.5	21.0
	14.0	13.0	14.0	15.5
	14.0	14.0	14.0	15.5
Atropin, 1%	16.5	16.5	16.5	16.5
	16.5	16.5	16.5	16.5
	23.0	23.0	25.0	23.0
	23.0	23.0	25.0	23.0
	19.5	19.5	19.5	23.0
	19.5	23.0	21.0	23.0
	23.0	23.0	21.0	19.5
	21.0	23.0	19.5	19.5
	..	13.5	13.5	14.5
	..	14.5	16.5	16.5
Pilocarpin, 1%	15.5	18.0	15.5	14.5
	15.5	18.0	15.5	14.5
	16.5	16.5	18.0	19.5
	18.0	18.0	15.5	21.0
	19.5	19.5	21.0	21.0
	19.5	19.5	21.0	21.0
	16.5	23.0	19.5	16.5
Pilocarpin, 2%	18.0	23.0	18.0	16.5
	13.5	15.5	13.5	13.5
	14.5	18.0	18.0	15.5
	23.0	23.0	23.0	23.0
	23.0	21.0	21.0	19.5
	16.5	15.5	19.5	18.0
	16.5	15.5	21.0	21.0
	18.0	20.0	18.0	15.5
	18.0	20.0	16.5	12.5
Eserin, 0.25%	19.5	23.0	25.0	23.0
	23.0	25.0	25.0	23.0
	23.0	25.0	21.0	23.0
	19.5	25.0	21.0	25.0
	23.0	23.0	21.0	21.0
	23.0	23.0	21.0	21.0
	21.0	16.5	16.5	16.5
	21.0	16.5	16.5	16.5

The figures are the average of three tests.

In his observation on pilocarpin and eserin Schiötz examined one eye with aniridia and one iridectomized eye, and in these the diminution of the tension following the pilocarpin and eserin was just as marked as in the other eyes, which shows that the effect is not wholly due to the miosis.

Stock examined one case of paralysis of the sympathetic on one side, but found the tension of each eye the same, also—an interesting observation.

Two recent and interesting articles giving results of tonometric observations are, first, by Meller, on Sclerectoiridectomy, in the Klin. Monatsbl. f. Augenh., December, 1909, and, second, the article by Stock, already quoted in the recent Beilageheft of the same journal.

CONCLUSIONS.

1. The instrument is thoroughly accurate. I have two tonometers and invariably have the two instruments registered exactly alike.

2. Neither refraction nor age has any influence on the tension.

3. In normal eyes the drugs ordinarily used as mydriatics or miotics have no appreciable effect on tension. Neither does cocain.

4. The normal tension varies between 15 and 25 mm. of mercury; anything above 25 is suspicious; anything below 14 is hypotony.

5. The average normal tension in our cases was 19.5. We have demonstrated repeatedly what an unsafe guide as to tension is the finger, for with the tactuse ruditus a tension is not recognized unless above 35, nor is a minus tension appreciated as such unless as low as 10 or under. Also, an eye with a stiff sclerotic oftentimes gives to the fingers the impression of increased tension when the tonometer shows it to be normal.

6. Its greatest value is in determining low degrees of tension and in excluding plus tension.

I believe the tonometer has come to stay and that it will not be long before the Schiötz instrument (until a better one is devised) will be as indispensable a part of the skilful oculist's armamentarium as is today that other instrument, to the perfection of which, also, Schiötz collaborated so ably with Javal, the ophthalmometer.

I want here to express my appreciation of and thanks for the painstaking and careful manner in which my assistant, Dr. George Young, has made for me the largest part of the observations on which the conclusions in this paper have been based.

DISCUSSION.

DR. CHARLES J. KIPP, Newark: I have used this instrument for about three months, and have had considerable difficulty in its employment. Even with cocain there are many patients who will not hold sufficiently still to enable one to make reliable measurements. As to its reliability, I suppose there is no doubt whatever.

THE HISTOLOGIC FINDINGS IN A CASE OF TUBERCULOUS CYCLITIS, AND A THEORY AS TO THE ORIGIN OF TUBERCULOUS SCLERITIS AND KERATITIS.

F. H. VERHOEFF, A.M., M.D.,
Boston.

(From the Pathologic Laboratory of the Massachusetts Charitable Eye and Ear Infirmary.)

(The photomicrographs were made by the Pathologic Department of Harvard University.)

Cases of episcleritis, scleritis, and sclerokeratitis, with nodule formation, are generally classified according to etiology into two groups—one group comprising the cases of rare occurrence due to syphilis, leprosy, or active tuberculosis, and the other those of frequent occurrence due to some obscure cause, commonly supposed to be rheumatism. The second group is typified by a distinctive clinical condition designated anterior nodular scleritis. In a previous communication* I have brought forward evidence to show that the latter condition is always due to tuberculosis. This evidence, while partly histologic, consisted chiefly in the results of subcutaneous tuberculin injections in a consecutive series of cases. Since then I have confirmed my observations in a still larger series of cases, and in every case have obtained a general reaction, and in most cases also a local reaction, to the tuberculin test. While a local reaction in the eye did not always occur in the diagnostic tests, it could practically always be obtained later if treatment with old tuberculin was carried out with this end in view. Local reactions repeatedly obtained in this way are, I am convinced, desirable, contributing, as I have elsewhere

* Tuberculous Scleritis, a Commonly Unrecognized Form of Tuberculosis, Boston Med. and Surg. Jour., March 14, 1907, p. 317.

maintained,* largely to the success of the tuberculin treatment, provided sufficiently long intervals are allowed to elapse between them.

I have also pointed out that no sharp distinction should be made between cases of apparently pure tuberculous keratitis and cases of sclerokeratitis, that they both represent the same type of chronic ocular tuberculosis, and that, in fact, most often, if not always, tuberculous keratitis has been preceded by scleritis. In addition, I have called attention to the fact that, like tuberculous scleritis, tuberculous keratitis has characteristic clinical features which serve to distinguish it from other forms of interstitial keratitis.

My experience in connection with ocular tuberculosis has been sufficiently extensive to justify the belief that the failure of certain observers to obtain equally consistent results with the tuberculin test in cases of anterior nodular scleritis has been due either to some error of technic or procedure in making the test, or to an erroneous clinical diagnosis. Probably the condition that is most often mistaken for nodular scleritis or sclerokeratitis is the neuropathic conjunctivitis recently described by me.† This occurs under the same conditions as neuropathic keratitis—most commonly under those which give rise to facial herpes, with which, in fact, it is often associated. Gumma of the ciliary body and sclera, judging by the few cases I have seen of this rare condition, should not readily be mistaken for tuberculous scleritis. Leprous scleritis is, of course, too rare to give rise to any confusion, and in any case its nature would, no doubt, be rendered clear by the presence of other manifestations of leprosy.

Admitting that anterior nodular scleritis and sclerokeratitis are due to tuberculosis, the questions arise why

* Some General Considerations Concerning Tuberculosis of the Eye, Ophthalmic Record, December, 1908.

† Neuropathic Keratitis and Some Allied Conditions, Jour. Amer. Med. Assoc., July 17, 1909.

such resistant and relatively avascular structures as the sclera and cornea should be the favorite sites of ocular tuberculosis, and how it is that the infection reaches them. The experimental observations of Stock* suggest that tuberculous scleritis is due to extension from a metastatic focus in the uveal tract. This apparently satisfactory explanation, however, is not supported by the results of a number of histologic examinations which showed the ciliary body practically normal. It is not borne out also by clinical observations, which, on the contrary, go to show that cyclitis is a late occurrence in scleritis, and apparently secondary to the latter. The experiments of Stock were made under highly artificial conditions—conditions that more resemble those obtaining in miliary tuberculosis than in the chronic tuberculosis of scleritis. Moreover, in the two animals in which Stock actually obtained scleritis, the latter obviously can be explained equally well by the theory that I shall bring forward in this paper. This theory was suggested by the following case, which, by its exaggeration of certain features possibly unusual, pointed to the explanation of features not unusual. The case also afforded an exceptionally good histologic picture of both the late and early stages of tuberculous scleritis and keratitis.

Frances F., female, aged thirty-four, admitted to the Massachusetts Charitable Eye and Ear Infirmary October 14, 1908. Fairly well nourished and general health good. Highly nervous temperament. Previous health good except that patient stated that she had pleurisy (?) ten months ago. She also stated that her left eye was affected similarly to present attack four and one-half years ago, and that the vision afterward remained much impaired. The present attack began two months ago, the left eye becoming increasingly red and painful.

* Tuberkulose als Ætiologie der chronischen Entzündungen des Auges und seiner Adnexe, besonders der chronischen Uveitis, Graefe's Arch. f. Ophthal., 1907, lxvi, p. 1.

On examination the right eye was found apparently normal, and with normal visual acuity. The left eye showed near the limbus above two small, reddish-yellow nodules, typical of tuberculous scleritis. There was only moderate circumcorneal injection, intensified at the sites of the nodules. The cornea showed old interstitial gray opacities, most marked laterally where they extended out from the limbus on both sides. There were apparently no active foci in the cornea, the opacities evidently being due to old sclerokeratitis. The iris showed a few old posterior synechiæ, but was little inflamed. Visual acuity of left eye, $\frac{1}{400}$. General physical examination negative.

Atropin solution was instilled into the eye, and the temperature taken every two hours for forty-eight hours as a control preliminary to the tuberculin tests. The temperature was constantly within normal limits. Koch's old tuberculin, 1 mg., was then injected subcutaneously, followed by no reaction in forty-eight hours. Ten mg. were then injected. This was followed by a febrile reaction of 101° F., a reaction at the site of the injection, and a local reaction in the eye consisting in increased congestion and pain. After lasting several days the local reaction in the eye gradually subsided, leaving the eye slightly improved. October 31, 1908, the patient was discharged.

After leaving the hospital the patient attended the outpatient clinic, where an attempt was made to carry out the usual antituberculous treatment—forced feeding, rest, fresh air, and tuberculin injections. This was found difficult, owing to the nervous temperament of the patient and her lack of pecuniary means. Nevertheless, she gained steadily in weight and the eye slowly improved. Koch's old tuberculin was injected once a week, or once in two or three weeks in case a reaction resulted from the previous injection. The doses varied from 1 to 2 mg., an attempt being made each time to regulate the dose so as to produce a slight reaction. As a result, slight local reactions in the eye were obtained several times, thus confirming the diagnosis. After five months' treatment the eye was free from inflammation and the patient was allowed to go to her home, which was at considerable distance from the city.

Six months later the patient returned to the hospital

stating that about two months after discontinuing the tuberculin treatment her eye had again become inflamed, and that recently it had become excessively painful. There was very slight ciliary injection, and no nodules of scleritis. On account of the old corneal opacities it was difficult to determine whether or not there was active keratitis or iritis. The tension was markedly lowered, and the visual acuity reduced to the counting of fingers at two feet. At the urgent request of the patient, who, owing to the pain and other circumstances, did not desire to undergo another course of prolonged treatment, the eye was enucleated by Dr. Savage, September 17, 1909. When last heard from, in February, 1910, the patient was in excellent health.

PATHOLOGIC EXAMINATION.

After remaining in 10% formalin several days, the eye was opened and photographed. After three months in the formalin it was placed in a saturated solution of potassium bichromate for two days, washed in water six hours, and embedded in celloidin.

The globe is distinctly quadrilateral in shape, and measures, anteroposteriorly, 21.5 mm.; vertically, 20 mm.; horizontally, 21 mm. The cornea, 11.5 mm. x 11 mm., shows extensive old sclerosing keratitis at the limbus, and several opaque interstitial spots away from the limbus (Fig. 1). Three of these are well defined, one of which is especially opaque. The surface of the cornea is perfectly smooth. The anterior chamber is of normal depth. The pupil, 1.5 mm. wide, shows numerous posterior synechiæ. The root of the iris in general is free, but here and there adhesions to the ligamentum pectinatum can be made out, which, however, do not extend to the apex of the angle. The lens is *in situ* and apparently normal. The internal surface of the ciliary body shows 10 discrete opaque white areas, making a striking picture (Fig. 2). All these are slightly elevated and are situated on the ciliary processes, except three, which are just behind them. The largest is 1.5 mm. in diameter; the smallest, 1.5 mm. The larger ones appear to be conglomerations of several small ones. The largest ones are situated about 4 mm. apart. They do not correspond in position accurately to the corneal

Fig. 1.—Photograph of anterior portion of globe after fixation in formalin. Showing corneal opacities of old sclerokeratitis.

Fig. 2.—Same specimen seen from behind, showing punctate tuberculous exudates on surface of ciliary body. Note the conglomerate character of the larger exudates.

Fig. 3.—Section of one of the ciliary exudates Its origin from the ciliary processes and its conglomerate character are well shown. Note also the character of the adhesion of the iris root to the ligamentum pectinatum and the vascularization of the sclera and cornea leading from the ligament (photo. × 18).

Fig. 4.—Same ciliary exudate under higher magnification Note that the overlying

opacities. The choroid and retina are *in situ* and apparently normal. The optic disc is greatly swollen.

Histologic Examination.—Sections were made at close intervals, so that practically the entire anterior part of the eye was examined. Many of the sections were mounted serially.

Cornea.—The corneal epithelium and Bowman's membrane are everywhere intact and normal, except that the epithelium shows an insignificant infiltration with leukocytes. Descemet's membrane is also intact. The endothelium is normal except beneath some of the active corneal lesions to be described. Clumps of cells, chiefly large lymphocytes, are infrequently found adhering to the endothelium. The anterior one-fourth to three-fourths of the corneal stroma is, for the most part, normal. The posterior portion is vascularized, vessels being found in a median section from limbus to limbus (Fig. 9). The vessels occur chiefly four to five lamellæ anterior to Descemet's membrane, and almost no vessels are found anterior to the middle layers of the cornea. In places where they extend out from the ligamentum pectinatum they are immediately in front of Descemet's membrane. The vessels are in general large, and although three or four smaller ones may occur together, they are usually widely separated from each other. The vessel-walls seldom consist of more than a single layer of endothelium. In this vascularized portion the stroma, except in certain places, does not depart greatly from the normal, the chief change being an increase in the number of corneal corpuscles. Even immediately around the vessels the stroma is, as a rule, little altered, the vessels simply pushing apart the lamellæ between which they lie. In areas, however, evidently corresponding to the corneal opacities, more marked changes are found, although these are not so great as the macroscopic appearance of the opacities would seem to indicate. In what appear to be the older opacities there is a decided increase in the number of fixed cells, but little disturbance of the lamellæ. Many of the cells here show a finely vacuolated or reticulated structure, no doubt due to the presence of fat-globules. Such cells are particularly noticeable about the blood-vessels. One small opacity of this kind is found just

beneath Bowman's membrane; all the others are in the posterior half of the cornea.

In one large area, evidently a scar of more recent date, the corneal stroma is replaced by tissue which has little resemblance to the normal. Here there is found ordinary fibrous tissue, with an abundance of cells which are larger than the normal corpuscles. Many of these cells contain large vacuoles filled with transparent substance staining bluish in hematoxylin, probably mucin. The fibrous tissue is slightly less eosinophilic than the normal lamellæ. The appearance produced closely simulates that of a fibrosarcoma. Behind this area, but not in continuity with it, there is a smaller area which is undoubtedly in an active stage (Fig. 11). This occurs immediately anterior to Descemet's membrane, is about ½ mm. in diameter, and situated 3½ mm. from the limbus. In this the corneal lamellæ are destroyed or so altered as not to be recognizable, and replaced by actively proliferating cells. The nuclei are large and lie in no one general direction. The cell outlines are not distinct; apparently the cell bodies are all continuous, forming a richly nucleated syncytium. There are no typical giant-cells of the Langhans type. The mucoid degeneration of the cells is more marked here than in the area just described. Intimately connected with the syncytium there is a newly formed ground substance which is more strongly eosinophilic than the normal stroma, and which gives the reaction for collagen with van Gieson's stain. This area is free from blood-vessels. Behind it Descemet's membrane is normal, but the endothelium shows marked proliferative changes. Its nuclei stain more deeply, and it is lifted up in places by new cells which have formed beneath it. Newly formed endothelial cells are also being cast off into the anterior chamber. The cornea also shows several old scars, corresponding in size to this focus, which, no doubt, would represent the appearance of the latter when healed. At these places Descemet's membrane is greatly wrinkled, due, no doubt, to the contraction of the scar tissue. At the periphery above, in the region of the active scleritis, there is an active tuberculous process continuous with foci in the ligamentum pectinatum, which extends for a short distance between Descemet's membrane and the

corneal lamellæ. Beneath this the endothelium shows changes similar to those beneath the active focus just described.

The Filtration Angle.—The ligamentum pectinatum is nowhere normal, but in some places it is more greatly altered than in others. Everywhere it shows an increase in its fixed cells, the nuclei of which stain more deeply than normal, and show other evidences of active proliferation. There is also infiltration of the spaces with chronic inflammatory cells. These cells, chiefly large lymphocytes, in places are also abundant, free in the angle, and, strangely enough, are about as abundant above as below. In some places the trabeculæ are not appreciably thickened, and the spaces of Fontana are well shown, but even in these situations small blood-vessels are almost always found in some of the spaces. In other places there is marked thickening of the trabeculæ, and almost complete obliteration of the spaces. Here the proliferation of fixed cells is excessive, and multinucleated cells are often seen. There are also large numbers of chromatophores. Some of the sections, which also include the foci of active scleritis, to be described, show still more definite tuberculous foci in the ligament, similar to the active focus in the cornea. The canal of Schlemm in all sections is much reduced in size, and in many it cannot be recognized. This seems to be due partly to compression by the new fibrous tissue around it, and partly to subendothelial proliferation of its own wall.

The filtration angle is practically never completely blocked by the root of the iris. Partial adhesions, however, occur in places. These are markedly different from those ordinarily seen in glaucoma. In some places delicate strands of iris tissue carrying blood-vessels bridge over the angle and unite with the ligament. Most often, however, the adhesions are more definite, the iris stroma, as a whole, being drawn over and fused with the ligament. These adhesions are especially noteworthy from the fact that, instead of taking place at the apex of the angle, they occur at a considerable distance therefrom, terminating, however, at the beginning of Descemet's membrane (Figs. 3, 4, and 8). These are the adhesions noted macroscopically. From these adhesions the chromatophores of the anterior boundary

layer of the iris sometimes have extended as a single layer of branching pigmented cells for a short distance over Descemet's membrane, replacing the endothelium. One set of serial sections shows one of these adhesions in an early stage of formation. It is seen, by comparison with a normal eye, that the adhesion is taking place at a point about opposite Schlemm's canal. It is seen also that the adhesion is not primarily due to inflammation of the iris, but to exudate and proliferated cells collected on the surface of the ligament having come in contact with the iris. By the contraction of this exudate it is evident that the close union of the iris to the ligament seen elsewhere would have resulted.

The Sclera.—In the region of the canal of Schlemm, and extending a variable distance backward, the sclera in places shows a marked increase in vascularization. The vessels are not only increased in number, but especially in size. The larger vessels consist simply of dilated spaces between the scleral fibers, lined by endothelium. These are, no doubt, veins. Some of the smaller vessels, evidently the arteries, show definite walls with muscular coats. Associated with this increased vascularization there is an alteration in the stroma of the sclera. The fibers are much distorted (Figs. 6, 7, and 9), are less eosinophilic than the normal sclera, and, in fact, present the appearance of scar tissue. In places these changes are limited to the region immediately about the ligamentum pectinatum, not extending further backward than the iris root. In fact, they sometimes extend further toward the cornea than backward in the sclera. The episcleral tissue at the limbus in those situations where the sclera is most affected is denser than normal, and vascularized with large vessels. Occasionally it also shows nodular infiltration with lymphoid cells.

In addition to the above changes, which are evidently the results of old scleritis, an active deep scleritis is found in one situation above (Fig. 8). As already mentioned, there is here an active focus in the ligamentum pectinatum, which extends also into the cornea. The vessels coursing backward from this region are surrounded by chronic inflammatory cells, while the stroma shows foci of actively proliferating epithelioid cells. These foci, which are similar

Fig. 5.—Small punctate ciliary exudate on *pars plana*, showing origin from subepithelial focus containing a giant-cell (photo. × 146).

Fig. 6.—Showing vascularization and scarring of sclera about the filtration angle at site of old scleritis. Note that the ciliary body is normal (photo. × 30).

Fig 7.

Fig. 8.

Fig. 7.—Section stained by van Gieson's method, showing scarring and vascularization of sclera leading from ligamentum pectinatum (photo. × 40)

Fig. 8. -Active scleritis extending from ligamentum pectinatum Active foci are present in the ligament in other sections of this series. The underlying ciliary body is normal, except for a slight infiltration with lymphoid cells opposite the scleral foci. Note the tuberculous exudate between the two layers of the *pars ciliaris retinæ*, involving the *pars plana*. Serial sections showed that this had no continuity with the scleritis. Note the adhesion of the iris root to

to the active focus in the cornea, occur not only at the same level, but at different levels in the sclera. The largest focus is in the middle layers of the sclera, over the orbiculus ciliaris. Beneath this there is a smaller focus which lies in the innermost layers of the sclera, and, by continuity, slightly involves the ciliary muscle. Serial sections show that there is here no continuity with any of the exudates on the surface of the ciliary body.

The Ciliary Body.—Except at the sites of the lesions seen in the gross specimen, and at the place just mentioned, the ciliary body is normal. In most places there is some exudation of lymphoid cells from the pars plana, but this is insignificant except in the vicinity of the gross lesions now to be described. These lesions are found to involve only the surface of the ciliary body, the underlying ciliary muscle being perfectly normal. They consist of sharply circumscribed exudates of actively proliferating epithelioid cells, with relatively few lymphoid cells (Figs. 3 and 4). They lie, for the most part, upon the inner surface of the pigment epithelium, which is in most places intact. At the margins of the exudates the unpigmented epithelium may be seen passing over or into the proliferated cells and losing itself therein. Here it appears that the epithelioid cells of the exudate are largely derived by proliferation of the cells, of the unpigmented epithelium. Closer examination, however, shows that in places the tips of the ciliary processes are broken through, and that it is from small foci just beneath the pigment layer that the cells of the exudate are chiefly derived. It is seen in these places that the proliferated cells raise up the unpigmented epithelium so that, in general, it may be said that the exudates occur between the two layers of the pars ciliaris retinæ. The epithelioid cells do not resemble discrete endothelial cells, but form a complicated, richly nucleated syncytium. In this, giant-cells of the Langhans type are occasionally seen. Upon the inner surfaces of these exudates, or rather upon the unpigmented epithelium which largely covers them, there is a smaller exudate of a different kind. This consists of elongated cells which extend along the fibers of the zonule. This exudate, on a small scale, appears to be identical with that generally seen in cyclitis, which finally leads to the

formation of cyclitic membranes. In some sections the conglomerate character of the larger exudates is apparent, separate foci having formed on adjoining ciliary processes and fused together.

Most of the exudates, as shown in Fig. 2, are situated on the ciliary processes. Those situated on the pars plana, however, are of the same nature. In the smallest of these the origin of the epithelioid cells is especially well shown. In this one there is a small focus just beneath the pigment layer, consisting of epithelioid cells, among which typical Langhans' giant-cells occur (Fig. 5). These cells have broken through the pigment layer and split the two layers of epithelium apart without anywhere breaking through the unpigmented layer.

The Iris.—Except for a slight infiltration with chronic inflammatory cells, most marked at the ciliary and pupillary margins and around the vessels, the iris stroma is not far from normal. There is, however, undoubtedly some increase in fixed cells. This is especially evident at the pupillary margin, where, in places, by cicatricial contraction, there is produced the beginning of ectropion uveæ. Extending out from the pupillary margin is a delicate membrane similar to that commonly seen in old chronic inflammatory conditions. This, however, does not completely block the pupil, because it is absent in the horizontal median sections. In one place there is a condition apparently analogous to the exudates of the ciliary body. A short distance from the pupil, on the surface of the pigment layer, there is a flattened nodule composed of epithelioid cells and an occasional giant-cell (Figs. 9 and 10). This is continuous, through a break in the epithelium, with a focus of similar cells just beneath the surface. This nodule appears to differ from those on the ciliary body only in the fact that it contains pigment cells, derived from the pigment epithelium, which take the place of the unpigmented epithelial cells of the ciliary exudates.

Other Ocular Structures.—The lens is almost normal, showing only slight vacuolization of the cortex at the equator. The choroid is normal throughout. The retina, including the multipolar ganglion-cells, is also normal. The optic disc shows marked edema. The condition is

Fig. 9.—Showing vascularization of cornea and sclera, and punctate tuberculous exudate involving posterior surface of iris continued into a synechia (photo. × 10).

Fig. 10.—Same iris exudate under higher power, showing giant-cell and origin from subepithelial tissue (photo. × 46).

Fig. 11.—Active tuberculous focus in posterior layers of cornea, *keratitis punctata profunda*. Note proliferation of endothelium beneath it. In the middle layers of the cornea is a larger and older focus (photo. × 32).

Fig. 12.—Showing papillitis, probably due to toxins carried along the central canal of the vitreous body (photo. × 14).

indistinguishable from the papillo-edema associated with brain tumor (Fig. 12). There is very slight infiltration with lymphoid cells about the large vessels, and an equally slight exudation of these cells from the surface of the disc. This, however, is too insignificant to distinguish the condition from choked disc. The lamina cribrosa is curved slightly backward, but not abnormally so.

Numerous sections of the ciliary exudates and of the active foci in the cornea and sclera, stained and examined for tubercle bacilli, give negative results.

The clinical features of this case, which were typical of recurrent tuberculous sclerokeratitis, and the local and general tuberculin reactions repeatedly obtained, show conclusively enough that it was one of chronic ocular tuberculosis. No doubt had circumstances permitted the patient to have resumed the tuberculin treatment, the lesions would have again healed.

The punctate tuberculous exudates (Figs. 2 to 5) involving the surface of the ciliary body and its processes, so far as I can find, have not previously been observed. The most probable explanation for them is that they resulted from recent metastases which lodged in the superficial capillaries of the ciliary body. This is supported by the fact that the sources of the exudates were evidently the small subepithelial foci which were connected with them through breaks in the epithelium. It is certain that they did not result from the direct extension of the scleritis or keratitis, because the underlying portion of the ciliary body was normal. It is also clear that they were not metastases from the vitreous humor, since there was no primary focus from which they could have arisen. No one of the exudates could have served as a primary focus for the others, because all were in approximately the same stage of development, the larger exudates representing conglomerates of smaller.

The form of tuberculous cyclitis hitherto recognized has been an interstitial tuberculous infiltration of the ciliary

body, occurring usually in continuity with scleritis, or, more rarely, as the active caseating form of tuberculosis. In this case the condition might well be designated superficial punctate cyclitis. Such a condition, occurring in an otherwise normal eye, would obviously produce the clinical picture of serous cyclitis. As is now well known, the tuberculin test has shown that this clinical picture is undoubtedly sometimes due to tuberculosis. I would not imply, however, that this is usually the case. On the contrary, my own observations lead me to believe that serous cyclitis is often due to some cause as yet unknown.

The condition found in the iris in this case was clearly analogous to that in the ciliary body, and hence might properly be termed superficial punctate iritis. The small nodule (Fig. 10) was not observed clinically, probably owing to the corneal opacities. It is evident, however, that, seen from in front, it would have the situation and appearance believed by Stock to be typical of chronic tuberculous iritis. This case, therefore, affords histologic support for Stock's belief, which was based purely on clinical observations. In addition, this case suggests that chronic tuberculous iritis is associated more often than not with superficial punctate cyclitis.

The papillitis in this case was no doubt analogous to that which often occurs in association with other inflammatory conditions affecting the anterior portion of the eye. Van der Borg* has suggested that it is here due to toxins carried through the central canal of the vitreous, and thus concentrated upon the disc. It is noteworthy that in this case the swelling of the disc was due to pure edema, practically unaccompanied by cellular infiltration or proliferation.

A condition of considerable interest was the extremely low tension the eye finally developed, although it was, of

* Die Papillitis im Auschluss an Erkrankungen des vorderen Teils des Auges, Klin. Monatsbl. f. Augenheilk., xlvi, 1908, p. 359.

course, not uncommon. Not a sufficient area, apparently, of the surface of the ciliary body was involved to account for this, and there was no atrophy of the ciliary body. Moreover, in one of the cases carefully examined by van Sparwoude* in which there was low tension, the ciliary body is described as practically normal. Judging by the amount of cicatrization about the filtration angle, high tension would have been expected. This, however, was at no time noted clinically, and the facts that the retina was normal and the optic nerve neither atrophied nor cupped shows that high tension could not have been present for any length of time. Two possible explanations suggest themselves: One is that, in spite of the obstruction in the ligamentum pectinatum and the canal of Schlemm, the excessive vascularization of this region permitted an undue outflow of aqueous humor. The other, which seems more probable, is that this excessive vascularization of the sclera, after it had become well established, reduced the capillary blood-supply pressure of the ciliary processes and consequently the pressure of the aqueous humor.

The active lesions in the cornea and sclera, consisting chiefly of small foci of epithelioid cells without caseation, were essentially similar to those described by other observers in cases of sclerokeratitis. On a smaller scale they appeared to be identical with those recently described by van Sparwoude* in three cases, and with those still more recently described in one case by Komoto.† They were also similar to the small excised nodules from cases of scleritis which I have elsewhere described.

Failure, as in this case, to find tubercle bacilli in sections

* Keratitis profunda scleroticans tuberculosa, Academisch Proefschrift ann de Universiteit van Amsterdam, 1909.

† Beitrag zur pathologischen Anatomie der Skleritis, Klin. Monatsbl. f. Augenheilk., xlvii, 1909, p. 761. In this case the observer contents himself with the bare statement that tuberculosis was excluded. Just how, is left to the imagination.

is, of course, not unusual in cases of chronic tuberculosis, but is none the less difficult to explain. It seems inconceivable that bacilli are not present in considerable numbers. Stock was usually unable to find them in his experimentally produced lesions, where they obviously must have been present. It, therefore, appears probable that in the tissues under certain conditions, doubtless having to do with immunity, they do not retain their characteristic staining reaction. A suggestion is given in regard to this by the exaggerated beaded forms often found in chronic lesions elsewhere, for it is not difficult to imagine that other bacilli must occur without even the beads, that is entirely unstainable by the usual methods. Animal inoculation was, unfortunately, not carried out in this case, owing to my absence from the city at the time the eye was removed. However, negative results are usually obtained after animal inoculation in cases of chronic ocular tuberculosis, owing, no doubt, either to the small dosage of bacilli or to the diminished virulence of the latter.

In regard to the source of infection in tuberculous scleritis and keratitis, the findings in this case lend no support to, in fact controvert, the view that it is through extension from foci in the uveal tract. On the other hand, it seems altogether improbable that scleritis is due to direct metastases from the blood. Against this is the fact that blood metastases to the sclera in cases of pyemia, malignant tumors, and miliary tuberculosis are practically unknown, if not entirely so. This is, no doubt, due to the fact that the sclera is poorly supplied with capillaries. There remains, however, a third explanation which I now desire to bring forward, namely, that the infection takes place from the filtration angle. Strong evidence that this is the true explanation is afforded by the changes in the region of the filtration angle in this case. At the sites of the old scleritis the vascularization and scarring of the tissue

extended directly from the ligamentum pectinatum (Figs. 6, 7, and 9). That the changes in and about the latter were not due to extension forward of scleritis occurring primarily further back was shown by the fact that in some places these changes were limited to this region. At the site of the active scleritis (Fig. 8) the inflammatory changes likewise lead directly from the ligament, within which active foci of epithelioid cells were found.* Accepting this explanation, it becomes obvious that the infection is carried to the filtration angle by the aqueous humor. As possible sources for the infection of the aqueous humor the exudates on the ciliary processes in this case suggest themselves. These were too recent, however, to explain the original scleritis. Moreover, no such lesions have been found in other cases reported, and in this case there were no old scars recognizable where similar lesions might have previously existed. On the other hand, it might well be that these exudates were unusual only in regard to size. It is even conceivable that when of such comparatively large size as in this case, they might heal without leaving recognizable scars. Still smaller ones could undoubtedly do this. However this may be, the occurrence of these lesions serves to establish the fact that tuberculous metastases may readily lodge in the superficial capillaries of the ciliary body, a fact that, *a priori*, seemed obvious. And it is not necessary to assume that definite lesions should always result for infection of the aqueous humor to ensue, for bacilli might readily pass through the intact pars ciliaris retinæ when carried in leukocytes or endothelial cells. Exudates on the posterior surface of the iris, similar to that in the present case, also offer possible sources for the infection of the aqueous humor, but, no doubt, they play only a subordinate part.

It may be asked here why it is that if, under these cir-

* Compare also Komoto's Fig. 4.

cumstances, lesions usually fail to develop, or undergo retrogression in the ciliary body, metastatic foci should form in the sclera. This can easily be explained by the poor capillary blood-supply of the latter. It must be remembered, too, that the lesions in the sclera, while sometimes of considerable size relative to the eye, are absolutely very small and show decided tendency to heal. Another question which arises is whether the recurrent attacks of scleritis are due to renewed activity of old foci or to fresh metastases. The frequency with which the second eye becomes affected indicates that the latter is often the case.

This explanation of scleritis obviously applies with equal force to the lesions of tuberculous keratitis. Where the latter occurs without definite scleritis, as it rarely does primarily, the infection, no doubt, is directly from the filtration angle, and produces either deeply seated discrete metastatic foci (keratitis punctata profunda) or extensions from the ligamentum pectinatum. Where scleritis has occurred, the infection may, in addition, take place similarly from foci in the sclera, giving rise to more superficial discrete foci, or, by direct extension, producing the so-called sclerosing keratitis.

The character of the adhesions of the root of the iris to the ligamentum pectinatum in this case (Figs. 3, 4, and 8) accords well with this theory. Unlike the adhesions in glaucoma, they do not involve the apex of the filtration angle, and occur only in certain sharply localized spots. The incompleteness of the adhesions is not an artefact, because this was recognized before the eye was placed in alcohol. In most instances the union is firm, evidently old, but one adhesion is found still in the formative stage. The appearances here are almost, if not quite, conclusive that the adhesion is due to the contact of the iris with an exudate which had formed over the central portion of the

ligament. The exudate is obviously to be explained as the result of tuberculous metastases from the aqueous humor.

This theory of the origin of tuberculous scleritis and keratitis gains additional support from the recent important work of Henderson* on the filtration angle. The significance, in this connection, of the following paragraph from one of his papers is apparent (page 172): "The main vessels of the venous system of the iris and ciliary body, including the afferent and efferent veins of Schlemm's canal, are surrounded by perivascular lymph-spaces. In the case of Schlemm's canal the sheath is absent on the inner side, so that the aqueous comes into direct contact with the walls of the sinus. I have never found pigment traveling along in a vessel, but always outside in the perivascular sheath. This is certainly a most important point which one would certainly dwell on if one were discussing the more detailed physiologic instead of the anatomic aspect of the aqueous outflow."

This fact, emphasized by Henderson, that the spaces of Fontana are connected with the perivascular lymph-spaces, explains why the nodules of scleritis occur so often in the region of the anterior perforating vessels, which he has shown elsewhere are almost all connected indirectly with the canal of Schlemm. He also has shown (p. 55) that the spaces are continuous with the corneal spaces, which explains how the cornea may be infected by extension or metastasis from the filtration angle. Henderson has also pointed out (p. 52) that the spaces of Fontana communicate with the suprachoroidal lymph-space. This suggests that the foci in the choroid, which occasionally occur in scleritis, are due to metastases carried from the filtration angle. More likely, however, they are analogous to the foci on the

* The Anatomy of the So-called Ligamentum Pectinatum Iridis and Its Bearing on the Physiology and Pathology of the Eye, Trans. Ophthal. Soc. of the United Kingdom, 1908, p. 47; also, the venous connections of Schlemm's canal, *ibid.*, p. 168.

ciliary processes in this case, that is, they are due to blood metastases lodging in the choriocapillaris.

Support is also given to this theory by a case of highly malignant intra-ocular sarcoma, which I have recently described.* In this case a small sarcoma of the ciliary body situated in the upper outer quadrant gave rise to numerous minute metastases in the filtration angle, and one comparatively large nodule in the episcleral tissue contiguous with the corneal limbus on the nasal side. The analogy to tuberculous scleritis is here almost perfect.

The occurrence of the metastatic tumor nodule at the inner side, instead of below, as might have been expected, brings up the question as to the most frequent sites of the foci of scleritis. To obtain, if possible, definite information on this point, Dr. Wm. Liebman, at my suggestion, has kindly examined the house records of the infirmary and tabulated the positions of the lesions recorded in a consecutive series of cases of scleritis and sclerokeratitis.† Both recent nodules and old areas of bluish discoloration were counted. Out of 46 lesions (42 cases), they occurred below only three times, above 24 times, to the nasal side, 12 times to the temporal side, 7 times. They occurred in the upper outer quadrant 15 times; in the upper inner quadrant, 5 times. These statistics show conclusively that the lesions are much more frequent above than below. On the theory of scleritis that I have just advanced this is difficult to explain, but it is equally so on any theory. The frequent occurrence of lesions to the inner and outer sides is explainable as due to the position of the eye with reference to gravity during sleep. A possible explanation of their still more frequent occurrence above is that it is in some way

* A Small Sarcoma of the Ciliary Body Showing Some Unusual Manifestations of Malignancy, Ophthalmology, July, 1908.

† Statistics as to the situations of the deep lesions of tuberculous keratitis would also be desirable, but at present are not obtainable, owing to the fact that clinical notes are not made with this object in view. Judging, however, from a few recent cases, these lesions are most common below.

dependent upon the repeated traumatism to the upper part of the sclera incident to the act of winking. This almost constant irritation might well cause small metastatic foci to reach macroscopic size, which elsewhere would undergo retrogression. That even slight trauma may stir into activity quiescent lesions I have several times had occasion to observe in the experimentally produced tuberculosis of animals.

CONCLUSIONS.

In tuberculous scleritis (anterior nodular scleritis), the infection reaches the sclera through the filtration angle. The infecting bacilli are derived chiefly from the superficial vessels of the ciliary processes, and are carried in the aqueous humor to the filtration angle. Whether there are always small initial foci on the surface of the ciliary processes, or whether the bacilli, contained probably in phagocytic cells, are exuded through the intact pars ciliaris retinæ, is uncertain.

In tuberculous keratitis the infection is also from the aqueous humor, the cornea becoming infected either by metastasis or extension from foci about the filtration angle, or in a similar manner from the foci of a preceding scleritis. In pure tuberculous keratitis, which rarely, if ever, occurs, the infection takes place in the former way only.

Two forms of tuberculous cyclitis are to be distinguished, namely, the interstitial and the superficial (punctate). Interstitial cyclitis is usually secondary to scleritis, and due to the direct extension of the latter. Superficial cyclitis occurs as direct blood metastases. Clinically, it manifests itself as one of the forms of serous cyclitis.

Superficial tuberculous iritis, involving the posterior surface of the iris, may occur, and is analogous to superficial cyclitis, with which it is probably often associated.

DISCUSSION.

DR. E. V. L. BROWN: I should like to ask whether Dr. Verhoeff made serial sections in all his cases.

DR. F. H. VERHOEFF: I have made serial sections, not of every one of the ciliary exudates, but of a number of them. As a matter of fact, they were not necessary, since an interstitial process in the ciliary body would have been evident in any section passing through one of the exudates on the surface. Sufficiently complete serial sections were made throughout the anterior part of the eye.

RECURRENT TUBERCULAR CHOROIDITIS.

CARL KOLLER, M.D.,
New York.

The prominent part which tuberculosis plays in the causation of eye diseases was not recognized before the beginning of the present century. Tuberculosis was formerly thought to occur but rarely, whereas the part allotted to syphilis was overrated. It was von Michel who first called attention to the fact that about 40 % to 50 % of all diseases of the uveal tract were tubercular in origin. In chronic inflammations of the choroid it was usual for ophthalmologists generally to be satisfied with classifying choroiditis with reference to the position, shape, and number of the foci, without giving much thought to the etiology. In the vast majority of the cases syphilis was supposed or implied. It is mainly to the incessant endeavors of Sydney Stephenson and George Carpenter in England, since 1901, that we owe any progress in the recognition of choroiditis which is tubercular in origin. They pointed out that tubercle of the choroid may be found at any stage and in any kind of tuberculosis, and that cases may occur without generalized tuberculous infection.

It is the object of this paper to show that tubercle of the choroid is not only more common than we have heretofore thought, but that it occurs with a distinct clinical picture, and should be classified as one of the ophthalmoscopically recognizable forms of choroiditis. Up to the present we have classified tubercle of the choroid under two headings: *First*, conglomerated (yellow) tumor-like tubercle, or so-called solitary tubercle, and, *second*, multiple miliary tubercles occurring in the choroid during the last stages of general tuberculosis, miliary tuberculosis, or tubercular meningitis.

In the third class should be placed miliary tubercles of the choroid, whether solitary or multiple, which run a chronic course, which recur, and which may be associated with chronic tuberculosis of other parts of the body, but may also frequently be found in persons in whom no other tubercular focus can be proved.

These cases were formerly almost universally, and are even now quite commonly, diagnosed as choroiditis syphilitic in origin. The general clinical picture of these cases is the following: A young adult, from twenty to thirty-five years of age, seeks advice because of a slight disturbance of vision, usually seeing a dark spot in some direction before his eye. Examination discloses now, or a few days later, precipitates on Descemet's membrane, occasionally opacities of the vitreous, and a distinct swelling of the papilla, especially in one quadrant, as if a woolly mass partially covered it. In the choroid, just a few disc diameters from the nerve, at a spot not very far from the macula, a focus is seen, the appearance of which varies greatly, not only according to the stage when first seen, but also most probably according to the direction of its growth (whether toward the retina or toward the sclera). In a fresh case the focus most frequently has the appearance of an indistinct, pearl-pink exudate, or a roundish, bulging heap of asbestos-like fuzz

of varying size (from $\frac{1}{4}$ to disc size). In one of my cases a pearl-gray (opalescent), absolutely circular, sharply defined, and non-vascular nodule was seen to protrude above the level of the retina, having apparently no covering whatever. The appearance was absolutely that of an uncovered miliary tubercle of about $\frac{1}{3}$ disc size, seen through a magnifying-glass. In other cases similar but much smaller nodules have been observed, these being seemingly the denuded exposed portions of a deeper submerged nodule or group of nodules. Many changes take place in these foci during the period of involution, which takes two or three months for completion. The focus becomes flatter and begins to develop a well-defined yellow border zone, faintly stippled with pigment. The border becomes more and more prominent through the accumulation of pigment; the center, denser white. Finally, a very sharply circumscribed defect of the choroid is seen, *larger* than the original focus, white in its general aspect, traversed by large parallel blood-vessels, irregularly dotted or "peppered" on its surface with pigment masses, and bordered by a narrow pigment margin. This pigment border becomes wider and heavier as time goes on, encircling the cicatrized focus like an ever-growing thorny wreath, as if attempting to encapsulate the patch. Studied in detail, it is found to consist of brown masses, stellate or branched in shape, exactly like the pigment scattered over the fundus in retinitis pigmentosa. Three cases of this kind have lately come under my observation.

CASE I.—Mrs. B. Z. K. was first seen in October, 1906, when she was twenty-eight years old. Occupation, church singer. General health perfect. Complained of seeing black speck before her right eye. Examination: Veil-like opacities of the vitreous, and, below, in the periphery, two atrophic choroidal patches, each larger than the disc. One of them was sharply defined, the other less so. No attention

was at that time paid to a recent focus, which was probably present, as evidenced by the patient's complaint and by the veil opacities of the vitreous.

About three years later, on February 2 of this year (1910), patient appeared again, with the complaint of visual disturbance of four weeks' duration. She was otherwise in perfect health, and gave a good family history. Examination showed many fine, and a few larger, floating opacities of the vitreous. Nerve, edematous, outline, hazy. A few disc diameters from the nerve, below, almost in the vertical meridian, a chain of four choroiditic foci, two old and two new ones, the oldest and largest being most peripheric. The new focus most centrally located is sharply defined and perfectly circular. It is non-vascular, has a clear, pearl-gray color, is raised above the choroidal surface, and about one-third as large as the disc. It abuts one of the older foci, and is almost confluent with it, having only a minute pigmented area between. The other new focus lies between the two old patches, and presents a picture of edematous retina overlying some indefinite exudate, with a disturbance in the regularity of the retinal pigment distribution. The old foci appear as two more or less round white patches, in the depths of which a few faintly outlined large vessels may be seen, each patch bordered by irregular brown pigment masses, with spatterings of pigment on the central white surface—details common enough to all atrophic choroiditic patches of any appreciable size. No drawing of the fundus was made at this time.

On February 9 the new foci had undergone some change. The larger, pearly, circular focus is now somewhat flatter, and has developed a narrow, yellowish, halo-like border zone. The pigment over the small one was still more scattered, the natural choroidal color disappearing around the pigment blotches.

In the plate shown, drawn about February 25, the perfectly round and sharp contour has not been brought out, but is clouded by the prominence given to some minor details. March 11: No further changes. April 24: The circular focus is now horizontally oval, much larger than the original nodule, still sharply outlined, but flat, grayish-white, translucent, with the large vessels of the other

choroidal layers shining through. There is no definite reticulated or blotched pigment border as yet, but an indefinite intensity of the pigmentation of the surrounding background in place of the yellow zone. On each side of the focus a few, very minute, irregularly pigmented, scattered pale areas can be made out. The small focus between the two old large peripheral ones appears now as an irregularly atrophied choroidal area, over which a few spots with an intense pigment center and pale surroundings are spread. A little nearer to the large retinal vein, more central than any of these foci, an entirely new small focus is beginning, having the appearance of a pearl-pink exudate. This new focus has not caused any new visual disturbance. Neither are there any fresh precipitates, and the media are clear, except for a few old strand-like floating vitreous opacities.

CASE II.—Mr. S. G., twenty-three years old, presented himself March 17, 1909. Is in perfect general health; also looks well; has a brother who is suffering from tuberculosis. Says for four or five days he has noticed black spots before the left eye, the vision of which is somewhat blurred. Findings: Precipitates on Descemet's membrane; optic nerve swollen; outline obliterated; nerve swelling in the center, 2 diopters. About 5 disc diameters from the nerve, near a branch of the upper nasal artery, a whitish, choroidal exudate is seen; retina here elevated 3 or 4 diopters; surrounding the focus, a few small hemorrhages and a little pigment.

March 28: Choroidal patch more sharply circumscribed; opacities of the vitreous present.

April 9: Eye without irritation; precipitates have disappeared. Swelling of the disc lessened, and beginning involution of the patch.

May 18 (six weeks later): Changes in the patch have progressed. Now well defined; *pigmented border beginning to appear.* Patient complains that for past six days his vision has been worse. A veil-like opacity of the vitreous blurs somewhat the clear view of the optic nerve, which has now become more swollen again. (In the light of later observations it is probable that, somewhere in the neighborhood of the choroidal patch, a new small focus had appeared,

which had not been observed, but which produced the subjective symptoms.)

June 24: Nerve swelling diminishing; outline becoming visible; choroidal patch almost cicatrized.

Patient was not seen again until February 14, 1910, eight months later, when he came because of renewed visual disturbance. Media clear. Near the nasal and lower edge of the old patch there is now to be seen an indefinitely outlined new focus, which is probably deep in the choroid or beneath it, imparting a grayish, fawn-colored tint to the area, which is elevated, and over which the retinal pigment is disturbed.

In this area the elevation of the choroidal focus measures 6 diopters at the point of greatest prominence, just where a branched retinal vein runs over it. At its inferior incline, between the branches of the vein, there is one small, round, pearl-gray nodule with a sharp scalloped border; another, less sharply defined, lies above the upper branch. Elevation in this region is 5 diopters. Papilla markedly swollen.

February 28: Seen by Dr. Young, who was making the drawing of the fundus. Had had about this time an injection of $\frac{1}{2}$ mg. tuberculin for diagnostic purposes. No reaction.

March 4: A second injection of T. V. was made (this time 1 mg.). Was seen the next day by Dr. Young, who noticed marked alteration in the condition of the eye, which may be taken as a local reaction. There were new opacities of the vitreous. In the region above the vein, where the retina had been grayish fawn, the color had changed to a purple gray (retinal edema).

March 15: The old patch has become somewhat succulent (edematous) and striated, bulging in its lower portion (adjoining the new focus), and rather indistinct through many fresh opacities of the vitreous, both strand-like and diffuse.

March 28: Vitreous entirely clear. The edema of the nerve passing away. In place of the two small nodules near the branching vein there are flat, round, choroidal patches, paler in color than the surrounding choroid, and covered by scattered, fine pigment dots.

May 1: The choroid and retina are still elevated over an area which takes in the old atrophic patch and the new

irregular focus below it, as if the whole were pushed forward by a mass or focus in the underlying sclera. This is well demonstrated in the atrophic patch, where the large choroidal vessels make a sudden dip at the edge. Media, clear; nerve, well defined.

CASE III.—Mrs. F. L., twenty years old, with good family history, of frail build, but in good health, presented herself May 20, 1908, complaining of seeing black spots in front of her right eye for two or three days. (She was at that time at the end of the second month of her first pregnancy, was at the proper time delivered of a healthy child, and has continued in her usual good health since.) Vision of the affected eye, $\frac{6}{8}$. Just above the macula, along the course of the superior temporal vessels, an oval atrophic choroiditic patch, bordered by pigment, is seen, at the upper outer edge of which a small fresh focus is appearing, recognizable mainly by the edematous retina and irregular pigment covering it. This is probably the freshest focus which has come under my observation.

June 1 (about six days after the onset of the trouble, and three days after the patient's first presentation). The optic nerve was considerably clouded by vitreous opacities, and vision was reduced to $\frac{4}{12}$. Four days later, June 4, the vision had diminished still further, to $\frac{4}{18}$. The focus had grown, having the appearance of a light colored, indefinitely outlined choroidal exudate.

June 16: Floating and dust-like opacities in the vitreous, especially anteriorly.

June 24: Considerable clearing of the vitreous; vision, $\frac{6}{6}$.

July 30: Nine weeks after the onset of the trouble vision was $\frac{6}{5}$ (above normal), and there were no opacities of the vitreous remaining, though involution of the patch was not complete. After that the patient was lost sight of until she presented herself upon request.

April 11, 1910: Media clear, no opacities of the vitreous. The first old patch shows a thick, voluminous border or wreath of pigment, composed of stellate or branched pigment masses. The white center is sparingly pigmented. Above and temporally, almost contiguous with this focus, there is a smaller one, less distinct and less pigmented, of tessellated appearance. The larger focus is most likely very old, as

indicated by the amount of the pigment. All the retinal vessels in this region run anterior to the pigment border.

These three cases have in common: their occurrence in healthy young adults in whom no other tubercular lesions could be found; the recurrence of the process, a characteristic grouping of the foci, the appearance of precipitates and veil-like vitreous opacities during the early stages, an intense optic-nerve swelling, a comparatively central location of the patches, and the disappearance, during regression, of all symptoms interfering with clear vision, the circular or oval shape of the old patches, and their increased size and pigmentation. They exemplify a type of chronic recurring inflammation in the choroid, the true nature of which has not thus far been generally recognized, nor has it consequently received its proper classification among the tubercular choroidal affections.

It is not possible to furnish absolute proof in each case that the lesion is tubercular, but the circumstances pointing in this direction are so many that they may be taken as positive evidence clinically. A few of these points may be enumerated:

First, the great prevalence of the tubercular compared to other pathologic processes. In the statistics of autopsies tubercular lesions are found in 80 to 90%.

Second, the ophthalmoscopic recognition of tubercles as such in some of the fresh cases of this class, and in others the identity of the picture with that seen during the last stages of an acute miliary tuberculosis or tubercular meningitis. A separate obsolete focus may not, it is true, be distinguishable ophthalmoscopically from an old patch of other origin, but in both the fresh and obsolete cases the other factors characteristic of miliary tubercles of the chronic type become decisive—*the foci in this chronic tubercular type have a characteristic distribution.* They are

not widely disseminated over the fundus, as we find them in syphilitic choroiditis or in the large atrophic patches of myopic eyes, but they occur either singly or as a confluent group or chain of foci in one region,—not all in the same stage of the inflammatory process,—and they are usually confined to one eye only.

Carpenter,* referring to miliary tubercle of the choroid in general, has called attention to some of these points, and tersely expresses them by saying that "miliary tubercle of the choroid is generally central, solitary, small in size, and unilocular." Referring, however, to the diagnosis of tubercular from syphilitic lesions, he says: "The early stages of both are identical in appearance, and the final stages are probably quite indistinguishable, the one from the other, as no doubt will be proved to be the case at some future date. If such chronic choroidal changes be associated with chronic tubercles in other parts of the body, or with the history of past tuberculous infection, and if syphilis can be excluded, surely the weight of clinical evidence is in favor of their tubercular origin." In this view of Carpenter's as to the ophthalmoscopic identity of the tubercular and the luetic forms I do not entirely concur, as has been seen, though it is quite true that the absence of a syphilitic seroreaction and an associated chronic tuberculosis of other parts may be important corroborative data in doubtful cases.

Third, Stephenson, in his well-described case, found tubercle bacilli in the aqueous, and so proved the tuberculous nature of the lesion. This case bears great resemblance in its general features to my Case I, in which an uncovered tubercle could be seen ophthalmoscopically. While the examination of the aqueous is not generally feasible, Stephenson has made his case of inestimable value through this positive evidence in one case.

* Tubercle of the Choroid (Trans. Ophth. Soc. Unit. King., vol. xxix, 1909).

Fourth, the positive ocular reaction after the diagnostic tuberculin injection in my Case II is a further proof that this type of miliary choroidal foci is tubercular; for, although a negative local reaction may not preclude the tubercular nature of a lesion, it is very generally conceded that a positive local reaction is evidence of an active tuberculous process in the organ affected.

Fifth, the tendency of this form of choroiditis not only to recur, but the fact of recurrence at the edge of or in the neighborhood of old cicatrized foci, is characteristic of chronic tubercular processes everywhere. They progress contiguously, a new tubercle beginning just outside of a cicatrizing or an encapsulated old focus. This is not characteristic of a syphilitic lesion anywhere in any stage.

To recapitulate: the factors pointing to the tubercular nature of this far from rare type of recurring choroiditis are:

The prevalence of tubercular lesions generally, the ophthalmoscopic identity of the foci with tubercles in the known acute cases, the finding of tubercle bacilli in the aqueous of one authentic case, the further proof of a local reaction upon a diagnostic injection in another case, and the well-known pathologic characteristics of the chronic tubercular process. All these justify us in classifying as tubercular such cases as I have described, and, so far as I know, it is the first time that these cases have been so classified.

LITERATURE.

S. Stephenson and G. Carpenter: Tuberculosis of the Choroid—Report of the Society for the Study of Diseases of Children, 1901.

Von Michel: Grundriss der Augenheilkunde, 3te Aufl., S. 242, 1903.

Schutz-Zehden: Die chronische herdförmige Chorio-retinitis Tuberculosa. Zeitschrift f. Augenheilkunde, xiv, p. 213, 1905.

Stock: Experimentelle Tuberculose der Uvea. Bericht d. Ophthalm. Gesellschaft in Heidelberg, 1905. Zeitschrift f. Augenheilkunde, xiv, 1905, v. Graefe's Archiv f. Ophthalmologie, Bd. lxv.

Valude: Tubercule de la Choroide. Recueil d'Ophtalmologie, 1906, p. 156.

Schleich: Ueber die primären tuberculösen Uveal-Erkrankungen, Deutsche medizinische Wochenschrift, 1906, S. 1540.

Lawford: Rare Forms of Choroiditis, Ophth. Record, 1906, p. 549.
Carpenter and Stephenson: Ueber Tuberkulose der Aderhaut, Ophthalmologische Klinik, Bd. xvi, 1906.
Sidney Stephenson: Intra-ocular Neoplasm-Tubercle? Trans. Ophthalmological Society U. K., 1906, p. 96.
Claude E. Taylor and Hugh A. Thompson: Tubercular Tumor of the Choroid, Trans. Ophth. Soc. U. K., 1906, p. 98.
L. V. Cargill and S. Mayou: A case of general miliary tuberculosis in an adult, in which choroidal tubercle with implication of one optic disc was the only physical sign in the early weeks of the illness, Trans. Ophthalm. Soc. U. K., 1906, p. 101.
L. V. Cargill: Solitary quiescent (obsolescent) tubercle in the right eye, associated with tubercular glands in the neck. Trans. Oph. Soc. U. K., 1907, p. 164.
Groenouw: Graefe-Saemisch Handbuch, II. Theil, XXII. Kapitel, Abth. 1, Tafel X.
Snell: Tubercle of the Choroid, Transactions of the Ophthalmological Society of the United Kingdom, 1907, vol. xxv, p. 156.
Warren Tay: Tubercle of Choroid, which led to Diagnosis of Tubercular Disease, Transactions of Ophth. Soc. U. K., 1907, vol. xvii, p. 159 (child).
Sydney Stephenson: Case of Tuberculosis of the Choroid, Transactions of the Ophthalmological Society of the United Kingdom, 1908, vol. xxviii, p. 35.
Rumschewitsch: Case of Tubercle of the Choroid, Westn. Ophth., p. 735, 1907.
Oeller: Atlas seltener ophthalmoscopischer Befunde, Ergänzungstafeln. 6te Lieferung, 1908. Plate O., iv.
Clark and Mayou: Tuberculosis of the Choroid Treated by Tuberculin, Ophthalmic Record, 1908, p. 195.
Ernest Clarke and Sir Almroth Wright: Solitary or Conglomerate Tubercle of the Choroid Treated by Tuberculine, Tr. Oph. Soc. U. K., 1908, p. 192.
Carpenter, George: A Further Clinical Contribution to the Study of Tubercle of the Choroid, Tr. Oph. Soc. U. K., 1909.
De Schweinitz: Some Unusual Forms of Exudative Choroiditis, Oph. Record, 1909, p. 23.
Ginsberg: Zur Kenntniss der chronischen herdförmigen disseminirten Aderhaut-Tuberculose, v. Graefe's Archiv f. Ophthalmologie, 1909, Bd. lxxiii, Heft 3, S. 538.

DISCUSSION.

DR. W. B. MARPLE, New York: I saw some cases of so-called obsolescent tubercle, which Dr. Koller presented at a recent meeting of the New York Academy of Medicine, and I must say that in most of them I was not at all convinced as to their tubercular origin. I could not see how one could say they were tuberculous rather than the ordinary cases of choroidal atrophy following exudative choroiditis. I would still have been skeptical, except that through Dr. Koller's courtesy I was permitted to see one of his cases in which, at the margin of an area of old choroiditis, there

was, as he has described, a typical picture of recent tubercular invasion. I was convinced that Dr. Koller was right as to the nature of this case.

I should like to know what is the experience of those who see children with tubercular meningitis. I have had the opportunity of seeing perhaps 30 or 40 of such cases every year at the Babies' Hospital, in New York City. Mr. Sydney Stephenson and Dr. Carpenter, of London, state that the percentage of choroidal tubercle in these cases is 25 or 50. I have examined these cases most carefully under a mydriatic and with an electric ophthalmoscope, but have not seen tubercles of the choroid in more than 2 or 3 % of the cases of choroiditis, if even in that many.

DR. E. E. JACK, Boston: In the large number of children I have seen, the only instances of tubercular invasion of the choroid have been in cases of miliary tuberculosis.

VACCINE AND SERUM THERAPY IN OPHTHALMOLOGY.

JOHN E. WEEKS, M.D.,
New York.

The control of disease by the use of bacteria or their products or by cytogenic products is brought about by immunizing the individual against the particular disease. This is accomplished in two ways: First, by stimulating the tissues to produce antagonistic substances (antibodies)—"active" immunization; second, by introducing antibodies already formed into the system of the patient—"passive" immunization. The substances employed to produce active immunization are the vaccines (bacterins, tuberculins); to produce passive immunization, the antisera, broadly speaking. Vaccines and sera are specific against the bacteria (and in the case of sera produced by means of animal cells or their products [cytogenic sera] against the cells) from which they are made. Thus, the gonococcus vaccine is specific against gonococcous infections and no other; anti-diphtheric serum, against infection from the Klebs-Loeffler bacillus and no other. In the case of vaccines, a vaccine made from the same strain of bacteria (autogenic) against which it is to be employed is more efficient than a vaccine made from other strains (heterogenic). It has been found that the elements of one heterogenic strain differ from those of another, and that a vaccine made of a number of strains (polyvalent or stock vaccine) approaches more nearly in therapeutic value to the autogenic vaccine than one made from a single heterogenic strain.

VACCINES (BACTERINS).—Tuberculins may be considered under this heading. On account of the fact that my

colleague, Dr. George S. Derby, has prepared a paper on "Vaccines and Serum Therapy in Ocular Tuberculosis," this part of the subject will receive but brief consideration here.

Tuberculins are of value in ophthalmology for the purpose of aiding in establishing a diagnosis, as well as in therapy. For diagnostic purposes a number of methods have been employed—reaction from the subcutaneous injection of tuberculin (Koch and others), from inoculation of the skin (von Pirquet), and from inoculation of the conjunctiva (Calmette). Because of the impossibility of excluding the presence of tubercular foci in other parts of the body, the writer believes that it is necessary to obtain a *reaction in the diseased eye itself* by the use of tuberculins in order to have positive evidence of any value in the diagnosis. Such a reaction can be obtained by the subcutaneous injection of tuberculin, but cannot be satisfactorily obtained by the von Pirquet and Calmette tests. The writer follows the method of Trudeau (Park's Pathogenic Bacteria and Protozoa, p. 334), using Koch's original tuberculin T. O., which is as follows:

"The range of the patient's temperature is ascertained by taking it at 8 A. M., 3 P. M., and 8 P. M. for three days before making the test. The first injection should not exceed 0.5 mg., and if any fever is habitually present, should even be less, and is best given early in the morning or late at night, as the typical reaction usually begins, in my experience, within six to twelve hours. Such a small dose, while it will often be sufficient to produce the looked-for rise of temperature, has, under my observation, never produced unpleasant or violent symptoms. An interval of two or three days should be allowed between each of the two or three subsequent injections it may be necessary to give, as reaction in very rare cases may be delayed for twenty-four or thirty-six hours. On the third day a second dose of 1 mg. is given, and, if no effect is produced, a third

dose, of 2 mg., three days later. In the great majority of cases of latent tuberculosis an appreciable reaction will be produced by the time a dose of 2 mg. has been reached. If no effect has been caused by the tests applied as above, I have usually gone no further and concluded that no tuberculous process was present. If some slight symptoms, however, have been produced by a dose of 2 mg., it may be necessary to give a fourth injection of 3 mg. in order to reach a positive conclusion. Nevertheless, it should be borne in mind that in a few cases the exhibition of even larger doses may cause reaction, when the smaller do not, and indicate the existence of some slight latent tuberculous lesion, and the negative result should not, when applied within the moderate doses described, be considered absolutely infallible.

"It is evident that the size of the doses given has much to do with the limitations of this method for usefulness and the correctness of the conclusions reached by its application. The tuberculin used is also a matter of some importance in determining the dosage, as different samples vary considerably in their efficiency. If the test be pushed to the injection of such large amounts as 10 mg. or more, as advocated by Maragliano, such doses are by no means free from the objection of occasionally causing unpleasant and sometimes dangerous symptoms; and even if the amount given be not carried to the dose of 10 mg., which is known to produce fever in healthy subjects, it is likely that, on account of individual susceptibility or the presence of some other morbid process in the body, reaction will be found to occur with the larger dose when no tuberculous process exists. The adoption of an initial dose so small as to guard against the absolute possibility of producing violent reactionary symptoms, and the graded increase of the subsequent doses within such quantities as are shown never to produce reaction in healthy individuals, would seem to afford the best protection against unpleasant results and misleading evidence."

Therapeutic Value of Tuberculins.—It is well known that Koch's original tuberculin, T. O., possesses less therapeutic value because it has been subjected to a temperature of 70°

to 90° C. in its preparation. However, the writer has found that T. O. tuberculin, as produced in the laboratory of the Board of Health of New York city, possesses some therapeutic value, as demonstrated in the beneficent effect produced in cases of tuberculosis treated in great part with this tuberculin. Tuberculins that have not been subjected to so high a temperature in their preparation apparently possess greater therapeutic value in less dosage. Of these, Koch's new tuberculin (tuberculin residuum), T. R., bacillus emulsion, B. E., bacillus filtrate (Denys'), B. F., are examples. The dosage of these tuberculins is about the same with each.

Treatment.—The tuberculin, properly diluted, is injected into the subcutaneous areolar tissue of the abdomen, subscapular region, or arm, after the skin at the point of puncture has been thoroughly rubbed with 95% alcohol. The puncture may be subsequently sealed with collodion.

It is advised to so regulate the dose that the effect on the patient is little short of the general reaction. If a general reaction has been produced, no more tuberculin should be administered until the temperature has returned to the normal and has so remained at least forty-eight hours. The method of procedure at present advocated by those of large experience is approximately that of von Hippel, beginning with a dose of not more than $\frac{1}{500}$ mg. of T. R., B. E., or B. F., and increasing by $\frac{1}{500}$ mg. each dose, the maximum dose not to exceed 1 mg. A dose should be given every fifth day if no general reaction is occasioned, in the early stage, less frequently as the patient improves. The value of tuberculin in the treatment of ocular tuberculosis is now generally conceded. The writer has treated 13 cases: Sclerokeratitis, 5 cases—recovered, 3, improved, 2; iritis, 1 case (conglomerate tubercle)—recovered, 1; choroiditis, 4 cases—improved, 4; keratitis, 3 cases—recovered, 3.

GONOCOCCIC VACCINE.—This micro-organism is not

readily cultivated. It is, therefore, difficult to obtain autogenic vaccine. The polyvalent or stock vaccines must be used ordinarily. These are found on the market in bottles containing 1 c.c. of an emulsion of two strengths—one of 20,000,000 and one of 100,000,000. In regard to the dose: Cole and Meakins (Bull. Johns Hopkins Hosp., June and July, 1907) gave an initial dose of 300,000,000 gonococci. A dose of 1,200,000,000 did not produce any unfavorable symptoms. They state that "in no case have we seen the administration of gonococcic vaccine do harm." It must be remembered that vaccines are antigens, and that their capacity to excite the development of antibodies depends on the ability of the tissues to react to their stimulus and not on the size of the dose. It is held by the Wright school that the condition of the tissues in this respect can be determined by a study of the "opsonic index"; this study requires the time of a skilled laboratory worker, which is not always at the command of the clinician. Many clinicians are of the opinion that the opsonic index does not furnish data that is of any more value than the clinical manifestations; they rely on the local and general reaction occasioned by the vaccine employed, and the effects on the course of the disease. Although large doses of gonococcic vaccine are well tolerated, the tendency now is to give smaller doses than formerly, ranging from 2,500,000 to 50,000,000.

Gonococcic vaccine is regarded by some investigators as valuable as an aid to the diagnosis of obscure affections due to the gonococcus. Irons (Journal of Infectious Diseases, June 4, 1908) writes: "A typical gonococcus reaction is characterized by a rise in temperature, often only slight, . . . and a variable degree of malaise. The symptoms follow the injection in from eight to twelve hours, and commonly last about twenty-four hours. Frequently there is a decided tenderness at the site of the

injection—greater than occurs after the inoculation of the same dose of the same preparation in normal subjects. Occasionally there is a marked redness and edema, lasting from twenty-four to forty-eight hours. . . . The degree of reaction is influenced by several factors. After small doses (20,000,000 to 50,000,000) the reaction was not marked, and in a number of early cases either did not occur or was overlooked. . . . The reaction is in many subjects similar to that which follows injections of tuberculin in cases of tuberculosis."

The reaction described by Irons has not been observed by the writer. If it occurs fairly regularly, it may be of service in clearing up the etiology of obscure cases of uveitis, iritis, and metastatic conjunctivitis.

Efficiency.—It is now generally recognized that gonococcic vaccine is of little value in *acute* gonorrheal infection, either of the urethra or of the eye. Of 79 cases of acute urethral gonorrhea tabulated by Duncan (New York Med. Jour., November 6, 1909), "satisfactory" results were obtained in 9, slight improvement noticed in 10, no improvement in 60. (The cases of acute gonorrheal infection of the conjunctiva treated with gonorrheal vaccine known to the writer are only 3 in number. In none was there any benefit derived by the use of the vaccine.) In 13 cases of chronic gonorrhea occurring in females, satisfactory results were obtained in 11—no result in 2. Of 46 cases of gonorrheal arthritis, satisfactory results were obtained in 42, no result in 4 (Duncan). Of chronic gonorrheal affections of the eye, Posey (personal communication) reports a severe case of uveitis much benefited, Dr. S. Hanford McKee 3 cases of metastatic gonorrheal conjunctivitis. All ran a mild course; the vaccine appeared greatly to relieve the pain in the joints affected with gonorrheal rheumatism in these patients.

Two cases of gonococcal iritis in patients with arthritis,

in which fluid from the synovial sacs contained gonococci, were reported to me by Dr. Charles A. Oliver. On the use of gonococcic vaccine he writes: "Both cases showed some local reaction, with marked recrudescence of joint lesions. The first improvement was probably more rapid than I have formerly seen, but of this I am uncertain."

The writer's experience is with 2 cases only, as follows:

First: Double metastatic gonorrheal iritis occurring in a negro of twenty-three years who had a gleet. In the right eye the anterior chamber was about one-quarter full of plastic lymph; in the left eye there was a very little plastic lymph. The patient was admitted to the New York Eye and Ear Infirmary. Rest in bed and atropin were the only measures employed other than the vaccine. The initial injection was one of 2,500,000, followed in twelve hours by a similar dose; twenty-four hours later a dose of 5,000,000, which was repeated every two to three days. Recovery occurred in two and one-half weeks. Some of the plastic lymph was removed from the anterior chamber of the right eye. It did not show gonococci. The discharge from the gleet showed gonococci.

Second case: R. L., male, age forty-four, recurrent iritis. Gleety discharge for years. Iritis of left eye seventeen months ago, preceded by an attack of gonorrheal rheumatism; made a slow recovery. Iritis of right eye began February 1, 1910, preceded by an attack of gonorrheal rheumatism. No history of syphilis. Treatment with the salicylates, mercury, and the iodids, with the use of atropin and hot bathing locally, to March 19th; did not modify the attack to any appreciable degree. Injected gonococcic vaccine 10,000,000 into the subcutaneous areolar tissue of the arm, repeating the dose in twenty-four hours. Improvement began at once. A dose of 20,000,000 gonococci was given one week later. Patient discharged April 18th, recovered.

STREPTOCOCCIC VACCINE.—The dose recommended by Sir A. E. Wright is 10,000,000 to 20,000,000, the minimum dose to be the initial dose, this to be increased according

to the toleration of the patient. Injections to be intramuscular.

Efficiency.—Of 117 cases of erysipelas tabulated by Duncan (New York Med. Jour., November 6, 1909), 7 were cured. In 53 the result was "satisfactory." In 37 improvement was slight, and in 20 no result was obtained. This vaccine may be of value in cases of erysipelas affecting the eye. C. R. Holmes has employed the vaccine in erysipelas. "Some cases were greatly modified, but in none of them was there any decided result."

STAPHYLOCOCCIC VACCINE.—It is well known that the staphylococcus is a factor in the production of eczematous processes of the lids, conjunctiva, and cornea, in some of the abscesses of the lids, in some forms of blepharitis marginalis, and in some suppurations of the globe after traumatism of whatever kind.

The following cases of the use of staphylococcic vaccine have been reported:

Duane, Alexander, of New York, reports a case of sluggish purulent infection of the eye. Hypodermic injections of a polyvalent vaccine of the Staphylococcus aureus were given with apparently good results. Six injections were given in seventeen days, beginning with a dose of 240,000,000.

Todd, Frank C., of Minneapolis, Minn., reports one case of chronic hordeoli, with pustules on the face and eczema around the nostrils. The patient had been treated for this condition from time to time for five years. Hypodermic injections of an autogenic vaccine of Staphylococcus aureus were followed by complete recovery.

Oliver, Charles A., of Philadelphia, has employed Staphylococcus albus vaccine (autogenic) in cases of recurrent hordeoli, injecting in corresponding arm and upper dorsal region, with apparent good results.

Gradle, H., of Chicago, has treated a number of cases of eczematous conjunctivitis and keratitis, with eczema about

the nares, using autogenic staphylococcus vaccine, with very excellent results, not only as regards recovery from the local disease, but also in improvement of the general condition of the individuals.

"*Coley's Toxins.*"—This is in reality a bacterin or vaccine composed of a mixture of Streptococcus pyogenes and Bacillus prodigiosus. The method of preparation is described in Coley's article (Boston Med. and Surg. Jour., February 6, 1908).*

Coley states that carcinoma is not influenced by the treatment, and he has not had a recovery in melanotic sarcoma. He reports having treated 430 cases of inoperable sarcoma with the mixed toxins. In 47 cases the growth completely disappeared; in 28 cases a period of from three to fifteen years has passed since the disappearance. The treatment has also been employed as a preventive to recurrence after operation, with apparent good results.

A number of brief reports of cases affecting the eye or orbit have been obtained and are given below.

Jack, E. E., Boston, Mass.: Sarcoma of orbit; toxins injected into the growth and into the arm. Local reaction occurred when the toxins were injected into the growth. Result negative.

De Schweinitz, George E., Philadelphia, Pa.: Inoperable sarcoma affecting the antrum. Result "most unfavorable." Obliged to discontinue treatment.

Brandoux, Henry A., St. Paul, Minn.: Two cases, one of which resulted in a cure. The second case resulted in death after exenteration of the orbit and the subsequent removal of a recurrent growth on the anterior margin of the orbit.

* This form of treatment originated from the recorded fact (J. Bland-Sutton, Tumors, Innocent and Malignant, fourth edition, p. 303) that inoperable sarcoma has been known to disappear after an attack of erysipelas. The prodigiosus element was incorporated after it was shown by Rogers that, by growing the Bacillus prodigiosus with the streptococcus of erysipelas, the virulence of the latter was increased.

Coley (Amer. Jour. Med. Sci., 1906, cxxxi, p. 375) mentions a personal report of R. Tilly, of Chicago: "Adult male, aged twenty-four years; inoperable sarcoma of orbit, which disappeared under three weeks' treatment with the serum."

Weeks, J. E., New York: Case of recurrent melanotic sarcoma of the orbital tissue. Male, seventy-two years. After exenteration of the orbit Coley's fluid was injected as a preventive to recurrence for three weeks, and again after an interval of about three weeks for three weeks longer. The injections were given every third day. Metastasis, apparently in the liver, occurred three years later, causing death.

ANTISERA.—*Diphtheria Antitoxin.*—The great value of this serum is too well known to require further elaboration here. The initial dose is 2000 to 10,000 units, according to the severity of the infection. The dose may be repeated in twelve hours if no improvement is noted—in twenty-four hours if improvement is moderate. In ocular diphtheria two injections are frequently sufficient; however, should there be an arrest in the improvement, or should the improvement be very slow, a third or fourth injection may be given.

Diphtheria antitoxin is being used by some ophthalmic surgeons (Ramsay, Glasgow, Lauber, Vienna) in the ordinary way in the treatment of affections of the sclera, cornea, and iris that are apparently not diphtheric. They claim good results. The indications for such use of this antitoxin are not clear.

GONOCOCCIC SERUM.—The serum of Rogers and Torrey is made by a number of manufacturers. It is obtained from the sheep some days after the injection of an emulsion of living gonococci into the peritoneal cavity.

A number of cases of gonorrheal conjunctivitis have been treated with the serum, both by local application and by injection with little or no benefit. With iritis, however,

the results have been very promising in the few cases reported.

Dr. Arnold Knapp (Arch. of Ophthal., 1908, xxxvii, 231) reports the following case of gonorrheal iritis treated by Torrey's serum:

J. W.: Gonorrhea contracted two and one-half years ago; metastases in joints, pericarditis, and three attacks of iritis; The last two attacks treated with Torrey's antigonococcic serum. Iritis characterized by pain, fibrinous exudate, marked ciliary congestion; no adhesions. Symptoms aggravated in both attacks after second or third injection. Condition of eyes then rapidly improved, clearing in from two to three weeks from onset. Ten injections on each occasion.

Dr. Torrey, in discussing the above case, stated that the inflammation and exudate became more marked after the first injections. This corresponds to the action of the serum in gonorrheal arthritis.

In a personal communication Dr. Arnold Knapp reports having treated three other cases, with cure in two and an indefinite result in one.

Dr. C. W. Cutler (Trans. Ophth. Section, New York Academy of Medicine, February 19, 1906, Arch. of Ophthal., 1906, xxxv, 409) has employed serum treatment in a few cases of gonorrheal ophthalmia. He injected it hypodermically in the case of two infants, and also dropped it in the eyes, without any reaction or pain. Both recovered. One was a moderately severe case, and seemed to improve after each injection. The routine treatment was continued, however.

Dr. George S. Derby, Boston, in a personal communication, reports one case of acute gonorrheal ophthalmia in which the Rogers-Torrey serum was employed. The result was negative.

The value of gonococcic serum in ophthalmology is very similar to the value of the vaccine. The acute manifesta-

tions of gonorrhea are not influenced. The late subacute manifestations are generally benefited by its use.

STREPTOCOCCIC SERUM.—The Streptococcus pyogenes is usually employed in the preparation of the serum.

My thanks are due to the gentlemen named for the following brief reports of cases treated:

Bull, Chas. S., New York: Case of deep orbital streptococcic infection. Subconjunctival injection of antistreptococcic serum prepared by the Board of Health of the City of New York. The result was doubtful. "There was an apparent diminution of infiltration and shortening of the period of duration of the acute symptoms."

Ellis, B. A., Los Angeles, has employed antistreptococcic serum (Parke, Davis & Co.) in streptococcic eye infections with "excellent results."

Gibson, R. D., Youngstown, O., has employed antistreptococcic serum (Stearns & Company) in streptococcic eye infections by subcutaneous injection. Results negative.

Greenwood, Allen, Boston, Mass., has employed Marmoreck's serum injected subcutaneously in large dose. Results were good in cases of erysipelas of the eyelids.

Lewis, E. R., Dubuque, Iowa, has employed antistreptococcic serum (Parke, Davis & Co.) "in probably a hundred or more cases" by deep intramuscular injection "of from 10 to 30 c.c. at various intervals." Results negative.

Rogers, F. T., Providence, R. I., has used antistreptococcic serum (Parke, Davis & Co.) by deep injection. Results negative.

Todd, Frank C., Minneapolis, Minn., has employed the antistreptococcic serum by hypodermic injection. In one case of septicemia due to streptococci recovery took place, due, Dr. Todd thinks, to the serum. In other cases the result was negative.

Dennis, D. N., Erie, Pa., employed antistreptococcic serum (Parke, Davis & Co.) hypodermically in a case of erysipelas and in corneal ulcer due to streptococci. Results very good indeed; the improvement was immediate.

Wilson, N. L., Elizabeth, N. J., has employed the anti-streptococcic serum (Parke, Davis & Co.) in a few cases, injecting hypodermically. Results "not good."

It will be noted that the results obtained by use of the serum have been variable.

TETANUS ANTITOXIN SERUM.—The following cases of the treatment of tetanus developing from the eye have been reported:

Ellis, Bert, Los Angeles, Cal., has employed the anti-tetanic serum in three cases, injecting the serum hypodermically. There were two recoveries. Further particulars fail.

Lewis, E. R., Dubuque, Iowa, reports one severe case of ten days' duration. Parke, Davis & Co. antitetanic serum employed. Deep injections at frequent intervals and varying dosage. Result, recovery. Is favorably impressed with the serum.

Bernstein, E. J., Kalamazoo, has employed the anti-tetanic serum to control infection (immunize) in 9 cases of wounds of the eye in which tetanus infection was suspected. Development of tetanus did not take place.

That this serum is of much value in the early treatment of tetanus is conceded by all who have used or studied it.

The serum of Chantemesse (typhoid antitoxin) (L'Hygiene Generale et Appliquée, October, 1907) need not be considered in relation to the eye.

FLEXNER'S SERUM (meningitis antitoxin), which has proved so beneficial in epidemic cerebrospinal meningitis, will probably never be of value in ocular therapeutics except in connection with its use for the systemic disease. The relatively infrequent affections of the eye due to the meningococcus will mend as the epidemic cerebrospinal disease improves under the use of the serum.

DEUTSCHMANN'S SERUM (Münch. med. Woch., No. 19, 1907) is obtained from animals that have been fed on living

yeast cells in large quantities. The serum, as found on the market, is prepared in two forms: one, the true Deutschmann serum, with some trikresol added to prevent decomposition, marked "Deutschmann's serum," and one in which the active principle of the serum is precipitated by a method devised by Mr. Enoch, of the Reute-Enoch Laboratory, Hamburg, then redissolved in water, and designated "Deutschmann's Serum E."

Deutschmann claims that his serum is efficient as an adjuvant against pneumococcic, streptococcic, and staphylococcic infections.

The following cases of its use have come to the writer's notice:

Gifford, H., Omaha, Nebraska, reports one case of severe infection of the eye. Deutschmann's serum was injected. Results negative. (Further particulars fail.)

Knapp, Arnold, New York, employed Deutschmann's serum in one case. Result negative.

This serum is of doubtful value.

CYTOGENIC SERA were among the first produced. Von Dungern (Münch. med. Woch., 1899, xlvi, 1228) suggested the possibility of using an epitheliolysin for the destruction of epithelial cancer-cells that were left in the body after the work of the surgeon. These sera all possess hemolytic and hemagglutinative properties, and are specific against the cells of the organs from which the inoculations were made.

Working on the line that "the accepted biologic principle at the present time is that the nucleus is the most important morphologic and physiologic portion of the cell, and hence it follows that its chemical constituents must be those most necessary for nutrition," S. P. Beebe (Jour. of Exper. Med., New York, 1905, p. 733) isolated nucleoproteids from various tissues and produced antisera by injecting them into the

peritoneal cavity of alien animals, hoping to obtain specific sera. Active sera were produced.

At the suggestion of Dr. John Rogers, Beebe (Jour. Amer. Med. Assoc., February 17, 1906) endeavored to apply these methods to the thyroid in the treatment of exophthalmic goiter. Two human subjects were first used. They had died with and from Graves' disease. The nucleoproteids and the thyroglobulians were extracted from the thyroid glands by Ostwald's method (Virchow's Arch. clxix, 1902). A mixture of the two proteids was injected into rabbits, and the serum thus obtained was believed to possess both cytolytic and antitoxic properties.

As the difficulties attending the getting of the thyroid gland in cases of exophthalmic goiter would make it impossible to produce sufficient sera to place it on the market, normal human thyroid glands, obtained at autopsy, were employed. The nucleoproteids obtained from this source produced a serum less potent than the first, but sufficiently active. It was found that the best serum was obtained from the sheep.

Since it is possible to obtain sera from diseased glands in small amounts, which are more active than those obtained from normal glands, Rogers (Jour. Amer. Med. Assoc., September 1, 1906, p. 655) proposes that the different sera be designated as "pathologic" and "normal" sera respectively. Rogers (Annals of Surgery, December, 1909), referring to the results of the therapeutic use of thyroid cytoserum, gives the following statistics:

"Four hundred and eighty cases, representing all stages and varieties of thyroidal disease, have thus come under my personal observation for a greater or less length of time, and Dr. Beebe has records of about as many more who have been treated with his laboratory products by many other physicians. In my series approximately 15 per cent. have been cured of all trace of their disease; some 10 per cent.

have no abnormal subjective symptoms, but still retain signs generally of goiter—less often of exophthalmos or other indication of their disorder noticeable to the trained observer; about 50 per cent. have improved to a greater or less extent, which usually means that after a month or two of treatment, with alleviation of symptoms, the patients have passed from observation and may at present be better or worse than when last seen; about 17 per cent. have failed to show any improvement, and 8 per cent. have died from the natural progress of their disorder."

The cytoserum of carcinoma (Strauss, Jour. Amer. Med. Assoc.) has not been used as yet in carcinoma of the eye.

SYPHILIS.—Since the application of the method known as complement deviation (Bordet and Gengou, Annales Pasteur, xv, 1901), by Wassermann, Neisser and Bruck (Deut. med. Woch., 1906, xxxii, p. 745), to the diagnosis of syphilis, and the discovery of the so-called Wassermann reaction, a method for the diagnosis of syphilis has been developed which is undoubtedly of value to ophthalmologists in clearing up the etiology of doubtful eye lesions. In regard to its value Butler (Jour. Amer. Med. Assoc., September 5, 1908), after an exhaustive review of the literature on the subject, sums up as follows: "The serum (Wassermann) reaction for syphilis is specific. It is found positive in from 60 to 85 per cent. of all cases with syphilitic manifestations. . . . in 50 to 60 per cent. of latent cases . . . in from 70 to 80 per cent. of parasyphilitic diseases." A negative reaction does not positively exclude syphilis.

The Noguchi test,* based on the increased globulin content of syphilitic serum, has proved to be reliable and is a relatively simple method.

* Jour. of Exper. Med., New York, January, 1909.

VACCINE AND SERUM THERAPY IN OCULAR TUBERCULOSIS.

GEORGE S. DERBY, M.D.,
Boston.

The furor created by Koch's announcement at the Berlin Congress in 1890 that he had discovered a cure for tuberculosis will not be soon forgotten. And, although it was a secret remedy, nevertheless, on account of the great reputation of its discoverer, it was at once adopted by many practitioners. Together with their confrères in other branches of medicine the ophthalmologists began to test tuberculin, or lymph, as it was called, and a number of articles on the subject were published in 1891 and 1892. Cases of scrofulous eye disease, lupus of the lids, tuberculosis of the conjunctiva, sclera, cornea, pectinate ligament, and iris were treated by Uhthoff,[1] Sattler,[2] Cohn,[3] Schaffranek,[4] Gepner,[5] Albrand,[6] Silex,[7] Wagner,[8] Landgraf,[9] Königshöfer and Maschke,[10] Schweigger,[11] Leber,[12] Gradle,[13] von Hippel,[14] Enslin,[15] Schwann,[16] and Haase.[17] On the whole, their results, even with the mistaken technic of that time, were encouraging, and the wide-spread adoption in ophthalmology of this new remedy might possibly have taken place at this early date. Soon, however, reports began to appear from many sources telling of unfortunate results in pulmonary cases, and the rapid discrediting of tuberculin was no less dramatic than its introduction. This was especially due to the work of Virchow, Baumgarten, and Hansemann, who showed beyond doubt that the lymph could cause the general dissemination of a tubercular infection throughout the body. Furthermore, although Dönitz[18] and Sattler[19] had obtained favorable therapeutic

results by the use of tuberculin in the experimental ocular tuberculosis of rabbits, Baumgarten,[20] Alexander,[21] Gasparrini and Mercanti,[22] Yamagiua,[23] Czapleuski and Roloff,[24] Baas,[25] Kostenitsch,[26] and Trudeau[27] came to opposite conclusions on guinea-pigs and rabbits. And, finally, when Koch announced that tuberculin was a toxin derived from cultures of the tubercle bacillus, ophthalmologists, as well as the rest of the medical profession, took fright, and little more was heard of tuberculin in ophthalmology for a decad.

Koch had been led to his discovery by finding that guinea-pigs could be immunized against tubercular infection by the injection of tuberculin. He began his treatment on the human with large doses, but urged the profession especially that the essential point of the new method was in its earliest possible application, saying that "the later cases furnished an inexhaustible source of ever fresh infection." The astonishing cures which occasionally followed the use of tuberculin in large doses led to over-confidence, and advanced cases were treated with too large quantities of the new remedy, leading to severe reactions, injury, and even death. Koch had warned against it. Its failure to work on guinea-pigs could be laid to the fact that these animals act very differently to tubercular infections than does the human; that they succumb to infinitesimal inoculations with bacilli, and yet stand infinitely larger proportional doses of tuberculin than do men.

It is far easier to introduce a new remedy than to restore to favor one that has been discredited. In spite of the general reaction of the medical profession against tuberculin, certain far-sighted workers still retained their confidence in its power and held fast to it through thick and thin. Among these were Goetsch, Hager, Krause, Thorner, Carl Spengler, and Petruschky. It was seen that large doses were often disastrous, and so even in 1891 the mild method of administration was inaugurated, at the same time, but

independently, by Ehrlich and Guttmann and by Petruschky. In 1901 it was again brought to the front by Goetsch. Koch's original view was that, as tuberculin caused necrosis of tubercular tissue and only acted on living tissue, it was logical to give big doses. He assumed that, at first, much living tubercular tissue was present, and that a small dose at that time was sufficient to cause a severe reaction. A certain amount of tissue, however, disappeared at each injection, and thus increasing doses were necessary in order to obtain the same amount of reaction as before. Also a certain amount of toleration was established. On this basis Koch assumed that the gradual disappearance of the tuberculin reaction was a sign of casting off and healing of the tubercular tissue. This view is not tenable, however, and we must regard the process as one of immunization against a bacterial toxin (Bandelier and Roepke[28]).

Although the first reports were undoubtedly exaggerated, the very evident danger of using large doses of tuberculin led the above-mentioned observers to give small doses and avoid reactions as far as possible.

After 1893 tuberculin was largely given up by the ophthalmologist, and between that year and 1900 there is but one observation on its therapeutic use on man. In 1898 Zimmermann[29] reported a case in which the left eye of a patient having been enucleated for tuberculosis, the right eye became infected and was apparently saved only by the use of tuberculin (T. R.) injections.

This is also the first record of the use of T. R. in ophthalmology, and to the writer's knowledge the first use of the mild dosage.

In 1897 Koch brought out new tuberculin (T. R.), which he announced contained only curative substances, while old tuberculin (T. O.)* contained toxic bodies also.

* In the later pages of this article will be found a brief description of the preparations of tuberculin commonly used in ophthalmology.

Zimmermann[29] published favorable results on the use of T. R. in the experimental ocular tuberculosis of rabbits, but his results were regarded as accidental, and of no value, by Baumgarten and Walz,[30] who soon after published experimental works of a like nature, but which led to conclusions diametrically opposed to those of Zimmermann.

Zimmermann's paper excited little interest in the profession, and Schieck's[31] exhaustive study, which appeared in 1900, secured but little more attention.

Schieck,[31] working in the Halle clinic under von Hippel, reported five cases of ocular tuberculosis, part treated by T. O. and part by T. R. His article contains an analysis of the literature up to that time, and a series of observations on the treatment of experimental ocular tuberculosis in rabbits with tuberculin. His clinical results on human tuberculosis were distinctly favorable, recovery taking place in all cases. In addition he collected from the literature all the previously reported cases of tuberculosis of the iris, and found available for his purpose 103 eyes treated by the older methods. Of these eyes, 39 were cured and 64 lost—a percentage of cure of 37.8. In 13 cases treated with tuberculin all were cured—100%. To quote from his summing up (p. 301): "All cases treated by injections, even the most severe forms . . . were cured. Not a single eye came to enucleation; indeed, in 12 cases not only could the form of the eye be saved, but also some of the function. To this striking result the important fact must be added that the retention of the tubercular eye, as far, at least, as the literature goes, causes no damage to the general organism; neither does the use of injections. The fear of a dissemination of the bacilli from a tuberculosis of the iris through the use of Koch's remedy is not confirmed by experience."

Schieck sought to confirm his observations on the human by animal experimentation, but his results were uncertain

and even unfavorable. It would perhaps have been better to have let the clinical results stand for themselves, and to have published the experimental conclusions separately. However that may be, we must regard his work as of the first importance. It excited some interest, but not the general recognition which it deserved. However, beginning soon afterward, tuberculin began to be used again in ophthalmology, even if in a sporadic way, and between 1900 and 1905 we find articles by the following authors: Reimar,[32] Morax and Chaillous,[33] Falckenberg,[34] Handmann,[35] Petella,[36] Salie,[37] Haab,[38] Morinami,[39] Weigelt,[40] Groenouw,[41] Hess,[42] Schoeler,[43] von Hippel,[44] and von Michel.[45] Of these, von Hippel was really the first to apply tuberculin therapy consistently, and it is due to him more than to any one else that it made its way at this time into ophthalmologic therapeutics.

His important publication of 1904 was not the recital of a few hastily collected cases, but the outcome, as he says, of over ten years' experience with this remedy. He was led to its use by the exceedingly unfavorable results following the treatment of severe tubercular disease of the eye, believing that the danger in its use, set forward especially by the pathologists, did not hold in ocular tuberculosis, and that in many of these cases tuberculosis elsewhere could not be detected, and that in ocular tuberculosis the number of bacilli in the tissues was notably few, and thus the danger of metastasis was very slight. Further, he says: "It (tuberculin) saves not a small number of eyes that, according to the views of the present day, are destined for enucleation, and, indeed, in part with the retention of a serviceable amount of sight." In the beginning of his work he was handicapped by the fact that old tuberculin was uncertain in its action, and not infrequently caused reactions at place of injection and also a rise of temperature. This led to long interruptions of treatment, and thus numerous re-

currences occurred, which later experience has shown could have been avoided by consecutive use of the remedy. "Since the adoption of new tuberculin T. R. these unpleasant complications have become uncommon, and the success of the treatment much more certain." His method was as follows:

Begin with an injection of $\frac{1}{5\,0\,0}$ mg. of the dry substance, and repeat every second day, taking the temperature every two hours, increasing each time $\frac{1}{5\,0\,0}$ mg. From $\frac{1}{5\,0}$ mg. the dose is increased by $\frac{1}{5\,0}$ mg. each time. From $\frac{1\,0}{5\,0}$ mg. by $\frac{4}{5\,0}$ or $\frac{5}{5\,0}$, so long as the temperature stays normal. If it rises over 38° C., he injects the same dose two or three times and increases it only when the patient shows no general reaction. It is unnecessary to go over 1 mg. He warns against beginning with larger doses, as he has seen corneal nodules break down and ulcerate.

To obtain a permanent cure it is of the greatest importance to inject long enough—in the severest cases six months and over. Injections must be continued until all signs of inflammation have disappeared, until all precipitates on Descemet's membrane and all floating vitreous opacities have been absorbed. It might be said that von Hippel was the father of modern tuberculin therapy in ophthalmology, but Dor's statement is incorrect that he (von Hippel) "established the technic of a treatment which is applicable to all the other branches of medicine"; for, as has been previously shown, this was inaugurated in the earlier days of tuberculin. Von Hippel published 13 severe cases of ocular tuberculosis which had recovered under his treatment, and had remained well for periods ranging from six months to nine years. At the Heidelberg Congress the following year he reported 14 more cases with favorable results, although the period of observation was considerably shorter.

Following von Hippel's work, tuberculin began to be

used more generally, and since that time a large number of articles on its use have appeared—in 1905 papers by Gilbert,[46] Lundsgaard,[47] von Hippel,[48] Gamble and Brown,[49] Jessop,[50] Bulson,[51] Risley,[52] Schwartz,[53] Stanculeano,[54] Kayser,[55] Reunert,[56] and Fleischer.[57] Gamble and Brown's paper contains a valuable summary of the literature to date. Schwartz succeeded in curing a case of tuberculosis of the conjunctiva by injections of Marmorek's serum. At the Heidelberg Congress von Hippel's second publication was discussed by Sattler, Halben, Uhthoff, Czermak, Haab, and Purtscher, all of whom had obtained favorable results from tuberculin. In 1906 we find the articles of Rohmer,[58] Capolongo,[59] Wilder,[60] Reuchlin,[61] Risley,[62] Wolfrum,[63] Brückner,[64] Török,[65] Stargardt,[66] Koster,[67] da Gama Pinto,[68] Jessop,[69] Ziegler,[70] and Parker,[71] most of whom are enthusiastic in its favor. Diem,[72] who records 32 cases treated with old tuberculin, saw good results in a majority, but in by no means all. Darier[73] suggests that where a local reaction of dangerous severity occurs in the eye, it can be controlled by subconjunctival injections of guaiacol. Axenfeld[74] strongly recommended tuberculin in tubercular infections of the uveal tract, according to von Hippel's directions. He regards its success as undoubted. Tuberculosis elsewhere in the body is favorably affected. The year 1907 was marked by several important articles which appeared. Stock[75] published most important observations on the frequent tubercular origin of chronic iridocyclitis, and recommends T. R. strongly in its treatment. In his opinion cases of chronic disseminated choroiditis are less favorably influenced by it than is the more anterior involvement of the eyeball.

Collin[76] reports 25 cases treated with von Behring's preparations, Tulaselaktin and Antitulase. These preparations now, however, possess only historic interest (Baudelier and Roepke).

Török[77] reports 16 cases, 10 of whom were cured, 4 improved, and 2 negative. Helbron's[78] success was not striking. Bock[79] reports the unsuccessful use of Marmorek's antitubercular serum in scrofulous affections of the eye. The first influence on the eye of Wright's work on the opsonic index is seen this year in the article of Hancock and Mayou,[80] who report 9 cases treated with partially good results, using small doses of T. R. and following the index carefully.

Other reports which appeared are those of Snell,[81] Lubowski,[82] Erdmann,[83] Krstitch,[84] Bull,[85] and Herford.[86]

In 1908 Allen[87] reported good results in choroidal tuberculosis and in infections of the orbital bones. He was less successful in phlyctenular keratitis and in scleritis. He advised controlling the tuberculin dosage with opsonic index estimations, and if this is not used, wait a considerable time between injections—three weeks to one month. Begin with $\frac{1}{100.000}$ mg. and increase slowly to $\frac{6}{10.000}$. Eye infections with tuberculosis may be due to either a human or bovine strain—therefore in some cases bovine T. R. is better than human. Begin with human tuberculin, and if there is no definite improvement in two to three months, change to bovine, or mix the two in equal parts. If the eye disease be secondary to a glandular infection, use a bovine preparation; if secondary to a pulmonary infection, use a human product.

Schumacher[88] treated 48 cases with from 11 to 42 injections; the shortest recovered in one and one-half months; the longest, in eight months. He reports fairly numerous recurrences, but, on the whole, the results were good, though not so striking as von Hippel's.

Verhoeff[89] disagrees with the views of the majority regarding several points. He believes that the therapeutic use of old tuberculin has been too quickly abandoned, and that for the best results it is necessary to obtain, at least once,

a general or a local reaction; on the next injection, which comes ten days later, an attempt is made to fall just short of a local reaction. Where no reaction has taken place, injections are given at four-day intervals.

Davids,[90] in a report from the Göttingen clinic, presided over by von Hippel, speaks of the advantage of the new preparation, Tuberculin B. E. (bacillus emulsion), over the older preparations. They have used it since 1906. Von Hippel saw recurrences after treatment with T. R., and communicated with Koch, who furnished him with this new preparation. Davids[90] reports 10 cases in which B. E. was used with extraordinarily favorable results. Duration, one to two years. He believes that it is a better preparation, and also much cheaper.

Other articles which appeared in 1908 are those of Török,[91] who continues his valuable work, Bock,[92] Alessandro,[93] Krämer,[94] Rohmer,[95] Derby,[96] Fejer,[97] and Lichtenstein.[98]

In 1909 appeared an extensive article by Dor,[99] in which he covers the history of the use of tuberculin from its beginning at the Berlin Congress in 1890, at which he was one of the interested listeners. He speaks of the good results obtained with T. R., and publishes eight cases treated with Béraneck's tuberculin, of which preparation he is a very enthusiastic adherent, both on account of the favorable results obtained by it and also on account of its simplified dosage.

Junius[100] is also an adherent of Béraneck's tuberculin, for convenience and on theoretic grounds. He has found it to work well in ocular tuberculosis.

Zur Nedden[101] emphasizes the fact that tuberculin treatment is no more nor less than an active immunization, and that we can expect a cure only when the body possesses the power to react in the right way to the injections—that is, the power to form the necessary curative substances. Persons in poor general condition are not likely to have this

power, but even when the general condition is good, it is not possible to say that a tuberculin cure will be successful, as the reacting power of the tubercular human body cannot be calculated and is very variable.

He does not believe that it is possible to cure all cases of ocular tuberculosis with tuberculin, and cites two cases of his own where, in spite of the most careful treatment, a cure could not be obtained.

He believes that von Hippel's method of injecting every third day is too frequent. while, on the other hand, the infrequent injections of Wright's method do not give the best results. The opsonic index estimation is of little practical value, since the method is very complicated and the phagocytic index does not fairly indicate the progress of the disease. Small doses, as practised by Wright, are not sufficient, and a gradual increase is now considered the best practice. Only the results of a large clinical material will show us which is the best tuberculin preparation, but it is again being recognized that old tuberculin, previously discarded for treatment, is regaining favor, and may be regarded as an efficient preparation. Stock[102] gives his experience of a year with the opsonic index, and concludes also that it is of little practical value in conducting a tuberculin cure, but that careful observations of temperature and general conditions should be made on each patient to determine the individual doses of tuberculin best suited to his particular case. Weeks[103] has collected 58 cases of various forms of ocular tuberculosis treated with tuberculin. Of these, 35 were virtual cures and 15 were improved. His work shows that tuberculin is favored by a large majority of the ophthalmologists in the United States.

Other articles appearing in 1909 are those of Clark and Wright,[104] Laas,[105] Hornike,[106] Derby and Ayer.[107]

In the last number of Graefe's Archiv A. Leber[108] discusses at length tuberculin immunity and tuberculin

therapy, and states his preference for old tuberculin, as it is more uniform than the newer products, shows less tendency to cause a local reaction, is easier to use, and is more certain as to dosage. He prefers to begin with very small doses, which will not cause either a local or a general reaction—for adults, $\frac{1}{500}$ mg. of old tuberculin; for children of two years and older, $\frac{2\frac{1}{2}}{10.000}$ to $\frac{5}{10.000}$ mg. He emphasizes the importance of using freshly prepared solutions. Mild local reactions are not injurious, but a too hasty increase in dosage may easily lead to an injurious general reaction. To avoid this, a careful reading of the temperature is indispensable—a rise shows that the action of the tuberculin is not confined to the diseased area, but has spread to the general organism and has caused an injury. Leber does not interrupt his dosage unless the temperature rises over .3° C. From that to .5° C. he repeats his dose. Over .5° he lengthens the interval and goes back a dose. The normal interval is four to five days. The opsonic index is not of practical value. In his 13 cases reported here the results were favorable.

In his opinion tuberculin has a specific action on the diseased focus; therefore local reactions are unavoidable and indispensable for a cure; they should, however, be limited to the smallest degree possible.

A careful study of the literature and the writer's own experience with tuberculin, now extending over four years, point out the fact that certain tuberculous affections of the eye are less favorable for treatment than are others. It is generally recognized that conjunctival tuberculosis is most resistant to tuberculin injections. Perhaps we may explain this by assuming that in the conjunctiva the disease is usually primary. Of the bulbar types of tuberculosis, there is some ground for believing that the choroidal is less amenable to treatment than are the other forms.

In the opinion of nearly all writers the tuberculin treat-

ment has proved of decided value in ophthalmology, and deserves to be taken up by all who treat this form of ocular disease. It will not help all cases, even when used in the most approved fashion, but it can be so administered that those who are not benefited at least will receive no harm. Tuberculin is a powerful agent, even in minute doses, and should be intrusted only to those who have been carefully instructed in its use and who realize what they are trying to accomplish.

TUBERCULINS.—What is the best preparation to use?

This question cannot be answered at the present time. It is probable that beneficial results may be obtained with all the standard preparations. On general principles, however, the filtrates or solutions, such as Koch's old tuberculin T. O., and those of Denys, B. F., and Béraneck, T. B. K., are safer for the beginner, more uniform in their dosage, and less likely to cause noticeable reaction than are the emulsions or vaccines T. R. and B. E. Theoretically, B. F. and T. B. K. are better than preparations in which heat is used in the manufacture. Thus far there is not enough evidence available to decide the relative merits of human and bovine extracts.

Tuberculin solutions should be reasonably fresh, and should be renewed from the stock solutions not less than once every two or three weeks, and it is advisable to make very high dilutions weekly. Even the 0.5% phenol solution used in making the dilutions is sufficient to cause deterioration in the tuberculin after a time. The emulsions should always be thoroughly shaken before measuring off the dose. Directions for making the dilutions come with all tuberculins.

Where a considerable number of patients are to be treated, it is desirable and convenient to make up a number of dilutions of varying strength. Dilutions of 1 : 10 are convenient and in general use.

Syringe.—A glass syringe of 1 c.c. capacity is preferable, on acccunt of ease in sterilization and measurement. At the Tuberculosis Class of the Massachusetts Charitable Eye and Ear Infirmary a glass syringe with asbestos packing has proved reliable and cheap.

Injections are best given in the back, below the scapula, alternating the side on each successive occasion. For convenience, however, the upper aspect of the arm may be used. The skin is cleansed with ether or alcohol, and the puncture may be closed with collodion if desired.

Dosage.—Authorities are divided on what tuberculin accomplishes. If the theory of specific bacterial immunity be accepted, then general and focal reactions hold a place in the treatment. They hold no place, however, in Wright's method, for he regards fever reaction as a manifestation of a negative phase, and simply tries to measure the amount of specific immunity produced by opsonic index determinations.

The adherents of the toxic immunity theory also try to avoid reactions, regarding them as evidence of intolerance; they produce no specific immunity, and although when mild they do no harm, in their severer forms they injure the patient's general condition and make the disease focus more active.

Bandelier and Roepke,[28] whose excellent treatise should be known to all those who use tuberculin, state: "If a mental picture is to be made of the curative action of tuberculin in the light of present-day knowledge, it must be based on a consideration of the two specific factors of its action—the production of toxic immunity and the local hyperemia" (p. 85).

In the face of these diverging views we must rely on clinical experience alone to guide us.

Certain observers, and they are now in a small minority, at least as far as ophthalmology is concerned, use large doses

at infrequent intervals, intending thereby to produce a marked local reaction.

This practice, it seems to the writer, should be discouraged, as it is pretty definitely established that such heroic measures may produce harmful results not only to the eye itself, but also to the whole organism, for it must be remembered that with this method of injection we have no way of controlling the severity of the reactions. On the other hand, Wright and his school maintain that the administration of very minute doses, $\frac{1}{100000}$ to $\frac{1}{10000}$ mg. of new tuberculin, repeated at long intervals and increased only to a slight extent under the control of opsonic index estimations, is the proper method of administrations.

The choice of the great majority lies between the two extremes. The initial dose should be small—T. O., $\frac{1}{500}$ to $\frac{1}{100}$ mg.; B. E. and T. R., $\frac{1}{1000}$ to $\frac{1}{500}$ mg.; B. F., $\frac{1}{10000}$ to $\frac{1}{1000}$. (The writer prefers the smaller dose in each case.) It should be increased slowly and with great care, avoiding, as far as possible, all signs of reaction, both general and local. When increasing from one solution to the next higher, the step should be gradual, *e. g.*, $\frac{9}{10000}$, $\frac{1}{1000}$, $\frac{1.5}{1000}$, $\frac{2}{1000}$, etc. It is not unlikely that slight local reactions occur with each injection, but these, when slight, are probably beneficial, and every effort should be made to keep them at a minimum.

Frequency.—Von Hippel regarded two days as the proper period between injections; later, Wright and his school advised much longer periods—eight or nine days, up even to three or four weeks (Allen). Again, a middle course seems desirable, and four to five days may be taken as the average time between injections. It is most important, however, to have no settled rule, but to treat each case on its own merits. The rate of increase and frequency of dosage may be controlled by careful observations of the temperature, which is best taken four times daily, by the

pulse, by careful attention to the general condition of the patient, loss of appetite, malaise, etc., and by careful observation of the eye itself when that is possible. A local reaction at the point of injection may also give evidence of a beginning intolerance. After a rise of temperature of more than .5° F., or any other toxic symptoms, the previous dose should be repeated until it no longer causes disturbance. If the toxic symptoms are pronounced, the interval should be lengthened or the next weaker dose given, or both. It is best not to inject during the first few days of the menstrual period. The treatment of many patients may be carried through without the signs of a reaction, but in most instances at some period the symptoms of intolerance appear, and we should be on the lookout for them. Marked reactions may lead to hypersusceptibility, and then even if the dose be considerably reduced, the patient continues to react. In such cases Trudeau[109] advises discontinuing injections for from ten days to two weeks, and then beginning again with a far weaker dose, and increasing very gradually. To quote from Trudeau[110] again, "the main features of our treatment would be—

"1. To raise the point attainable in each case by an almost imperceptible and long-continued progression in dosage.

"2. To avoid general and focal reactions as much as possible, and to consider them merely as evidences of intolerance.*

"3. To follow no arbitrary rule as to rate of increase or the maximum dose to be reached, but to be guided merely by the degree of toxin tolerance of each patient, as shown by the symptoms and general condition, whether the highest individual maximum dose attainable be only a small fraction of a milligram or a cubic centimeter or more."

* It should be noted here that Trudeau regards neither the theory of bacterial immunity nor that of toxic immunity as satisfactory, but feels that a dosage based on the latter theory gives the best results.

The majority of cases of ocular tuberculosis may be treated as out-patients, coming to the hospital at stated intervals for observation and injection. It is indispensable to have them keep a careful record of their temperature, pulse, and general symptoms in a book designed for the purpose. They should be controlled as closely as possible by having a social worker or nurse visit them in their homes occasionally, and see that they carry out the directions received. It should be strongly emphasized that general tubercular hygiene forms the most important part of the treatment of these cases, and that if we expect to get good results from injections, we must get the system into such condition that tuberculin can be utilized to the best advantage.

In previous papers the writer has pointed out the advantages to be obtained by the establishment of tuberculosis classes in connection with eye hospitals for the treatment of this disease.

In conclusion, the writer wishes to record 30 cases of ocular tuberculosis treated by tuberculin and tabulated briefly; 15 of sclerokeratitis; 9 of interstitial keratitis, and 6 of kerato-iritis. The earliest case recorded was discharged cured somewhat over two years ago, while 3 cases of long duration are still under treatment.

On the whole, it will be seen that the results are favorable, although in a number of cases it is by no means certain that a cure would not have taken place as speedily without the use of tuberculin. The writer intends to publish the case histories in full at some future time, for only by observation over a considerable period will it be possible to decide whether the cures produced are permanent or only temporary, and only by observation of a large number of cases over years will it be possible to determine the exact value of tuberculin therapy.

KERATO-IRITIS.

Name.	Method of Diagnosis.	Number of Injections.	Frequency, Days.	Maximum Dose.	Duration of Treatment, Months.	Results.	Remarks.
N. F.	Clinical picture.	37	7 to 21	$\frac{6}{10}$ mg. B. F.	15	Slight improvement.	Pupil adherent. Very resistant case. Patient lived at a distance, and treatment was somewhat intermittent. Still under treatment.
W. L.	Clinical picture.	10	7	$\frac{8}{100}$ mg. B. F	2	Cure.	Mild case.
Mary D.	Clinical type of disease. Signs of tuberculosis in lungs.	28	3 to 4	3 mg. B. F.	3½	Cure.	Large corneal nodule. Iritis.
E. S.	General and local reaction B. F.	47	7	$\frac{4.5}{100}$ mg. B. F.	4	Cure.	Severe case with many nodules in cornea and iris. Pupil bound down. Enucleation advised outside.
M. B.	General reaction B. F. Signs of tuberculosis in lungs.	22	4 to 7	$\frac{4.5}{100}$ mg. B. F.	7	Cure.	Four puncture reactions in arm. Eight weeks in sanatorium.
W. W.	General and local reaction T. O.	23	4 to 7	$\frac{7}{100}$ mg. B. F.	4½	Cure.	Diffuse deep corneal infiltrations. Mild iritis.

INTERSTITIAL KERATITIS.

Name.	Method of Diagnosis.	Number of Injections.	Frequency, Days.	Maximum Dose.	Duration, Months.	Results.	Remarks
M. J.	General and local reaction T. O.	25	7	$\frac{8}{100}$ mg. B. F.	7	Cure.	Poor general condition. Diffuse corneal infiltration with very moderate ciliary injection.
M. D.	Signs of tuberculosis elsewhere. Bad family history. Wassermann negative.	22	7	$\frac{7}{100}$ mg. B. F.	8	Cure.	Poor general condition. Lungs suspicious. Probable tubercular ulcer of larynx.
A. H.	General and local reaction T. O.	19	7	$\frac{8}{100}$ mg. B. F.	5	Cure.	Diffuse infiltration of upper two-thirds of cornea.
L. S.	Clinical picture. Marked signs of tuberculosis in glands and lungs. No evidence of syphilis.	27	7	$\frac{3.5}{100}$ mg. B. F.	6	Improvement, but still under treatment.	Diffuse corneal process with nodule in pectinate ligament.
R. P.	General and local reaction T. O.	22	7	$\frac{7}{100}$ mg. B. F.	9	Cure.	Diffuse homogeneous infiltration covering upper two-thirds of cornea.
Josephine M.	Local reaction in eye B. F.	37	4 to 7	$\frac{5.5}{100}$ mg. B. F.	8	Improvement.	Very severe type, with many deep yellow nodules in cornea. Still under treatment.
E. M.	Clinical picture. Signs of pulmonary tuberculosis.	17	7	$\frac{3}{100}$ mg. B. F.	7	Cure.	Two deep nodules in cornea.
J. G.	Clinical type of disease.	26	average 14	2 mg. B. F.	12	Cure.	Three deep round nodules in cornea. Patient lived at a distance and came irregularly.
C. C.	Clinical picture. Signs of tuberculosis at right apex.	22	7	$\frac{4}{100}$ mg. B. F.	4	Cure.	Two deep round nodules in cornea.

SCLEROKERATITIS.

Name.	Method of Diagnosis.	Number of Injections.	Frequency, Days.	Maximum Dose.	Duration of Treatment, Months.	Results.	Remarks.
G. deC.	Clinical picture. Signs of tuberculosis elsewhere. General reaction B. F.	36	7	1 mg. B. F.	10	Cure.	Very severe case. Nodules in cornea and iris. Pupil tied down. Enucleation advised outside.
M. S.	General reaction T. O.	40	7	2.5 mg. B. F.	10	Cure.	Obstinate case. Improvement not reached till large injections.
J. C.	General reaction T. O.	39	7	3 mg. B. F.	6	Cure of one eye.	As patient was about to be discharged from treatment the previously healthy eye became diseased and patient refused further treatment.
C. G.	Slight general reaction B. F. Marked signs of tuberculosis elsewhere.	21	7	$\frac{3.5}{10}$ B. F.	4	Cure.	Patient riddled with foci of healed tuberculosis.
A. B. P.	Microscope.	41	7	7. $\frac{5}{10}$	11	Cure.	Very severe case, with many nodules in cornea and two large granulated growths at limbus.
M. R.	Four slight local reactions to B. F.	42	7	5.5 mg. B. F.	10	Cure.	Patient insists on keeping up occasional injections "to keep eyes well."
Julia C.	Local and general reaction to T. O.	30	7	..	7	Cure.	
S. McD.	Local and general reaction to T. O.	12	7	$\frac{1}{10}$ mg. B. F. 1 mg. T. O.	3½	Cure.	Marked sclerokeratitis, with old perforating ulcer of cornea. This patient had several large therapeutic injections of T. O. before coming under our care.

A. C.	Clinical appearance.	10	7	$\frac{1}{1000}$ mg. B. F.	1	Cure.	Mild case.
Cath. G.	One slight local reaction to B. F.	25	4 to 7	$\frac{1}{10}$ mg.	5	Some improvement.	Patient refused further treatment.
Jas. M.	General and local reaction to T. O.	105	3 to 7	3 mg. B. F.	28	Improvement.	A most resistant case; still under treatment.
L. D.	General and local reaction T. O. Marked pulmonary signs of tuberculosis.	26	7	$\frac{7}{10000}$ mg. B. F.	9	Cure.	Case first treated with T. O., and reacted sharply to $\frac{3}{1000}$ mg. on two occasions. It was never possible to raise the dose of B. F. above $\frac{7}{10000}$ mg.
A. B.	General and local reaction T. O.	50	7	$\frac{1}{10}$ mg. B. F.	17	Cure.	Numerous nodules in sclera which developed one after another during treatment. Eye would nearly quiet down, only to flare up again.
I. F.	Clinical picture. Signs of tuberculosis elsewhere. Positive cutaneous test.	11	7	$\frac{3}{1000}$ mg. B. F.	4	Cure.	

TUBERCULIN PREPARATIONS.

Old Tuberculin.—T. O. is a filtrate of tubercle bacilli cultures grown on glycerin broth, concentrated by heat to one-tenth of its volume, and then filtered through porcelain to remove the germs. T. O. contains the soluble products of the tubercle bacillus in a 50 % glycerin solution. This was the original preparation recommended by Koch, and used extensively in the early nineties. Its use now in ophthalmology is confined almost entirely to diagnosis, as it is thought that valuable immunizing properties are lost by the heating process to which it is subjected.

Tuberculin T. R. consists of dried tubercle cultures ground up, treated with physiologic salt solution, and separated into two layers by centrifuging, and the upper one containing the glycerin-soluble substances, and a lower one, T. R., containing chiefly the substance left behind after extraction with glycerin. This has been extensively used in ophthalmology. The initial dose commonly used is $\frac{1}{1000}$ to $\frac{1}{500}$ mg.

Tuberculin B. E. (bacillus emulsion), which has more recently come into high favor, may be regarded as a mixture of the glycerin-soluble products with T. R. It is a suspension of 1 part of pulverized tubercle bacilli in 100 parts of distilled water to which equal parts of glycerin are added. Initial dose, $\frac{1}{1000}$ to $\frac{1}{500}$ mg.

Tuberculin B. F. (bouillon filtrate) (Denys) is a preparation similar to T. O., except that it is not concentrated by being subjected to heat. Besides the toxins secreted by the living bacilli, it contains only those proteids which go into solution in the culture fluid, and none of the insoluble proteids which remain in the bodies of the bacteria. Initial dose, $\frac{1}{10000}$ to $\frac{1}{1000}$ mg.

Tuberculin T. B. K. (Béraneck) has met with considerable favor, and although up to this time used but little in ophthalmology, it is strongly recommended by Dor. It consists of the extracellular toxins of the bouillon culture, together with intracellular toxins extracted from the bodies of the bacilli with 1% phosphoric acid. Theoretically, therefore, it should contain, as far as possible, all substances having immunizing properties, and avoids the danger, common to the emulsions, of containing live bacilli and toxins possibly

harmful. It is supplied in 15 different solutions, each one double the strength of the preceding one. First dose for children under twelve, $\frac{1}{20}$ c.c. of solution A 128; adults, $\frac{1}{20}$ c.c. solution A 32, best for weak persons. Besides these preparations, there are innumerable others which cannot be mentioned here, but which may be found in Bandelier and Roepke.[28]

LITERATURE.

1. Uhthoff: Ein Beitrag zur Behandlung Augenkranker nach dem Koch'schen Verfahren, Berlin. klin. Woch., No. 7, p. 173, 1891.
2. Sattler: Ueber die Behandlung der verschiedenen Formen der Conjunctival-Tuberculose mit Tuberculin, etc., Bericht über die XXI. Versammlung der ophthal. Gesellschaft, Heidelberg, p. 33, 1891.
3. Cohn: Notizen über Einspritzungen Koch'scher Flüssigkeit bei Augenleiden, Berlin. klin. Woch., p. 175, 1891.
4. Schraffranek: Ein Fall von scrophulösem Augenleiden geheilt durch vierwöchentliche Behandlung mit Tuberculin, Deut. med. Woch., p. 1199, 1891.
5. Gepner: Ein Fall von Bindehautlupus, nach dem Koch'schen Verfahren behandelt, Centralbl. f. Augenheilk., p. 1, 1891.
6. Albrand: Erfahrungen über das Tuberculin aus der Prof. Schöler'schen Augenklinik in Berlin, Klin. Monatsbl. f. Augenheilk., pp. 149, 168, 1891.
7. Silex: Robert Koch's neues Heilverfahren, Allgem. med. Centralzeitung, p. 386, 1891.
8. Wagner: Die Tuberculose des Auges, und der Erfolg der Anwendung des Koch'schen Tuberculins bei derselben, Münch. med. Woch., pp. 266, 286, 1891.
9. Landgraf: Tuberculose Geschwulst der Uvea, mit Koch'scher Flüssigkeit behandelt, Berlin. klin. Woch., p. 285, 1891.
10. Königshöfer und Maschke: Beobachtungen über die Wirkung des Koch'schen Mittels bei Augenerkrankungen, Deut. med. Woch., p. 72, 1891.
11. Schweigger: Die Wirksamkeit des Koch'schen Mittels gegen Tuberculose, cited by Wagner,[8] Deut. med. Woch., p. 289, 1891.
12. Leber: Ueber abgeschwächte Tuberculose des Auges, Bericht der Ophthal. Gesellschaft Heidelberg, p. 44, 1891.
13. Gradle: On the Curative Influence of Tuberculin on Certain Types of Corneal Ulceration, Chicago Med. Record, ii, p. 544, 1891.
14. Von Hippel: Cited by Gamble and Brown.[49]
15. Enslin: Cited by Gamble and Brown.[49]
16. Schwann: Fall von tuberculösem Hornhautgeschwür des rechten Auges: Heilung nach 6 Injectionen, Deut. med. Woch., p. 116, 1891.
17. Haase: Ueber Tuberculose des vorderen Tractus uvealis, cited by Schieck, p. 250.[31]
18. Dönitz: Ueber die Wirkung des Tuberculins auf die experimentelle Augentuberculose des Kaninchens, Deut. med. Woch., p. 1289, 1891.
19. Sattler: Ueber die Wirkung des Tuberculins auf die experimentelle Iristuberculose bei Kaninchen, Deut. med. Woch., 1892.
20. Baumgarten: Cited by Schieck, p. 306.[31]
21. Alexander: Ueber die Wirkung des Tuberculins auf die Impftuberculose des Kaninchenauges, Centralbl. f. Augenheilk, p. 161, 1891.

22. Gasparrini und Mercanti: Ueber die Wirkung des Koch'schen Tuberculins auf die experimentelle Augentuberculose, cited in Centralbl. f. Augenheilk., p. 491, 1891.
23. Yamagiwa: Cited by Schieck.[31]
24. Czaplewski and Roloff: Cited by Schieck.[31]
25. Baas: Experimentell-anatomische Untersuchungen über den Einfluss des Tuberculocidins und Tuberculins auf die Impftuberculose des Kaninchenauges, Arch. f. Ophth., xxxix, 4, p. 178.
26. Kostenitsch: De l'evolution de la tuberculose provoquée chez les lapins par les bacilles morts et son traitement par la tuberculine, Arch. de Med. exper. et d'anat. path., p. 1, 1892.
27. Trudeau: A Report of the Ultimate Results Obtained in Experimental Eye Tuberculosis by Tuberculin Treatment and Antitubercular Inoculation, Trans. Association American Physicians, ix, p. 168, 1894.
28. Bandelier and Roepke: Tuberculin in Diagnosis and Treatment, translated by E. C. Morland, London, 1909.
29. Zimmermann: Experimentelle und anatomische Untersuchungen über die Einwirkung der neuen Koch'schen Präparate "O" und "R" auf den Verlauf künstlich erzeugter Augentuberculose der Kaninchen, Ophth. Klinik, pp. 144, 172, 1898.
30. Baumgarten und Walz: Cited by Schieck.[31]
31. Schieck: Klinische und experimentelle Studien über die Wirkung des Tuberculins auf die Iristuberculose, Arch. f. Ophth., l, p. 247.
32. Reimar: Casuistische Beiträge zur Conjunctival-Tuberculose, Klin. Monatsbl. f. Augenheilk., p. 83, 1900.
33. Morax et Chaillous: Sur le diagnostic des affections Tuberculeuse de l'appareil visuel, Annal. d'Oculist., p. 119, 1901.
34. Falckenberg: Ein Beitrag zur Pathologie und Therapie der Iridocyclitis tuberculosa, Inaug.-Diss., Tübingen, 1901, cited by Gamble and Brown.[49]
35. Handmann: Zur Behandlung der Iristuberculose mit Tuberculin T. R., Klin. Monatsbl., ii, p. 219, 1902.
36. Petella: Tuberculose de la conjunctive oculo-palpebrale, Arch. d'ophthal., p. 484, 1903.
37. Salie: Ueber die Erfolge der Tuberculinbehandlung bei Conjunctival-Tuberculose, Inaug.-Diss., Göttingen, 1902, cited by Gamble and Brown.[49]
38. Haab: Ueber die Anwendung des Tuberculins bei Augenerkrankungen, Correspondenzbl. d. Schweizer Aerzte, p. 728, 1903.
39. Morinami: Beiträge zur Therapie und Diagnose der Augentuberculose, Inaug.-Diss., Rostock, cited by Kayser.[55]
40. Weigelt: Cited by Gamble and Brown.[49]
41. Groenouw: Tuberculose, Graefe-Saemisch Handbuch, Vol. ii, part 1, p. 670.
42. Hess: Cited by Kayser,[55] Klin. Monatsbl., i, p. 121, 1905.
43. Schoeler: Vorläufige Mitteilung über Versuche mit Tuberculin zu Heilzwecken, Berlin. Ophth. Gesell., Mai, 1904, Klin. Monatsbl., i, p. 600, 1904.
44. Von Hippel: Ueber den Nutzen des Tuberculins bei der Tuberculose des Auges, Arch. f. Ophth., lix, p. 1.
45. Von Michel: Discussion of Schoeler's paper,[43] Klin. Monatsbl., ii, p. 145, 1904.
46. Gilbert: Zur Prognose und Therapie der Conjunctival-Tuberculose, Klin. Monatsbl., ii, p. 22, 1905.
47. Lundsgaard: Cited by Dor.[99]

48. Von Hippel: Weitere Erfahrungen über die Behandlung schwerer Tuberkulose des Auges mit Tuberkulin T. R., Bericht Ophthal. Gesellsch., Heidelberg, p. 136, 1905.
49. Gamble and Brown: Iritis Tuberculosa as Diagnosed and Treated by Koch's Tuberculin, Jour. Amer. Med. Assoc., October 14, 1905.
50. Jessop: Intra-ocular Tuberculosis, Brit. Med. Jour., August 26, 1905.
51. Bulson: Discussion of Gamble and Brown's paper,[49] Jour. Amer. Med. Assoc., p. 1151, 1905.
52. Risley: Tuberculin Treatment for Disease of the Bulbar Conjunctiva, Ophthal. Record, November, 1905.
53. Schwartz: Heilung eines Falles von Augentuberculose durch Marmorek's Serum, Deut. med. Woch., p. 1346, 1905.
54. Stanculeano: Recherches diagnostiques et therapeutiques dans la keratite parenchymateuse au moyen de la Tuberculine T., Annal. d'oculist., cxxxii, p. 340.
55. Kayser: Ueber die Tuberculose des Auges, Klin. Monatsbl., i, p. 115, 1905.
56. Reunert: Ueber die durch Tuberculose bedingte pseudoleukämische Erkrankung und ihre Behandlung mit Neutuberculin, etc., Deut. med. Woch., xxxi, p. 907.
57. Fleischer: Demonstration zweier Fälle von Conjunctival-Tuberculose, Ophth. Klin., p. 212, 1905.
58. Rohmer: Soc. Med. de Nancy, 16 Mars, 1906, cited by Dor.[99]
59. Capolongo: Ann. d'Ottalm., xxxv, p. 933, cited by Dor.[99]
60. Wilder: Tuberculosis of the Cornea, Ophthal. Record, p. 610, 1906.
61. Reuchlin: Ueber Erfahrungen mit dem Koch'schen Tuberculin, Klin. Monatsbl., i, p. 352, 1906.
62. Risley: Iridocyclitis with Conjunctival Disease, Ophthalmology, April, 1906.
63. Wolfrum: Fünf Fälle mit Tuberculose des Auges unter der Behandlung mit Tuberculin T. R., Arch. f. Augenheilk., p. 1, 1906.
64. Brückner: Erfahrungen mit dem Koch'schen Tuberculin (Alttuberculin und Tuberculin T. R.), Arch. f. Augenheilk., p. 352, 1906.
65. Török: Ueber die Behandlung der Augentuberculose mit Tuberculin T. R., Zeitschr. f. Augenheilk., p. 56, 1906.
66. Stargardt: Das Tuberculin in der Augenheilkunde, Münch. med. Woch., p. 578, 1906.
67. Koster: Jets over behandeling van tuberculose van het oog met tuberculine, abst. in Jahresbericht der Ophth., p. 312, 1906.
68. da Gama Pinto: Trans. 15 Internat. Congress, Lisbon, abstract in Ophthal. Yearbook, p. 50, 1908.
69. Jessop: Discussion of da Gama Pinto's paper, Ophthal. Yearbook, 1908.
70. Ziegler: Keratitis Tuberculosa Relieved by Tuberculin Injections, Trans. Amer. Ophth. Soc., p. 78, 1906.
71. Parker, W. R.: Tubercular Affections of the Eye, Ophthal. Record, p. 371, 1906.
72. Diem: Die an der Züricher Universitäts-Augenklinik ausgeführten Tuberculin-Injektionen aus den Jahren 1898–1905, Inaug.-Diss., abstract in Jahresber. der Ophth., p. 311, 1906.
73. Darier: Des Tuberculoses Oculaires et de leur traitement par la tuberculine, Clinique ophtal., p. 331, 1906.
74. Axenfeld: Ueber Anwendung des Tuberculins nach von Hippel bei intraokularer Tuberculose und chronischen Entzündungen der Uvea, Münch. med. Woch., p. 2417, 1906.
75. Stock: Tuberculose als Aetiologie der chronischen Entzündungen des

Auges und seiner Adnexe, besonders der chronischen Uveitis, Arch. f. Ophth., lxvi, p. 1.
76. Collin: Erfahrungen mit den Behring'schen Tulasepräparaten bei der Behandlung tuberculöser Augenerkrankungen, Münch. med. Woch., p. 1761, 1907.
77. Török: Ueber Tuberculose des Auges und dessen Behandlung mit Tuberkulin, Szemeszet No. 1, 1907.
78. Helbron: Die Tuberculose des Auges und ihre Behandlung, Berlin. klin. Woch., No. 28, 1907.
79. Bock: Erfolglose Behandlung scrofulöser Augenerkrankungen mit Antituberculose-Serum Marmorek, Wien. med. Wochenschrift, No. 38, 1907.
80. Hancock and Mayou: Nine cases of Ocular Tuberculosis Treated by Injections of Tuberculin T. R., Controlled by the Opsonic Index, Ophthalmoscope, p. 347, 1907.
81. Snell: Tubercle of the Choroid, Trans. Ophth. Soc. U. K., xxvii, p. 156.
82. Lubowski: Klinischer Beitrag zur Kenntnis der tuberculösen Uveitis, Klin. Monatsbl., ii, p. 539, 1907.
83. Erdmann: Ueber eine erfolgreiche Behandlung von Tuberculose des Auges mit Tuberculin, Münch. med. Woch., p. 671, 1907.
84. Krstitch: Thèse de Nancy, cited by Dor.[99]
85. Bull: The Value of Tuberculin T. R., as a Diagnostic and Therapeutic Agent in the Recognition and Treatment of Tuberculosis of the Eye, Trans. Section on Ophthal., Amer. Med. Assoc., 1907.
86. Herford: Retinitis proliferans tuberculöser Natur, Centralbl. f. Augenheilk., p. 204, 1907.
87. Allen: The Opsonic Index in Ophthalmology, Practitioner, May, 1908.
88. Schumacher: Erfahrungen mit dem Koch'schen Alttuberculin bei Erkrankungen des Auges, Zeitschr f. Augenheilk., p. 223, 1908.
89. Verhoeff: Some General Considerations Concerning Tuberculosis of the Eye, Ophth. Record, December, 1908.
90. Davids: Ueber den Nutzen des Neutuberculins (B. E.) bei Tuberculose des Auges, Arch. f. Ophth., lxix, p. 231.
91. Török: Diagnostic and Therapeutic Value of Tuberculin in Tuberculous Eye Diseases, Arch. of Ophth., p. 531, 1908.
92. Bock: Noch einmal die erfolglose Behandlung skrofulöser Augenkrankheiten mit Antituberculose-Serum Marmorek, Wien. med. Woch., p. 511, 1908.
93. Alessandro: Tuberkulose der Iris, festgestellt und behandelt mit Tuberkulin, Ophth. Klinik, p. 353, 1908.
94. Krämer: Beitrag zur Tuberkulinbehandlung der Augentuberkulose, Ophth. Klinik, p. 1, 1908.
95. Rohmer: Tuberkulose oculaire et tuberculine, Arch. d'Opht., xxviii, p. 422.
96. Derby: The Increasing Importance of Tuberculosis as a Cause of Ocular Disease, etc., Arch. of Ophth., p. 515, 1908.
97. Fejer: Ein seltener Fall von Solitärtuberkel der Aderhaut, Centralbl. f. Augenheilk., September, 1908.
98. Lichtenstein: Die Augentuberculose und ihre Behandlung, abstract, Jahresber. f. Ophth., pp. 320, 321, 1908.
99. Dor: On Tuberculins T. R., B. E., T. B. K., translation, Ophthalmoscope. June, July, 1909.
100. Junius: Tuberkulinbehandlung des Auges, Zeitschr. f. Augenheilk., p. 427, 1909.
101. Zur Nedden: Die Behandlung der Tuberculose des Auges, Klin. Monats., i, p. 295, 1909.

102. Stock: Ueber die Anwendung der Wright'schen Opsonintechnik in der Augenheilkunde, etc., Klin. Monats., ii, p. 503, 1909.
103. Weeks: Serum and Vaccine Therapy in Ophthalmology, XVI. Congres Internat. de Medicine, Section IX, p. 73.
104. Clark and Wright: Solitary or Conglomerate Tubercle of the Choroid Treated by Tuberculin, Ophthalmoscope, Fasc. 3, 1909.
105. Laas: Ein durch Tuberkulin T. R. geheilter Fall schwerster parenchymatöser Keratitis, Klin. Monats., i, p. 416, 1909.
106. Hornike: Konglobierte Tuberkel der Iris geheilt durch Bazillen-Emulsion, Zeitschr. f. Augenheilk., Heft 3, 1909.
107. Derby and Ayer: A Clinical Investigation on the Relationship of Tuberculosis to Certain Diseases of the Eye, Trans. Section of Ophth., Amer. Med. Assoc., p. 296.
108. Leber: Tuberculin-Immunität und Tuberculin-Therapie bei tuberkulösen Augenerkrankungen, Arch. f. Ophth., lxxiv, p. 539.
109. Trudeau: Tuberculin Immunization in the Treatment of Pulmonary Tuberculosis, Amer. Jour. Med. Sci., June, 1907.
110. Trudeau: Antibacterial or Antitoxic Immunization in Tuberculin Treatment, Jour. Amer. Med. Assoc., vol. lii, p. 263.

DISCUSSION OF PAPERS OF DRS. WEEKS AND DERBY.

DR. F. H. VERHOEFF, Boston: It is obvious that opinions in regard to tuberculin therapy based upon clinical results are rather diverse. We might expect this, because no one man in a short period of time can treat a sufficient number of cases definitely to decide as to the best method. Therefore, it seems to me worth while to consider the subject from a theoretic standpoint also. The theory which I hold, however, is supported by my clinical experience. I started out with the idea that the correct method of giving tuberculin was to give a dose that did not produce a reaction. In attempting to do this I did occasionally get a reaction, and I found that good resulted. I continued to use tuberculin, and found that in cases in which reactions were not obtained I did not get good results. In these same cases I then deliberately produced reactions and got better results. My theory is that since we cannot immunize an animal against tuberculosis with tuberculin, it is fair to assume that tuberculin does not cure by producing general immunity, but by setting up reactions in the local processes which lead to their healing. Hence it may even be disadvantageous to produce tolerance to tuberculin, as is done by giving gradually increasing doses at frequent intervals. The ocular tuberculosis which chiefly concerns us is an extremely chronic and sluggish process, and even if untreated, does not cause death. The ocular lesions,

which are insignificant in size compared to tuberculous lesions elsewhere, have a marked tendency to heal, and, in fact, practically always do heal in time, although, if untreated, often not before sight is destroyed. To me it seems obvious that in just such lesions local reactions should do most good, and, owing to the great resistance of the patients, should be the least likely to do harm. I believe in producing reactions that you can see, so that you may be sure that you have produced them. Whether this method is suitable for all forms of tuberculosis I do not know. Probably it is for all forms in which tuberculin is indicated at all. Dr. Pratt tells me that he has been using it in certain cases of pulmonary tuberculosis, with the best results.

In regard to the question of the kinds of tuberculin to be used, I think it would be unwise to abandon old tuberculin until we have some evidence that the newer varieties are superior. I have obtained such good results with it that I should be loath to take up other tuberculins simply because they are new.

DR. W. H. WILDER, Chicago: An interesting observation in the examination of these cases is that, in making diagnostic tests with the old tuberculin, the cases distinctly tuberculous show a local reaction in the affected eye, or, at least, an aggravation of symptoms. If conjunctival and ciliary involvement is present, there may be an aggravation of this condition. This, it would seem, according to the observations of most men who have studied the subject, is about the most reliable diagnostic test that we have, although its absolute value may be questioned. This question of diagnosis is to be made the subject of a report by a committee at the next meeting of the American Medical Association, in which a number of gentlemen connected with this society are interested. I wish only to speak briefly of some work in which I have been engaged for a year or a year and a half, and which I shall report more fully in the future. It is with regard to the dosage of tuberculin in the conjunctival sac. Most of us have been fearful about trying the Calmette test, since observations have been made by numerous ophthalmologists of serious

results from its use. In many cases in which we get distinct local reaction in our diagnostic tests the eye immediately begins to improve. I was, therefore, prompted to see how much tuberculin could be used safely in the conjunctival sac in the normal eye, and also in one supposed to be tuberculous. Beginning with a small amount of old tuberculin, $\frac{1}{1000}$ milligram, in a suspected case of tuberculosis, the dose was gradually increased until a slight reaction was caused. It was noted in a number of cases that improvement of the condition followed this reaction. In a few of them a reaction did not occur until $\frac{1}{10}$ milligram was used in this manner.

I mention this in connection with the subject of vaccine therapy, but not to advocate its use. It is, however, a subject which is interesting me, and which I shall study still further. If we have some means of determining the dosage and a proper method of using it, I think tuberculin may be employed with benefit locally.

DR. S. D. RISLEY, Philadelphia: I have treated 6 cases of recognized ocular tuberculosis, all of them being affections of the cornea, iris, or sclera. They have been invariably placed in bed for two or three days, the temperature taken four times daily, and in neither case was any rise in temperature observed. One minim of old tuberculin was then injected subcutaneously in each case, causing not only general, but local, reaction. Only in the first case in which I used it did the local or general reaction prove troublesome, but was in no sense alarming, and rapidly subsided, the evening rise of temperature falling on the fourth day. The progress of the local disease seemed to be arrested. In the first case the injection was not repeated until the thirteenth day, causing a more moderate local and general reaction. After the reaction had subsided, there was a most rapid improvement in the local conditions, and in ten days the third injection was given, followed by very slight reaction, but a progressively rapid improvement in local conditions. In all 6 of these cases a cure was effected after prolonged treatment of the eye disease by usual methods had failed. In all the cases, not only did no harm result from the reaction following the injections, but the general health

was greatly improved. I hope to publish the details in the future.

DR. H. FRIEDENWALD, Baltimore: I should like to ask Dr. Weeks his opinion of the Römer's pneumococcus-serum. I refer to the treatment of corneal ulcer. I did not hear Dr. Weeks make any reference to it.

DR. JOHN E. WEEKS, New York: I did not mention it. It has not proved of real value. In its preparation "old" tuberculin is subjected to a temperature of 60° to 90° C., varying with the different laboratories in which it is produced, and it is supposed that the old tuberculin is less valuable as a therapeutic agent because of that. The other preparations are subjected to 50° C. I have treated three cases with the old tuberculin with excellent results, but a larger dosage is necessary to produce the same therapeutic effect than with other tuberculins.

I feel that light is dawning upon the question of the dosage of tuberculins and vaccines. We know that these preparations are antigens, that they must excite the tissues to the production of antibodies, and if the tissues are not in condition to produce antibodies, the injection of the tuberculin or vaccine is not of any value. In some cases excessive doses produce death. There are a number of cases on record where death has occurred in the "negative phase." It is necessary to know how the system will react to the introduction of antigens which these substances are, and it is not at all necessary to produce the local manifestation by the dose in order to produce a favorable effect upon the disease. In fact, it is much better to avoid the depression that is indicated by the reaction. In pulmonary tuberculosis, as a rule, the tissues are not in condition to produce antibodies, and in those cases the use of tuberculin is of no value whatever. If we are using antiserum, the question is a different one. There we are introducing antibodies that are already prepared, and there the size of the dose can be increased with value.

Now, in regard to the effect that Dr. Wilder has obtained by the introduction of tuberculin to the conjunctival sac, it is thought by a great many that the production of anti-

bodies is greatest in the vicinity of the introduction of the dose of the remedy. Wright holds that the production of opsonins is greatest at the point of introduction of the vaccine. It is possible that the dropping of dilute solutions of tuberculin into the conjunctiva may produce in that vicinity the more active development of antibodies.

DR. GEORGE S. DERBY, Boston: I think this method of giving tuberculin vaccines and serum is an exceedingly dangerous one. It has been observed many times over that large doses produce violent reactions. You cannot tell how severe the reaction is going to be. It may cause dissemination of the process throughout the eye. Until we have some accurate method of dosage, it is safer to use mild measures. The average man is safe when he employs the mild method of dosage.

I agree with the speaker who advocated rigid observance of general hygiene. That is the very first thing that should be observed, and the tuberculin treatment should always be secondary. Personally, I use a filtrate of tuberculin which is not prepared by heat, so that it is free from the objections which apply to the ordinary old tuberculin.

SUGGESTIONS REGARDING THE NATURE OF VISUAL SENSATIONS.

BY GEORGE T. STEVENS, M.D.,
New York.

Perhaps my excuse for presenting an elementary subject which has been fully discussed may be found in the bulletin furnished us by the secretary in connection with this part of the program. The part to which I refer reads as follows:

"The theory that once prevailed, that visual sensations consist of veritable reproductions in the brain of images cast upon the retina, has been in late years largely discarded, mainly through the influence of the teachings of Helmholtz. This old theory, however, which has always had some defenders, has recently been somewhat revised and elaborated. The object of the present discussion is to briefly suggest a few facts and experiments which bear upon the subject."

I confess that I would not have selected this topic had I not at the moment of receiving from our secretary the circular asking for contributions to this meeting been engaged in the perusal of an article published in a French scientific journal, an article by a writer of some distinction, in which the author summed up his conclusions somewhat to this effect:

The visual impression is received as a picture upon the retina, whence it is transmitted by way of the optic nerve to the appropriate ganglia of the nervous centers, being on its way adjusted and made erect and then again pictured within the brain.

It would hardly seem necessary to discuss such a proposition before this society, for I assume that we all accept the

view that the visual impressions of forms of objects which we observe are the result of movements of the visual organs. In other words, that we do not get the picture on the retina as we have so often seen it represented in our text-books on physiology. It is a very generally conceded doctrine today among physiologists and psychologists that we obtain our conceptions of form, those of the three dimensions, through the movements of the eyes or through the knowledge of the movements which would be required visually to traverse the object observed. This last method I have elsewhere spoken of as that of "unconscious conclusions." Therefore, in the general presentation of the subject I shall not attempt to say anything new or original, but at the end I purpose to renew some practical suggestions to be drawn from well-known experiments—suggestions which I have before made, but which I suspect have not received any general acceptance.

If there were occasion for proving the incorrectness of the older view, the view that a picture formed on the retina is transferred to the brain, where it becomes a conscious sensation, we might refer to the very interesting series of cases reported to this society by Dr. Kipp a year ago. In that series of cases the disability consisted of a very small area of disease situated exactly at the macula. If I recall the histories correctly, in none of these cases did the affection extend to an area equal to half the diameter of the disc. In all the cases, however, there was a marked reduction of vision. A diseased area of the retina of this extent, but situated elsewhere than at the macula, might have caused a scotoma or might have had little effect upon vision. If it is replied to this that the macula is the point of extreme sensibility of the retina, and that, therefore, a disability of this portion must cause greater disturbance of vision than one situated elsewhere, because the most clearly defined portion of the retinal picture would be eliminated,

we should remember that when we look at a surface within a moderate field of view we do not see it fading out from center to circumference, as we would were the center of the field the only portion seen clearly.

In fact, a scotoma would not interfere with the ability to see to the extent stated by Dr. Kipp. On the other hand, when the center from which all estimates of distance are made is disabled, we are no longer able to control the exact movements of the eye, and hence are no longer able to form adequate conceptions of the forms of objects by the eye, and this leads me to a renewal of the statement that at the present time there is a very general consent among physiologists and psychologists to the view that our consciousness of form through the medium of visual sensations depends upon the movements of the eyes.

Assuming this view, we may regard the main expanse of the retina as a finder by means of which the adjusting apparatus of the eye may bring the fovea into direct relation to any desired point of the object to be seen, and may carry this relation to as many different points as may be required in order that the sense of movements of the eye shall convey an impression of the form of the object seen; or, in place of these actual movements, the knowledge gained by experience of the necessary energy which would be demanded in order to execute these movements may and does in some measure replace the actual physical act of movement.

To illustrate this proposition I will present a few very simple diagrams, placed in the stereoscopes, which will be distributed. Most of them are not new; some of them are, I assume, familiar to you, and it is because of their simplicity and their familiarity that I have selected them as guides to a few suggestions.

The first of these diagrams (Fig. 1) is seen to consist of two pairs of vertical lines, the lines of one pair being sepa-

rated from each other somewhat more than are those of the other pair.

Looking at the diagram through the stereoscope we observe two upright lines or staves, one of which appears considerably in front of the plane of the paper, the other behind it. We see also that the staff which appears in front also appears materially shorter than the other. Now, since all the lines are, of course, at the level of the paper, and since they are all equal in length, we have a phenomenon or rather two phenomena to account for. We have also to consider an important fact, which is apparently not consistent with one of the doctrines of the physiology of sight, namely, the doctrine of corresponding points.



Fig. 1.

Considering this last fact first, we observe that the two pairs of lines unite as a single pair, although on the two retinas they cannot fall upon corresponding points. As a matter of fact, it is rare, and only in case of very small points that the image of an object presented to the two eyes falls upon corresponding points of the two retinas. This statement might be thought incorrect when we recall the fact that a slight obstruction to the proper adjustment of the eyes or the interposition of a prism may induce diplopia. Yet it is a fact that images of objects of three dimensions cannot be simultaneously impressed upon corresponding points of the two retinas. I have elsewhere shown that

these corresponding points are *finders* of distances and directions from the maculas.

If we hold before our eyes two pencils, erect and parallel, but one nearer to the face than the other, we shall observe that the space between them is greater when one eye is closed than when the other is closed. In the design in the stereoscope the distance between one pair of lines is greater than that of the other, corresponding with our ordinary experience, but, as in ordinary experience, the impressions are not made upon corresponding points of the two retinas. If we ask an explanation for the apparent positions of the two lines, we may find it in this diagram (Fig. 2). Let the half-shaded disc represent the thicker of the lines of the two

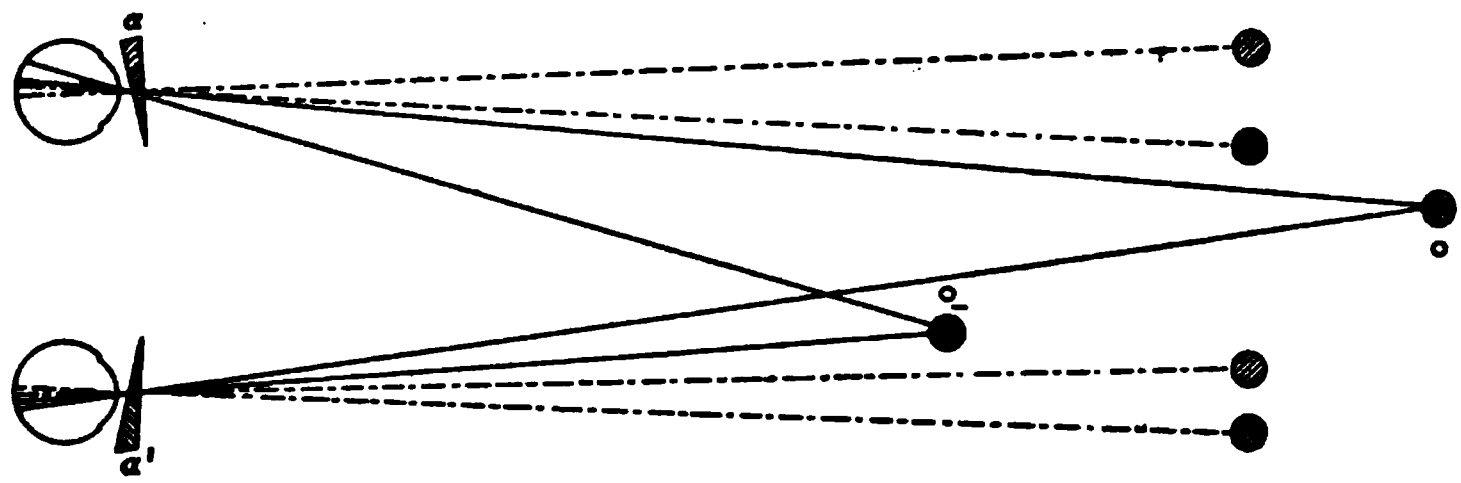

Fig. 2.

pairs in the stereoscopic design and let the two full-shaded discs represent the thinner lines. Then the distance between the full-shaded discs is greater than that between the half-shaded ones. Now, as the lines of light from these discs fall upon the two prisms, a and a', they are deflected in such a manner that the combined images of the two pairs are projected so as to meet, the one pair at the point 0, the other at the point 0′. Now, since the angle 0′ is greater than the angle 0, the image of the combined elements which form this angle appears nearer than the image formed at 0, on the principle that our experience has taught us that the greater the angle of convergence, the nearer to the eyes is the object.

Stereoscopic diagrams, such as Figs. 1 and 3, have been commonly characterized as "optical illusions," and yet they are more in conformity to our ordinary experience than the common shaded picture.

The second notable phenomenon in the stereoscopic experiment is the apparent inequality of length of the two staves. It is evident that two equal lines situated at the same plane and at the same distance from the eye could not form two unequal images on the retina, yet it is quite impossible to receive any mental impression of these two lines, as we see them in the stereoscope otherwise than as two lines of quite unequal length.

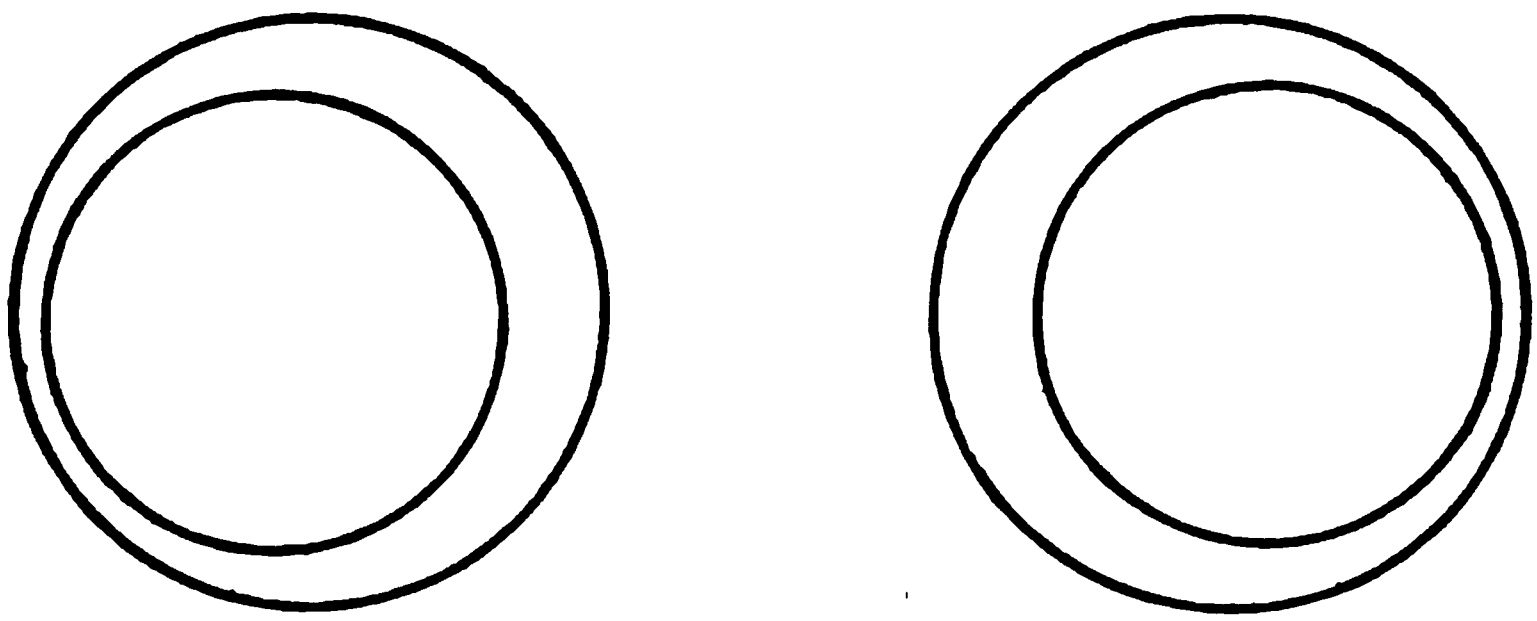

Fig. 3.

This is not only a mental conclusion, but a secondary conclusion. The first conclusion is that one of these staves is in front of the other. This being accepted, the conclusion is drawn from this assumed fact that, one being nearer than the other to the eye, and yet occupying the same angle of movement, it must of necessity be shorter than the other.

Passing to the next diagram in the stereoscope (Fig. 3) we have a striking illustration of our unconscious conclusions, which may be regarded as the counterpart of Fig. 1, for while in that diagram lines all actually alike in length appear of unequal lengths, in this case circles which are, in fact, quite unequal appear to be of exactly the same size.

Glancing at the card, we observe two pairs of unequal circles, the lesser circle in each case within the other. Viewed by the stereoscope we have two exactly equal circles forming the two ends of an exact cylinder. The principle is precisely the same as that involved in the first diagram, but its application is to conditions exactly the reverse. Now it is evident that in neither of these cases is the mental impression we receive in any sense a copy of a picture received by a retina or by both of these organs. As literal copies they would have no meaning, but as representing our

Fig. 4.

habitual experiences of adjustment of the positions of the eyes and of the movements of those organs, they induce unconsciously conclusions which we cannot resist.

A third diagram in the stereoscope (Fig. 4) is familiar to those who are students of Helmholtz, as it is taken from his great work on physiologic optics.

We notice, without using the stereoscope, two series of oblique lines which, when united in the stereoscope, combine to form a series of diamond-formed figures. As we look for a few moments one series of lines disappears, then reappears, and the other series perhaps fades away. Thus,

if the two eyes of the observer are nearly equal, there is a pretty uniform and alternate disappearance and reappearance of each series of lines.

Some investigators have explained this phenomenon on the theory that the retinas become alternately fatigued. The explanation is not sound. Helmholtz explained it on the theory that we alternately withdraw attention from one and the other series of lines.

This is in a way true, but it is not the whole truth, and does not explain the phenomenon. We can show this by

Fig. 5.

another diagram in which the lines of the two series are arranged one in the horizontal the other in the vertical direction (Fig. 5). When we combine these two series as before, we have a number of squares, and the squares are more permanent than the diamonds; neither series of lines has so marked a tendency to disappear as is shown in the other diagram. Now, if it were as easy to see the oblique lines as the horizontal and vertical lines, there would be as little tendency for the first to disappear as for the last. As a matter of fact, movements of the eyes in oblique and opposite directions are not so easy as movements in direct

vertical and horizontal directions, hence in case of the oblique lines one or other eye discontinues its movements, and when the movement stops, the lines necessarily disappear. To some extent this also occurs in the case of the vertical and horizontal lines, but to a much less extent.

It is a law of sensation that if one of the several attributes of a sensation is absent, there is no sensation. The principal attributes of visual form perception are light and movement of the eye. If either is absent, vision fails.

We may now make a practical application of this principle.

We are all familiar with the fact that most strabismics are amblyopic in the habitually squinting eye. This amblyopia often amounts to an absolute impossibility for the strabismic person to distinguish any form, or even to locate in general direction a lighted candle in a darkened room. Yet the ophthalmoscope may not indicate any disability of the eye, and, in fact, the eye as an organ is essentially normal. Why then does it not see? Because it has forgotten, if it ever learned, how to move in conformity to the signals upon the retina. A blindness depending upon a disease or a physical defect of the eye or of its optic nerve is a sensorial blindness, but an inability to see, such as has just been mentioned, is a psychic blindness arising from an inability to interpret the meanings of the impressions received at the retina. It is as though one were looking at strange characters representing words of an unknown language. The characters, which to one who knows them and the language, may convey clear and definite ideas, but to another, they suggest nothing but irregular lines and spaces.

Taking this view of the amblyopia of strabismus, it follows that in any effort to correct the defect we have a question aside from the mere cosmetic improvement—it is the question of restoring an impaired usefulness to an

important organ. It is a question of good vision against poor or almost no vision.

It is not too much to say that the amblyopia of strabismus should be corrected with the correction of the physical defect, and that with intelligent procedure the amblyopic eye does become a good seeing eye. But the restoration of useful vision cannot be accomplished by the procedures commonly practised in such cases. The procedure must have reference to the ability of the eye to move exactly in conformity with its fellow and in conformity to the typical plan of movements of the eyes. Exactly in proportion to the improved ability to conform to such movements may the visual power be expected to improve. The purpose of a correction for strabismus, therefore, should be to establish between the two eyes such normal and easy conformity of movements that the former squinting eye will adjust itself in all cases to the circumstances of the relative impressions on the two retinas. With equal freedom of movement the disabled eye will become an educated and, therefore, a useful one.

DISCUSSION.

DR. LUCIEN HOWE: I am one of those who still believe that we do see without moving the eye. If I close one eye and look steadily at an arrow I see it, and I think my eye is still. At least, there is nothing to indicate that my eye is in motion.

A WINDOW RESECTION OF THE NASAL DUCT IN CASES OF STENOSIS.

J. M. WEST, M.D.,
Baltimore, Md.

(Read by invitation.)

Over a year ago Dr. R. L. Randolph referred to me a case of bony stenosis of the nasal duct of such a degree that the introduction of the smallest probe beyond a point about 5 mm. below the lacrimal sac was impossible. The patient was suffering from epiphora in a marked degree. I operated, following the so-called Killian procedure—that is, the anterior part of the inferior turbinate was removed, after which the entire nasal duct was opened up. The epiphora stopped at once, and correspondence with the patient during the past year showed that a permanent cure was obtained.

Ophthalmologists agree that this class of cases is extremely difficult to deal with, since the treatment with probes or with the stricturotome is inapplicable. The method of opening the nose from without through the lacrimal fossa, as recommended by Toti, has not, as far as I can learn, been adopted. The resulting scar and the general anesthesia would argue against it, even provided this procedure gave as good results as other methods. Extirpation of the lacrimal sac has been followed by some with success, particularly in cases with associated dacryocystitis; while others are not enthusiastic over this method of treatment. Then, too, if possible, it would seem more rational to remove the stricture, the primary cause of the trouble, than to extirpate the sac, which is only secondarily involved.

The rhinologist has given but little attention to the surgical treatment of this condition, a lack of interest explained by the fact that patients suffering from epiphora usually seek relief of the ophthalmologist. Intranasal operations for cure of stenosis of the nasal duct have, however, been described by Caldwell, Killian, and Passow. In 1893 Caldwell reported a case in which, after passing a probe into the duct as far as the stenosis, he removed with an electric trephine part of the inferior turbinate as far back as the nasal duct. The duct was then followed in an upward direction until the probe was reached and drainage was established. Six years later Killian advocated the removal of the anterior part of the inferior turbinate and the entire nasal wall of the nasolacrimal duct. In 1901 Passow reported having done a similar operation four times under general anesthesia, with good results.

All these intranasal operations involve the removal of a part of the inferior turbinate, and, considering that in all branches of surgery our aim should be toward conservatism when possible, it occurred to me that a conservative intranasal procedure—a window resection of the lacrimal duct above the inferior turbinate, leaving this structure, a physiologic organ, intact—ought to accomplish the same result as the more radical procedure of Killian and Passow. Moreover, owing to the ability to control hemorrhage by the use of adrenalin, the operator is able to do more accurate work than was formerly possible. The operation suggested is shown in Fig. 1, and consists in resecting, under local anesthesia (cocain and adrenalin), a window from the nasal duct in the upper part of the nose above the inferior turbinate, and involves the removal of part of the lacrimal bone and also a piece from the superior maxilla. (The instruments used are bevel-edged chisels.) This removes a stricture in the upper part of the duct, but leaves a stenosis in the lower part untouched. It is, however, immaterial

whether the lower part of the duct is stenosed, so long as the tears can drain through the artificial window. Previous to operation a probe is passed into the duct to act as a guide.

Fig. 1.—Window resection of the nasal duct.

The canaliculus may be slit or, preferably, as suggested by Dr. Randolph, a fine probe is passed through the dilated punctum. In no instance can the operation make the previous condition worse, and the result is either a complete

cure or considerable improvement. Care must be taken in operating that the antrum is not opened up.

The operation has been done in six cases, four of which were cured and two improved. Of the cured cases, two were of bony stenosis high up in the duct, and two presented apparently a condition of hypertrophy of the entire lining membrane. The two improved cases presented also a condition of thickening of the lining mucous membrane. One of the cases cured was also associated with definite dacryocystitis; another, a traumatic case, presented a lacrimal fistula of eighteen months' duration. Three of the cases which were cured I am able to demonstrate before the society. The description of the operation and the demonstration of these cases are in the nature of a preliminary report, and serve to call attention to the encouraging results which have been obtained. It is my purpose to report later with Dr. Randolph the results in a series of cases.

I am indebted to Dr. Randolph, who first interested me in this work, and whose coöperation and enthusiasm have enabled me to develop the technic of the operation.

DISCUSSION.

DR. ROBERT L. RANDOLPH, Baltimore: The case alluded to by Dr. West was that of a brakeman on the B. & O. Railroad. He had found his efficiency much impaired by a chronic dacryocystitis of several years' standing. He had received a blow on the nose from a heavy piece of iron which had crushed in the lower end of the sac and upper end of the nasal duct. A No. 4 probe could be passed, but nothing larger. It occurred to me then that through an intranasal operation would be the proper way to seek relief for such a condition, and with this in view consulted with Dr. West, of the Laryngological Department of the Johns Hopkins Hospital. Dr. West has just described what was done in this case, and in all cases of epiphora which were afterward admitted to my service in the dispensary. It would seem important to make the window big and carry it

high up, and from the few cases which have been subjected to this method of treatment, it looks promising, and particularly so in cases of traumatic dacryocystitis. The brakeman returned to work and has never had any trouble since. It is proposed in the future to simply enlarge the punctum and pass in a No. 4 or No. 5 probe without slitting the canaliculus. To effect a cure in this troublesome class of cases without destroying in a measure the function of the canaliculus, as is often done, would be a great gain. It remains to be seen whether this opening will be closed with granulation tissue.

ILLUMINATED BOX EYE-TESTING CHART.

HARRIS G. SHERMAN, M.D.,
Cleveland, Ohio

My reason for submitting the following report is the difficulty we all experience in refraction work, whether dependent upon solar or artificial illumination, in illuminating our test-type charts. I take it for granted that nearly all of us employ artificial illumination, whether reflected or transmitted.

Until Black's admirable transluminous test-type cabinet was practically made unobjectionable by eliminating the light spots, I had experienced the usual difficulty due to lack of uniform intensity of light, confusing reflection, etc., no matter how the cards were placed, or whether porcelain plates or paper charts, white or black, were used.

While the National Electric Lamp Company were at work on Dr. Black's chart, Dr. Hyde, head of the Department for Physical Research, called my attention to a very clever device originated by Dr. Herbert E. Ives, of his department, in conjunction with Dr. P. W. Cobb, Physiologist. The gentlemen were engaged in working out certain physiologic problems connected with vision and illumination, the need

having arisen for a visual acuity test-object as free as possible from the defects of existing forms.

I am quoting from Dr. Ives's description of his device with permission. He states that the various acuity test-types of different sizes, such as are used by the oculist for eye testing, are unsatisfactory as an exact measure of vision, owing to the fact that all letters of the same size are not equally distinct. He believes that the details of the test chart or plate should be continuously variable in size, but that the illumination, the flux of light entering the eye, the distance of the object, and the observer's visual accommodation should remain the same.

It occurred to Dr. Ives to make use of a well-known property of fine gratings, such as has been used in the testing of diffraction grating ruling engines. If two gratings, consisting of glass plates ruled with fine parallel equidistant opaque lines, too close to be separated by the eye, are laid one over the other and rotated, there are produced parallel dark bands whose separation varies with angle of grating lines to each other. The gratings are made so that the transparent and opaque spaces are of equal width. It is seen that at regular intervals there are bands across the superposed gratings, through which no light passes, with spaces between that transmit light as the angular position of the gratings is changed and these bands of complete opacity alter their distance. As their distance changes the distribution of light from center to center remains the same, and, unless the field is very small or the bands are very far apart, the total flux of light is constant. From these factors, Dr. Ives works out the geometry of the figure.

With these gratings it is found that the whole range of band distances needed corresponds to about 20 degrees rotation. For this angle the difference between the arc and the chord is about 0.6 %, the quantity absolutely negligible in visual acuity photometry. It is, therefore,

planned to mount them on rings to rotate by a slow motion yoke and screw, with scales and verniers attached directly to the rings to read the angle of rotation. The visual acuity is then as the angle read off. It is further provided that the gratings shall each rotate so that the bands, which bisect the angle between the grating lines, shall keep their direction constant. Between observations, while the test-objects appear a uniform gray, it will be possible to change the direction unknown to the observer, so that his judgment of the point where the lines are just visible will be entirely unaided by memory, and his statement of their direction affords a check of the correctness of his observation. If this is done, the observer must be free from astigmatism. The gratings with their mountings are placed behind an opening in a screen which conceals, if desired, the movements of the person setting and reading the angle. The illumination is, of course, from behind. Under these conditions the cross grating would appear to admirably fulfil all requirements of a visual acuity test-object.

As stated above, the cross grating test plate was designed for use in certain physiologic work. It is, however, equally applicable to any place where visual acuity is used as a test of illumination. Because of its compactness, it would appear well suited for use by oculists in place of the rows of different sized letters now employed. Astigmatism could be detected, and its angle determined by readings on the test plate turned at various angles.

The above quotations from Dr. Ives's interesting description are given for their suggestive value, with the hope that Dr. Ives may have hit upon a very clever and accurate device which may prove of great value in our refraction work.

REPORT OF IMPROVEMENTS MADE ON ILLUMINATED BOX EYE-TESTING CHART, BY ENGINEERING DEPARTMENT, NATIONAL ELECTRIC LAMP ASSOCIATION, MARCH 23, 1910.

The chart submitted by Dr. H. G. Sherman was designed by Dr. Black, of Milwaukee. Among the claims made for an illuminated chart of this character is the elimination of direct reflection to the eyes of the patient and the distinct outlining of the characters.

The chart consists of a wooden box framework about 11 inches square and 32 inches long, so mounted as to be capable of being revolved about its vertical axis. The sides are fitted with plates of milk glass upon which are painted in black the letters and characters used in eye testing. In its original form the chart was illuminated by five 10 candle-power, all-frosted carbon lamps mounted on the vertical supporting rod. These were arranged as indicated in Fig. 1. It is self-evident, after an inspection of the sectional view, that, with the lamps in the positions shown, faces C and D will be much more uniformly illuminated than faces A and B. It is also obvious that various portions of the four faces will be illuminated to highly different intensities, owing to the fact that some of the lamps are closer to one face or another, the direct rays of the nearer lamps producing highly illuminated spots. This is a decidedly objectionable feature in eye testing, and was the occasion for Dr. Sherman's request that we redesign the system of illumination.

Inasmuch as it was neither practical nor necessary to light all four faces of the chart uniformly at the same time, face D was selected as the working face for the preliminary test. It was found that, by simply placing small pieces of cardboard (shown at *a* and *b* in Fig. 1) in front of each of the five lamps, thus cutting off the direct rays from these lamps,

there was a decided improvement in uniformity of the resulting illumination.

It was thus evident that the solution of the problem

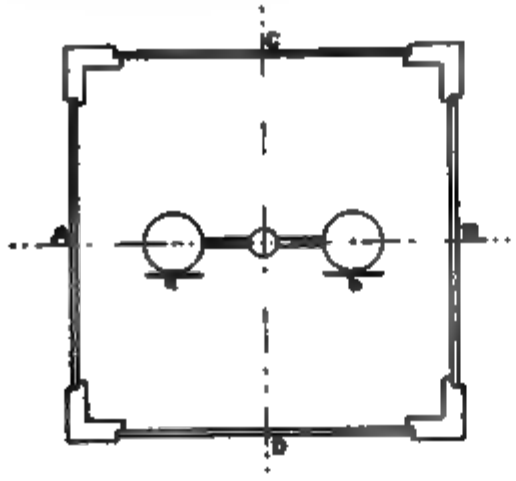

Fig. 1.

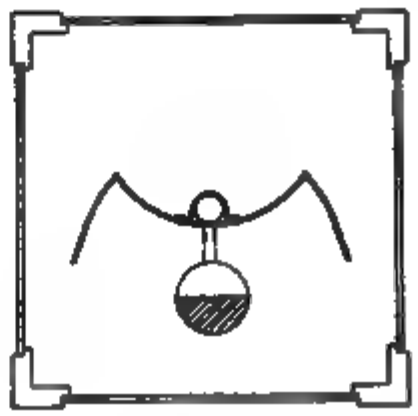

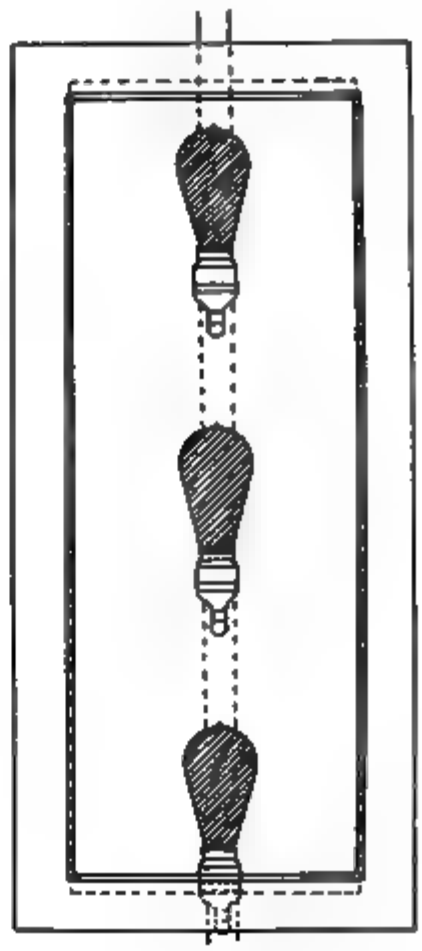

Fig. 4.

lay in the use of reflected light only for the illumination of the working face. To this end a reflector of design shown by Fig. 2 was made up. This was made of sheet iron and

painted inside with white enamel. It was of the cross-section shown, and extended the entire length of the frame-work. It was mounted as indicated by the sketch, the two lamps on one side of the vertical rod, shown in Fig. 1, being removed, and face A (Fig. 1) being selected as the working face. The three lamps on the other side of the vertical rod (Fig. 1) were replaced with three 40-watt "Mazda" lamps, these three of 32 candle-power each practically doubling the total candle-power of the original installation.

Inasmuch as only reflected light was desired on face A, and no desirable reflectors of sufficient size to meet condi-

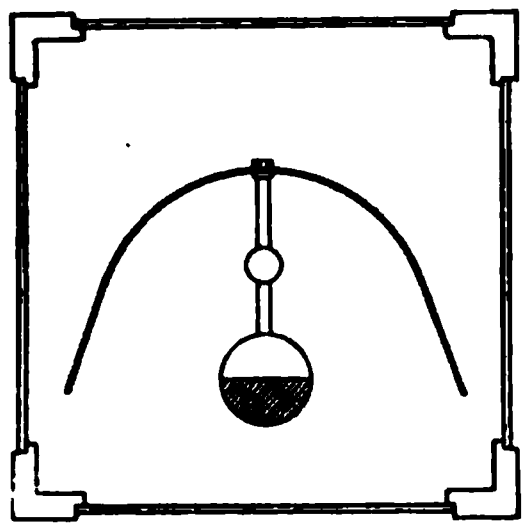

Fig. 2.

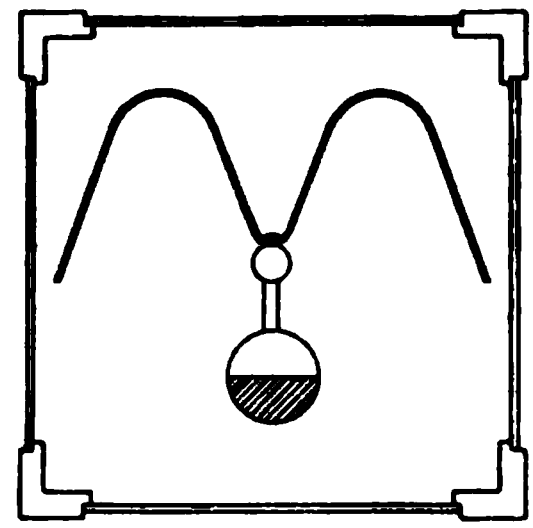

Fig. 3.

tions could be found on the market, one-half of the lamp bulbs was covered with a thick coat of aluminum paint, as shown in Fig. 2, the coated side being turned toward face A to be illuminated. The light from the lamps was thus thrown back into the large sheet metal reflector, and was again reflected to the working surface.

With the equipment as shown in Fig. 2 an illuminometer test was run on the working surface. Inasmuch as it was found that the black characters on the test-chart materially affected the readings obtained, this plate was removed and a sheet of thin white bond paper substituted. This surface was divided into 44 squares, approximately $2\frac{1}{2}$ inches on a side, and illuminometer readings were taken at the center

of each. The illuminometer is a small, portable photometer, and as used in these tests, the illumination produced by the rays of light transmitted through the paper on a milk-glass screen 2 inches in diameter at a distance ¼ inch from the illuminated paper was balanced against the light from a

Photograph 1.

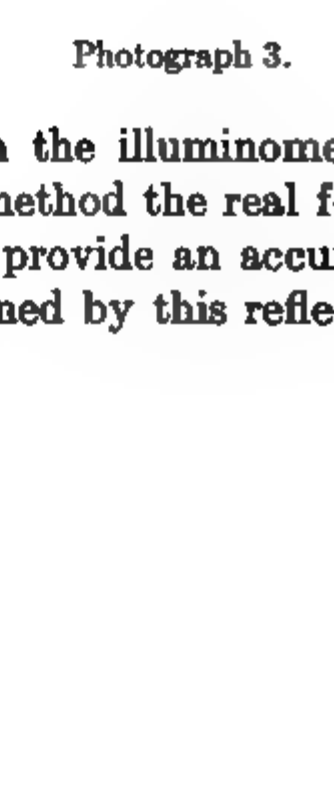

Photograph 3.

standard "Mazda" lamp contained in the illuminometer. It was not our idea to obtain by this method the real foot-candle intensities on the plate, but to provide an accurate method of comparing the results obtained by this reflector with those of other designs.

A mere inspection showed a vast improvement in conditions. The illumination resulting was much more uniform. The illuminometer readings showed that, while the result was apparently much better than originally, the uniformity of the illumination was not yet satisfactory, there being a

Photograph 2.

total variation from 96.3 %; the maximum and minimum readings being respectively, 55.5 % above and 40.8 % below the average.

The readings in the table correspond in position to the location upon the glass plate of the square upon which they were taken, there being four squares across and eleven up and down the plate.

A series of tests was then run with other reflector designs, but with the lamps remaining the same. The results given by a metal reflector of design similar to Fig. 3 show an improvement over the above equipment, but still leave much to be desired. We have here the maximum intensity to be 31.7 % above the average, and the minimum, 35.3 % below.

A reflector of the design in Fig. 4 was made up of white bristol board. The resulting illumination was much better than that of all the prior tests which were made.

This reflector, while still giving a variation of 18.4 % above and 22.45 % below the average, was made up, the final results of which are given in Table A, giving the maximum and minimum values on the plate 18 % above and 19 % below the average. With this variation, the difference in illumination between the light and dark portions of the working face were unnoticeable to the eye.

Accompanying this report are photographs of the chart. Photograph No. 1 shows the general exterior appearance. Photograph No. 2 shows the interior of the chart, indicating the arrangement of the lamps and reflector. Photograph No. 3 shows the face of the chart illuminated for use in its present condition.

TABLE A.

	a	*b*	*c*	*d*
(1)	62.9	63.2	60.5	60.3
(2)	72.6	73.5	77.6	66.6
(3)	79.8	79.8	82.2	71.4
(4)	81.0	84.6	87.1	76.2
(5)	76.2	81.0	87.1	79.8
(6)	75.9	83.5	87.1	78.6
(7)	77.3	85.9	86.4	76.9
(8)	71.4	79.8	82.5	77.9
(9)	64.8	77.6	79.6	63.2
(10)	60.5	63.9	65.8	62.9
(11)	59.8	61.4	61.7	60.9

Average	73.834
Maximum	87.100
Minimum	59.800
Per cent. above average	18.000
Per cent. below average	19.000

A BRIEF NOTE CONCERNING THE TROPOMETER.

GEORGE T. STEVENS, M.D.,
New York.

At the last session of this society Dr. Howe presented a paper in which he described an instrument which he proposed as an improvement upon the Stevens tropometer. I should have treated the proposed modification with the silence which has characterized my treatment of quite a number of supposed improvements upon instruments which I have happened to devise, had not the author of the paper clearly implied that I had myself resorted to the questionable device of improving on the instrument of another with the view of making it my own.

In the course of that paper Dr. Howe stated that a tropometer "very similar" to that of Dr. Stevens, and over which the Stevens instrument was an improvement, had been described by Nicati in 1876.

In the discussion following I declared that no tropometer "very similar" to that of Stevens had been described or used prior to the instrument which was exhibited at the meeting of the American Medical Association at Baltimore in 1894.

Dr. Howe's response to this statement, a reply calculated to emphasize the implication of the appropriation by myself of another man's labors, was to refer to a paper by Nicati, a paper from which he did not read. As the discussion was closed, there was no opportunity to say what I wish now to state, that the instrument described in that reference was not only not "very similar" to that of Stevens, but that neither in principle nor in detail had it any resemblance.

The instrument therein described was a perimeter, with

all the limitations and imperfections represented by that instrument as a measurer of ocular rotations. It had attached to it a sighting instrument (une lunette) for determining when the eye was at the center of the arc of the perimeter—and this sight could be adjusted to any perimeter. Otherwise it differed in no respect from other perimeters, and the methods of examination were exactly similar to those before employed with perimeters.

It is this perimeter, by means of which measurements of rotations of no normal eye could be determined, of which Dr. Howe says that it is "very similar" to the Stevens tropometer, and upon which the latter is an improvement, and to which Dr. Howe refers as a proof of priority.

METHOD OF MEASURING THE FIELD OF REGARD, BY DOCTOR NICATI, TRANSLATED FROM GAZETTE DES HÔPITAUX, 1877, P. 556.

Given a perimeter like Landolt's, and also a finder (lunette) so fixed that its optical axis cuts the center of the graduated arc of the perimeter, so that it is constantly directed toward the observed eye. At the focus of the ocular the finder has a thread or, better, a fine line traced perpendicularly in a glass slide which can be moved at will in the plane of the focus. The eye to be observed being at the center of the graduated arc, and the observer fixing this eye through the finder, the patient looks as far as possible in a given direction by following an object which is moved along the arc. At the same time the indicating line of the finder is moved so that it is tangent to the border of the cornea opposite to the direction of the movement. It is left in place when the cornea has reached its extreme position, and will serve as a marker.

Carrying, then, the same object as before along the arc, for example, the point of a pencil, the position is sought where it must be carried to bring the cornea again in its position tangent to the marker. This point indicates in degrees the angle of greatest excursion sought.

(The context shows that the purpose of the finder is

simply and only to enable the observer to know when the eye is at the center of the arc of the perimeter, the measurement of excursion being read from the arc.—G. T. S.)

DISCUSSION.

DR. LUCIEN HOWE, Buffalo: First, I wish to disclaim the thought that Dr. Stevens intentionally presented anything as new which he was aware had previously been published. Only, it has occurred to us all probably to think we have some new idea and afterward that we discover that it is old.

The instrument which Nicati also described as a tropometer consisted, like the tropometer of Dr. Stevens, of an arrangement for viewing a point on the cornea through a lens. Then, as the eye turned from that position, the amount of rotation was marked in his instrument on an arc, by the later instrument on the tangent scale of an arc. The name is the same, and the principle seems to be so similar, that the similarity was naturally mentioned in my paper a year ago.

ON THE DIFFERENT PRISM TESTS, WITH PRESENTATION OF A SERIES OF PRISMS ARRANGED ON A CIRCULAR DISC.

LUCIEN HOWE, M.D.,
Buffalo, N. Y.

It is unfortunately true that there is still much confusion, even in the minds of ophthalmologists, as to what is meant by tests with prisms. One practitioner means by this one procedure, while a second means another method which may give quite different results.

The first object of this paper is to call attention very briefly to the three methods of using prisms which are generally employed, and, second, to present an instrument which has been found useful in making tests of both the minimum and maximum powers of duction.

Concerning the Use of Prisms for Measuring the Position of the Eyes at Rest.—The principle on which this familiar test depends is well known. It is the physiologic fact that if the retinal image of one eye is displaced too far from the position which it should occupy to correspond to the retinal image in the other eye, then, there being no longer any possibility of uniting these retinal images, each eye tends to swing into the position which is most natural and comfortable to it. Thus, if we take the usual example of placing a prism base down before the right eye, and the subject under examination is directed to look at a light immediately in front, the displacement of the image on the lower part of the retina of the right eye is such that the right eye, as well as the left, tends to swing into the position most natural to the eyes when they are at rest. It is only necessary to mention this test for esophoria, exophoria, etc., so familiar to every ophthalmologist. The only reason for doing that is to show that when prisms are used in this way they indicate the position which the visual axes assume when the eyes are at rest, that is to say, the *static* position of the globe. This group of tests, of course, is to be clearly and widely separated from the two groups to be described next.

Concerning the Use of the Prisms to Test the Dynamic Condition.—Although the majority of ophthalmologists recognize a distinct difference between the use of prisms to show the static as distinguished from the dynamic condition, it is by no means every one who recognizes the fact that when we test the dynamic condition of the eyes by one method we obtain one result, and if we use the prisms in another way, we obtain quite a different result.

For example, in testing what we call the strength of the adductors, if we place a spot of light at a distance of 5 meters or more in front of the patient, and begin with prisms, arranged in series, or prisms from the test-case, which are

amply *sufficient to produce diplopia*, and gradually *decrease* the strength of these prisms, we find usually that a prism of 6 or 7 degrees before one eye with the base out (or 3 to $3\frac{1}{2}$ with each eye) is the weakest which permits double vision. This has been called "the minimum power of adduction." It is quite constant, and a very considerable number of tests approximately give the same results.

But, on the other hand, if the separate prisms are arranged in series, or especially if we use the revolving prisms, such as we call the Risley prisms,—in using any of these, if we begin with a prism base out which is so weak that double vision is not produced, and if we *increase* the strength of the prism *very gradually*,—particularly if we keep the patient intently looking at a distant object, then apparently the effort to obtain binocular vision becomes so great that we find by this method of testing the person can overcome a prism before one eye of 10, 12, even 15 degrees or more. The result obtained by such an effort has been called "the maximum power of adduction." It is by no means constant. It varies not only in different persons, but also in the same person at different times.

This observation is by no means new, and in order to overcome in part the confusion on this point, the Section of Ophthalmology of the American Medical Association agreed that in any mention of the use of prisms for testing the dynamic condition of the eyes it should be understood that the examiner had begun with prisms which were too strong and proceeded with those which were weaker.

In spite of that rather exact definition it is still unfortunately evident that ophthalmologists among us disregard this matter, so important to us all. If we are to understand each other intelligently, we must keep this difference of these tests clearly in mind. The frequent failure to do that is the reason for calling attention to it now.

A Simple Instrument for Making Tests of the Dynamic Condition.—From the foregoing it is evident that the revolving prisms of Crete and Risley are in general not so reliable for the tests of the dynamic condition as are separate prisms or prisms in series. The separate prisms, of course, are ready in every ophthalmologist's case, but the trouble of reaching first for one, and then another, prism is so great that long ago these prisms of rather large size were placed one above the other in series, such as the series suggested by Noyes and by others.

For several years I have also used a series of about 20 such prisms on a long handle. The difficulty with them all, however, is that they are inconvenient and clumsy, and if the series is at all complete, the instrument is too long to be pushed up and down before the patient's face. Of course, it is impossible to take this in one's pocket for home or hospital examinations. In view of these disadvantages it occurred to me to make these prisms very small, and arrange them on a disc, as we have the lenses in the disc of an ophthalmoscope. With a disc of say 11 such prisms of even numbers on one side, and 11 other prisms of the odd numbers on the other side, we have at once a range of from 1 to about 40 degrees. Accordingly, I have had such a disc constructed. It is simple in the extreme, as the disc is only about 5 cm. in diameter; it is easy to hold it, for example, in the right hand, and we can in that way test the power of abduction or simply turn the disc around so that the central portion comes to the nose. We test in that way the adduction and abduction, or, by holding the handle horizontally, we can test the superduction or subduction.

This arrangement of the prisms has a slight addition which also seems to be of some value. It consists in placing on the handle a small pendulum which may swing through an arc of about 10 degrees. Therefore, when in testing the adduction, for example, if we hold the disc by its handle in

the right hand, and the pendulum points to the zero mark, we know that the prism before the eye is just horizontal.

This arrangement is useful for the horizontal muscles, because with them we often need to use strong prisms, and a slight malposition of the prism may make a difference in the result. It is not so essential for the vertical muscles, however, for we seldom use strong prisms in testing them, and the corresponding error of malposition is, therefore, very slight.

The whole arrangement with the pendulum mentioned is so small that it can be easily placed in a vest-pocket or kept in the trial-case when not in use.

STANDARDIZING OF TEST-TYPES AND RECORDS OF VISUAL ACUITY.

EDWARD JACKSON, M.D.,
Denver, Col.

At the Eleventh International Ophthalmological Congress, held at Naples last year, the report of the committee appointed at the preceding congress at Lucerne, of which committee Dr. Hess was chairman, recommended as the standard of visual acuity the broken ring advocated by Landolt, large enough for the whole ring to subtend an angle of five minutes, for the break in it to subtend an angle of one minute. They also recommended that five meters be the standard distance at which visual acuteness be tested; and that the visual acuity be recorded in decimal fractions—tenths. These recommendations were adopted by the congress, receiving the support of a large majority of those present. It is extremely desirable that this international standard for visual acuity be generally employed by writers in reporting cases and in estimating visual acuity in daily practice.

Its adoption is not merely the choice of a new and better standard, it is the first adoption of any real and definite standard. The recording of visual acuity merely by the test-letters seen is very indefinite. Dennett showed (see Trans. Amer. Ophth. Soc., 1885) that for block letters to be equally visible some must be twice as large as others; and a standard that varies by 50 per cent. has little claim to definiteness or scientific value.

To adopt the international standard it is not necessary to throw aside the test-cards we have used, and to do our testing with the broken ring. It is only needful to compare

the visibility of the test-letters we are accustomed to using with that of the broken ring; and then to number our lines of test-letters in conformity with the international standard. To facilitate this I have had prepared a series of the broken rings, which are marked with the visual acuity they indicate when the direction of the break in the ring can be just detected at five meters. This chart can be placed with the test-card in a good light, and any one with corrected astigmia



Plate A.—Visual acuity at five meters.

can compare the visibility of each test-letter with that of the broken rings.

For instance, comparing the test-card of Dr. John Green, indorsed by a committee and published with the Transactions of this society in 1905, with the international standard test, it will be found: At five meters the 5.04 or xv line on Dr. Green's test-card requires, to recognize three letters, visual acuity of about 0.7; to recognize half the letters,

vision equal 0.8; to recognize all but two or three letters, vision equal 0.9; to certainly recognize all the letters, vision equal 1. On the 6.35 or XIX line the recognition of three letters means vision equal 0.5; eight letters, 0.6; and all the letters, 0.7 vision. With the 4. or XII line placed at five meters, three letters can be recognized if vision



Plate B.—Visual acuity at six meters.

equal 0.9; half the letters, with vision equal 1, and all the letters, with vision equal 1.25.

For sight-testing in general it is advisable that the standard distance of five meters be adopted, but, as six meters (20 feet) has been very generally employed heretofore, and as some find it convenient to have a range of more than four meters, sets of the broken rings are appended for com-

parison with the test-type at these distances. In each of these sets the small figures below each broken ring indicate



Plate C.—Visual acuity at four meters.

the acuteness of vision according to the international standard required to recognize the ring at the given distance.

COLORED TORIC GLASS FOR USE IN EXAMINING CASES OF OCULAR PARALYSIS.

W. GORDON M. BYERS, M.D.,
Montreal, Can.

While small appliances like that which I have to describe are in themselves unimportant, their wide-spread use and their use for a long period mean in the aggregate a great saving of time; and anything that helps to smooth the difficulties of medical practice is undoubtedly worth while.

In making a differential diagnosis of ocular paralysis it is customary to place a red glass before one of the patient's eyes, first, to enable him more easily to locate the two

objects, and, secondly, to overcome any tendency to binocular vision that may remain. But the use of the colored glass, as ordinarily taken from the test-case, is often the cause of slight but real annoyance. In the lateral ocular movements the vision of the eye before which the glass is placed first strikes the rim of the lens, and then passes beyond it, out of the color field. This confuses the patient, and makes it difficult both for him and the examiner accurately to place the images.

About four years ago I tried to remedy this defect by making a glass double the size of that which is found in the test-case; but this only partially overcame the difficulty which I wish to correct. With the introduction of toric lenses it struck me that a colored glass of this sort might be of service in making examinations easier in the class of cases I have mentioned. The little apparatus was procured for me by Mr. R. N. Taylor, of Montreal, from a large company in England, as the leading optical concerns in the United States were unable to make it. It is simply a large, perfectly ground, toric lens, of a rich red color, properly rimmed, and supplied with a convenient handle; but the wider color field which the curved glass affords does away almost entirely with the difficulties previously experienced in examining cases of ocular paralysis.

R.M.A.

TRANSACTIONS

of the

American Ophthalmological Society

Forty-Seventh Annual Meeting

NEW LONDON, CONN., 1911

VOL. XII, PART III

Philadelphia
American Ophthalmological Society
1911

BOSTON MEDICAL
JUN 27 1912
LIBRARY.

CATALOGUED
JUN 27 1912
J. F B.

PRESS OF WM. F. FELL CO.
PHILADELPHIA

TABLE OF CONTENTS.

	PAGE
List of Officers and Members	681
Necrology	687
Minutes of the Proceedings	708
The Field of Vision in Tabetic Atrophy of the Optic Disc: Professor E. Fuchs	718
A Report of Four Cases of Acute Disseminated Myelitis with Retrobulbar Degeneration of the Optic Nerves: Dr. Ward A. Holden	728
Episcleritis Periodica Fugax: Dr. Albert C. Snell	736
Dystrophia Epithelialis Corneæ (Fuchs), with the Report of a Case: Dr. Arnold Knapp	745
The Use of Serum in Sympathetic Ophthalmia: Drs. George S. Derby and Horatio N. Pratt (by invitation)	748
A Case of Gonorrheal Conjunctivitis with Arthritis Preceding Conjunctival Discharge by Four Days: Dr. M. H. Post	759
A Protest Against the Indiscriminate Use of the Organic Compounds of Silver in Ophthalmic Practice: Dr. Samuel Theobald	763
The Operation of Excision of Tarsus and Conjunctiva (Heisrath) in Old Trachoma, Together with Demonstration of a New Instrument, and a Description of a New Method of Performing It: Dr. J. Herbert Claiborne	767
A Case of Ring Sarcoma of the Ciliary Body: Drs. A. N. Alling and Arnold Knapp	778
Neuroma of the Ciliary Nerves: Professor E. Fuchs	786
Smallest Sarcoma of the Choroid: Professor E. Fuchs	787
The Pathology of Superficial Punctate Keratitis, with Remarks on Neuropathic Keratitis in General, and on a Hitherto Undescribed Lesion of the Iris: Dr. F. H. Verhoeff	791
Some Questions Concerning the Method of Development and the Pathology of the Retinitis of Bright's Disease: Dr. N. M. Semple	817
Probable Cyst of the Retina, with a Demonstration of the Patient: Dr. George S. Derby	827
Report of Two Cases of Pulsating Exophthalmos. Relief of one by Ligation of the Common Carotid; Relief of the Other by Ligation of the Common Carotid, Followed after Recurrence by Ligation of the Internal Carotid: Dr. William H. Wilder	832
Concerning Certain Tumors of the Orbit, and Certain Conditions Simulating Neoplasms of the Orbit, Being a Clinico-pathologic Contribution, with the Report of Six Cases: Dr. G. E. de Schweinitz	842

PAGE

Subsequent History of a Case of Exostosis of the Orbit Reported to the Society in 1897: Dr. William M. Sweet 879

Phantom Intraocular Tumor: Dr. Arnold Knapp 883

The Position of the Eye the Element of Safety in the East Indian Extraction in Capsule: Dr. Myles Standish 885

Intracapsular Extraction of the Cataractous Lens: Dr. Robert Sattler . . . 889

The Iris in the Intracapsular Operation for Cataract: Dr. Andrew Timberman 906

Cataract Extraction with the Least Trauma; Excellent Visual Results: Dr. Arthur E. Ewing 914

The Mechanics of Choked Disc: Dr. Myles Standish 936

The Relation of Choked Disc to Intraocular Tension: A Clinical Study of Six Cases: Dr. Walter R. Parker 940

Intestinal Sepsis as an Etiologic Factor in Cardiovascular Disease and Associated Ocular Affections: Dr. S. D. Risley 950

Cilioretinal and Other Anomalous Retinal Vessels: Dr. Edward Jackson 960

Exhibition of a Bjerrum Stick: Dr. T. B. Holloway 966

A Double Coloboma (Nasal and Temporal) of the Optic Nerve and Sheath: Exhibition of Drawing: Dr. B. Alex. Randall 968

Retinitis Pigmentosa Associated with Albuminuric Neuroretinitis: Dr. T. B. Holloway 972

Embolism of the Right Central Retinal Artery in a Boy Aged Eight Years: Dr. E. Gruening 978

Congenital Deviations of the Eyes: Dr. Alexander Duane 981

Note on the Heredity of Corneal Astigmatism and of Muscular Anomalies: Dr. Lucien Howe 1001

APPENDIX

Report of the Committee on Ophthalmia Neonatorum 1005

INDEX TO AUTHORS, VOL. XII 1013

INDEX TO SUBJECTS, VOL. XII 1019

American Ophthalmological Society.

FOUNDED 1864.

OFFICERS.

1911—1912.

President,	Dr. Edward Jackson,	Denver, Col.
Vice-President,	Dr. Myles Standish,	Boston, Mass.
Secretary-Treasurer,	Dr. Wm. M. Sweet,	Philadelphia, Pa.
Corresponding Secretary,	Dr. A. Knapp,	New York, N. Y.

MEMBERS.

* Associate Members. O. M. Original Members.

Elected.	Name.	Residence.	Place.
1896	Dr. A. E. Adams,	44 Grand Street,	Newburg, N. Y.
1902	Dr. J. L. Adams,	38 East 51st Street,	New York, N. Y.
1899	Dr. A. N. Alling,	257 Church Street,	New Haven, Conn.
1896	Dr. G. W. Allyn,	Empire Building,	Pittsburg, Pa.
1882	Dr. A. Alt,	Metropolitan Bldg.,	St. Louis, Mo.
1883	Dr. J. A. Andrews,	1229 State Street,	Santa Barbara, Cal.
1881	Dr. S. C. Ayres,	4 West 7th Street,	Cincinnati, Ohio.
1907	*Dr. C. H. Beard,	15 E. Washington Street,	Chicago, Ill.
1911	*Dr. Arthur J. Bedell,	354 State Street,	Albany, N. Y.
1908	Dr. Geo. H. Bell,	12 West 46th Street,	New York, N. Y.
1905	*Dr. Jas. H. Bell,	Moore Building,	San Antonio, Texas.
1909	*Dr. James Bordley, Jr.,	330 N. Charles Street,	Baltimore, Md.
1881	Dr. H. W. Bradford,		Wolfboro, N. H.
1908	*Dr. E. V. L. Brown,	122 S. Michigan Blvd.,	Chicago, Ill.
1903	*Dr. Gustave E. Bruère,	Electric Building,	Portland, Oregon.
1907	*Dr. Wm. E. Bruner,	New England Bldg.,	Cleveland, Ohio.
1901	Dr. H. D. Bruns,	211 Camp Street,	New Orleans, La.
1910	*Dr. E. U. Buckman,	70 S. Franklin Street,	Wilkesbarre, Pa.
1906	Dr. W. K. Butler,	1207 M Street, N. W.,	Washington, D. C.
1906	Dr. W. Gordon M. Byers,	346 Mountain Street,	Montreal, Canada.
1909	*Dr. L. W. Callan,	452 Fifth Avenue,	New York, N. Y.
1876	Dr. Peter A. Callan,	452 Fifth Avenue,	New York, N. Y.
1885	Dr. F. P. Capron,	118 Angell Street,	Providence, R. I.
O.M.	Dr. W. H. Carmalt,	87 Elm Street,	New Haven, Conn.

Elected.	Name.	Residence.	Place.
1898	Dr. J. T. Carpenter, Jr.,	2040 Chestnut Street,	Philadelphia, Pa.
1911	*Dr. James J. Carroll,	330 N. Charles Street,	Baltimore, Md.
1904	Dr. Burton Chance,	235 So. 13th Street,	Philadelphia, Pa.
1893	Dr. H. B. Chandler,	34½ Beacon Street,	Boston, Mass.
1904	Dr. J. W. Charles,	509 Humboldt Bldg.,	St. Louis, Mo.
1893	Dr. Wm. Cheatham,	303 W. Chestnut Street,	Louisville, Ky.
1893	Dr. F. E. Cheney,	126 Commonw'th Ave.,	Boston, Mass.
1898	Dr. J. H. Claiborne,	11 East 48th Street,	New York, N. Y.
1891	Dr. C. F. Clark,	188 East State Street,	Columbus, Ohio.
1875	Dr. David Coggin,	7 Chestnut Street,	Salem, Mass.
1903	Dr. Wm. G. Craig,	15 Fuller Building,	Springfield, Mass.
1890	Dr. C. M. Culver,	36 Eagle Street,	Albany, N. Y.
1906	Dr. R. J. Curdy,	1134 Rialto Building,	Kansas City, Mo.
1902	Dr. Colman W. Cutler,	8 East 54th Street,	New York, N. Y.
1908	*Dr. Jno. P. Davidson,	316 E. Franklin Street,	Richmond, Va.
1907	*Dr. A. E. Davis,	50 West 37th Street,	New York, N. Y.
1878	Dr. W. S. Dennett,	8 East 49th Street,	New York, N. Y.
1909	*Dr. George S. Derby,	7 Hereford Street,	Boston, Mass.
O.M.	Dr. Hasket Derby,	Back Bay P. O.,	Boston, Mass.
1874	Dr. Lewis S. Dixon,	232 Clarendon Street,	Boston, Mass.
1902	Dr. Alexander Duane,	139 E. 37th Street,	New York, N. Y.
1908	*Dr. J. L. Duncan,	Jenkins Bldg.,	Pittsburg, Pa.
1887	Dr. J. B. Emerson,	40 East 41st Street,	New York, N. Y.
1890	Dr. Arthur E. Ewing,	Metropolitan Bldg.,	St. Louis, Mo.
1896	Dr. T. H. Fenton,	1319 Spruce Street,	Philadelphia, Pa.
1893	Dr. George F. Fiske,	32 N. State Street,	Chicago, Ill.
1909	*Dr. M. L. Foster,	211 Centre Avenue,	New Rochelle, N. Y.
1904	Dr. W. H. Fox,	1826 Jefferson Place,	Washington, D. C.
1902	Dr. Percy Fridenberg,	60 East 58th Street,	New York, N. Y.
1894	Dr. H. Friedenwald,	1029 Madison Ave.,	Baltimore, Md.
1895	Dr. G. M. Gould,	Sentinels, Cayuga Hts.,	Ithaca, N. Y.
1896	Dr. H. Y. Grant,	Falls View,	Ontario, Canada.
1908	*Dr. L. S. Greene,	1610 I Street, N. W.,	Washington, D. C.
1905	Dr. Allen Greenwood,	101 Newbury Street,	Boston, Mass.
1875	Dr. Emil Gruening,	36 East 57th Street,	New York, N. Y.
1903	*Dr. C. W. Haddock,		Beverly, Mass.
1892	Dr. G. W. Hale,	214 Wilcox Building,	Nashville, Tenn.
1895	Dr. Wm. D. Hall,	416 Marlborough Street,	Boston, Mass.
1887	Dr. H. F. Hansell,	1528 Walnut Street,	Philadelphia, Pa.
1901	Dr. Herbert Harlan,	516 Cathedral Street,	Baltimore, Md.
1889	Dr. David Harrower,	9 Elm Street,	Worcester, Mass.
1896	Dr. N. D. Harvey,	119 Waterman Street,	Providence, R. I.
1904	Dr. H. H. Haskell,	29 Commonwealth Ave.,	Boston, Mass.
1890	Dr. Neil J. Hepburn,	317 West 23d Street,	New York, N. Y.

Elected.	Name.	Residence.	Place.
1896	Dr. Ward Holden,	43 West 48th Street,	New York, N. Y.
1909	*Dr. T. B. Holloway,	1819 Chestnut Street,	Philadelphia, Pa.
1906	*Dr. C. R. Holmes,	8 East 8th Street,	Cincinnati, Ohio.
1883	Dr. E. E. Holt,	723 Congress Street,	Portland, Me.
1878	Dr. Lucien Howe,	87 West Huron Street,	Buffalo, N. Y.
1891	Dr. D. W. Hunter,	80 West 40th Street,	New York, N. Y.
1898	Dr. J. W. Ingalls,	874 Lafayette Avenue,	Brooklyn, N. Y.
1895	Dr. E. E. Jack,	215 Beacon Street,	Boston, Mass.
1885	Dr. Edward Jackson,	Metropolitan Building,	Denver, Col.
O.M.	Dr. B. Joy Jeffries,	15 Chestnut Street,	Boston, Mass.
1892	Dr. W. B. Johnson,	170 Broadway,	Paterson, N. J.
1908	*Dr. B. R. Kennon,	Taylor Building,	Norfolk, Va.
1901	Dr. H. W. Kilburn,	192 Marlborough Street,	Boston, Mass.
1903	Dr. Arnold Knapp,	10 East 54th Street,	New York, N. Y.
1889	Dr. Carl Koller,	681 Madison Avenue,	New York, N. Y.
1888	Dr. Chas. W. Kollock,	86 Wentworth Street,	Charleston, S. C.
1891	Dr. W. E. Lambert,	47 West 38th Street,	New York, N. Y.
1902	*Dr. W. B. Lancaster,		Amherst, Mass.
1903	*Dr. J. C. Lester,	616 Madison Avenue,	New York, N. Y.
1907	*Dr. George F. Libby,	530 Metropolitan Bldg.,	Denver, Col.
1883	Dr. J. A. Lippincott,	Jenkins Building,	Pittsburg, Pa.
1878	Dr. F. B. Loring,	1420 K Street,	Washington, D. C.
1909	*Dr. R. G. Loring,	2 Arlington Street,	Boston, Mass.
1899	Dr. D. B. Lovell,	32 Pearl Street,	Worcester, Mass.
1908	*Dr. J. B. Lynch,	148 West 22d Street,	New York, N. Y.
1891	Dr. F. W. Marlow,	731 University Block,	Syracuse, N. Y.
1878	Dr. W. V. Marmion,	1211 13th Street, N. W.,	Washington, D. C.
1896	Dr. W. B. Marple,	46 W. 53d Street,	New York, N. Y.
1868	Dr. Arthur Mathewson,	Cosmos Club,	Washington, D. C.
1905	Dr. S. C. Maxson,	225 Genesee Street,	Utica, N. Y.
1907	*Dr. C. H. May,	698 Madison Avenue,	New York, N. Y.
1887	Dr. Chas. H. McIlwaine,	703 6th Avenue,	Asbury Park, N. J.
1906	Dr. Jno. R. McIntosh,	40 Coburg Street,	St. John, N. B.
1874	Dr. C. S. Merrill,	27 S. Hawk Street	Albany, N. Y.
1908	*Dr. H. S. Miles,	417 State Street,	Bridgeport, Conn.
1888	Dr. B. L. Millikin,	1110 Euclid Avenue,	Cleveland, Ohio.
1883	Dr. J. Lancelot Minor,	Randolph Building,	Memphis, Tenn.
1881	Dr. W. F. Mittendorf,	140 Madison Avenue,	New York, N. Y.
1887	Dr. H. S. Oppenheimer,	11 East 43d Street,	New York, N. Y.
1910	*Dr. Frank J. Parker,	40 E. 41st Street,	New York, N. Y.
1908	*Dr. W. R. Parker,	Ch'mb'r of Commerce,	Detroit, Mich.
1908	Dr. S. McA. Payne,	542 Fifth Avenue,	New York, N. Y.
1895	Dr. R. J. Phillips,	123 So. 39th Street,	Philadelphia, Pa.
1869	Dr. Thomas R. Pooley,	26 Trinity Street,	Newton, N. J.

Elected.	Name.	Residence.	Place.
1898	Dr. W. Campbell Posey,	2049 Chestnut Street,	Philadelphia, Pa.
1887	Dr. M. H. Post,	Metropolitan Bldg.,	St. Louis, Mo.
1895	Dr. H. R. Price,	435 Clinton Avenue,	Brooklyn, N. Y.
1906	Dr. Brown Pusey,	7 West Madison Street,	Chicago, Ill.
1902	Dr. Walter L. Pyle,	1931 Chestnut Street,	Philadelphia, Pa.
1901	Dr. Alex. Quackenboss,	143 Newbury Street,	Boston, Mass.
1906	Dr. McCluney Radcliffe,	1812 Chestnut Street,	Philadelphia, Pa.
1885	Dr. Alex'r Randall,	1717 Locust Street,	Philadelphia, Pa.
1892	Dr. R. L. Randolph,	609 Park Avenue,	Baltimore, Md.
1891	Dr. J. M. Ray,	Atherton Bldg.,	Louisville, Ky.
1901	Dr. R. G. Reese,	147 W. 57th Street,	New York, N. Y.
1889	Dr. R. A. Reeve,	48 Bloor Street East,	Toronto, Canada.
1899	Dr. H. O. Reik,	506 Cathedral Street,	Baltimore, Md.
1884	Dr. Stephen O. Richey,	732 17th Street,	Washington, D. C.
1891	Dr. Wheelock Rider,	26 Gibbs Street,	Rochester, N. Y.
1901	Dr. G. O. Ring,	2014 Chestnut Street,	Philadelphia, Pa.
1895	Dr. H. W. Ring,	187 Church Street,	New Haven, Conn.
1908	*Dr. J. Norman Risley,	2018 Chestnut Street,	Philadelphia, Pa.
1880	Dr. Samuel D. Risley,	2018 Chestnut Street,	Philadelphia, Pa.
1887	Dr. Edmund C. Rivers,	1632 Welton Street,	Denver, Col.
1900	Dr. Wm. K. Rogers,	188 East State Street,	Columbus, Ohio.
1899	Dr. Dunbar Roy,	Gr. Opera House Blk.,	Atlanta, Ga.
1875	Dr. John D. Rushmore,	129 Montague Street,	Brooklyn, N. Y.
1880	Dr. Robert Sattler,	30, The Groton,	Cincinnati, Ohio.
1898	Dr. T. B. Schneideman,	1831 Chestnut Street,	Philadelphia, Pa.
1889	Dr. G. E. de Schweinitz,	1705 Walnut Street,	Philadelphia, Pa.
1895	Dr. P. N. K. Schwenk,	810 North 7th Street,	Philadelphia, Pa.
1909	*Dr. N. M. Semple,	Humboldt Building,	St. Louis, Mo.
1905	Dr. John R. Shannon,	25 W. 36th Street,	New York, N. Y.
1906	Dr. H. G. Sherman,	736 Rose Building,	Cleveland, Ohio.
1911	*Dr. J. F. Shoemaker,	1006 Carleton Bldg.,	St. Louis, Mo.
1902	Dr. Wm. A. Shoemaker,	1006 Carleton Bldg.,	St. Louis, Mo.
1902	Dr. Wm. T. Shoemaker,	109 South 20th Street,	Philadelphia, Pa.
1905	Dr. E. A. Shumway,	2007 Chestnut Street,	Philadelphia, Pa.
1896	Dr. F. D. Skeel,	147 West 57th Street,	New York, N. Y.
1910	*Dr. Albert C. Snell,	53 S. Fitzhugh St.,	Rochester, N. Y.
1909	*Dr. F. M. Spalding,	390 Commonw'lth Ave.,	Boston, Mass.
1878	Dr. J. A. Spalding,	627 Congress Street,	Portland, Me.
1911	*Dr. Chas. N. Spratt,	900 Nicollet Avenue,	Minneapolis, Minn.
1884	Dr. Myles Standish,	6 St. James Avenue,	Boston, Mass.
1873	Dr. George T. Stevens,	40 East 41st Street,	New York, N. Y.
1903	Dr. Edw. Stieren,	Westinghouse Bldg.,	Pittsburg, Pa.
1871	Dr. Geo. Strawbridge,	202 So. 15th Street,	Philadelphia, Pa.

Elected.	Name.	Residence.	Place.
1887	Dr. T. Y. Sutphen,	997 Broad Street,	Newark, N. J.
1900	Dr. Wm. M. Sweet,	1205 Spruce Street,	Philadelphia, Pa.
1888	Dr. Lewis H. Taylor,	83 So. Franklin Street,	Wilkes-Barre, Pa.
1880	Dr. Samuel Theobald,	Cathedral & How'd Sts.,	Baltimore, Md.
1893	Dr. Ch. Herman Thomas,	3634 Chestnut Street,	Philadelphia, Pa.
1898	Dr. A. G. Thomson,	1516 Locust Street,	Philadelphia, Pa.
1903	Dr. Edgar S. Thomson,	19 E. 44th Street,	New York, N. Y.
1898	Dr. Jas. Thorington,	120 So. 18th Street,	Philadelphia, Pa.
1908	*Dr. Andrew Timberman,	112 East Broad Street,	Columbus, Ohio.
1911	*Dr. Fred. T. Tooke,	368 Mountain Street,	Montreal, Canada.
1906	Dr. H. H. Tyson,	47 West 51st Street,	New York, N. Y.
1884	Dr. John Van Duyn,	318 James Street,	Syracuse, N. Y.
1898	Dr. C. A. Veasey,	Traders Bank Bldg.,	Spokane, Wash.
1905	Dr. F. H. Verhoeff,	95 Mountfort Street,	Boston, Mass.
1866	Dr. O. F. Wadsworth,	526 Beacon Street,	Boston, Mass.
1903	Dr. F. L. Waite,	68 Pratt Street,	Hartford, Conn.
1873	Dr. David Webster,	308 Madison Avenue,	New York, N. Y.
1893	Dr. J. E. Weeks,	46 East 57th Street,	New York, N. Y.
1900	*Dr. C. D. Westcott,	22 E. Washington Street,	Chicago, Ill.
1892	Dr. J. A. White,	200 E. Franklin Street,	Richmond, Va.
1895	Dr. W. H. Wilder,	1417 Peoples Gas Bldg.,	Chicago, Ill.
1910	*Dr. Carl Williams,	School L. & Greene St.,	Philadelphia, Pa.
1874	Dr. Chas. H. Williams,	1069 Boylston Street,	Boston, Mass.
1893	Dr. Wm. H. Wilmer,	1610 I Street, N. W.,	Washington, D. C.
1888	Dr. F. M. Wilson,	834 Myrtle Avenue,	Bridgeport, Conn.
1906	Dr. J. Scott Wood,	172 Sixth Avenue,	Brooklyn, N. Y.
1898	*Dr. William L. Wood,	412 Oregonian Bldg.,	Portland, Oregon.
1900	Dr. Hiram Woods,	842 Park Avenue,	Baltimore, Md.
1881	Dr. J. P. Worrell,	20 South 7th Street,	Terre Haute, Ind.
1905	Dr. Wm. Zentmayer,	1819 Spruce Street,	Philadelphia, Pa.
1903	Dr. S. Lewis Ziegler,	1625 Walnut Street,	Philadelphia, Pa.
	Total		186

HONORARY MEMBERS.

1866	Dr. Jno. Green,	Metropolitan Bldg.,	St. Louis, Mo.
1868	Dr. J. S. Prout,	Garden City,	Long Island, N. Y.
O.M.	Dr. F. P. Sprague,	229 Commonw'lth Ave.,	Boston, Mass.
	Whole number		189

Dr. Herman Knapp.

NECROLOGY.

DR. HERMAN KNAPP.

E. GRUENING, M.D.,
New York.

Dr. Herman Knapp died at Mamaroneck, near New York, on April 30, 1911, in his eightieth year. With him passes one of the last of the group of eminent men who stood at the cradle of modern ophthalmology. To his life applies Luther's version of the Psalmist: "Unser Leben währet siebenzig Jahre, und wenn es hoch kommt, so sind es achtzig Jahre, und wenn es köstlich gewesen ist, so ist es Mühe und Arbeit gewesen."

He had already achieved success in the old world as a scientific investigator, an author, a teacher, a physician, and a skilled and experienced operator, when he settled here and gave to America the benefits of his culture and learning.

He was born March 17, 1832, in Dauborn, Prussia. After the usual preliminary training in the humanities, he studied at the universities of Munich, Würzburg, Berlin, Leipzig, Zürich, and Giessen, taking the degree of Doctor of Medicine at the last-named university.

His student years fell in that memorable time in the history of ophthalmology when Helmholtz had invented the ophthalmoscope and von Graefe and others, with its aid, discovered a new world. Knapp became very much interested in the new science of ophthalmology, and made prolonged visits in Berlin, where Graefe had founded his clinic, in Utrecht, where Donders had begun to systematize the

anomalies of refraction and accommodation; in London, where Bowman and Critchett operated; as well as in Paris, where he studied at the Sorbonne and visited the clinic of Desmarres. In the laboratory of Helmholtz at Heidelberg he did his first scientific work in physiological optics. The friendship with Helmholtz, begun at this time, lasted until the latter's death.

Knapp's paper on the "Optical Constants of the Eye" was presented as his thesis for admission to the teaching faculty at Heidelberg in 1859. Horner, in his autobiography, mentions that, at the meeting of the Ophthalmological Society in Heidelberg in 1860, Donders and Knapp read papers on the anomalies of accommodation and refraction. In Donders' book, translated by Otto Becker, "Die Anomalien der Refraction und Accommodation des Auges," which appeared in 1866, Knapp is given full credit for his share in the development of this important branch of ophthalmology.

The numerous scientific contributions of Knapp in his Heidelberg period were published in von Graefe's "Archives." His paper on the asymmetry of the eye in its various meridional planes pointed out for the first time that meridional asymmetry of the eye constitutes a special class of refractive error.

His report on one hundred cataract extractions, according to von Graefe's method (Graefe's "Archives," vol. xiii), deals in detail with the method of operation, the operative accidents, the after-treatment, the course of healing, the influence of the nature of the cataract on the course of healing, and the visual results. A second hundred of cataract extractions, giving similar details, is contained in vol. xiv of Graefe's "Archives." The extraction of the cataractous lens in its capsule was also practised by Knapp at this period. His assistant, Dr. F. Bergmann, reports thirteen cases operated on by Knapp (Graefe's "Archives,"

vol. xiii, part 2). The results were not satisfactory. Knapp abandoned the method and remained averse to it.

In 1865 he was appointed Professor of Ophthalmology at the University of Heidelberg. He continued his scientific and literary work simultaneously with his university duties, and also conducted a clinic which he had himself founded. At this time he wrote his monograph on "Intra-ocular Tumors."

In 1867 he visited the United States, and was much impressed with the vast field for work which presented itself to him. A year later he resigned his Heidelberg professorship in order to settle permanently in New York. Here he founded a private clinic and hospital, which was later incorporated as the Ophthalmic and Aural Institute. It was modeled after von Graefe's Berlin clinic, to which prince and pauper equally were admitted and were given the benefit of hospital treatment. Forty years ago there were no institutions in New York in which the well-to-do could receive the advantages of organized care. To make his institution available for all classes of society, rich and poor, marked a signal advance.

Before leaving Heidelberg, Knapp devoted much time and study to otology, it being the practice in America, then more than nowadays, for one practitioner to unite both branches. Knapp approved of this dual practice, and in his prospectus of the "Archives of Ophthalmology and Otology," founded by him in 1869, and edited and published simultaneously in German and in English, he says: "The physiological connection between the organs of sight and hearing has at all times been deemed by eminent naturalists a good reason and a powerful incentive for extending their investigations over both the eye and ear."

Knapp came to America when still a young man, thirty-six years of age. He had a compelling and sustaining energy. His working capacity, then and always, was

unusual. His mornings were devoted to private practice, his afternoons to the clinic, where, with his staff of assistants, he examined, treated, and operated until five or six o'clock. The early evening was given to his family life, the later hours to literary labors, to editing of the "Archives," and to informing himself as to all that was new in medical literature. He was always a hard reader, and the extent of his information along the line of his specialties was unparalleled.

In a comparatively short time he had acquired a good command of English. In his speech he was terse and direct, emphasizing salient points without any attempt at rhetoric. When he wished to illustrate a particular point he would go straight to the blackboard, and, with few lines, give a clear idea of a pathological condition or an operative procedure.

As an operator, Knapp did brilliant work in the whole field of ophthalmic surgery. It was a rare treat to witness his operation for the extraction of cataract. In the first volume of his "Archives" he published his third hundred of cataract extractions; and this was followed by the several hundreds, and finally the thousand, of cataract extractions, with critical remarks in the various volumes of the "Archives." He advocated a peripheral division of the capsule, and mentions, among its manifold advantages—(1) simplification of the operative procedure; (2) lesser liability to injury by operative manipulation; (3) rapid healing of the linear wound in the capsule.

In later years he became an advocate of cataract extraction without iridectomy, and published a first, second, and third hundred of simple extractions. The results of his third hundred were: Perfect, 96%; moderate, 3%; failure, 1%; and he concludes the article by saying: "The simple operation is not only the best, but also the safest method of extracting cataract. *Facta loquuntur.*"

The peripheral division of the capsule, which he at first advocated, will probably always be employed, for the very

good reasons which he gave. His private practice grew to extraordinary dimensions, and people came from all parts of the country to be treated and operated by him.

In his otology he was much interested in physiological acoustics, and at one time gave a course of lectures on sensations of tone. In his clinical work he performed the operations of advanced aural surgery in a conservative spirit, and operated only when the indications were unmistakable.

Medical men, interested in the study of ophthalmology and otology, gathered around him at his Institute to see and to learn, some as observers merely, some as volunteer workers, and others as regular assistants. Of the men who either visited the institution or became connected with it during its first period we may mention Charles J. Kipp, Thomas R. Pooley, Joseph Aub, E. Gruening, Xenophon Scott, Charles S. Turnbull, Boerne Bettman, Robert Sattler, H. Gifford, Adolf Alt, A. Schapringer, R. Gebser, F. A. Munson, Thomas J. Dills, Edward Fridenberg, Cornelius Williams, and, in later years, Rudolf Born, F. E. D'Oench, Alexander Duane, Ward A. Holden, Charles H. May, John A. Weeks, Wilbur B. Marple and Arnold Knapp, amid a host of others. The prominence each of these men gained in his profession was due in no small degree to what he had imbibed in the atmosphere of the clinic. Knapp was a man of scrupulous intellectual honesty, and could not fail to impress his qualities of mind and heart on those who were closest to him. He was not a member of any club, and took no part in medical politics. He was a staunch friend.

In the forty years that Knapp was active in America he accomplished a vast amount of work in many fields. During all this time he was the executive surgeon of the institute he had founded, and kept up a large private practice. He was Professor of Ophthalmology in New York University from 1882 to 1888, and Professor of Ophthalmology in the College of Physicians and Surgeons of Co-

lumbia University from 1888 to 1902. He edited the "Archives of Ophthalmology and Otology"; and over one hundred and fifty articles contained in its pages came from his own pen, not to mention over fifty important contributions to medical literature published in the Transactions of the American Ophthalmological and Otological Societies. In 1898 he contributed the chapter on "Eye-Operations" in Norris and Oliver's "System of Diseases of the Eye." He frequently attended the meetings of medical societies, read papers, and took an active part in the discussion.

He was a member, and one time President, of the New York Pathological Society; one of the Vice-presidents of the Academy of Medicine; Chairman of the Section of Ophthalmology, and Chairman of the Section of Otology of the New York Academy; charter member of the New York Otological Society; member and one time President of the New York Ophthalmological Society; member of the American Ophthalmological and American Otological Societies; and member of numerous foreign medical societies.

Of the instruments which bear his name, the improved lid forceps, permitting bloodless operations on the lid; the needle-knife, used in discission of secondary cataract and division of the incarcerated capsule; and the roller-forceps for the cure of trachoma, will retain a lasting place in the outfit of the ophthalmic sugeon. He remarked, incidentally, that the idea of the roller-forceps was suggested to him on seeing the sugar-cane pressed out by the action of cylinders on a Cuban plantation.

In spite of his tremendous burden of work, Knapp never broke down; and, with the exception of a few attacks of bronchitis, his health always remained good. His principal exercise was walking. He was also fond of swimming. In his younger days he was a horseback rider, and often rode through Central Park after his hours at the clinic. In stature he was above middle height, well-proportioned,

and bore himself, even in age, with youthful elasticity. He had a florid complexion, which gave an impression of youth, even after his blond beard had changed to gray.

Knapp's recreations were few. Summer vacations were usually spent abroad, largely in observing the work of other men, and his notes on ophthalmology and otology, made during these journeys, testify to his continuous activity. He never traveled without taking notes. He himself says: "He who travels without taking notes overrates his powers of comprehension and memory, and does not know how to profit by one of the greatest opportunities for improvement." In a letter written from Paris, February, 1886, he says: "I spend a large part of my time in the laboratory and in Charcot's wards. He has an astounding material. Panas makes his clinic interesting, and has many cases." In 1897 he wrote to the Chairman of the Section of Ophthalmology and Otology of the New York Academy as follows: "I attended the Congress at Moscow, where there was much to interest me. If you desire to have a report on my impressions of the Ophthalmological and Otological Sections of the Congress for the Academy they are at your disposal."

As an editor, he would, on his own responsibility, correct erroneous and omit unscientific statements. This course sometimes gave rise to acrimonious correspondence, without, however, altering his ideal as to the necessity of maintaining the scientific standard of his publication.

Knapp's memory is cherished, not only as a worker in a scientific field, but as a man of high ideals and noble character. His modesty caused him to avoid all ovations and forms of public recognition. He had no desire for applause and outward regards, finding satisfaction in the work of his life. Even here he was his own sternest critic, and from first to last was constantly seeking to improve his methods.

His memory will live in the annals of medicine and in the hearts of his friends.

DR. CHARLES STEDMAN BULL.

WILLIAM H. CARMALT, M.D.,
New Haven, Conn.

To those of us who, for forty years, have attended with fair regularity the meetings of this society, the absence of the engaging personality of our late colleague comes with a keen sense of personal loss; those who have joined later, who knew him perhaps less intimately, must miss his scientific papers based upon an extensive experience and characterized by clear-cut expression and honest thought. One of the most diligent attendants, he enriched our proceedings by frequent contributions to the science and art of our calling, as the bibliography herewith appended shows.

Charles Stedman Bull was born in New York City on April 21, 1844, where he died on the 17th of the same month in 1911—just sixty-seven years of age. He was graduated B.A. from Columbia in 1864, M.A. in 1867, and was given his medical degree from the College of Physicians and Surgeons, the medical department of the same institution, in 1868. He served the two following years as interne in Bellevue Hospital, then went abroad, studied in Germany and France, and returned to New York to practise in 1871, taking up at first a general practice. The following year he went to St. Louis, but the conditions there were not to his liking and he returned to New York. While he did not at first specialize in practice, he showed where his inclinations were by joining this Society in 1871, and on his return from St. Louis took up work in the Manhattan Eye and Ear Hospital and the New York Eye and Ear Infirmary. He was also visiting surgeon to the ophthalmic service of the Charity Hospital, on Blackwells Island, from 1875 to 1880. He continued in general practice until 1881, when he gave up other than ophthalmology. His principal public

Dr. Charles Stedman Bull.

work was with the New York Eye and Ear Infirmary, in which he held successively the positions of Assistant Surgeon, Surgeon, Director, and Executive Surgeon of the Board of Directors. He was appointed consulting ophthalmic surgeon to St. Luke's, Presbyterian, and St. Mary's Free hospitals, which positions he held until his death. Besides his membership in this Society, of which he was President from 1903 to 1907, he was a member of the New York Ophthalmological Society, of the Practitioners Society, of the American Medical Association, of the New York State Medical Association, and of the New York Academy of Medicine, being corresponding secretary of the latter from 1903 to 1910. He was lecturer in the Bellevue Hospital Medical College for several years, and since 1898 professor of ophthalmology in the Cornell University Medical College.

He served in the Seventh Regiment, New York State National Guard, from 1864 to 1871, and was one of the detachment which stood guard over the body of President Lincoln on its journey to its resting place, in Springfield, Illinois. He was a member of the Society of Colonial Wars, of the Sons of the Revolution, of the Huguenot Society of America, and of the Century and University Clubs of New York.

Dr. Bull was a diligent student, and wrote well on many ophthalmological subjects; the bibliography shows that he took particular interest in tumor growths connected therewith.

His ideals were high, and he lived up to the best standards of professional ethics; a man of strong convictions, he did not obtrude them, but if occasion arose no one had doubt as to where he stood. Of a quick and ready wit, he was a genial companion, and one of the most charming of men in a social gathering.

He died of a ruptured aneurism of the common iliac artery, unsuspected until the autopsy.

PAPERS BY CHARLES STEDMAN BULL, M.D.

Transactions of the American Ophthalmological Society:

On the circulation of the optic nerve and retina in disease of the spinal cord and membranes dependent upon caries of the vertebræ, vol. ii, 1874.

Two cases of interesting syphilitic lesion of the eye, vol. ii, 1874.

Two cases illustrating rare diseases of the eyelids, vol. ii, 1878.

A case of syphilitic gumma of the conjunctiva, vol. ii, 1878.

Hyperostosis and periostosis of the bones of the orbit, vol. ii, 1879.

A contribution to the pathology and treatment of vascular tumors of the eyelids, vol. iii, 1880.

Treatment of scars of the face involving the eyelids directly or indirectly, vol. iii, 1881.

Pulsating vascular tumors of the orbit, eyelids, temple, and forehead treated with electrolysis, vol. iii, 1882.

Two cases of ophthalmoplegia externa, associated with disease of the optic nerves, from brain tumor, with an account of the post-mortem examinations, vol. iii, 1883.

Three cases of restoration of the eyelids by transplantation of a flap without a pedicle, vol. iii, 1884.

Two cases of unilateral temporal hemianopsia, vol. iv, 1885.

Abscess of both frontal sinuses and of ethmoid bone; operation and complete recovery, vol. iv, 1885.

An analysis of one hundred and three cases of exudative neuroretinitis associated with Bright's disease, vol. iv, 1886.

Report of thirty-six cases of simple extraction of cataract without iridectomy, vol. iv, 1887.

Passive motion in the treatment of paralysis of the ocular muscles, vol. iv, 1887.

A contribution to the surgical treatment of membranous opacities in the vitreous, vol. v, 1888.

Memorial notice of the late Dr. Edward G. Loring, vol. v, 1888.

A case of double choked disc due to intracranial tumor with autopsy, vol. v, 1889.

Contributions to the subject of tumors of the orbit and neighboring cavities, vol. v, 1889.

An analysis of ninety cases of simple chronic glaucoma, vol. v, 1889.

Extraction of lenses dislocated into the vitreous humor, vol. v, 1890.

Simple extraction of cataract without iridectomy, vol. v, 1890.

Tumor of brain, with autopsy, vol. vi, 1891.

Operative treatment of detachment of the retina by Schoeler's method, vol. vi, 1891.

A case of traumatic iridochoroiditis from contusion of the eyeball, ending in the development of intraocular glioma, vol. vi, 1892.

Contribution to the subject of intracranial lesions, with defects in the visual fields. Five cases with autopsies, vol. vi, 1892.

Gouty retinitis, chorioretinitis and neuroretinitis, vol. vi, 1893.

Recent experiences in the treatment of detached retina, vol. vii, 1894.

Preliminary report of six hundred and twelve cases of convergent squint with the final results of operation, vol. vii, 1895.

Course and prognosis of orbital tumors as influenced by surgical operation for their removal, vol. vii, 1896.

Tumors of the orbit, eyeballs, and vicinity, vol. viii, 1898.

Gunshot wounds of the eyeball, vol. viii, 1898.

Retinitis albuminurica as a factor in causation of secondary glaucoma vol. vii, 1899.

Three cases of vascular tumor of the orbit, vol. ix, 1900.
Metastatic choroiditis in pneumonia following grippe, vol. ix, 1901.
Post-operative history of fifty cases of glaucoma, vol. ix, 1902.
Sub-conjunctival injections of sublimate in orbital cellulitis, vol. ix, 1902.
Present status of sub-conjunctival injections in ophthalmic therapeutics, vol. x, 1903.
Pulsating exophthalmos of traumatic origin, ligation of common carotid artery, recovery, vol. x, 1903.
Operations upon the eyeball in the presence of an infected conjunctival sac, vol. x, 1904.
Choroidal disease in intestinal inflammation from ptomain poisoning, vol. x, 1905.
X-ray treatment in inoperable cases of malignant disease of the orbit, vol. x, 1905.
Post-operative history of sixty cases of simple chronic glaucoma, vol. xi, 1907.
Mixed streptococcus and pneumococcus infection of the orbit and adjacent sinuses, vol. xi, 1908.
Adverse influence of diabetes in operations on the eye, vol. xii, 1909.
The post-operative history of eighteen cases of magnetic foreign bodies removed from the eye by the Haab or giant magnet, vol. xii, 1910.

Medical Gazette:

On some affections of the conjunctiva, June, 1871.

Medical Record:

Sarcoma of conjunctiva, amyloid infiltration, and degeneration; Myxo-sarcoma of orbit; rapid growth, June, 1870.
Sarcoma of the orbit. Fibrosarcoma of the orbit with cystoid development. Intra-ocular and extra-ocular orbital sarcomata. Recurrent orbital tumor, 1880.
Intra-ocular and orbital sarcomata, 1881.
A consideration of some unusual forms of intra-ocular hemorrhage, with especial reference to etiology and prognosis, December, 1886.
The ocular complications of typhoid fever, 1887.
Some points in the symptomatology, pathology, and treatment of diseases of the sinuses adjacent to the orbit, June, 1899.
Significance of intra-ocular hemorrhage as to prognosis of life, Feb., 1900.
Three cases of vascular tumor of the orbit; two cured by operation, one apparently cured spontaneously, 1900.
Tuberculosis of the eye, its differential diagnosis, pathology, and treatment, December, 1900.
Lesions of the eye which occur in the course of diseases of the heart, blood vessels, and the kidneys, November, 1903.
Certain forms of ocular tuberculosis, December, 1905.
A case of supposed glioma of the eyeball, December, 1906.
Rare forms of choroiditis: one variety due to general malarial infection, and one to auto-intoxication from intestinal ptomains, May, 1907.
The deep intra-ocular lesions of infantile inherited syphilis and tardy inherited syphilis, April, 1908.
The prognosis and treatment of the deep lesions of the eye associated with gout, with especial reference to secondary acute glaucoma, December, 1908.
The increasing frequency of inherited syphilis and the grave importance of its early recognition in infants and young children from the standpoint of the ophthalmologist, January, 1911.
The systemic or constitutional character of gonorrhœa illustrated by five cases of iridochoroiditis, date undetermined.

New York Medical Journal:

Some forms of keratoiritis, September, 1874.

Observations on toxic amblyopia; course, prognosis, and treatment, September, 1875.
A contribution to syphilis of the eyelids, March, 1878.
The use of eserine and pilocarpine in ophthalmology, April, 1879.
Inflammation of the frontal sinuses, abscess and fistula, Nov., 1879.
Förster's operation for the rapid artificial ripening of cataract, with an analysis of thirty cases, May, 1884.
The hydrochlorate of cocaine as a local anesthetic in ophthalmic surgery, November, 1884.
The value of electrotherapeutics in lesions of the optic nerve, April, 1889.
Papillitis, or inflammation of the intra-ocular end of the optic nerve; its etiology and connection with intra-ocular disease, February, 1891.
Tumors of the orbit, December, 1891.
Tumors of the orbit and neighboring cavities, January, 1893.
The question of the efficacy of subconjunctival injections of mercuric bichloride in ocular therapeutics, January, 1895.
Adenosarcoma of the lachrymal gland. Malignant tumor of the anterior cerebral fossa and orbit. Sarcoma of the dura mater and orbit. Cystoid angioma of the orbit. Myxosarcoma of the ethmoid, sphenoid and orbit, November, 1895.
Ophthalmia neonatorum and its prophylaxis from the standpoint of the ophthalmologist, May, 1909.

American Journal of the Medical Sciences:

On the treatment of various forms of amblyopia, April, 1873.
Retinal hemorrhage and its connection with cerebral, cardiac, and renal lesions, July, 1874.
Lesions of the optic nerve and pupil in connection with certain affections of the spinal cord, with especial reference to Pott's disease, July, 1875.
Bromide of potassium in the treatment of amblyopia potatorum, July, 1875.
Observations on infiltration of the retina in lardaceous disease of the kidneys, October, 1879.
Certain traumatic lesions of the bones of the orbit with caries and perforation, July, 1880.
Some points in the pathology of the ocular lesions of cerebral and spinal syphilis, April, 1881.

Medical News:

Malignant growths, probably osteosarcoma of the orbital walls, involving all the bones of the face and base of the skull, but mainly the ethmoid and sphenoid; bilateral exophthalmos; growth in the nasopharynx and maxillary sinus, March, 1882.
Syphilis of the eye and its appendages, May, 1899.
The operative treatment of myopia of high degree by the removal of the crystalline lens, January, 1900.
The class of cases of simple chronic glaucoma in which operation is not advisable, January, 1902.

Journal American Medical Association:

Treatment of progressive atrophy of the optic nerve due to acquired syphilis by subconjunctival and intravaginal injections of sublimate of mercury, September, 1906.
The value of tuberculin, T. R., as a diagnostic and therapeutic agent in the recognition and treatment of diseases of the eye, August, 1907.
The management of acute hemorrhagic glaucoma in the presence of advanced arteriosclerosis, July, 1909.

Annals of Ophthalmology:

On the removal of foreign bodies from the eye, March, 1880.
Sarcoma of the choroid, ciliary body, and iris, June, 1881.
Some of the rare ocular lesions associated with gout or general lithemia, April, 1907.
Gonorrheal iridochoroiditis, 1893.
Purulent inflammation of the eyeball and orbital tissue and paralysis of the ocular muscles as a possible complication or sequel of typhoid fever, April, 1895.
Panophthalmitis; orbital cellulitis and diaphragmatic abscess. Autopsy, July, 1896.
Arteriosclerosis and its bearing upon certain lesions of the retina and optic nerve, January, 1904.

Kansas City Medical Journal:

Scleritis and episcleritis, August, 1873.
Retinitis albuminurica as distinguished from uræmic amaurosis, December, 1873.
The use of poultices in ophthalmic practice, April, 1874.

St. Louis Courier of Medicine:

Observations on three unusual cases of syphilitic gummata of the eye, August, 1879.
The effects of malarial poisoning upon the eye, June, 1880.

New York Journal of Medicine:

Purulent, croupous, membranous, and diphtheritic conjunctivitis in infants, July, 1881.
Syphilitic diseases of the lachrymal apparatus, April, 1882.

Miscellaneous:

Tumors of the orbit secondary or consecutive to tumors of the neighboring bony cavities, Transactions, New York State Medical Association, 1891.
Tumors of the orbit, a detailed account of nineteen cases, illustrating the paper presented to the Association in 1891, Transactions, New York State Medical Association, 1892.
A contribution to the pathology of orbital tumors; being a study of the secondary processes in the periosteum and bones of the orbit and vicinity, Transactions, Medical Society of New York, 1881.
The surgical treatment of fixed membranous opacities in the vitreous humor, Ophthalmic Review, June, 1890.
Forms of choroiditis resembling the well-known syphilitic type, British Medical Journal, 1906.
The connection between diseases of the eye and diseases of the teeth, International Dental Journal, March, 1896.
Lesions of the retinal vessels, retina and optic nerve associated with gout, Transactions of Congress of American Physicians and Surgeons, 1897.
The eye defects which may cause apparent mental dullness and deficiency in children, Pediatrics, 1902.
The increasing frequency of asthenopia, unidentified St. Louis journal, 1871.
Syphilitic iritis and its complications, journal unidentified.
Edited American edition of J. Solberg Wells on Diseases of the Eye, 1880 and 1883.
Article on Diseases of the Eye in Park's System of Surgery by American Authors.
Article on Diseases of the Orbit in Norris' and Oliver's System of Diseases of the Eye, 1898.

DR. CHARLES JOHN KIPP.

PETER A. CALLAN, M.D.,
New York.

Dr. Charles J. Kipp died of pneumonia at Newark, N. J., on January 13, 1911. He was born in Hanover, Germany, in October, 1835, and came to the United States in 1854, where he continued his academic studies and later began the study of medicine at the College of Physicians and Surgeons, N. Y., receiving his diploma in 1861. He was appointed Acting Assistant Surgeon in the United States Army in 1862, and Assistant Surgeon, U. S. V., in 1863, Major and Surgeon in 1864, Brev't Lieutenant Colonel and Surgeon, U. S. V., in 1865. He resigned in November, 1867.

In 1869 be began the practice of ophthalmology and otology in Newark, N. J. He organized an eye and ear clinic at St. Michael's Hospital, and some years later founded the Newark Eye and Ear infirmary. He became President of the Essex County Medical Society in 1880, and from 1885 to 1886 was President of the New York Ophthalmological Society. In 1886 he was President of the New Jersey Medical Society, and from 1901 to 1906 was President of the New Jersey State Tuberculosis Sanitorium.

He was President of the American Ophthalmological Society in 1907 and 1908, and President of the Otological Society and Vice-President of the American Medical Association the same years. He was a member of the Heidelberg Ophthalmological Congress and the New York Pathological Society. He was Chief Surgeon of the Newark Eye and Ear Infirmary and Consulting Surgeon to the German, St. Barnabas, Bayonne, Mountainside, and Somerset hospitals.

Dr. Kipp's contributions to ophthalmology were numerous and valuable. He was the first to recognize the frequent connection between optic neuritis and otitic throm-

Dr. Charles John Kipp.

bosis of the lateral sinus. He was the first to report in America a case of cysticercus in the ocular conjunctiva.

In the death of Dr. Charles J. Kipp our Society has sustained a great loss. He was an indefatigable worker and a close observer; his style was concise and lucid, presenting his facts in a convincing manner. He was esteemed and loved by all who knew him.

DR. CHARLES AUGUSTUS OLIVER.

S. LEWIS ZIEGLER, M.D.,
Philadelphia.

Dr. Charles Augustus Oliver died suddenly from an attack of acute pulmonary edema, at his late residence in Philadelphia, on April 8, 1911, in his fifty-eighth year. Although a brilliant student and a tireless worker, he nevertheless failed to recognize that his painstaking methods of studying and recording the minute details of the normal and pathologic fundus of every case that he examined were causing a mental and physical strain that would ultimately undermine his health. To this intense application we must, therefore, ascribe his final breakdown which culminated in the attack of nephritis and pulmonary edema to which he succumbed.

Dr. Oliver was born in Cincinnati, Ohio, on December 14, 1853. He was the son of the late Dr. George Powell Oliver, who was the founder and first president of the Medico-Chirurgical College of Philadelphia. He received his degree of Bachelor of Arts and the subsequent Master of Arts, in course, from the Central High School of Philadelphia. He also had conferred upon him the honorary degree of Master of Arts by Lafayette College. He was graduated in medicine from the University of Pennsylvania in 1876, and served one year as Resident Physician in the Philadelphia Hospital. During the following year be became con-

nected with the Wills Eye Hospital as Clinical Clerk, in the service of Dr. William F. Norris, who was then Professor of Ophthalmology at the University of Pennsylvania, His association with the Wills Eye Hospital was uninterrupted from that time until his death, having been elected Attending Surgeon to this institution, with its enormous clinical and teaching facilities, in 1890, and having served as Secretary to the Surgical Staff during the whole of that period.

He helped to establish a clinical service for diseases of the eye at St. Mary's, St. Agnes', and the Presbyterian Hospitals, and on retiring from active service in the two former institutions became Consulting Ophthalmic Surgeon. In 1894 he was appointed Ophthalmic Surgeon to the Philadelphia Hospital, which placed at his command the immense indoor operative service of that large institution. He was made Associate Clinical Professor of Ophthalmology in the Woman's Medical College in 1897, and became full Clinical Professor in 1906, a position which he filled with distinction until 1909. He was also Consulting Ophthalmologist to the Friends' Asylum for the Insane, and to the State Hospital for the Chronic Insane of Pennsylvania.

His knowledge of the literature of his specialty was most comprehensive, and his own contributions were both valuable and voluminous. One of the most important publications was a "Text-Book of Ophthalmology," written in collaboration with his teacher, Dr. William F. Norris, which enjoyed a full measure of popularity in this country and was later translated into Chinese by Neal of Chinanfu, and adopted as a text-book in the medical schools of China. His well-known monograph, entitled "A Description of Some of the Most Important Ophthalmic Methods Employed for the Recognition of Peripheral and Central Nerve Disease," was translated into French by Baudry of Lille, and into German by Wolff of Berlin.

His monumental editorial work consisted in the personal

Dr. Charles Augustus Oliver.

supervision of Norris and Oliver's "System of Diseases of the Eye," in four volumes, to which more than sixty American, British, Dutch, French, German, and Spanish authors made contributions. He also translated and edited the English editions of Ohlemann's "Ocular Therapeutics," Baudry's "Injuries to the Eye in Their Medico-Legal Aspect," and Donders' "Essay on the Nature and the Consequences of Anomalies of Refraction." More recently he contributed to Wood's "System of Ophthalmic Operations" a comprehensive chapter on "Paracentesis, Keratotomy, Conjunctivoplasty, and Some Other Operations on the Cornea."

He was editor, co-editor, and collaborator of many American and foreign publications. His monographs, magazine articles, reviews, and abstracts embrace several hundred subjects which lack of space will not permit to be enumerated. Some of the most important of these papers relate to color perception, color-blindness, and tests for the same: "The Comparative Action of Various Mydriatics on the Iris and Ciliary Muscle"; "A New Series of Test-Letters and Words for Determining the Visual Acuity and Range of Accommodation"; "A New Method for the Implantation of Glass Balls in Tenon's Capsule"; "A Single-stitch Operation for Advancement of the Exterior Ocular Muscles"; "Studies of the Sensory Changes and Conditions of the Ocular Apparatus found in Imbecility, Epilepsy, and General Paralysis of the Insane."

He was a member of many medical societies, including the College of Physicians of Philadelphia, the American Ophthalmological Society, the Wills Hospital Ophthalmic Society, the Pathological Society of Philadelphia, the Philadelphia Neurological Society, the Philadelphia County Medical Society, the Pennsylvania State Medical Society, and the American Medical Association. He was also a member of the American Philosophical Society, the American

Association for the Advancement of Science, the Military Order of the Loyal Legion of the United States, and the University Club of Philadelphia.

In addition to these he held active membership in many foreign societies, such as the Pan-American Medical Congress, of which he was an Honorary Vice-President, the International Medical Congress, the International Ophthalmological Congress, the Heidelberg Ophthalmologischen Gesellschaft, and the Societé Française d'Ophtalmologie.

During his extensive travels abroad he visited many of the most important eye clinics and hospitals throughout the world, and thus acquired a very large personal acquaintance among his foreign colleagues, who held him in high esteem. Much of the research work that he placed on record has been recognized as original and authoritative. His distinguished professional career has added luster to what has been termed "The Philadelphia School of Ophthalmology." His untimely death *in medias res* must be considered a distinct loss to ophthalmology, because of the elaborate work for which he had collected much data and which he was compelled to leave unfinished.

DR. FRANK NEWELL LEWIS.

EDGAR S. THOMSON, M.D.,
New York.

Dr. Frank Newell Lewis, the son of Dr. James Lewis and Abigaïl B. (Mason) Lewis, was born at Burlington, Vermont, October 7, 1857. He was educated at the University of Vermont, receiving the degree of A.B. in 1879, and the degrees of A.M. and M.D. in 1882. After his graduation he served as house surgeon in the Mary Fletcher Hospital in Burlington, and later as house surgeon in the Brooklyn Eye and Ear Hospital. After leaving the latter institution

Dr. Frank Newell Lewis.

he entered the service of the New York Eye and Ear Infirmary, where he served as house surgeon in 1885–86. On the completion of his term at the New York Eye and Ear Infirmary he went abroad and remained for a time at several of the foreign clinics.

He began practice in New York City in 1888, confining himself to diseases of the eye and ear. At this time he received an appointment on the clinical staff of the Manhattan Eye, Ear and Throat Hospital, in the clinic of Dr. D. B. St. John Roosa, where he passed through the various grades of clinical assistant, assistant surgeon, surgeon, and director. He served for a time as executive surgeon, and was active in the various forms of committee work connected with the service of the hospital.

He was for a time Professor of Diseases of the Eye in the New York Post-Graduate Medical School.

He became a member of the New York Ophthalmological Society in 1889 and served as its president. He was a member of the New York county and state societies, the New York Academy of Medicine, the American Medical Association, and the Alpha of Vermont Chapter of the Sigma Phi Fraternity. He became a member of the American Ophthalmological Society in 1898.

He was a regular contributor to medical literature, and was active in clinical and surgical work up to within a short period of his death.

On November 15, 1899, Dr. Lewis married Miss Mary Aymar Fowler, who survives him. He died on November 13, 1910.

His personal character was above reproach. Kind, considerate, courteous, and unselfish, with a strict sense of right and justice, and always mindful of the rights of others, he endeared himself to those who were fortunate enough to know him well, and earned the personal respect and confidence of all who came in contact with him.

DR. EDMUND W. STEVENS.

EDWARD JACKSON, M.D.,
Denver, Colorado.

Edmund W. Stevens was born at Woodstock, New Brunswick, in 1864. His determination to study medicine was carried out in spite of unusual obstacles, and he graduated from the Jefferson Medical College in 1884. Returning to New Brunswick, he entered upon the general practice of medicine. But, six years later, suffering with pulmonary disease, he returned to Philadelphia to escape the rigor of the more northern climate.

While serving as demonstrator of anatomy in the Pennsylvania College of Dental Surgery, he turned his attention to ophthalmology. His thorough work in the eye departments of the Philadelphia Polyclinic, the Jefferson Medical College, and the Wills Eye Hospital gave him an excellent mastery of practical ophthalmology, and made for him warm friends among his colleagues.

In 1898 his pulmonary disease completely disabled him, and he was sent to Colorado. After about a year of rest and recuperation he resumed ophthalmic practice in Denver, and continued his active professional work until within three days of his death, October 30, 1910.

Always handicapped by poor health, he yet accomplished as many days' work each year as most of his colleagues, and achieved a high place in the esteem of his neighbors in the medical profession. He served as President of the Medical Society of the City and County of Denver, was active in the Colorado State Medical Society, and was one of the charter members and active supporters of the Colorado Ophthalmological Society. In 1901 he was elected an associate member of the American Ophthalmological Society; but on account

of poor health was unable to attend its meetings so as to complete his membership.

His more important writings on ophthalmology are:

Section on the Use of the Ophthalmometer, in de Schweinitz's Diseases of the Eye.
Extirpation of the Lacrimal Sac for Dacryocystitis, Colorado Medicine, 1904, p. 261.
Fatal Septicemia Due to Ophthalmia Neonatorum, Ophthalmic Record, 1905, p. 519.
Retinal Hemorrhage in Apparently Healthy Eyes, Colorado Medicine, 1906, p. 176.
Emphysema of Orbit and Lids Following Removal of Middle Turbinate, Denver Medical Times, November, 1907, p. 157.
Indirect Injury to Optic Nerve, Colorado Medicine, 1908, p. 269.

Both in his writings and in his part in medical society discussion, Dr. Stevens exhibited accurate knowledge and a talent for clear, condensed statement. His sound judgment and conservatism made him a valued consultant. His character and life are well indicated by a member of this Society, who had been closely associated with him in clinical work, in the following words: "Modest in deportment, scholarly in attainments, and successful in results. It was a real satisfaction and an actual inspiration to labor with him."

MINUTES OF THE PROCEEDINGS.

FORTY-SEVENTH ANNUAL MEETING.

THE GRISWOLD,
New London, Conn., July 11, 1911.

The Forty-seventh Annual Meeting of the Society was called to order at 10 A. M. by President Dr. Emil Gruening. Dr. Gruening introduced Prof. E. Fuchs, of Vienna, the guest of the Society.

The following committees were announced:

On Membership for Next Year—Drs. M. H. POST, G. E. DE SCHWEINITZ, PETER A. CALLAN, HIRAM WOODS, and W. H. WILMER.

On Bulletin—Drs. G. E. DE SCHWEINITZ, W. C. POSEY, and WILLIAM M. SWEET.

Auditing Committee—Dr. E. A. SHUMWAY.

Publication Committee—Drs. W. S. DENNETT, D. W. HUNTER, and WILLIAM M. SWEET.

On Time and Place of Meeting—Drs. W. H. CARMALT, EDWARD JACKSON, and W. H. WILDER.

On Ophthalmia Neonatorum—Drs. LUCIEN HOWE, EDWARD JACKSON, and PETER A. CALLAN.

On Wood Alcohol Blindness—Drs. E. GRUENING, G. E. DE SCHWEINITZ, W. H. WILDER, and WM. H. WILMER.

The following papers were read and discussed:

1. "A report of four cases of acute disseminated myelitis, with retrobulbar degeneration of the optic nerves," Dr. Ward A. Holden.

2. "Episcleritis periodica fugax," Dr. Albert C. Snell.

3. "The use of serum in sympathetic ophthalmia," Drs. George S. Derby and (by invitation) H. N. Pratt.

Discussed by Drs. Randolph, Claiborne, and Derby.

4. "Dystrophia epithelialis corneæ (Fuchs). Report of a case," Dr. Arnold Knapp.

5. "A case of gonorrheal conjunctivitis with arthritis preceding conjunctival discharge by four days," Dr. M. H. Post.

Discussed by Drs. Randolph, Verhoeff, Greenwood, Holloway, Randall, and Post.

6. "A protest against the indiscriminate use of the organic compounds of silver in ophthalmic practice," Dr. Samuel Theobald.

Discussed by Drs. Howe, Duane, Johnson, and Theobald.

7. "The operation of excision of tarsus and conjunctiva (Heisrath) in old trachoma, together with demonstration of a new instrument, and a description of a new method for performing it," Dr. J. H. Claiborne.

Discussed by Drs. Hunter, Foster, and Claiborne.

8. "A case of ring sarcoma of the ciliary body," Drs. A. N. Alling and Arnold Knapp.

Discussed by Drs. Randolph, Fuchs, and Verhoeff.

9. "Exhibition of specimens. (*a*) Smallest sarcoma of the choroid. (*b*) Neuroma of the ciliary nerves," Prof. E. Fuchs.

Discussed by Drs. de Schweinitz and Fuchs.

10. "A probable cyst of the retina. With demonstration of the patient," Dr. George S. Derby.

11. "Report of two cases of pulsating exophthalmos. Relief of one by ligation of the common carotid; relief of the other by ligation of the common carotid, followed after recurrence by ligation of the internal carotid," Dr. William H. Wilder.

Discussed by Drs. Risley, Fisher, Gruening, Wilder, and de Schweinitz.

The President announced that the following were invited to sit with the Society and take part in its discussions:

Drs. M. Feingold, Carl Fisher, C. W. Stevens, John H. Ohly, D. P. A. Jacoby, E. W. Clap.

AFTERNOON SESSION.

12. "Concerning certain tumors of the orbit, and certain conditions simulating neoplasms of the orbit, being a clinico-pathological contribution, with a report of six cases," Dr. G. E. de Schweinitz.

Discussed by Drs. Johnson, Libby, Jackson, Shumway, and de Schweinitz.

13. "Subsequent history of a case of exostosis of the orbit reported to the Society in 1897," Dr. William M. Sweet.

14. "Phantom intraocular tumor," Dr. Arnold Knapp.

Discussed by Dr. Fuchs.

15. "The position of the eye the element of safety in the East Indian extraction in capsule," Dr. Myles Standish.

16. "Intracapsular extraction of the cataractous lens," Dr. Robert Sattler.

17. "The iris in the intracapsular operation for cataract," Dr. Andrew Timberman.

18. "Cataract extraction with the least trauma. Excellent visual results," Dr. A. E. Ewing.

Discussed by Drs. Standish, Wilson, Gruening, Timberman, G. O. Ring, H. W. Ring, Randall, Post, Sattler, Ewing, and Randolph.

EVENING SESSION.

19. "The field of vision in tabetic atrophy of the optic disc. With lantern demonstration," Prof. E. Fuchs.

Discussed by Drs. de Schweinitz, Jackson, Howe, and Fuchs.

20. "The pathology of superficial punctate keratitis, with remarks on neuropathic keratitis in general, and on a hitherto undescribed lesion of the iris. With lantern demonstration," Dr. F. H. Verhoeff.

21. "Some questions concerning the method of develop-

ment and the pathology of the retinitis of Bright's disease. With lantern demonstration," Dr. N. M. Semple.

EXECUTIVE SESSION.

The President, Dr. E. Gruening, called the meeting to order at 10 P. M.

The Treasurer's report was read, and the Auditing Committee, having certified to its correctness, it was accepted and placed on file.

It was voted that the assessment for the current year be ten dollars.

The report of the Committee on Ophthalmia Neonatorum was read by the Chairman, Dr. Howe, and is printed as an appendix.

It was moved and carried that the report be published in the Transactions, and that the Committee on Ophthalmia Neonatorum be continued.

The report of the Committee on Prevention of Blindness from Wood Alcohol was as follows:

The Committee interviewed Dr. Wiley, of the Bureau of Agriculture, who says that wherever the interstate laws in regard to methyl alcohol are violated the United States is prosecuting the offenders, and he adds that the great need now is to arouse the State officials to the point of getting strict State laws on the subject, and that we may count upon his coöperation and interest at all times.

Dr. Ernest J. Lederle, the Commissioner of the Department of Health of the City of New York, in answer to a letter written by your Committee, writes: "I have ordered a searching investigation made of the whole question, and am satisfied that before long I shall have information that will lead to the suppression of the use of wood alcohol in beverages."

Miss Carolyn C. Van Blarcom, Executive Secretary of the Committee of Blindness of the New York Association for the Blind, replies as follows: "I hope very much that you will let us know of cases of wood-alcohol poisoning which come under your observation, in order that they may be

farther studied and inxestigated, and I may say that, of course, we shall be most grateful for any suggestions or instructions from you as to points which you think might be well brought out in such investigations."

The report was received and the committee continued.

The Committee on Membership recommended the following candidates for admission to the Society, and they were declared duly elected as Associate Members:

Dr. Arthur J. Bedell, Albany, N. Y.

Dr. J. F. Shoemaker, St. Louis, Mo.

Dr. Charles N. Spratt, Minneapolis, Minn.

Dr. James J. Carroll, Baltimore, Md.

Dr. Fred. T. Tooke, Montreal, Canada.

The Committee also referred the names of a number of candidates to the Committee for 1912.

Dr. John R. Shannon, on a vote of the Society permitting him to do so, read a report made to the New York Ophthalmological Society by a committee appointed by it to consider measures with regard to optometrists.

No action was taken, the report having been read merely to show what was being done in this direction in New York.

The Executive Committee presented the following nominations of officers of the Society for the ensuing year:

President: Dr. Edward Jackson, Denver, Col.

Vice-President: Dr. Myles Standish, Boston, Mass.

Secretary and Treasurer: Dr. William M. Sweet, Philadelphia, Pa.

Corresponding Secretary: Dr. Arnold Knapp, New York, N. Y.

It was moved that the Secretary be authorized to cast a ballot for the election of the officers as nominated by the Committee, which motion was carried, and the officers were declared elected.

The Secretary read a letter from Dr. J. S. Prout, resigning his membership in the Society.

Dr. Carmalt moved that the resignation be accepted, and that Dr. Prout be transferred from the list of Active Members to that of Honorary Members. The motion was seconded and carried.

The Secretary reported the following deaths among the members of the Society during the past year:

Dr. Herman Knapp, New York.
Dr. Charles S. Bull, New York.
Dr. Charles J. Kipp, Newark, N. J.
Dr. E. W. Stevens, Denver, Col.
Dr. F. N. Lewis, New York.
Dr. Charles A. Oliver, Philadelphia.

The President appointed the following committee to prepare the obituary for each of the deceased members: Drs. E. Gruening, W. H. Carmalt, Peter A. Callan, Edward Jackson, E. S. Thomson, and S. Lewis Ziegler.

The Secretary read a communication from the Secretary of the Congress of American Physicians and Surgeons in reference to the selection of representation of the Society to the Executive Committee to arrange for the Congress of 1913. The Nominating Committee presented the name of Dr. E. Gruening as Delegate, and Dr. W. H. Wilder as Alternate on the Executive Committee of the Congress.

The Committee on Time and Place of Meeting recommended that the Society meet at Hot Springs, Virginia, on June 11 and 12, 1912.

Dr. Johnson inquired whether the time and place were not fixed by the By-Laws. The Secretary read Section III of the By-Laws, as follows:

"The determination of the time and place of each annual meeting shall be entrusted to a Standing Committee of three members to be appointed at each annual meeting, and in the case of the appointment of a Committee of similar character and powers by the American Otological Society, the two committees shall act together as a Committee of Conference

with a view to selecting such time and place of meeting as shall best subserve the convenience of members desirous of attending the meetings of both Societies."

Dr. Randall said that a committee had been appointed by the Otological Society to confer with a similar committee of this Society, and he would therefore move as an amendment that there be a conference held by the committee of this Society with the committee of the Otological Society; and that Hot Springs, Virginia, June 11 and 12, 1912, be the time and place of meeting, unless a different time and place were chosen by the two committees at this conference.

Dr. Johnson asked that the question on the amendment of Dr. Randall be put. It was voted on and carried.

Dr. Arthur E. Ewing moved that six additional copies of the card containing the smallest reading print of the set recommended several years ago by the committee appointed to consider cards for testing vision be added to the present set for sale by the Society, and that the expense for this be added to the present cost of the cards. He also moved that on one margin of these cards the old nomenclature of the type be placed, and on the other margin the new nomenclature.

It was moved and carried that a Committee be appointed to act. The President appointed on this Committee Drs. Ewing and Sweet.

The Executive Session then adjourned.

EXECUTIVE SESSION, WEDNESDAY MORNING, JULY 12TH.

The President called the meeting to order at 10 A. M.

Dr. Carmalt said that the Committee on Time and Place of Meeting felt embarrassed by reason of the mandatory clause in the By-Laws regarding the time and place of meeting and the conference with a similar committee of the American Otological Society. While they intended to act in accordance with the resolution passed the preceding

evening, providing that they should hold a conference with the committee of the other Society, they thought that in future it would be well to have that part of the By-Law stricken out. This would not prevent the holding of such a meeting, if it were desired, by the Otological Society. He moved, therefore, that the latter part of the third By-Law should be stricken out, beginning with the words: "and in the case of the appointment of a Committee of similar character and powers by the American Otological Society." This would make the By-Law read as follows: "The determination of the time and place of each annual meeting shall be entrusted to a Standing Committee of three members, to be appointed at each annual meeting."

It was moved, seconded, and carried that the motion be laid on the table until the next Executive Session.

The Executive Session then adjourned.

Exhibition of Instruments, etc.

Dr. T. B. Holloway exhibited a Bjerrum stick that he had devised.

The reading of papers was resumed.

23. "The mechanics of choked disc," Dr. Myles Standish.

24. "The relation of choked disc to intraocular tension," Dr. Walter R. Parker.

Discussed by Drs. Risley, Holloway, Randall, Brown, Gruening, Standish, and Parker.

25. "Intestinal sepsis as an etiologic factor in cardio-vascular disease and associated ocular affections," Dr. Samuel D. Risley.

26. "Cilio-retinal vessels," Dr. Edward Jackson.

Discussed by Dr. Randall.

27. "A double coloboma (nasal and temporal) of the optic nerve and sheath. Exhibition of drawing," Dr. B. Alex. Randall.

28. "Retinitis pigmentosa, with albuminuric neuroretinitis," Dr. T. B. Holloway.

29. "A case of embolism of the right central artery in a boy aged eight years," Dr. Emil Gruening.

Discussed by Drs. Duane, Gruening, and Rogers.

30. "Congenital deviations of the eyes," Dr. Alexander Duane.

Discussed by Drs. Theobald, Shumway, Duane, and Risley.

31. "Note on the heredity of corneal astigmatism and of muscular anomalies," Dr. Lucien Howe.

EXECUTIVE SESSION, JULY 12TH.—(*Continued.*)

The meeting was called to order by the President at 11.45 A. M.

Dr. Carmalt asked for action on the motion made by him at the previous Executive Session, that the last part of the third By-Law be stricken out. It was moved and seconded that the motion be adopted.

The motion to change the By-Law was then voted on and carried.

Dr. Jackson stated that the invitation to the Society to meet next year in Colorado had not come from all the Colorado members, but from those present at the meeting. He knew, however, that Dr. Edmund C. Rivers, of Denver, who was absent, would be glad to join the others in extending an invitation to the Society to meet in Colorado in 1912.

Dr. Johnson suggested that the Committee on Time and Place of Meeting consider Cape May, N. J. The New Hotel Cape May afforded good accommodations, and he felt sure that the management would be glad to have the meeting there at the time of year mentioned.

Dr. Gruening said that these suggestions could be referred to the committee, which had not yet made its report.

Adjourned.

Members present at the Forty-seventh Annual Meeting:

ALLING, A, N.
BELL, GEORGE H.
BELL, JAMES H.
BORDLEY, JAMES, JR.
BROWN, E. V. L.
CALLAN, LEWIS W.
CALLAN, PETER A.
CARMALT, W. H.
CARPENTER, JOHN T.
CHANDLER, HENRY B.
CHARLES, J. W.
CHENEY, FRED. E.
CLAIBORNE, J. H.
CRAIG, WM. G.
CURDY, R. J.
DERBY, GEORGE S.
DUANE, ALEXANDER
EWING, A. E.
FENTON, THOMAS H.
FOSTER, M. L.
FOX, WILLIAM H.
GREENWOOD, ALLEN
GRUENING, E.
HALE, GEORGE W.
HALL, WM. DUDLEY
HARLAN, HERBERT
HOLDEN, WARD A.
HOLLOWAY, T. B.
HOWE, LUCIEN
HUNTER, D. W.
INGALLS, JAMES W.
JACKSON, EDWARD
JOHNSON, WALTER B.
KILBURN, HENRY W.
KNAPP, ARNOLD
LIBBY, GEORGE F.
LORING, ROBERT G.
MARLOW, F. W.
MATHEWSON, ARTHUR
MCILWAINE, CHAS. H.
MILES, HENRY S.
MILLIKIN, B. L.
PARKER, FRANK J.
PARKER, WALTER R.
PAYNE, S. M.
PHILLIPS, R. J.
POST, M. H.
PUSEY, BROWN
QUACKENBOSS, ALEXANDER
RADCLIFFE, MCCLUNEY
RANDALL, B. ALEX.
RANDOLPH, R. L.
RING, G. ORAM
RING, HENRY W.
RISLEY, SAMUEL D.
ROGERS, W. K.
SATTLER, ROBERT
DE SCHWEINITZ, G. E.
SEMPLE, N. M.
SHANNON, JOHN R.
SHOEMAKER, WM. A.
SHOEMAKER, WM. T.
SHUMWAY, EDWARD A.
SNELL, ALBERT C.
SPALDING, FRED. M.
STANDISH, MYLES
SWEET, WM. M.
TAYLOR, LEWIS H.
THEOBALD, SAMUEL
THOMSON, ARCHIBALD G.
THOMSON, EDGAR S.
TIMBERMAN, ANDREW
TYSON, HENRY H.
VERHOEFF, F. H.
WILDER, WM. H.
WILLIAMS, CARL
WILMER, W. H.
WILSON, F. M.
WOOD, J. SCOTT

THE FIELD OF VISION IN TABETIC ATROPHY OF THE OPTIC DISC.

PROFESSOR E. FUCHS,

Vienna, Austria.

There are cases of tabetic atrophy in which the field of vision presents a central scotoma. Uhthoff estimates the frequency of these cases as about 2% of all cases of tabetic atrophy. According to my own experience, they are more common, as I could pick out not less than thirty from the histories of my private patients alone. My purpose in bringing these cases before you is to inquire into the nature of this particular sort of disturbance of the visual field. The common opinion is that in these cases the central scotoma is not a sequel of the tabes, but is to be considered as a complication, with a simultaneous syphilitic retrobulbar neuritis. I shall try to explain why I do not agree with this hypothesis.

The central scotoma in tabetic atrophy is nearly always bilateral. So it was in all my cases, and but a very few one-sided cases are on record. In the very beginning the scotoma is small, round, and actually central; at the same time the blind spot of Mariotte is found to be enlarged. Later on the scotoma extends its limits mainly to the temporal side, so as to join finally the blind spot and assume the shape of a horizontal ellipse. At first it is only the perception of colors, especially of red and green, which is abolished within the area of the scotoma. But if we examine carefully with small test objects and at the distance of 1 meter (3 feet) or more (Bjerrum's method), we do not fail to detect spots of absolute blindness within the color-blind area. The blind spot of Mariotte is, of course, one of these, but besides there may be

a small blind spot just in the center, or around it as a minute ring scotoma, which is rarely complete, but more often represented only by a blind arc concentric to the fixation point. Later on the scotoma not only becomes larger and larger, but also more and more absolute, all perception of light being abolished within its limits.

In the case represented by the diagram (Fig. 1) the central scotoma taken with the perimeter seemed to be an ordinary disc-shaped one. When the field was examined after Bjerrum's method, which was done for me by Dr. Gjessing, it

Fig. 1.

became manifest that in both eyes the blind spot was increased in size and was continued afterward into an absolute scotoma, forming one quadrant of a ring scotoma. Another smaller absolute scotoma existed adjacent to the fixation point, also representing only one half of a ring scotoma. Now, it is remarkable that these two incomplete ring scotomas were confined to the temporal half of the field, according to bitemporal hemiopia, a faint indication of which was also visible in the delimitation of the great relative scotoma in the right eye. Thence, although in this case

the periphery of the field exhibited but a simple concentric constriction, the central scotoma foreshadows bitemporal hemiopia, which, as I shall point out later, may also occur in consequence of tabes.

Together with the formation of the scotoma the periphery of the field becomes contracted. I have found a very slight concentric contraction, even in the earliest cases, in which the acuity of vision was still fairly good. The contraction is greater for the color field than for the field for white test-objects, and, at a period where the limits of the latter are

RIGHT

Fig. 2.

still tolerably wide, color perception may be entirely lost. Farther on, the contraction, as a rule, becomes irregular. The boundary of the field shows a slight indentation on one side, and narrows down here more and more, until it joins the central scotoma, usually pretty large in this advanced stage. Then the field has become eccentric and total blindness is spreading. If one eye is more advanced than the other, the first one, as a rule, presents a narrow and irregular field, while the field of the better eye is not only larger, but also more regular.

The acuity of vision in the different stages depends chiefly on the condition of the central scotoma. If this is dense, the vision will be bad, even with a good periphery of the field, and vice versâ. In most cases, of course, central scotoma and periphery of the field are more or less in harmony.

Central scotoma is most common in toxic amblyopia, mainly from poisoning by tobacco and alcohol. The contra-distinction from the tabetic cases is evident. In the toxic cases the periphery of the field always remains normal, and also the color perception outside of the scotoma. The

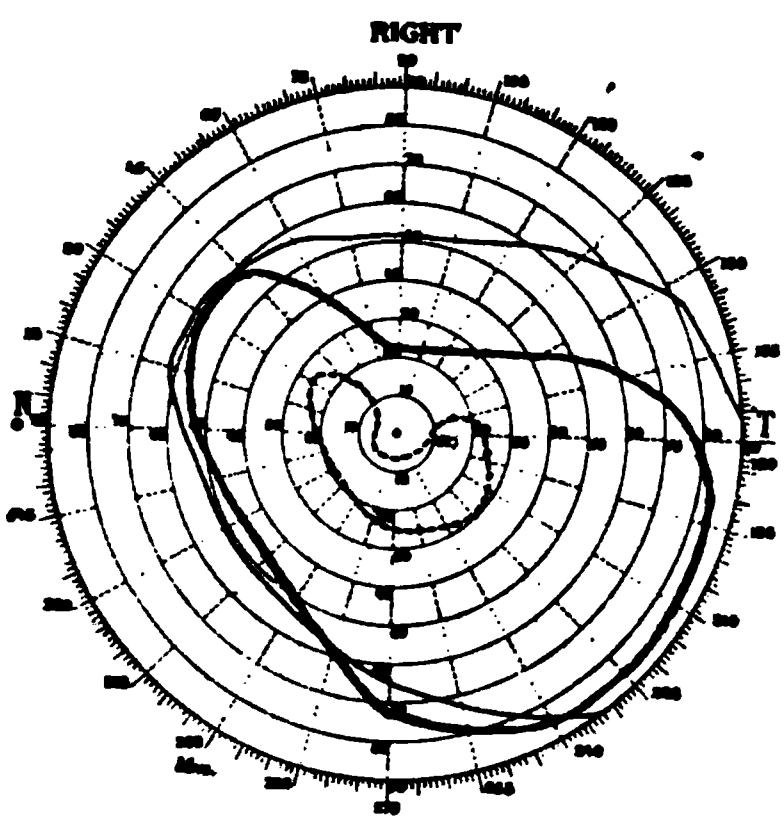

Fig. 3.

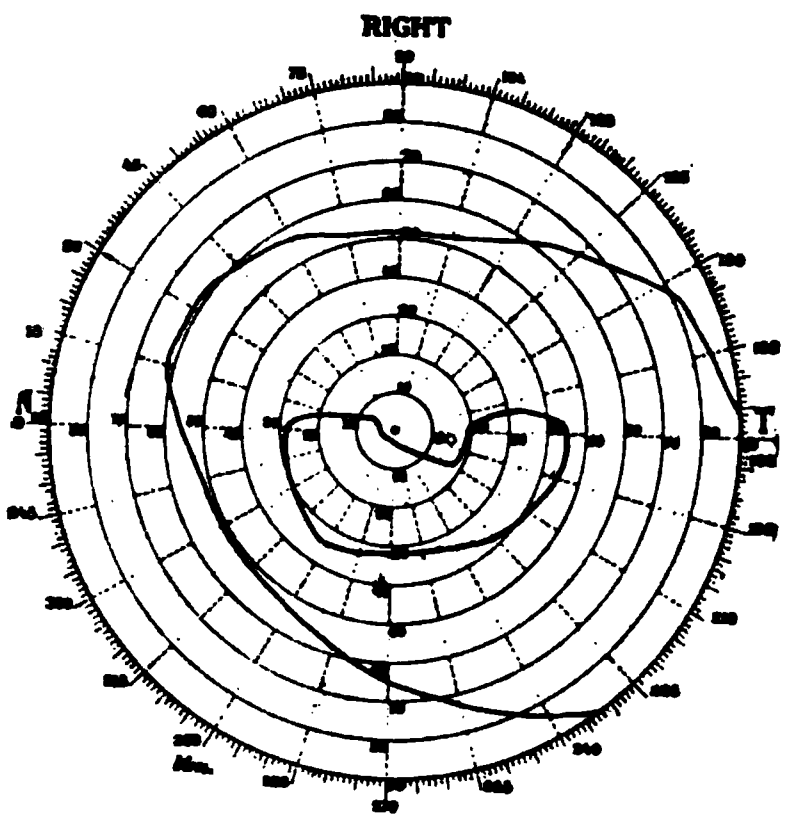

Fig. 4.

early loss of color perception within the whole field and its progressive contraction in general are indicative of the malignant character of the tabetic cases. The same results from the ophthalmoscopic changes. In toxic amblyopia the optic disc looks normal in the beginning, and only later on becomes pale in the temporal half. In the tabetic cases, on the contrary, the discs are pale from the very onset, and farther on the pallor spreads from the temporal to the nasal half.

It is more difficult to distinguish the tabetic cases of central scotoma from those due to syphilitic retrobulbar neuritis,

so much more as in the latter cases abolition of reflexes or Argyll-Robertson pupil may also be present in consequence of cerebral syphilis. I know of only two distinctive features which speak in favor of syphilitie neuritis. First of all, the good influence of appropriate treatment, which succeeds in stopping the decay of sight; in the second place, the pallor of the disc is likely to develop only at a later stage. Two such cases have been recorded by Wilbrand and by Eisenlohr. I have never myself seen a case which I could have attributed to syphilis alone; in all my cases there were the strongest evidences of tabes, and all these cases went blind in spite of treatment. I do not think of denying that cases of syphilitic retrobulbar neuritis do exist, but I affirm that in the great majority the central scotoma does not form an accidental complication, but an integral part of the tabetic processes. As regards the seat of the lesion, you know that there exist two hypotheses as to the primary localization of the tabetic atrophy in general. Some locate it in the ganglion layer of the retina, others in the optic nerve. The early enlargement of the blind spot and the tendency of the scotoma to proceed toward the blind spot and to join it plead in favor of the papillo-macular bundle of optic fibers. It is much more difficult to determine the nature of the lesion. The question whether tabetic changes are purely degenerative from the beginning, or if there intervenes some slight chronic form of inflammation, is still open. As to the cases of tabetic atrophy with scotoma, the ophthalmoscopic appearance is sometimes the same as in ordinary tabetic cases, and sometimes it is somewhat different. The nerve is pale, but instead of the cold blue tinge of simple atrophy it exhibits a yellowish color; the gray dots of the lamina are not exposed to view; the limits of the disc may not be perfectly sharp, and the retinal arteries are slightly contracted. Hence in these cases the disc may be said to present a somewhat post-neuritic appearance. In a similar case Boedecker

found at the post-mortem examination a slight interstitial inflammation involving the papillo-macular bundle. So in some cases the lesion of this bundle may be a pure degeneration, in others a slight inflammation.

Another exceptional type of alteration of the visual field in tabes is bitemporal hemiopia. These cases are very uncommon, and I have not met with more than six in my private practice. Bitemporal hemiopia is indicative of a lesion of the decussating fibers situated at the inferior side of the chiasma. It occurs in the case of a tumor pressing

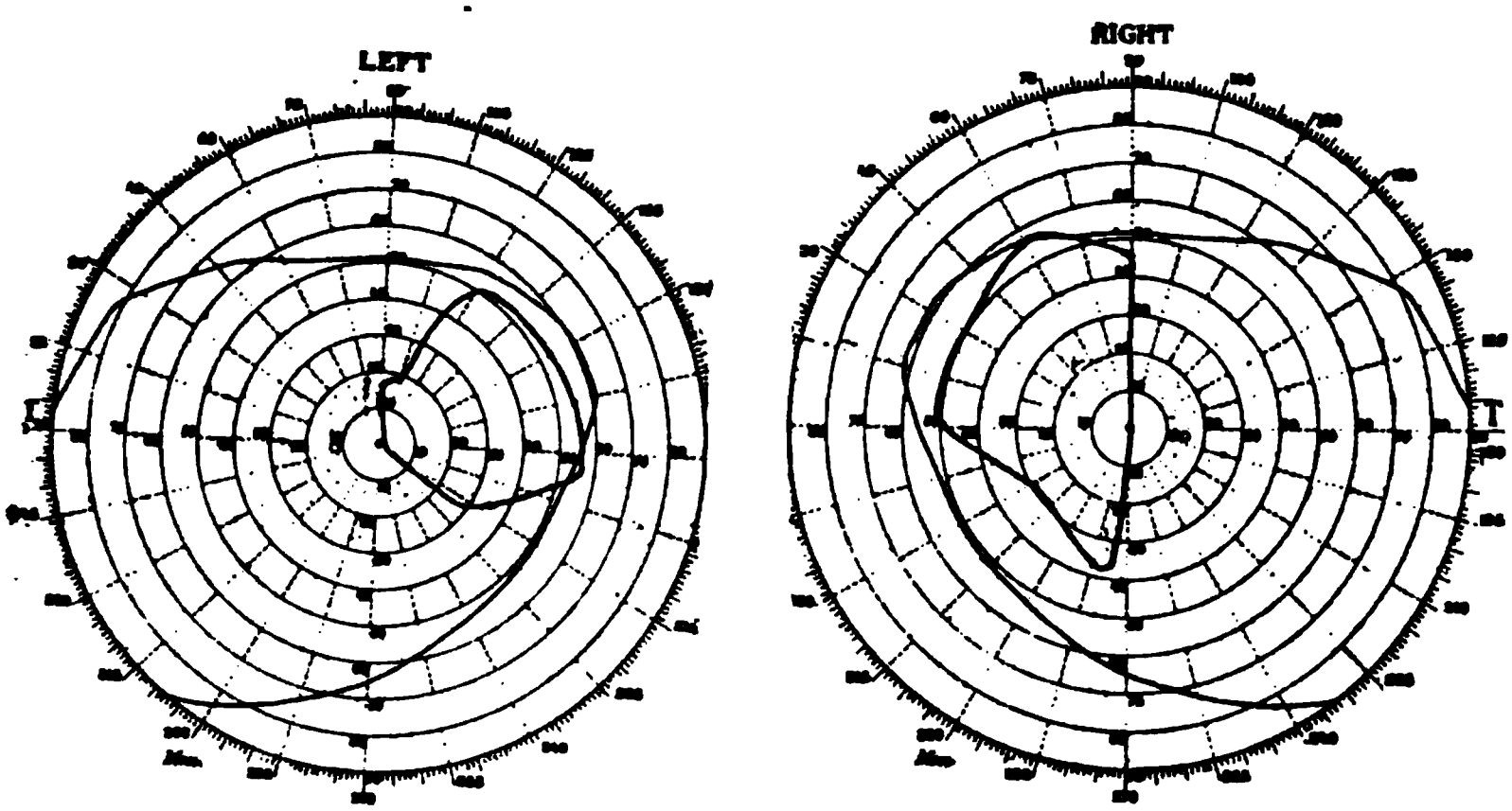

Fig. 5.

upon the inferior surface of the chiasma, as in tumors developing from the pituitary gland. It may also result from a local inflammation, mostly syphilitic, of the developing membranes of the brain at the same place. Such an inflammation has also been supposed to cause the bitemporal hemiopia in tabes. Without doubt this may be so in exceptional cases. I have myself observed a man, presenting every evidence of tabes, who rapidly developed a bitemporal hemiopia. When I saw him first, the sight of the right eye was nearly lost. The left eye had retained good central

vision, but the field of vision contracted rapidly, so that very soon only the nasal half of the field was left with nearly normal limits for white and colors. The optic discs then presented a normal appearance. An energetic treatment stopped the malady at once, and although the optic disc became pale in the end, the patient retained his good acuity of vision and was able to continue his work as an official. I do not hesitate to consider this case as a complication of tabes with syphilitic inflammation at the site of the chiasma. Contrary to this, the other six cases proved their malignant

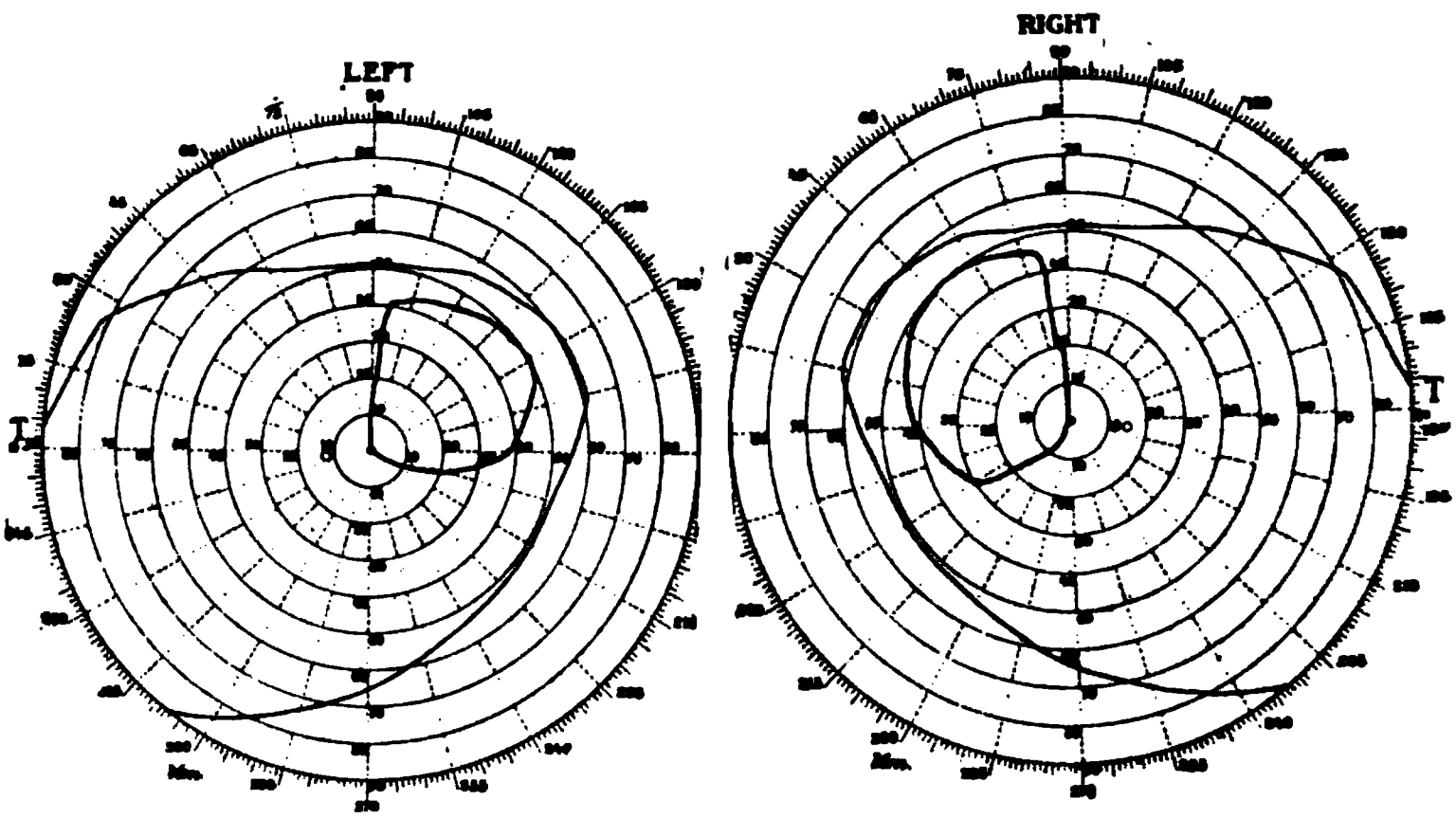

Fig. 6.

character in different ways. The preserved nasal half of the fields presented a noteworthy contraction of its limits, especially for colored test-objects. The color perception decayed rapidly and the contraction of the field progressed, sometimes symmetrically, so that only one sector, usually the upper nasal one, remained on each side, until at length the blindness became complete. The optic discs were pale from the very onset. All this leads me to believe that we have to do here with the same kind of gray degeneration which is characteristic for tabetic atrophy in general. As a rule, the spots of gray degeneration are located in the optic nerves.

Were it so also in the cases of bitemporal hemiopia, the hemiopic form of the fields would be merely accidental. This, of course, is not beyond possibility, but it is not probable with reference to the great regularity of the contraction of the fields in so many as six cases. Besides, if bitemporal hemiopia is supposed to be the consequence of mere chance, why is a binasal hemiopia never produced in the same way? I, at least, have never seen one, nor is one on record. So we must needs locate the lesion at the same place where it is situated in ordinary cases of bitemporal hemiopia from tumor: to wit, in the inferior part of the chiasma occupied by the decussating fibers. We must assume that the tabetic degeneration, as a rule seated in the optic nerves, may exceptionally locate itself farther back in the chiasma. So, according to my belief, bitemporal hemiopia is in most cases of tabes to be considered not as an accidental complication due to syphilitic inflammation, but as a genuine tabetic affection.

DISCUSSION.

DR. G. E. DE SCHWEINITZ, Philadelphia: I desire to express my appreciation of Professor Fuchs's interesting paper. I have made some investigations of the visual fields in tabetic atrophy and compared them with those furnished by the toxic amblyopias. The diagrams of the scotomas in tabetic atrophy I published in a book on nervous diseases edited by Dr. Dercum. While these scotomas do not exactly correspond with those illustrated by Professor Fuchs, they are at least analogous. Doubtless Professor Fuchs is familiar with some observations made in France, that the subjects of central scotomas in tabetic atrophy were always found to be users of tobacco and alcohol, and that when the history of tobacco and alcohol was eliminated, scotomas did not occur in tabetic atrophy. I would like to inquire of Professor Fuchs whether these statements corresponded with his own experience.

DR. EDWARD JACKSON, Denver: I am sure that other members of the Society feel as I do—unwilling to undertake the discussion of this subject without special preparation.

But there occurs to me a question that has been a practical one with all of us in studying cases of this class, or allied cases. This is regarding the methods of arriving at a correct visual field. While it is not the chief point in Professor Fuchs's communication, the question of methods of determining the visual field in different stages of the development of the scotomas is largely responsible for the different opinions regarding the matter. Perhaps Professor Fuchs has some routine method of making the examination, or some points regarding it, that if we understood them would bring us more frequently to the same results. That we fail to get exact maps, even by applying Bjerrum's method, as some of us have tried to apply it, or by other exact methods, is probably due to the fact that the fixation point in a field of this kind is often involved early to such an extent that fixation becomes difficult. I cannot help feeling that the map of the field, which is the test of the nature of such a case, must depend largely upon technic; and I am sure that others as well as myself would be interested if Dr. Fuchs would digress far enough to go into the question of taking the measurements of the visual fields.

DR. LUCIEN HOWE, Buffalo: I have had difficulty more than once with regard to just that technic. I soon found that if the center of the eye did not correspond to the center of the arc of the perimeter, it was possible to map out almost any kind of field. Because, if you extend the radius back two, or even one centimeter, you will have a very much larger arc.

In order to be sure that the eye is in the center of the arc, I attached a gun-sight to a carrier on the arc of the perimeter, the two points of the sight being in the line of a radius of the arc. This made it possible to center the eye quite exactly. Also, I attached an electric light to the concave surface of the carrier, and covered the light with a tube pointing toward the center of the arc. This, with other modifications which need not be mentioned here, make it possible to obtain more constant results. I can measure the visual field to-day and again to-morrow, and get practically the same results, which is not so easily done with other methods. I feel like apologizing for any such apparent digression, but the technic is so important a factor

that I would be much obliged to Professor Fuchs for a word on that point.

DR. E. FUCHS, Vienna: In one respect Dr. de Schweinitz has misunderstood me. It was not 30% of the cases of tabetic atrophy that showed a central scotoma, but thirty cases was the whole number of central scotomas seen among my cases of tabetic atrophy, which certainly amounted to many hundreds. I did not state the percentage, and am sorry that I was misunderstood.

Regarding the question of smoking or alcoholism, I would say that all the patients were men, as is usual in tabes. There was none of them that did not smoke, and the man from whom the specimen came was a heavy smoker. In the first case I thought that it might be a complication of toxic central scotoma, and gave a good prognosis, but I ordered the patients to abstain from smoking. The scotoma, however, became larger and larger, and the patient finally went blind. A man with tabes may get toxic scotoma, but if this were the case in most of these patients, stopping the use of tobacco and alcohol would have brought about an improvement in the scotoma. It did not do so, and all became blind. It was then only that I became aware of the fact that it must be something else than simple syphilitic neuritis or tobacco amblyopia. Stopping the tobacco and instituting anti-syphilitic treatment would have had success, if this had been so.

As to the question asked by Dr. Jackson and Dr. Howe, I would say that I used a MacHardy's self-registering perimeter and the ordinary perimeter with the campimeter. The diagram was first on a large scale, and was reduced in size in order to be in accordance with the general chart.

I ought also to say that if you examine the patient for the first time, you usually do not find the blind spot, as shown in the chart; but if you examine several times, it will be discovered. If repeated examinations are made on the same day, the result will be practically the same; but if you examine the patient on subsequent days, you will not find it exactly alike, because the fixation is not sure. If the central scotoma is difficult to locate, you should make the patient look at the tip of his finger. The figures given are the average results from three to five days' subsequent examinations. If you examine only once, the result is not reliable.

A REPORT OF FOUR CASES OF ACUTE DISSEMINATED MYELITIS WITH RETROBULBAR DEGENERATION OF THE OPTIC NERVES.

WARD A. HOLDEN, M.D.,
New York.

All four patients, adults, seen in 1910 at the Neurological Institute of New York, had sensory disturbances in the trunk and limbs and more or less complete paraplegia. These conditions continue to the present time in two patients, while the other two patients died of respiratory paralysis.

Retrobulbar neuritis may precede, accompany, or follow myelitis, but it is no longer regarded as being dependent upon the myelitis. The two have a common cause—a noxious matter circulating in the blood. In this disease foci of degeneration appear scattered through the spinal cord, and the vessels which run in from the pial sheath to these foci are surrounded by cellular infiltrations. Bielschowsky has found similar changes in the optic nerves and tracts in cases of myelitis. It is still uncertain whether these inflammatory changes are caused by bacteria or whether they are due to the action of toxins.

The fact that these foci of degeneration have an accidental distribution along the arteries entering the optic nerve from the pial sheath would lead us to expect ocular clinical pictures that are unusual, and indeed in two of the cases to be reported here there were defects in the fields of one eye of a hemianopic character, and in one case there was excessive concentric contraction of the fields of one eye, with fair central vision.

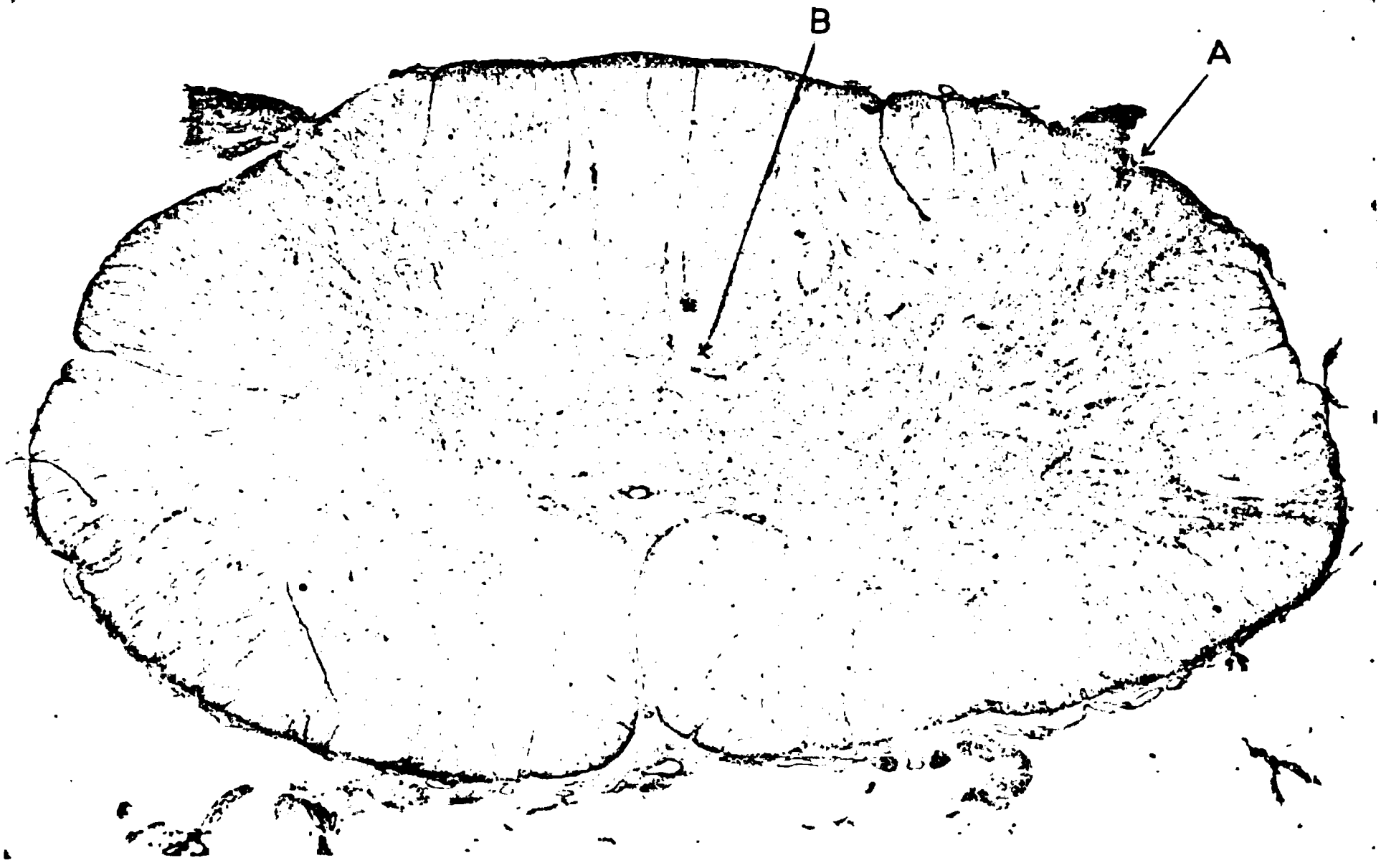

Fig. 1.—Cord of Case 2 at the sixth cervical vertebra. Central softening and two tongues of softening extending out to the pia on the right side.

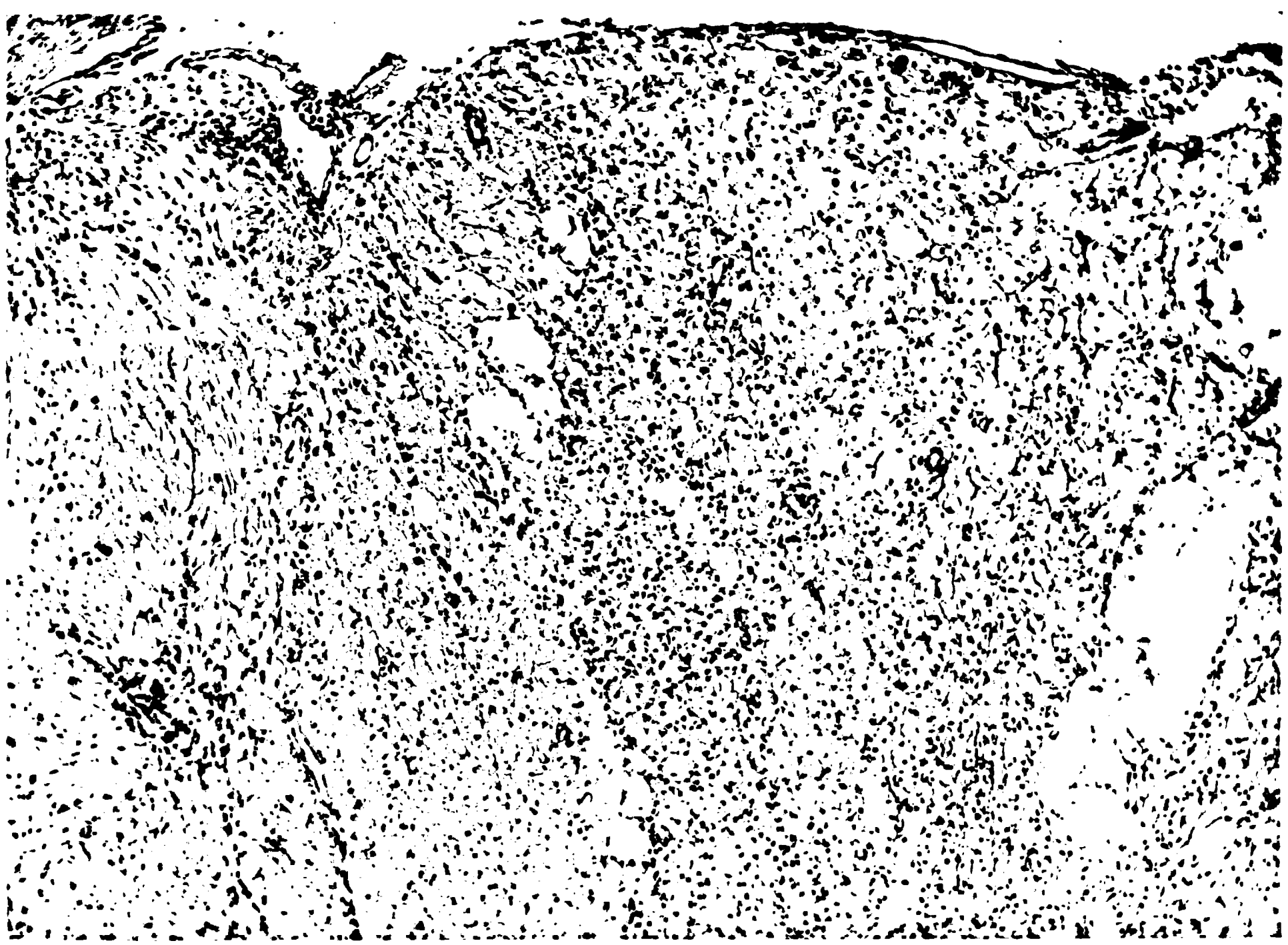

Fig. 2.—Spot A (Fig. 1) more highly magnified. Infiltration about pial vessels. Destruction of nerve tissue with glial overgrowth.

CASE 1.—*An Ascending Myelitis Following a Partial Degeneration of One Optic Nerve.*—Mrs. H., a housewife, aged thirty, was admitted to the Neurological Institute May 25, 1910, on the service of Dr. Collins.

A few days before Christmas, 1909, she had noticed that the vision of the left eye was becoming blurred, and by Christmas day the eye was totally blind. Two days later there appeared a paroxysmal stabbing pain in the left side of her face, not of constant location, eased by hot applications, and passing off in a few days. Early in January, 1910, her vision returned in the left eye and gradually improved for a month, since which time it has remained stationary. Her health continued good up to April 25th, when she awoke to find the fingers of her left hand numb. There were then no motor phenomena. April 27th paresthesia was noticed in the left foot, and on the following day in the right foot and hand. A feeling of tightness about both legs came on—a garter sensation. April 30th and in the week following there was sharp pain in both shoulders and also stiffness of the legs that rendered walking difficult, and later impossible. May 15th severe shooting pains were felt in the back of the neck and in the occipital region, but not in the arms. There was weakness of the left upper extremity, followed two days later by paralysis. The right upper extremity then became weak and later was paralyzed.

Status, May 25, 1910: Eyes: Corneal sensibility normal in each eye. Pupils: R. 3.5 mm., L. 4.5 mm., in diameter, round; light reflex diminished in right. Mobility normal; R. vision $=\frac{20}{30}$; L. vision $=\frac{20}{200}$. Skiascopy showed a slight error of refraction. Fields of the right eye normal. Field of the left for white nearly normal, but for green there was a defect of the temporal half of the field, including the fixation point and encroaching above slightly upon the nasal half of the field. The right fundus was normal. The left optic disc was pale, particularly in the temporal segment; its margin was blurred, and the arteries on the disc and in the neighboring retina were bordered with white lines, while the veins were of normal caliber and were not tortuous. The appearance of the left disc suggested atrophy of the optic nerve following a retrobulbar neuritis.

The other cranial nerves were normal. There was flaccid

palsy of both arms and both legs. Breathing was entirely thoracic. Sensation was variable. A touch with cotton-wool was felt everywhere. A pin-prick was usually perceived, and above the level of the nipples it felt "more disagreeable." Heat and cold were perceived as warm on the legs, but were felt correctly on the trunk. The reflexes were absent in the arms and abdomen. The knee-jerks and ankle-jerks were present. There was double clonus and Babinski.

There was no heart lesion, although there was considerable arrhythmia. The temperature fluctuated between 100° and 103°. The Wassermann reaction was negative. There was no lymphocytosis of the spinal fluid. The urine contained albumin and its specific gravity was 1.010.

Blood: r. b. c. 4,160,000; w. b. c. 9600; neutrophiles 66; large l. 18; small l. 5.

There were granular degeneration of the red blood-corpuscles, poikilocytosis, polychromatophilia, and anisocytosis.

May 30, 1910, the general condition was much worse and the spines and laminæ of the fourth, fifth, sixth, and seventh cervical vertebræ were removed by Dr. Elsberg. The dura was pale and pulsating. A 2 mm. incision was made and clear cerebrospinal fluid spurted out in large quantities. The wound was closed. Death occurred from respiratory paralysis four hours later.

Only a portion of the cervical cord could be obtained for examination. This, with a portion of the cervical cord from Case 4, was studied under the direction of Dr. C. B. Dunlap at the Pathological Institute of the New York State Hospitals, and to him my sincere thanks are due. The laboratory of the Neurological Institute was not then fully equipped.

CASE 2.—*An Ascending Myelitis with Pallor of Both Optic Discs.*—Mrs. S., aged thirty-eight, housewife, was admitted to the Neurological Institute on February 25, 1910; service of Dr. Collins.

Three weeks before admission, being one week after the birth of a child, she felt a constant severe pain in the small of the back. With this there were retention of urine and obstinate constipation. Stiffness of the legs was next noticed, and two days later there were paresthesias, and

soon all feeling was lost in the lower half of the body. The arms were not affected and the legs could be moved.

Two days before admission all sensation in the upper half of the body was lost, the fingers tingled, and the arms became weak. The pain in the back, which had ceased, returned and became general. There was vomiting, but no headache. She entered the hospital walking with assistance. Vision was said to be good.

Status on admission: She was paraplegic, and there were anesthesia and analgesia present below the fourth cervical vertebra, at which level there was a hyperalgesic zone. There was distinct tenderness on pressure over the cervical vertebræ from the second to the fifth. The knee-jerks were normal, the ankle-jerks were present, the abdominal and epigastric reflexes were absent on the right side. There was no ankle clonus, and there was plantar flexion.

Eyes: When the eyes were examined, the patient would not co-operate and the acuteness of vision could not be determined. There seemed to be no gross defects in the fields. Pupils and the movements of the eyes were normal. The optic discs were diffusely pale without alterations in the vessels. The state of distinct paleness of the discs was confirmed at subsequent examinations and seemed to indicate a degeneration of the nerves, although no history of previous disturbance of vision was obtained.

March 2d, the general condition was much worse. The anesthesia and analgesia extended above the clavicles. The Babinski and Oppenheim phenomena were well marked and there was pseudo-clonus.

March 7th, the patient was unable to move any limb, but the head movements were normally performed and the shoulders could be raised. Breathing was thoracic entirely. The temperature ranged from 98° to 100°; Wassermann reaction negative.

March 14th, Dr. Elsberg removed the spines and laminæ of the fourth, fifth, sixth, and seventh cervical and of the first dorsal vertebræ. The dura did not pulsate, but felt abnormally tense. Death took place from respiratory paralysis the following day.

Only a portion of the cervical cord could be obtained for examination.

CASE 3.—*A Myelitis with Complete Atrophy of One Optic Nerve.*—E., a cabman, aged twenty-eight, was admitted to the Neurological Institute April 22, 1910, on the service of Dr. Fraenkel.

A year before (May, 1909), without known cause, a sharp pain developed above the left hip and in the legs, lasting for two months. A few days after the onset paraplegia and paresis of the arms came on. His mouth was drawn to the left and there was difficulty in pronouncing words. There was gradual improvement for a time, but in November, 1909, the hands became worse and contractures developed.

In January the sight of the right eye began to fail, and in two months vision was almost lost. There was retention of urine and at times constipation. No headache or vomiting.

Status on admission: The patient lay on his back, unable to move his body except his head and shoulders. The arms were flexed, but he was able to extend the elbows and wrists. There was complete loss of power in the trunk and flaccid paralysis of the legs. There was slight blunting of sensibility below the level of the fourth dorsal vertebra. The cranial nerves were not involved, with the exception of the optic. The abdominal reflexes were present. The knee- and ankle-jerks were absent. Babinski positive; Oppenheim positive, right and left.

Eyes: Corneal sensibility normal. Pupils 5 mm. each in diameter, irregular, light reaction wanting in the right. Mobility normal, no nystagmus, no history of diplopia. Vision of the right eye was perception of movement of hands; of the left eye $V = \frac{20}{20}$. For a candle the temporal half of the field for the right eye was complete, but the entire nasal half was wanting, with a fairly sharp vertical line of demarcation between the two halves. The fields for white and colors were normal for the left eye.

The right optic disc was white and sharply outlined. The arteries were small, the veins were of normal caliber, some of them being slightly tortuous, suggesting a previous retrobulbar neuritis.

The patient's condition remained unchanged and he was discharged a month after admission.

CASE 4.—*An Ascending Myelitis Immediately Following Retrobulbar Neuritis in Both Eyes.*—Mrs. M., aged forty-five,

Fig. 3.—Spot B. in Fig. 1, showing vessels with cellular infiltrations about them.

Fig. 5.—Left half of Fig. 4, showing infiltrations about the vessels.

a housewife, was admitted to the Neurological Institute, in the service of Dr. Bailey, December 20, 1910.

She had been well, except for insomnia, until December, 1910, when, after an unpleasant discussion, she became very nervous and required the services of a nurse. The sight became blurred after a sharp pain in the left eye, and the eye within two weeks became entirely blind.

December 10, 1910, while walking, her knees gave way and she fell to the sidewalk. After this, burning and pricking were noticed in the right foot and leg, and the left leg became numb to the knee. She fell on successive days after this until admitted to the hospital, December 20, 1910.

Eyes: The corneal sensibility was reduced on the left side. Pupils: right, 5 mm.; left, 4.5 mm.; both slightly irregular; light and convergence reactions good in each eye. Mobility normal; no nystagmus. Right, vision $= \frac{20}{200}$; left, no perception of light. The right field for a 1 cm. white square and also for the hand was concentrically contracted to 15 degrees from the fixation point in every meridian. All colors, 1 cm. square, were recognized for about 5 degrees from the fixation point in every meridian.

The fundi were almost normal in appearance. There was a slight blurring of the margin of each disc, and the surrounding retina showed a trace of edema. The vessels appeared to be normal.

The other cranial nerves were normal. There was anesthesia of the legs and of the trunk up to the seventh cervical vertebra, with sensitiveness to pressure from the sixth to the third cervical vertebra. Sensibility and muscular power of the arms were normal, but the patient was unable to stand alone. The epigastric and abdominal reflexes were absent, the knee-jerks present. In the next few days there was severe shooting pain in the frontal and occipital regions and in various parts of the back. The patient was discharged December 23, 1910, and there is said to have been improvement in her condition since. There was no increase in temperature. The blood-count revealed nothing abnormal. The urine was normal. Spinal fluid: one lymphocyte to the c. mm.; no globulin; Wassermann negative; bacterial culture negative.

Blood: Wassermann negative, bacterial culture negative.

Clinical Summary.—An eye may become blind within a few days without fundus changes. Vision lost may be restored in part. Later, pallor of the disc, partial or total, may be found; the margins of the disc may be blurred; the veins may be tortuous, and the arteries may have thickened walls.

The fields of vision in the three cases in which they could be determined were peculiar. In one there was excessive concentric contraction of the field with fair central vision, and in two there was hemianopia for certain test-objects for one eye alone.

Pathologic.—Bielschowsky, in his monograph ("Myelitis und Sehnervenentzündung," Karger, Berlin, 1901), describes the pathologic findings in the cords and optic nerves of four patients dead of this disease, and concludes that a noxious agent in the blood produces focal changes in both the parenchyma and the interstitial substance of the cord. There were scattered foci of softening, with infiltrations about individual vessels running into these foci. In the optic nerves in some cases he found foci of degeneration along certain vessels of the nerve, while the pial sheath was normal. In other more advanced cases there were breaking-down of the nerve-fibers, increase in the septa, increase in glia cells, with the presence of fatty granular cells and cellular infiltrations along the vessels.

The pathologic changes found in the cords of Cases 1 and 2, described above, are well shown in a series of photographs of sections. Fig. 1 (Case 2) is from a section at the level of the sixth cervical vertebra, seen from behind, with the ventral side below, stained with hematoxylin-eosin. It shows a degeneration of the gray matter and lateral columns of the right side of the cord, in the latter areas extending in a dorsal and a ventral tongue to the pial sheath. In the degenerated area the blood-vessels are surrounded by cellular infiltrations. The pial sheath is but slightly infiltrated here and there. Fig. 2 is an enlargement of the section at point A,

Fig. 6.—Cord of Case 1, at fifth cervical vertebra. Large central softening

shown in Fig 1. At this point the pial vessels are surrounded by cellular infiltrations. In the cord there is degeneration of the nerve elements with glial overgrowth, many spider cells being present, and in certain areas there are numbers of gitter or fatty granular cells. Fig. 3 represents a higher magnification of the point B in Fig. 1, showing vessels surrounded by cellular infiltrations running into the area of degeneration.

Lower down in the cord we find a different arrangement of the softened areas. Fig. 4 is from a section at the level of the first dorsal vertebra. It shows a central degeneration with one ventral tongue extending to the pia on the left side of the cord and a dorsal marginal area of degeneration. The dorsal marginal area contains vessels with slight infiltrations about them, and there are present a few spider cells and a few fatty granular cells. The tissue is greatly rarefied, as is the tissue bordering the large areas in which the degenerative process is active and the fatty granular cells are abundant. Fig. 5 represents a greater magnification of the left portion of the section shown in Fig. 4. In this illustration are clearly seen the infiltrations about the vessels running from the pial sheath inward to the area of degeneration.

The conditions found in the cord of Case 1 were similar. Fig. 6 is from a section about the level of the fifth cervical vertebra. It shows an extensive central area of softening similar to those found in the other cord, except for the fact that many hemorrhages are present. The vessels running from the pial sheath to the softened area are surrounded by cellular infiltrations. The destruction of nerve tissue is less marked than in Case 2, and the Marchi reaction is not pronounced. Scharlach R shows the granular cells to be filled with fat globules. Fig. 7 represents a higher magnification of the softened area, showing two vessels cut transversely, with excessive cellular infiltration about them.

Many fatty granular cells are present, and there are a number of broken-down red blood-corpuscles.

In these two cases (Cases 1 and 2) there would seem to have been a noxious agent in the blood, which destroyed the parenchymatous elements of the cord and also damaged the vessels supplying the affected parts, and we are justified in assuming that a similar process occurred in the affected optic nerves.

EPISCLERITIS PERIODICA FUGAX.

ALBERT C. SNELL, M.D.,
Rochester, N. Y.

Reports of cases of fugacious episcleritis in ophthalmic literature are of such rare occurrence that a detailed report of two cases which have come under my personal observation may be of sufficient interest to be worthy of record.

Probably the first case of this nature was that reported by von Graefe[1] in 1871 under the designation of "subconjunctivitis." This condition was also described by Hutchinson[2] under the designation of "hot eye," in his Bowman Lecture of 1882, on "The Relation of Certain Eye Diseases to Gout." Three years later Nettleship[3] described four cases of this nature. In 1895 Professor Fuchs[4] reported his observations and conclusions of a study of twenty-two cases, under the title of "Episcleritis Periodica Fugax." It was his articles which first brought these interesting and peculiar cases to the wider notice of ophthalmologists in general. Professor Fuchs first presented the subject before the ophthalmological section of the British Medical Association in July, 1895, and later, in von Graefe's Archives, there appear the details of twenty-two cases. There have been only a few isolated cases reported since.

The history of my first case is as follows:

CASE 1.—Mrs. M., forty-two years of age, first consulted me May 24, 1909. She has the appearance of enjoying perfect health and takes great pride in stating that she has never had anything the matter with her. She is a well-nourished, moderately stout woman, weighing 140 pounds, who has not had any severe illness since the exanthemata of childhood, but is of a decidedly tense, neurotic type. She is the mother of two healthy children.

At the time of her first visit the left eye was involved. This had the appearance of an acute inflammation and was limited entirely to the outer quadrant. The conjunctival vessels of this area were distended, and the conjunctiva was slightly swollen and edematous, but there was no nodular enlargement. The subconjunctival vessels were distended and congested, as also were the episcleral vessels, giving the sclera the characteristic violaceous color, which did not disappear under pressure of the finger. The inflamed quadrant or sector was situated exactly in the region of the tendon of the external rectus muscle and its insertion, and the inflammation was most marked in the sheath of this muscle's tendon and its insertion. The remaining quadrants of the eye retained their normal appearance. Lacrimation and photophobia were present to a moderate degree. The onset of this attack began ten days prior to this visit, and was coincident with the beginning of menstruation. She complained of severe neuralgic pain in the eye, and above it, in the supraorbital region, where it was most intense. She was unable to read without exciting severe pain, and, in her own words, "I cannot focus on any object without causing a shooting neuralgic pain." She complained of a dull headache and a feeling of languor. The inflamed area was tender to touch. The cornea was clear, and the iris reacted normally to light and to accommodation. With the ophthalmoscope the media were found to be clear and all fundus structures to be normal. Her distant vision without glasses was $\frac{20}{20}$ in each eye. Although any attempt to read caused lacrimation and severe exacerbation of the neuralgic pain, she was able to read pearl print from 9 to 13 inches.

The history of the attacks prior to her first consultation with me, according to her best recollection, is as follows:

The first attack occurred in July, 1905, and lasted about five days. They recurred this year in August, September, October, and November, December being free from an attack. In the following year (1906) she was free from the attacks during January and February. Then they recurred during the months of March, April, May, and June. July and August were free from attacks. The attacks occurred each remaining month of this year, and recurred each month of the following year (1907), with possibly a single exception. In the year 1908 there was an attack each month, except for two months in the fall. Then recurrences were without exception up to the date of the first consultation.

The patient states that each attack recurred at the beginning of the menstrual epoch, the onset of the inflammation being rather sudden, coming on without prodromal symptoms and reaching its height in the first day. The inflammation invariably remained during the period of menstruation, often subsiding coincident with its termination, but occasionally persisting two or more days after menstruation had ceased. The duration of an attack was usually from five to eight days. In November, 1908, the attack began a week previous to the beginning of menstruation. At this time the patient was under a severe nervous strain, as her husband was in the hospital, and her son had an attack of appendicitis for which an operation seemed imperative. This attack lasted twelve days and was the longest and most severe to this date.

Patient states that during every one of these attacks the eye was painful, the pain being neuralgic in nature; that she was unable to do any close work on account of this pain, and that she had to remain in a darkened room. These attacks have occurred first in one eye, then in the other, without any regularity, and twice they have occurred simul-

taneously in both eyes. Likewise there was no regularity in the quadrants, which were successively involved. However, patient thinks that the left eye has been the one most often afflicted, and usually it has been either the outer or the inner quadrant.

During the year 1908, under the advice of her family physician, she had given careful attention to diet and to hygiene. Although this patient had been unusually rational in her dietetic habits, her physician restricted proteids to the lowest amount, though fish, eggs, and milk were taken in moderation. She spent the months of May, June, July, August, September, and October in a simple out-of-door life, living at the lakeside in the country.

This patient has now been under my own observation for over two years, and I have observed her eyes many times both during her attacks and during the interval between the attacks. As the appearance of each recurrence varies little, I shall not give the detailed case history, but shall summarize the further history of this case as shown by my case records.

Since she came under my care in May, 1909, the attacks recurred during the remainder of this year in the following months: June, September, October, twice in November, and again in December. In the year 1910 she had recurrences in February, March, April, May, June, July, August, September, November, and December. In 1911 attacks have occurred in January, February, March, April, and May. In the year 1910 the severest attacks occurred during June and July, and were of nearly two weeks' duration, whereas in the previous year the patient was free from attacks in July and August. The attacks of 1911 have been, on an average, of longer duration than those of the previous year, the shortest attack being ten days, and the longest three weeks. In January of this year an examination of the urine revealed for the first time some abnormality. There were present albumin and a few casts. The patient was im-

mediately put on a rigid diet and kept in bed for four weeks, at the end of which time the examination of the urine became negative again. During the intervals between the attacks the conjunctiva is normal, except for a slight velvety thickening, and it is also slightly yellowish in color. The sclerotics show no alteration whatsoever. Likewise during these intervals the patient is entirely free from all pain or discomfort, and is able to go about her usual vocation without any annoyance. Menstruation always has been, since its beginning, and still is, regular and perfectly physiologic. The pelvic organs have been examined by two competent surgeons, and both pronounced them absolutely normal.

CASE 2.—Mr. B., an office clerk by occupation, twenty-nine years of age, first consulted me June 6, 1911. He states that he has been having a recurrent inflammation, in various parts of one eye or the other, for the past three and one-half years. This inflammation lasts from four to ten days. During the attacks the eye seems "hot," and at times it is so painful that he has been unable to work. Pain is supraorbital, around the eye, and in the eye. On one occasion both eyes were affected at the same time. He states further that the inflammation is usually in different quadrants of the eye with each recurrence.

His eyes have not been sensitive to light, but efforts to do near work have often caused such pain as to compel him to give up work for a day or two. He has been entirely free from attacks for three months, but has had four recurrences in a single month. They have usually come on suddenly, reaching their height in a single day, the symptoms being rather severe for two or three days and then gradually subsiding. One attack, which lasted but two days, terminated suddenly while the patient was under great nervous excitement, for he had been told that his six-year-old daughter had been enticed from home by a strange man.

The appearance of the eye on the day of his first visit to me was as follows: There was an inflamed area confined to the region of the tendon of the right inferior rectus muscle, the conjunctival vessels being distended and congested, and

the conjunctiva itself appearing slightly edematous. The superficial scleral vessels were distended and congested, presenting a violaceous color, which did not disappear under pressure of the finger. This area, however, was tender to touch. On looking down he complained of a shooting pain. Strong convergence also produced pain. With a +0.75 c. in each eye vision was $\frac{20}{20}$, and he read pearl print from 9 to 18 inches. The eye was not sensitive to light, there was no lacrimation, no nodular enlargement, and no secretion. The attack began sixteen days previous to this visit, and two days later all inflammatory symptoms had disappeared. June 9th his eyes were perfectly normal and he was free from any discomfort.

His eyes remained quiet until June 13th, on which date he again consulted me, stating that an attack had begun that morning. I saw him twice on this day and each successive day for several days, and thus had a fine opportunity to watch the development of the local condition. On this occasion the inner quadrant of the right eye was involved. At the beginning of the attack the larger vessels were the first to become dilated, and, studied by means of the loop, they stood out very beautifully and could be seen distinctly lying in several layers. First lay the superficial conjunctival vessels, which were freely movable with the conjunctiva; then beneath these were seen the vessels in the subjacent loose tissue, crossing beneath the superficial ones and less freely movable than those above. Beneath these, the superficial vessels of the sclerotic were distinctly seen and were immovable. These imparted the bluish tint. A few days later the smaller vessels also became distended, imparting a bright red color to the affected quadrant, and the three layers were not then visible. But after the instillation of a few drops of adrenalin solution (1 : 1000), the smaller and superficial vessels having been emptied, one again saw the same condition as in the early stage. Adrenalin did not empty the scleral vessels.

Patient was free from pain except when making efforts at convergence. He complained that the eye had a burning, feverish sensation, that there was a sense of fullness in his head, and a sense of somnolence. The latter annoyed him very much.

Patient is a short, fat man, weighing 240 pounds. He has always enjoyed good health, with the exception of an attack of rheumatism nine years ago. Prior to this attack of rheumatism he was an excessive meat-eater. But since this time, under the advice of his physician, he has taken meat in moderation. However, he is still a hearty eater and partakes of malt liquors daily (one or two glasses). Since January 1st he has kept a diary of attacks, which is as follows: From January 3d–9th, right eye was inflamed; April 1st–2d, left eye; April 11th–13th, right eye; April 15th–21st, right eye; May 21st to June 9th, left eye.

Treatment of Case No. 1.—Prior to her first consultation with me she had been under the care of an ophthalmologist for more than a year. He had made a careful examination of the refraction and had ordered a low sphero-cylindrical correction for constant use. A number of therapeutic measures had been tried locally, including heat, cold, atropin, dionin, simple collyria, and electricity. Internally salicylates and potassium iodid had been given. Careful attention had been paid to diet and hygiene. For six months (the summer of 1908) the patient lived a simple life at the lakeside. After coming under my care scrupulous attention was paid to the gastro-intestinal tract, moderate exercise was insisted upon, and the patient was advised to live as much out-of-doors as possible. The urine has been repeatedly examined, and these examinations have always shown it to be of normal specific gravity, free from casts, albumin, and sugar, except in January, 1911, when, as has been stated, a slight trace of albumin was discovered.

Locally I have not been able to find anything which seems to afford relief. Both heat and cold seem to aggravate, and even a 1% yellow oxid salve has a like effect. Dionin also produces a decided exacerbation of symptoms. Atropin, however, which I have been forced to use on several occasions, has afforded considerable relief. She has also found marked relief by taking migraine tablets. These were

composed of acetanilid, 5 grains, and caffein, $\frac{1}{5}$ grain, of which she takes as many as six a day. This has been done without the advice of her physician. Treatment has apparently been of little avail, as at present her attacks are more severe and of longer duration than formerly.

Case 2 has not been under observation long enough to draw any conclusions in regard to benefit of treatment. Dionin relieved the pain of one attack, and no other local treatment has been used.

The remarkable characteristic of my first case is its persistent recurrence during the menstrual epoch, and the attacks have not occurred at any other time. Several authors have stated that their patients thought that menstruation caused the onset of their attacks of episcleritis, but these authors, for the most part, have expressed a doubt in regard to their relationship. Wyler[5] states: "My patient is prone to believe that her attacks are more frequent and of greater severity during her menses, but the greater excitability at that time may be the explanation. Sufficient grounds for an admission of this kind do not exist." Robinson[6] found that several cases had the beginning of their attacks during the climacteric, and the attacks were also found to be associated with disturbances of menstruation. Professor Fuchs found no connection with the disturbance of menstruation. Rubner[7] (Henrich), in an "Inaugural Dissertation on Further Contribution to the Study of Episcleritis," considering the general subject of episcleritis, mentions menstrual disturbances as having a possible slight influence.

The exact etiology of this class of cases is still unknown, and various etiologic factors have been ascribed by different authors. Hutchinson and Nettleship found gout to be apparently the principal factor. Fuchs, in his series, assigned gout, rheumatism, rhinitis, and malaria, the latter being the probable cause of several cases. He states, how-

ever, that no definite conclusion can be arrived at as to the cause of this condition. Burnett[8] (Swan M.), under the head of "Acute Hyperæmia of the Sclera," attributes the attacks to some transitory disturbance of the vasomotor system. Baas,[9] in the report of one case occurring in a young man, believes that a nervous origin alone can be assigned as the cause, and explains the local manifestation as a primary neurosis of the conjunctival nerves. E. T. Smith[10] believes that a paragonorrheal condition may have been an exciting factor. Wyler's patient precipitated a severe attack by an indiscretion in diet and excitement.

In my two cases malaria can positively be excluded, as we do not have malaria in Rochester and they have not lived elsewhere. Reflex disturbances from pelvic disorder may be excluded in the first case, and reflex disturbances from eye-strain may also be excluded in both cases. Neither is there clinically in either case anything which would lead one to think that there might be present a rheumatic or gouty element. There was no demonstrable gastro-intestinal disorder and the examination of the urine has always been negative (except as stated in case 1). However, from a review of all the reported cases one finds no more satisfactory conclusion than that some general metabolic disturbance is the exciting factor in this class of cases. But, in addition to this, a factor which is at least contributory to the onset of the attacks is an unstable or perturbed nervous system. In support of this, one finds that many of these patients have been afflicted during the climacteric, that the attacks have been associated with irregular menstruation, and that excitement has been a disturbing element. This latter was noted in both of my cases. In my first case a neurotic disposition was observed as well. The local condition seems to be essentially the result of a local vasomotor dilatation.

It seems to me, then, that the best explanation in this

peculiar form of episcleritis is that the local vasomotor disturbance is caused by some irritation which has resulted from a general metabolic disturbance to which a neurotic disposition or a disturbed nervous system is contributory.

BIBLIOGRAPHY.

1. von Graefe: Hirschberg, Klinische Vorträge, 1871, p. 161.
2. Hutchinson: Trans. Ophth. Society of the United Kingdom, 1881, vol. v, p. 3.
3. Nettleship: Trans. Ophth. Society of the United Kingdom, vol. viii, p. 94, Arch. of Ophth., xxi, No. 2, 1892.
4. Fuchs: British Med. Jour., Oct. 19, 1895, p. 951, von Graefe's Archiv, vol. xli, part iv, p. 229.
5. Wyler: Ophth. Rec., Feb., 1909, p. 57.
6. Robinson: British Med. Jour., 1888.
7. Rubner, H.: Univ. Press, Giessen, 1910.
8. Burnett, Swan M.: Norris and Oliver's System, vol. iii, p. 251; Arch. of Ophth., xxi, No. 2, 1892.
9. Baas: Zehender's Klin. Monat. für Augenheil., 1885, p. 238.
10. Smith, E. T.: Ophth. Rev., Oct., 1907.

DYSTROPHIA EPITHELIALIS CORNEÆ (FUCHS), WITH THE REPORT OF A CASE.

ARNOLD KNAPP, M.D.,

New York.

The patient, a woman, eighty-two years of age, came to me on February 1, 1910, with a hypermature cataract in the right eye. The left eye had been operated on for cataract twelve years ago, though the sight in that eye had never amounted to much. There was quite a thick secondary cataract with iritic adhesions, so that I did not at that time pay much attention to the corneal changes which were present, but proceeded to extract the cataract of the right eye. This was done without any accident on February 10th. At the first dressing, four days later, the wound was closed; no irritation, some deep opacity in upper cornea, the usual striped keratitis. This opacity on February 22d

had become fainter. On March 8th vision with correcting glass was $\frac{10}{200}$. The cornea showed a faint superficial opacity; the surface was uneven and finely stippled and was anesthetic. The deep vertical opacities were still present. The eye was otherwise perfectly normal; the pupil dilated freely with atropin. Tension normal. The condition was a very disquieting one for me; it seemed a neurotrophic disturbance which I could not explain. Dionin salve, yellow oxid of mercury salve, subconjunctival injections, hot applications, and bandaging was the local treatment; arsenic, strychnin, and iodid of potash were given internally. They were, however, of no avail. There was a temporary improvement, the corneal surface became smoother, and the opacity less in the center; then later the corneal changes increased. At no time was there any suspicion of increased tension; unfortunately, I neglected to use the tonometer.

At this time Professor Fuchs's article on "Dystrophy of the Corneal Epithelium"* appeared, and I was gratified to find an explanation for this obscure condition. I then examined the other eye more carefully and found the cornea partly opaque, with distinct small vesicles; the tension was not raised. The condition seems to be but a more advanced stage of the corneal changes seen in the eye recently operated upon.

On February 11, 1911, a year after the cataract extraction, the vision was unchanged. The cornea was superficially opaque except for a well-defined clear area down and in. There were faint but distinct vesicles. The sensibility of the cornea was reduced and in some places lost. The patient has since died.

Professor Fuchs, in his article, based on thirteen personal observations, gives us an unusually clear and complete picture of this interesting condition. He summarizes it

* Graefe's Archiv, lxxvi, No. 3.

as being a degenerative process of the cornea occurring in the aged, and usually in females. One or both eyes are involved. The first symptom is diminished sensibility of the cornea. The cornea then becomes opaque, generally in the superficial layers, and most marked in the pupillary zone. The corneal surface is opaque, uneven, with fine vesicles. In some of the cases glaucoma is present, though the opacity does not seem to be in any way the result of increased intraocular tension. The opacity slowly increases, and finally newly formed tissue is deposited on the cornea between Bowman's membrane and the epithelium. The cause is unknown and there is no treatment.

To my mind the above-mentioned case belongs to this group of dystrophies. It is of interest, as the condition could be followed from the very start. The tendency to this corneal degeneration was present before the operation, as the condition of the other eye operated upon twelve years ago shows. I regret that I did not appreciate the importance of testing the corneal sensibility before operation, as it is clear that the operation was the exciting cause.

The senile sclerosis of the cornea, mentioned by Fuchs as occurring after operations, which may be confounded with this condition shows a deeper corneal opacity and the superficial changes are absent. In my case the deep opacity, the striped keratitis, cleared up, while the superficial changes progressed and were permanent.

THE USE OF SERUM IN SYMPATHETIC OPHTHALMIA.

GEORGE S. DERBY, M.D.,
Boston, Mass.

AND

HORATIO N. PRATT, M.D. (BY INVITATION),
Louisville, Ky.

Our attention was drawn to the possibility of using serum injections in sympathetic ophthalmia by the article published by Zur Nedden in 1906.* Zur Nedden's case was as follows:

A twelve-year-old girl had met with a long, perforating injury which went through the left cornea and sclera into the iris and lens. The wound healed well; yet, as there remained a considerable inflammation of the eye, enucleation was advised, but not consented to by the parents. One month after the injury there was photophobia of the sound eye, soon followed by a well-marked iridocyclitis. The exciting eye was then removed, but the condition of the second eye continued to get worse in spite of all treatment, and the vision sank to $\frac{2}{7}$. The use of mercury, atropin, and cupping had no effect.

About twelve weeks after the onset of the sympathetic inflammation 20 c.c. of serum obtained from a patient (for a month this patient had had no ocular inflammation) shortly before blinded by sympathetic disease was injected subcutaneously. The success of this procedure was surprising. The change in the patient's condition came so promptly and was so marked following the serum injection that Zur Nedden did not regard it as an accident, but rather as a proof that shortly after the termination of a sympathetic

* Zur Nedden: Bakteriologische Untersuchungen bei sympathische Ophthalmie, etc., Archiv für Ophthalmologie, vol. lxii, p. 193.

inflammation the patient's blood contains antibodies, and if a quantity of it be injected into a second patient suffering from the same disease, his cure may be assisted.

In addition to this case we have been able to find in the literature a short statement by Brons* from the Freiburg Clinic to the effect that Zur Nedden's procedure had been tried there on two cases of sympathetic ophthalmia without any degree of success.

Outside of these three cases we have been unable to find any further references in the literature.

On March 25, 1910, Thomas Hurd, twenty-nine years old, came to the Massachusetts Charitable Eye and Ear Infirmary with an injury of the left eye and cuts of the face caused by the explosion of a bottle charged with gas. According to the record made at that time, there was an incised wound of the cornea extending obliquely across its entire surface and a slight wound of the iris beneath. He was advised to remain in the hospital, but refused.

On May 7th he returned, and, according to his story, the injured eye had quieted down in about five weeks. During the previous ten days, however, the good eye had been somewhat sensitive to light, and for two days it had been red and painful.

Examination of the left eye showed marked injection, the scar of the corneal wound running diagonally across the cornea, beginning just above the limbus superiorly and ending just below the limbus inferiorly. The iris was in contact with the posterior surface of the cornea; the pupil, displaced down and out, did not react to light nor dilate under atropin. The lens was opaque. Vision equaled hand movements close to the eye. Light perception and projection good.

The right eye (previously healthy) was markedly injected, very sensitive to light, and tender to the touch. There were many fine and a few large precipitates on the posterior surface of the cornea, the aqueous was turbid, the iris discolored,

* Brons: Zur klinischen Bild und zur Serumtherapie der sympathischen Ophthalmie (Verein Freiburger Aerzte), Münch. med. Woch., S. 1938, 1906.

the pupil small and irregular, with a little exudate along its margin. The lens was fairly clear, the vitreous slightly hazy. Vision = $\frac{20}{70}$. In short, there was a well-marked iridocyclitis.

The patient was admitted to the hospital on the service of Dr. E. E. Jack, through whose kindness we were allowed to treat the case with serum and to report it. He was placed in a dark room, and given mercurial inunctions twice a day, massive doses of salicylates, atropin every two hours, hot fomentations, etc.

On May 8th there was no change in his condition, except that he was having an increased amount of pain, particularly at night. There was a very slight amount of dilatation of the pupil upward. It was determined to try the effect of serum, as we had the following suitable case in the hospital:

Harlan Young, thirty-three years old, entered the Infirmary February 16, 1910, with a shrunken right globe resulting from a perforating injury three months previously. He had had pain in the globe for three weeks previously and photophobia.

Enucleation was performed, and he was discharged well on February 21st. At that time the left eye was normal, with a vision of $\frac{20}{20}$.

About the middle of March the left eye became red and slightly painful, and his symptoms have increased since then.

He came to the hospital on April 1st, on the service of Dr. Cheney. Examination showed marked injection, cornea slightly hazy, with a few precipitates on the posterior surface of the cornea. The iris was muddy, the pupil well dilated, and the lens clear. There was considerable pain.

The patient showed a gradual improvement, and on May 9th, at the time the first serum was taken, the eye was quiet, but there were still a few precipitates.

The pathologic examination showed an atrophied eyeball with very marked recent inflammatory changes. The picture of sympathetic ophthalmia was not typical, not improbably on account of the recent fresh inflammation.

An absolutely positive diagnosis of sympathetic ophthalmia cannot be made in this case from the pathologic examination, but the history and clinical picture were typical, while the pathologic examination was not inconsistent with it.

Technic of Blood Withdrawal.—The serum was obtained from this patient by puncturing the superficial veins of the arm and drawing the blood into a "Record" syringe of 20 c.c. capacity. Ordinary aseptic precautions were observed, and a tourniquet was applied above the elbow. For one unaccustomed to the procedure the technic is not easy, since a very considerable quantity of blood must be obtained. In several instances we had difficulty in entering veins on account of their small size. Too large a syringe may not be used, as it is unwieldy. Too large a needle will not enter the vein, and with a small needle it is difficult to avoid clotting, which will obstruct its lumen. We had trouble with several "Record" syringes in that when heated up to body-temperature the metal piston was exceedingly likely to jam in the glass barrel, and unless cleaned immediately after use it would stick badly.

To obtain a stated dose of serum it was necessary to withdraw about twice as much blood. For 30 c.c. of serum we had to take 60 c.c. of blood, and this necessitated several punctures, as it was rarely possible to obtain more than the capacity of the syringe (20 c.c.) at one puncture on account of clotting in the needle. After the blood had been emptied from the syringe into a sterile jar, we found it necessary to clean it at once in a jar of sterile water kept cold in an ice-bath.

On one occasion, being dissatisfied by these methods, the blood was obtained for us by Dr. Beth Vincent by a blood transfusion technic modified by him. A moderate size vein was laid bare at the bend of the elbow under cocain anesthesia. It was cut across, and a small glass tube coated with a special mixture of paraffin and stearin was inserted into one end, and no difficulty was found in securing 100 c.c. of blood. Our thanks are due to Dr. Vincent.

The difficulty in this procedure lies mostly in getting the

consent of the patient, especially when blood has to be secured on several different occasions.

The blood obtained was run into a sterile jar, and placed in the ice-chest for twenty-four hours, at the end of which time the serum was drawn off and injected subcutaneously between the shoulders.

On May 9th Hurd was given 23 c.c. of serum from Young. On May 10th, forty-eight hours later, there was a very considerable change in the condition of the right eye. The pupil had begun to dilate, the injection had nearly disappeared. The vision continued at $\frac{20}{70}$.

On May 11th the pupil was moderately dilated and nearly round; only a slight trace of injection remained. The iris was less muddy. There were many precipitates on the posterior surface of the cornea, and a number of small black pigment spots could be seen on the anterior surface of the lens where the iris had pulled away. Ciliary tenderness had disappeared. The vision had risen from $\frac{20}{70}$ to $\frac{20}{30}$. Tension was normal. In short, within the seventy-two hours following the injection there had been a remarkable change for the better in the condition. On May 12th the salicylates were omitted, as the patient was continually nauseated and could not eat.

The eye continued in the same condition until May 15th. There was a slight increase in the injection of the eye, and on the next day the vision decreased from $\frac{20}{30}$ to $\frac{20}{40}$. The injection then became more marked, and on the 18th, ten days after the first serum injection, a second was given, 30 c.c. being administered.

On May 19th V. O. D. $= \frac{20}{200}$. Marked ciliary redness, pupil getting smaller. Tenderness to the touch had reappeared. The left eye was then enucleated, as the projection in the upper field had become faulty.

On May 20th there was much less redness of the eye. Pupil fully dilated. Vision improved to $\frac{20}{70}$.

May 24th, eye white. No descemetitis to be seen. Pupil fully dilated. No photophobia. V. O. D. $= \frac{20}{30}$. Salicylate of soda, gr. 15, every two hours during the day, was again ordered; large doses of mercury were also being used.

In spite of this treatment, on May 27th the first signs of another recurrence began to appear, and by June 2d, five days later, in spite of energetic treatment, the eye was very red, cornea hazy, pupil only half dilated, and iris discolored. The patient's mouth was sore and his stomach upset. The mercury and salicylates were omitted and 20 c.c. of the same serum was injected. At this time the eye was in the worst condition it had been in at all; the pupil was closing down, and the vision had sunk to $\frac{20}{200}$.

Following this injection the redness and photophobia began in two days to disappear and the pupil again responded to atropin. Owing to increased vitreous cloudiness, however, the vision continued to sink for four days, reaching its lowest point, $\frac{2}{200}$, on June 6th. Then it began to rise rapidly, as the vitreous haze cleared, and on June 8th it was back at $\frac{20}{70}$.

It seemed at this time probable that the serum was efficient in temporarily overcoming the disease, but its action was limited as to time. As we could not obtain more of it at this time, we injected 6000 units of diphtheria antitoxin. The vision continued at $\frac{20}{70}$, and the eye remained white until June 16th.

On June 19th another recurrence began. Moderate redness, photophobia, pupil decreasing in size. V. O. D. $= \frac{10}{200}$. Tension slightly increased, pain at night.

June 22d, vision—fingers at six feet. Thirty c.c. of the same serum were then given. Two days later improvement was noticed.

June 26th, V. O. D. $= \frac{20}{200}$. June 29th, V. O. D. $= \frac{20}{70}$. Eye white and quiet.

On July 12th there was another recurrence, this time slight. Moderate redness and photophobia, pupil smaller, slight pain. V. O. D. $= \frac{20}{200}$.

July 14th, 25 c.c. of blood-serum were injected, and again two days later 25 c.c. more were administered. Following this the eye became white, the pupil dilated, the descemetitis cleared, and the vision had improved to $\frac{20}{50}$ by August 3d.

Steady improvement with no recurrences now took place, and on August 25th the patient was discharged. The eye was then white, pupil partially dilated, with a band of organized exudate all around its edge. Cornea and vitreous were slightly hazy.

Two months later the eye was white, vision $\frac{20}{30}$, and since then there has been continued slight improvement. During the early part of June he reported with a vision of one letter of the $\frac{20}{20}$ line. The pupil was moderately dilated and apparently bound down with connective tissue along its entire border. He is using his eye and earning a good living. It should be said that the pathologic examination of Hurd's eye showed well-developed sympathetic uveitis.

The apparent success of serum injections in this case led to our trying the same treatment on three other well-marked cases of sympathetic uveitis. The first of these received first 20 c.c. of serum from Hurd, the first case reported, whose eye then was practically well, and later 25 c.c. from the same source, and one injection of 25 c.c. from a patient who had recovered from sympathetic disease one year previously.

Case 3 received at intervals 35 c.c. and two injections of 30 c.c., all from Hurd (Case 1).

Case 4 received one injection of 30 c.c. from Hurd.

We are mentioning these cases together, and are not going into details about them because, although in certain instances improvement seemed to follow the use of the serum, yet in none was the result sufficiently striking and it could not be regarded as sure.

Judging from the action of special sera in other diseases, and reasoning by analogy, one would expect that if any good were to come from the injection of serum in sympathetic inflammation it would come quickly and leave no doubt as to the efficacy of the injection. In other words, it would act like diphtheria antitoxin and antimeningitis serum. Such was not the effect in the two cases reported from the Freiburg Clinic and in three of our cases. In Zur Nedden's case the effect of an injection was striking. Only one injection was given, and the patient recovered.

In our first case it will be noted that improvement following the injection of serum was very rapid, usually taking

MAY	JUNE	JULY	AUG.	OCT.	JUNE 1911

place within forty-eight hours. In one instance at the worst stage of the disease there was a marked improvement in the appearance of the eye at the end of seventy-two hours. The injection grew less and the pupil began to dilate. During this time, however, the vision continued to diminish owing to the increase in vitreous opacity. Five days after the injection, however, the vision began to improve, and rapidly rose from $\frac{2}{200}$ to $\frac{20}{70}$.

It may also be seen from the chart that the improvement in vision which followed the larger doses of serum continued somewhat longer than that observed when smaller doses were given. In this case each of the injections was followed by a very striking improvement. It was the kind of improvement one sees following diphtheria antitoxin. No one could have followed this patient as we did and have doubted that something was producing a remarkable change in a short time. It was the change which Zur Nedden saw in his case, and which led him on the basis of this one observation to regard the cure not as an accidental occurrence, but as due directly to the serum.

If the improvement in this case be regarded as no more than a striking coincidence, it certainly must be allowed that it was a coincidence of unusual consistency. The type of the disease was severe, and mercury and the salicylates were pushed to the point of toxicity. They seemingly could not check the disease.

It is apparent that serum will not work in every case—perhaps only in a small minority. We have too little knowledge as yet to give the reasons why. In case 1 the serum was obtained from a different individual than in cases 2, 3, and 4. We may conjecture that there is a great variation in the potency of the serum of different donors, and also a great variation in the action of different donees to a given serum.

What the best dose is, we do not know, but from our observations, probably not less than 30 c.c. And we are also

in ignorance of the period in relation to the disease in which it should have its greatest potency. But our first case and that of Zur Nedden lead us to believe that under certain circumstances the blood-serum of an individual who has been a victim of sympathetic disease may be of marked curative value when injected into a patient attacked by the same malady.

It is obvious that an opportunity to try out this method of treatment will not often occur, but we believe that further observations along this line are most desirable, for only by a large series of cases can we form a correct judgment as to its value. We hope that the report of this case will stimulate others to add to our very scanty knowledge.

DISCUSSION.

DR. ROBERT L. RANDOLPH, Baltimore: I had hoped that on a practical subject like this there would be a good deal of discussion. I am not satisfied that the condition as it now stands can be regarded as a permanent cure, and I should not be surprised if some of the remedies which were used in addition to the serum had contributed to the beneficial effect. We should be encouraged, however, by the statements of Dr. Derby. It is plain that the serum which he used is a potent agent, as evidenced by the marked reaction following its use; but so long as the exact nature of sympathetic ophthalmia remains in obscurity, some doubt would naturally arise as to the real value of this method of treatment, even though the serum were obtained from one suffering with sympathetic ophthalmia. I congratulate Dr. Derby on giving us an interesting and suggestive line of thought. I still think that nowadays I hear more often of cases of sympathetic ophthalmia than I did a few years ago, when ophthalmologists were less inclined to temporize with seriously injured eyes, and when the treatment of this disease with large doses of salicylate of soda was little known. The following interesting case was seen by me last autumn: The patient was a boy five years old whose right eye had been destroyed by an exploding torpedo. He had been for

five weeks immediately after the accident under the care of a skilful and sensible ophthalmologist, who had temporized from day to day until the child was brought to me with beginning sympathetic ophthalmia. This is an experience which any one of us might meet with in our desire and in our efforts to save the eye simply for cosmetic or social reasons. The child remained under my care for four months, during which time the treatment with massive doses of salicylate of soda and mercury inunctions also was given a fair trial. He was discharged with vision of $\frac{20}{100}$, and with a pupil well dilated, and a dusky iris adherent all around at the pupillary border, a picture resembling that seen in Dr. Derby's case, and a condition which to my mind presents anything but an encouraging prognosis. This eye no doubt will be the seat of recurrent attacks of inflammation until sight is lost. I am strongly of the opinion that no such risk should ever be taken with children, for in the absence of pain (as is so often the case with commencing sympathetic ophthalmia) they are slow to appreciate and tell us of their symptoms until the disease has made too great progress to be checked. There is no blindness which is as preventable as the blindness from sympathetic ophthalmia.

DR. J. H. CLAIBORNE, New York: I might state that six or eight years ago Dr. Coburn and myself made a number of investigations along these lines. We injected the posterior chamber and the anterior chamber of the eyes of rabbits with staphylococci, and caused an infection to become fully established. Then we injected into the venous system a serum corresponding to the microbe that we had used in injecting the eyes. The results of these experiments were absolutely negative. Finally, we injected the same micro-organism into the posterior chamber, and, after the inflammation had been established, serum was injected into the chamber, with no result. The eyes invariably went to complete destruction.

No reference has been made to these investigations, and it has been surprising to me that no notice was taken of them. Our conclusion was that in rabbits one cannot influence a suppuration in either the anterior or posterior chamber by injecting a corresponding serum into the venous system; nor a suppuration in the posterior chamber by

injecting serum directly into that locality. I agree with Dr. Randolph that it is unwise to attach too much importance to the results of Dr. Derby. Nevertheless, I think that progress will be made on this line of treatment. The experiments of Dr. Coburn and myself were the first made in this country, I believe.

DR. GEORGE S. DERBY, Boston: I should simply like to say that it is very hard to report a case of this sort and describe exactly what has happened, but I can assure you that the improvement in this case following the injections of serum was remarkable. A decided change took place, similar to the action produced in cases of diphtheria by the injection of antitoxin. The pupil widened out and the vision improved. Of course, you cannot judge from one or two cases alone; and in the other cases in which we used the serum we could not see that any effect was produced. In this instance, however, there was quite a remarkable effect, and we are publishing the case for what it is worth.

A CASE OF GONORRHEAL CONJUNCTIVITIS, WITH ARTHRITIS PRECEDING CONJUNCTIVAL DISCHARGE BY FOUR DAYS.

M. H. POST, M.D.,
St. Louis, Mo.

The following case is unique in my experience, and presents a very interesting question. But having depended upon another physician for certain data which I supposed he had, but which he finally did not furnish, the question is not answered, but rather suggested.

June 11, 1910, a girl, three years old, was brought to me with the following history: Six days previous she had complained of pain in her left wrist, later in her left shoulder, and two days after complaining of the pain in her wrist O. D.

became inflamed. She was taken to a general practitioner, who treated the arthritis with internal medication and confinement of the inflamed joints in a plaster-of-Paris splint. On account of the eye complication I was consulted.

When brought to me there was an acute conjunctivitis O. D. and O. S., much more marked O. D. than O. S. The lids were edematous, and thick, creamy pus was running over the child's face from the conjunctival sacs. Smears showed large quantities of gonococci in this discharge.

The patient was put in a hospital, where she remained under treatment until July. 13, 1910, at which time she was about well, the disease running its course in a little over four weeks. Recovery was perfect, leaving no unpleasant results.

The physician who treated the arthritis told me that the child had no vaginitis. The mother also asserted this, telling me that the physician had made a local examination.

I am not sure that a vaginal examination of the patient was made, though I understood at the time that it had been. The surgeon treating the joint affection may have depended upon the statements of the mother. I am sure that no blood tests were made. I have no doubt but that it was a case of gonorrheal arthritis. Gonorrheal arthritis may be caused by gonorrheal conjunctivitis. In "The Pathology of the Eye" (page 42) Herbert Parsons speaks of gonorrheal arthritis resulting from gonorrheal conjunctivitis. However, the conjunctiva was not the original seat of the infection in this case, as the conjunctivitis followed the arthritis by several days.

As no examination of the joint effusion or of the blood was made, I am not in a position to deny the possibility that the arthritis may have been other than gonorrheal, and that the gonorrheal conjunctivitis may have been due to direct infection by the gonococcus from an outside source, but the clinical picture is against such an explanation.

If we admit the mother's statement, that the child had no

vaginal discharge at the time the conjunctivitis began, and suppose that prior to that time she had had a vaginal gonorrheal discharge (which is not uncommon with little girls, as de Schweinitz and others mention[2]), but that the discharge had been overlooked, through the carelessness of the mother—under these suppositions, an interesting question is suggested. Is there such a disease as a metastatic, endogenous, gonorrheal conjunctivitis?

Metastatic gonorrheal ophthalmia is recognized where the uveal tract and the deeper structures of the eye are involved. De Schweinitz, in his book, "Diseases of the Eye" (page 269, sixth edition), mentions metastatic gonorrheal conjunctivitis, but does not describe it as violent, as was the condition in my case, saying, "The disease is almost invariably bilateral, and resembles a catarrhal conjunctivitis with some swelling of the mucous membrane and redness of the lids." This does not adequately describe my case.

Herbert Parsons, in his book, "The Pathology of the Eye" (page 41), makes no distinction between gonorrheal conjunctivitis and metastatic, endogenous, gonorrheal conjunctivitis in speaking of the two diseases, applying the same description to both.[3]

Gonorrheal arthritis usually occurs in the later stages of a urethritis, three or four weeks or longer after the beginning of the urethritis, sometimes when the urethritis seems to have gotten well, which may have been the condition in my case.

The gonococci are carried by the blood to the joints, where they light up the arthritis.[4] They are found in the subserous tissue and sometimes in the serous fluid of the joints,[5] in the pleural cavity, and often in the pericardial sac.

Considering these facts, is it not probable that the explanation of my case is that gonococci, originating in the vagina, entered the blood; the vaginitis stopped, but the gonococci still living in the circulation found lodgment in

the subserous tissue, or escaped into the cavity of the joints and developed the arthritis, and that about the same time other gonococci lodged in the submucous tissue of the conjunctiva, producing a conjunctivitis, or escaped into the conjunctival cavity and there lighted up an inflammation similar to that which follows the introduction of gonococci into the conjunctival sac from outside sources? This seems to the writer the explanation of this case, and he hopes that this history may lead to further investigation along these lines.

REFERENCES.

1. "Metastasis from a primary gonorrhœal conjunctivitis is much rarer, cases have been proved."
2. de Schweinitz: "Diseases of the Eye," sixth edition, p. 163.
3. "It [gonorrheal conjunctivitis] also occurs as a metastatic infection. It is characterized by an intense chemosis with marked papillary development and profuse mucopurulent discharge."
4. Herbert Parsons: "The Pathology of the Eye," p. 41.
5. Stengel: "A Text-Book of Pathology," fifth edition, p. 248.

DISCUSSION.

DR. F. H. VERHOEFF, Boston: The question of metastatic gonorrheal conjunctivitis and keratitis has recently been discussed by Heerfordt. He maintains that these conditions are much milder than those described as such in the text-books, and that only those cases can be regarded as endogenous in origin in which the discharge is free from gonococci. The conditions described by Heerfordt seem to be identical with certain forms of neuropathic keratitis and with the neuropathic conjunctivitis described by me. The thought suggests itself, therefore, that since gonorrheal urethritis is so common, the eye lesions attributed to it by Heerfordt may not be gonorrheal in origin at all, but due to ordinary herpes febrilis. Against this, however, is the frequent association of gonorrheal arthritis, so that it seems more probable that the eye lesions are due to gonorrheal toxins acting on the fifth nerve or its ganglia. Heerfordt, however, believes that they are due to the direct action of toxins on the cornea and conjunctiva.

DR. ALLEN GREENWOOD, Boston: I want to call attention to a case that I had recently, in which a young woman had

a gonorrheal vaginitis followed by infection of many of the joints, and, a few days later, by a bilateral acute conjunctivitis, the discharge showing no gonococci. A few days later a severe bilateral iritis occurred, which lasted for several months. It seems to me that it was a typical case of metastasis from a gonorrheal infection. Whether any gonococci were present in the joint lesions or those in the iris and conjunctiva, I cannot say.

DR. ROBERT L. RANDOLPH, Baltimore: It seems to me that it would be interesting to examine more closely our cases of ophthalmia neonatorum to find out whether there be any metastatic arthritis. In many cases I fancy that joint involvement would be found. It looks as though it ought to be so in a certain and perhaps a large number of these cases.

DR. T. B. HOLLOWAY, Philadelphia: Observations along these lines have been made in the Babies' Hospital in New York by Dr. Holt, and arthritis was found associated with conjunctivitis and cases of vaginitis. In the series of 129 cases of conjunctivitis occurring in the Philadelphia Hospital, reviewed by me several years ago, no instances of an associated arthritis were found.

DR. B. ALEX. RANDALL, Philadelphia: I should like to ask Dr. Post whether the nasal cavities were examined for nasal infection in his case.

DR. M. H. POST, St. Louis: In answer to the question of Dr. Randall, I would say that the nasal cavities were not examined. From the clinical standpoint, the case was a typical one of gonorrheal ophthalmia. The question it brings up is this: If a gonococcus can escape into a joint, is it not possible that it can escape into the conjunctival sac, and, having entered this, is it not possible for it to light up a conjunctivitis, just as if it had come from an outside source? Would its transit into the conjunctival sac destroy its ability to produce an infection?

A PROTEST AGAINST THE INDISCRIMINATE USE OF THE ORGANIC COMPOUNDS OF SILVER IN OPHTHALMIC PRACTICE.

SAMUEL THEOBALD, M.D.,
Baltimore, Md.

Whatever be the explanation, whether due to their chemical composition, to the greater freedom with which they are used, or to their supposedly greater penetrating power, there can be no doubt that the organic compounds of silver—at all events, those with which I am familiar, protargol and argyrol—are responsible for many more cases of conjunctival argyria than ever was, or is, silver nitrate.

Before these compounds came into use, argyria of the conjunctiva was a rare condition—practically never seen except in old cases of trachoma. Now it is relatively common, and is met with not only in chronic conditions, such as trachoma, but in acute affections as well, in which the silver treatment has been of comparatively brief duration.

I believe I am warranted in saying that I have never produced a case of ocular argyria from the use of silver nitrate. I regret that I cannot say the same as to the newer silver compounds. In several of my cases of gonorrheal conjunctivitis in the adult decided staining, especially of the bulbar conjunctiva, has resulted from the employment of protargol, and the same has happened in a case of acute trachoma, after only a few weeks' treatment.

I have also observed a number of cases of similar character which have occurred in the practice of my confrères. A well-known physician of Baltimore was given a 5% solution of argyrol for a mild chronic conjunctivitis. As its action was beneficial, his wife—in need only of glasses for the correction of a decided fault of refraction—also began to use it, and the

two continued to employ it, p. r. n., until the physician had acquired one of the most marked cases of argyria I have ever seen, and his wife's eyes had become conspicuously stained.

Let me make it plain that I have no unreasoning prejudice against these newer silver preparations. On the contrary, I have such faith in protargol, especially, that for some years I have employed it in the treatment of gonorrheal conjunctivitis, in both the infant and the adult, to the exclusion of silver nitrate, and in trachomatous conjunctivitis, especially in the acute stage, it has also been my chief reliance.

It is, therefore, not against the use, but against the indiscriminate—or, perhaps, I might say undiscriminating—use of the organic silver compounds that I would protest. When a remedy is at hand that is, at least, as efficacious as they are in the condition to be dealt with, that is cleanly, and that cannot by any possibility produce the untoward consequences to which, as has been pointed out, they not rarely give rise, common sense would seem to dictate that it be given the preference.

These observations apply with especial force to the now almost, it would seem, universal habit, particularly among the younger generation of ophthalmologists and of general practitioners, as well, of employing argyrol or protargol in the treatment of acute and chronic catarrhal conjunctivitis. This practice, in my judgment,—and it is based upon abundant observation,—is wholly indefensible, since we have a remedy—in a collyrium containing ½ grain of zinc sulphate and 10 or 12 grains of boracic acid to the ounce—that is cleanly, and that is not simply as efficacious, but is more surely and more promptly efficacious in these conditions than either of the silver compounds mentioned.

DISCUSSION.

DR. LUCIEN HOWE, Buffalo: I wish simply to call attention to a point which Dr. Theobald did not mention. It is,

that a very excellent report concerning the preparations of silver was made about five years ago by a committee of the Section of Ophthalmology of the British Medical Association. Those who are at all interested in the subject will gain a great deal of information by glancing at this report. It was a revelation to me, at least, to learn that the proportion of silver in these compounds varies very much. In silver nitrate it is 63.6 per cent., whereas in protargol, for example, it is about 7.4 per cent. If these compounds are as efficacious as some think, it is not due to the amount of silver they contain.

In a word, I simply want to corroborate in a feeble way what Dr. Theobald has said: Before adding to the advertising of these various proprietary compounds, it would be well to examine our records more exactly to see whether we do get the results that we imagine, and whether we could not have as good results from other preparations already known for many a year.

DR. ALEXANDER DUANE, New York: I want to say a word in defense of argyrol. I wish to second what Dr. Theobald has said. I use argyrol mainly for its detergent effects. In using solutions in the eye, the only antiseptic that has a practical value is nitrate of silver, a substance that has been shown to have a strongly antiseptic action in the limits of time in which a solution in the eye can act. Bichlorid of mercury has been shown to require too prolonged an action to be of service in the eye as an antiseptic. Therefore we are thrown back on detergent solutions. As a detergent solution, argyrol has an important value. It searches out all the recesses of the conjunctiva, it stays in the conjunctiva a long time, and it is heavy and drives the secretions before it. Therefore I have used argyrol with great satisfaction in the two following conditions: first, when there is a more or less considerable amount of secretion that must be expelled from the conjunctiva; and, second, in lacrimal cases in which there is obstruction of more or less recent origin. In the latter class of cases the specific gravity seems to me the important factor. After dilatation of the canaliculus, and syringing with adrenalin and cocain, I direct the patient to use the argyrol. In doing this I tell him to wash out the conjunctiva with salt solution, then put

in the argyrol and wait a few minutes, then wash that out, and then again put in another drop of argyrol. Used in this way, I find it to work very well in acute cases in which there is secretion, and also in acute obstruction of the lacrimal duct. I have never had but one case of argyrosis, and that was from syringing argyrol into the sac, and I do not believe that any one does that now. While I agree with Dr. Theobald that in a chronic case argyrol is contraindicated, yet I believe that in these two classes of cases it has important advantages over most solutions. I am careful, however, to keep the patients under observation and not to allow them to use the solution themselves for more than ten days continuously without being seen again.

DR. W. B. JOHNSON, Paterson: It seems to me that there is a decided advantage in the use of nitrate of silver. In the first place, you know the strength in each instance. In the second, by long usage you know that there is great benefit derived from it, and very little danger of argyrosis. I believe that these proprietary medicines are not what we have been led to believe them to be. I myself made a very considerable number of experiments in the treatment of ophthalmia neonatorum with argyrol and protargol when these first came out, and I am not prepared to say that the effect was as good as I had had previously from the use of nitrate of silver. I still generally use silver from 2% to 40%, and do not see why, because a particular firm of druggists has chosen to exploit a particular form of silver, for which extravagant claims are made, we should seize upon it as a panacea for all the troubles that the eyes are heir to.

DR. SAMUEL THEOBALD, Baltimore: While it is true that the organic compounds of silver contain a much smaller percentage of the metal than silver nitrate, this, so far as the production of argyria is concerned, is more than offset by the fact that they are used so much more freely and frequently and in solutions of so much greater strength. I am a firm believer in the value of protargol in gonorrheal conjunctivitis for both adults and infants. A possible argyria is of secondary importance in so serious an affection, if we have a more trustworthy therapeutic agent. To be efficacious the protargol must be used freely, a 5% to 10% solution being applied every three or even every two hours.

THE OPERATION OF EXCISION OF TARSUS AND CONJUNCTIVA (HEISRATH) IN OLD TRACHOMA, TOGETHER WITH DEMONSTRATION OF A NEW INSTRUMENT, AND A DESCRIPTION OF A NEW METHOD OF PERFORMING IT.

J. HERBERT CLAIBORNE, M.D.,
New York.

In the "Archives of Ophthalmology," March, 1910, Dr. H. W. Wootton described the combined excision of tarsus and conjunctiva in cases of old trachoma as performed by Heisrath, and accompanied it with illustrative diagrams. He referred to the present status of this surgical procedure, particularly in eastern Prussia. He also referred to the exsection of the tarsus without the sacrifice of the conjunctiva. He pointed out that these operations had met with but little favor outside of eastern Prussia, where they have been performed for the last ten or fifteen years. They are said to have yielded from 50% to 60% of cures and to have practically afforded immunity from infection.

Kuhnt, who was at first an opponent of excision, became an ardent advocate of it, first through necessity, and secondly by reason of the success the measure found in his hands. It is rather natural that any such radical surgical procedure as this should have had its origin in eastern Prussia, which is one of the most fertile soils for trachoma. Conversely, it is not surprising that the procedure should have found small favor in England and America, to which countries, it may be said, trachoma is not indigenous. The great success which has been attained in this country in

the treatment of trachoma by expression has naturally led surgeons away from a more radical procedure.

Expression has been considered as indicated in trachoma which is in the florid stage, or in that which is marked by cicatrization with abundant granulations.

It is well known, however, that in the later stages of trachoma the results from expression are disappointing. Those of us who have kept careful records of our cases know that trachoma recurs after the most thorough expression even in selected cases. Whether this is due to infectious material being left after the operation or to reinfection endemically from the same source, it matters not. It is simply a fact.

When the paper of Dr. Wootton was read at the New York Academy I opened the discussion on the subject. A number of cases were shown in which the operation had been performed, and I observed that granulations persisted in many cases. Nevertheless it was asserted that the cases had been much benefited. Of this point at that time I could not convince myself, as I had not seen the cases before. But I could see that keratitis was lacking in the majority of them or was slight in degree, and that there was no pannus, though I had been informed that all these symptoms had been present.

Now, it was claimed that the operation had cured the disease, whereas if granulations of a typical character on the conjunctiva constitute trachoma, the disease was not cured. I confess I returned from the discussion with grave doubt as to the efficacy of the operation and a profound conviction that it was a bad surgical procedure to remove the tarsus and overlying conjunctiva. Nevertheless, in view of the evidence of several reputable witnesses, I determined to try the operation.

The first case on which I tried it was that of a young man of twenty-six, an Irishman, who had had trachoma from

childhood. There were no granulations whatever on his lids, but his right cornea was in a condition of ulceration with mild pannus. His upper lid was much scarred and contracted, and his fear of light was so great that he had not been able to work at all for more than a year. I persuaded him to let me do the operation of combined excision, describing the nature of it and the status of opinion in regard to it. Subsequently I performed the combined excision on his right eye. The operation was ragged, owing to my lack of knowledge of the technic; but, to cut the matter short, in a month the eye had healed, his pain and fear of light were gone, and he went to work. He was comfortable, and at the end of several months asked to have the other eye done. He is now happy, entirely without pain, and is a useful member of the body politic. Without the operation he could never have been so, in my opinion.

It is unnecessary to go into details of other cases. Suffice it to say they were cases of old trachoma marked by ulcerative pannus, fear of light, pain, and dim vision. A number of them had persisted for many years—three from childhood. Remarkable results as to relief of all these symptoms were obtained in all the cases, and no other means, I believe, could have achieved the same results. All the operations were done by my colleagues and myself at the New Amsterdam Eye and Ear Hospital. Dr. Wootton thinks "the combined excision is indicated in the severe trachoma of adults, *in all stages except the cicatricial* [italics my own—J. H. C.], and is especially to be recommended when corneal complications are threatening or present."

I feel compelled to take marked exception to this view in some respects. If there is one class of cases in which the combined excision is indicated, it is in the purely cicatricial or the cicatricial form combined with granulations. Indeed, I consider it indicated in all cases of trachoma, such as are known to us all, in which cicatrization has commenced

and pannus and keratitis are present. I think it ought not to be performed in any case in which granulations are sufficiently abundant to justify expression, unless the disease has several times repeated itself after operation.

In order to illustrate his article, Dr. Wootton shows a case of exuberant granulations apparently without cicatrization. The picture is doubtless schematic, but it illustrates just the kind of case which, in my opinion, is suited for expression, and in which the combined excision is contraindicated. Perhaps it might be advisable to operate on such a case in eastern Prussia, but certainly not in New York, until expression has been thoroughly tried and has failed.

It is no light thing to remove the tarsus and the overlying conjunctiva in any case, and if it is done, it should be only as a last resort.

It may be argued that blue-stone will cure such cases as I have described, and that therefore combined excision is not indicated in them either. To that I would answer that blue-stone, with rare exceptions, never does cure trachoma, for such cases do not remain under care long enough to be cured. Most of our cases are of years' standing, as a rule occur in old people, and radical means are justified by the circumstances.

Just here I wish to declare myself as opposed to the resection of the tarsus without sacrifice of the conjunctiva. In those cases in which it is possible to resect the tarsus and leave the conjunctiva, I believe expression should be employed, for I am abundantly convinced that it is not possible to resect the tarsus successfully when cicatrices have formed. If expression fails, the combined excision is indicated. I wish to oppose also the combined excision or the resection of the tarsus of the lower lid. I cannot conceive why it should be done. It is well known that all the harm done the eye in trachoma is caused by the upper lid, and that the lower lid does none except at times when it is the site of symblepharon bands.

I have seen a case recently in which there were pannus, keratitis, ulcers, and symblepharon on upper and lower lids. The combined excision was done on the upper lid, with complete relief of all symptoms, which had persisted for forty years. The lower lid was not touched, and the bands are still present, but there is no discomfort. If there are granulations on the lower lid, they should be expressed; if none, they should be let alone. We are all inclined to carry radical measures too far when once we become radical.

I have seen the method of Heisrath, as described by Dr. Wootton, performed by several surgeons, and I have done it a number of times myself. It is tedious, bloody, takes a long time, and requires a number of hands besides those of the operating surgeon.

The operation as indicated below by means of my clamp forms a striking contrast to the method of Heisrath. It is only necessary to have an assistant to hand the instruments and sutures. The operating surgeon's hands alone are around the eye.

The clamp as shown is the final result of a number of experiments. I several times tried a clamp without spikes, but it slipped from the lid after the plate had been screwed down. The suggestion as to the spikes was made by my colleague, Dr. E. B. Coburn.

In a recent issue of the "Ophthalmoscope" there was published a picture of a clamp made for this purpose by Cyril Shepherd, of Australia. Shepherd and I evidently had the same idea, but from the picture which he published, I cannot understand how the operation could be successfully performed. The plate in his instrument is too large, and it could not hold the lid in position. I tried his idea during the process of my experiments, but it failed utterly. This was before I had seen the cut of his instrument.

I read my paper and showed my instrument before the Section on Ophthalmology, New York Academy of Medicine,

on December 19, 1910, whereas his article was published in the "Ophthalmoscope" on February 1, 1911. It happens, therefore, that I have the priority in the matter of publication.

My experience in this operation convinces me that the tarsal cartilage in a cicatricial state is the cause "of all our woe" in old trachoma—but only in the cicatricial state. It

Fig. 1. Fig. 2.

may be said approximately that *the tarsus is old trachoma.* I frankly believe that all the granulations possible in an eye from which the tarsus has been removed could not produce the picture which we know as old trachoma or destroy the sight of the eye. Without the tarsus, I believe the granulations are practically innocuous.

This would appear to be an argument in favor of the Auschällung of Kuhnt, but really it is not, since non-cica-

tricial trachoma can always be cured finally by expression combined with proper after-treatment.

The clamp (Fig. 1) is in effect a modification of Desmarre's. It consists of a fork with five spikes, four as seen in the cut, the other at the base, where the shank branches. The plate upon which the fork descends is of metal and is 4 mm. shorter than the forks. The spikes fit into fenestræ. These fenestræ are made primarily to receive the spikes when the clamp is closed and not in use. The shank is curved to fit over the brow.

Fig. 2 shows the clamp in the primary position. To enter the prongs accurately and successfully it is well to lift the center of the lid by grasping it with a pair of conjunctival forceps or the fingers. The right prong is then slipped under the lid and the left one afterward. Both prongs are now thrust well toward the supraorbital ridge. The prongs being well in position and the skin having been smoothed out, the fork is screwed tightly down by the ratchet upon the lid.

The clamp is then reversed and laid over the brow, as in Fig. 3. The conjunctival surface of the lid is now exposed and the section is made as shown by the continuous line. The curve of the prongs is the guide of the incision, and it should commence well down on one side and be carried over to a corresponding position on the other. As the knife cuts down upon the tarsus the latter springs away from the underlying tissue by virtue of the tension. The tarsus with overlying conjunctiva is dissected up and the conjunctiva of the fornix is well loosened by further dissection, to gain slack. This is to relieve pull when the conjunctiva is stitched to the lid. Owing to the pressure, the hemorrhage amounts to nothing.

The stitches are inserted as in Fig. 4. The line of the stitches lies parallel with the lower edge of the tarsus, and not at right angles to it. The threads are double-armed and

should be about 10 inches in length. They should be placed on a tray together with a needle-holder, separate from the rest of the instruments. The central sutures are put in first. The dissected tarsus, covered by conjunctiva, being grasped by the forceps and slightly put on the stretch, one needle and then the other is passed through the fornix conjunctiva, just below the dotted line indicating the limit of the tarsus, and both threads are laid on the center of the brow. The

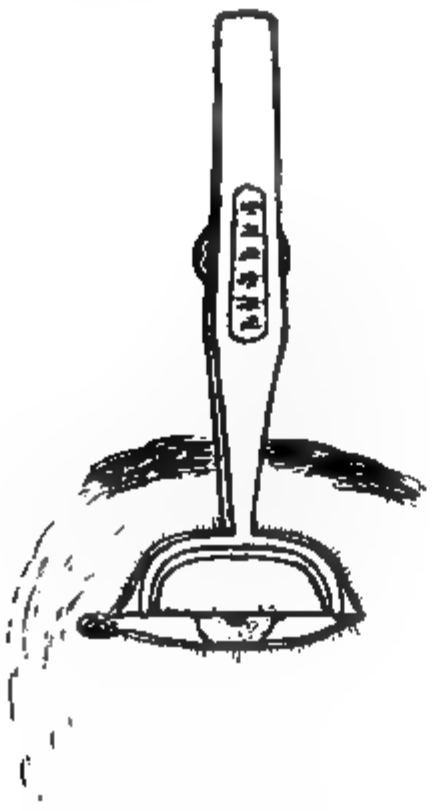

Fig. 3.

Fig. 4.

lateral stitches are next taken, and they too laid on the brow, care being taken to draw the nasal ones toward the nose and the temporal ones toward the temple. This is, of course, done to prevent the mixing of the threads. The tarsus is now grasped by the forceps, lifted slightly, and is cut away with a pair of scissors just above the line of the suture. The clamp is then removed. A slight bleeding takes place, but it ceases in a few seconds. The sutures are now laid upon the cheek, the center of the lid is grasped by a pair of

conjunctival forceps, and the needles of the middle sutures are passed through to the cutaneous surface, emerging on the skin 4 to 5 mm. above the ciliary border of the lid. The needles of these sutures are removed and the sutures arranged neatly in the center of the forehead. The lateral ones are then put in in a similar manner, but lie 2 to 3 mm. nearer to the lashes than the middle ones.

Fig. 5 shows very clearly the position of the sutures after the tarsus has been excised as one looks upon the everted lid. Fig. 6 shows the appearance of the sutures when they have

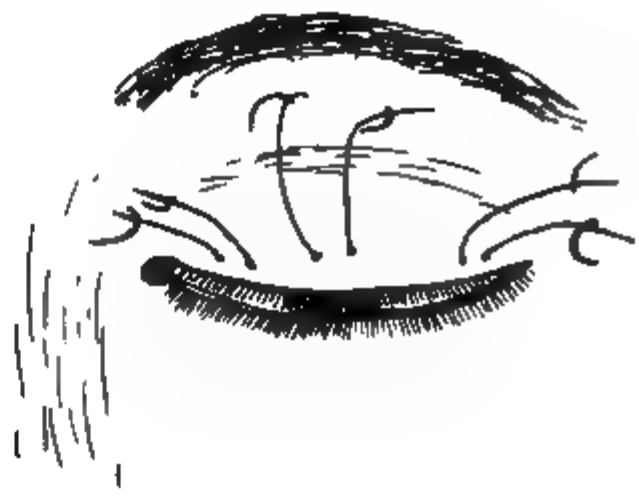

Fig. 5.

Fig 6.

emerged upon the cutaneous surface. It has been my custom of late, however, to pierce the skin still a little further away from the lashes in case of both lateral and central sutures. My object in carrying the central sutures a little higher than usual is to increase the depth of the upper cul-de-sac to prevent symblepharon and to prevent the lifting of the center of the lid, which is apt to occur if the central stitches are placed too near to the lashes. The stitches are tied upon small rolls of wet cotton to prevent them from cutting into the skin and to facilitate their removal. This done, the frayed ends of the cotton rolls are cut off neatly

and the operation is finished. The entire operation can be done in ten to fifteen minutes.

This method of performing the combined excision differs from that performed by the Kuhnt-Heisrath method in several respects:

1. It is practically bloodless.
2. It can be performed in ten or fifteen minutes.
3. The extent of the incision is outlined by the curve of the forks of the clamp.
4. The line of the sutures is not at right angles to, but is parallel with, the border of the lids.
5. The central sutures are set further from the ciliary region than in the other operation; in this way the tucking of the lid in the center is avoided and a deeper fornix insured.
6. The hands of the operator alone are around the eye.

DISCUSSION.

DR. D. W. HUNTER, New York: I have a device invented by my office nurse, who is also the operating nurse at the infirmary, and who designed this little instrument in 1909. It works beautifully in the operation of Heisrath and in resection of the palpebral portion of the lacrimal gland. It is very simple, and works without the slightest trouble.

DR. M. L. FOSTER, New Rochelle: I have had a little experience with this operation of which Dr. Claiborne speaks, though not with his instrument, and I cannot agree entirely with the view that it is an operation for adults alone. Provided that one can make a positive diagnosis of trachoma, I think that it may be employed for either adults or children. It is certainly contraindicated, however, in the doubtful cases in which it is a question whether the condition present is trachoma or the harmless folliculosis of schoolchildren. In the case of a girl of sixteen years with trachoma, ulcerative keratitis, and well-marked pannus, the performance of this operation cleared up the pannus and the ulcerations immediately, and left the cornea almost clear. I have watched this patient for two years since the operation, and she has had no recurrence. I think the

operation of combined excision is indicated whenever there is severe chronic trachoma with pannus and ulcerative keratitis. Kuhnt's excision of the cartilage is indicated, to my mind, in an entirely different class of cases—not at all in those in which there is any trachoma left, but only when the entire conjunctiva is changed into a cicatricial mass, and there is practically no retrotarsal fold left and the tarsus itself is distorted. I have found that trichiasis and entropion may become corrected of themselves when such a distorted tarsus has been removed. That is the indication for Kuhnt's operation, to remove a cicatricially distorted tarsus and so obviate the troubles dependent thereon.

DR. J. HERBERT CLAIBORNE, New York: I have seen the instrument constructed by the nurse mentioned by Dr. Hunter, and I had made what I think was almost a counterpart of that instrument, but tried it a number of times without success. This experience led me to roughen the surface of the clamp. I must give my former friend Dr. Coburn the credit for priority in the idea of the spikes. I do not see how the operation can be performed unless there are spikes to hold the clamp still. I should employ this procedure only in old cases of trachoma with cicatrices. It is absolutely wrong, I think, to remove the conjunctiva in a florid case of trachoma, which can usually be cured by expression. I have also used this operation in one case of horny granulation, so-called summer catarrh, and the patient was much improved, though not cured, as the retrotarsal fold was entirely infected. He now comes for treatment only once in every three weeks, whereas he formerly had to come three times a week. I think this operation is indicated not only in cases of old trachoma, but in those of horny granulations.

A CASE OF RING SARCOMA OF THE CILIARY BODY.

A. N. ALLING, M.D.,
New Haven, Conn.
AND
ARNOLD KNAPP, M.D.,
New York.

Diffuse or infiltrating sarcoma of the uveal tract, known as flat sarcoma, as distinguished from the circumscribed isolated tumor formation, was first defined by Fuchs in 1882. That form which involves the ciliary body and iris was first described by Ewetsky in 1898, and called by him ring sarcoma. About forty-five of the former variety are on record and about a dozen of the latter. The following is the history of a case of ring sarcoma:

Mary O'Brien, aged sixty, consulted me on January 15, 1911, complaining that she had been gradually losing her vision in the left eye during the past two years and that it was now totally blind. About one year after the first blurring appeared, she noticed some dark spots on the sclera. She had had but little pain.

The examination showed no congestion, a clear cornea, a somewhat shallow anterior chamber, and the pupil moderately dilated and immovable. On the iris was some pigmentation, especially at the periphery. The lens was cataractous. Tension was +2, and there was no perception of light. On the sclera, below and to the nasal side, nearly touching the cornea, was a slightly elevated, irregularly elliptical tumor, about 12 mm. in its longest diameter. Two other tumors of the same sort were seen above the horizontal meridian at varying distances from the limbus. Transillumination gave a deep shadow over the ciliary region, and in general as far back as the equator. There was no history of traumatism. She was advised to have the eye removed at once, and she entered the hospital on the follow-

ing day. A physical examination showed the urine to contain a trace of albumin, a few casts, and white blood-cells. There was a systolic murmur and the heart was enlarged to the left. The liver did not extend below the costal border, and its lower edge was smooth. The arterial blood-pressure was 160 mm. There were no glandular enlargements.

The eye was enucleated with a portion of the optic nerve, but no masses were felt in the orbital cavity. Four months after the operation no recurrence or metastases were apparent.

Pathologic Report (Dr. Arnold Knapp).—On the anterior scleral surface of the eyeball there are three black, irregular, flat elevations (Fig. 1). Two of these are next to the cornea; the third is some distance posterior.

After dividing the eyeball in the equator and looking at the reverse side of the anterior half (Fig. 2), the whole region of the ciliary body is seen occupied by a flat black mass which ceases irregularly between the equator and the ora serrata, except at one point, where the mass extends back nearly to the optic nerve.

The eyeball was fixed in formol, hardened in alcohol, and cut for microscopic examination after embedding in celloidin. A cross-section through the thickened part of the ciliary tumor reveals the following macroscopic changes: From the equator anteriorly within the sclera is a black tissue which involves the choroid and gradually increases in size to attain a thickness of 1 mm. in the ciliary body. At a point posterior to the ciliary body this has invaded the sclera and is indirectly continuous with a small black extraocular mass, superficial to the sclera. On the opposite side of the section the black mass in the choroid rapidly increases in size and forms a tumor, 5 mm. anteroposteriorly and 1.5 mm. thick, at the junction of ciliary body and iris. On the sclera over this part of the ciliary body is a rounded, flat black mass—an episcleral tumor.

Microscopically the mass is a pigmented structure which only occasionally permits the recognition of anatomic detail. It is made up of spindle cells in characteristically interlacing bands and invades principally the uvea. In the region of the greatest infiltration, at the base of the ciliary body on one side, the cells are fusiform and pigmented.

Among them and in other parts of the tumor deep black pigment is present in round, ball-like masses. These round pigment deposits are crowded together in some places, making a pitch-black mass; in other places they are arranged in irregular groups or in strings. The epibulbar nodes are moderately pigmented. In depigmented sections (Alfieri's method; permanganate of potash and oxalic acid) a much better idea of the nature of the cells is possible, and the exact infiltration of the tumor determined.

The tumor reaches its greatest development at a place where the ciliary body and iris are both involved, so that nothing of their original structure is visible. The adjoining angle of the anterior chamber is filled with the tumor. The tumor infiltration has everywhere invaded the pectinate ligament and is prolonged along Descemet's membrane and has extended into the ciliary processes, which are crowded together. Occasionally the tumor appears less dense, and these spaces are occupied by peculiar cells with large, round, protoplasmic bodies and a small round nucleus (Fig. 4). They are the carriers of the deepest pigment and resemble the free pigment cells of Fuchs.

"Free pigment cells" is a term which Fuchs introduces in his recent article on "Sarcoma of the Choroid" (von Graefe's "Archiv," vol. lxxvii, No. 2, 1910). These cells are round, large cells with coarsely granular pigment, which occupy no particular relation to the other pigment cells. Their nuclei are much too large for endothelia, nor are they ever found in the latter's characteristic alveolar grouping. In this specimen they seem to be derived from the spindle cells, though no direct transition was found. They practically develop where the looseness of the tissue permits them to assume their enlarged round contour. With this growth the increased pigmentation occurs, and then, their life-cycle being short, they are prone to undergo necrosis. These cells lie mostly in the infiltrated iris, and in that part of the ciliary body between the muscle and the processes. In two other regions just posterior to the ciliary body, and at another

FIG I
Episcleral nodules

FIG II
Showing extent of involvement of the ciliary body.

farther back, the tumor is composed entirely of these cells and has undergone necrosis. The cell contours are lost, the nuclei are degenerated and smaller, often lying free in a mass of homogeneous detritus. In the periphery and scattered throughout this area there are well-preserved examples of these free pigment cells. In one of these regions the tumor has diffusely infiltrated the sclera and formed an episcleral nodule. The necrosis has attacked some of the intervening scleral tissue. The retina in these regions shows inflammatory and degenerative changes.

The areas of necrosis in this tumor are characterized by diffuse and deep pigment. In the depigmented sections these areas are entirely made up of these peculiar cells and their degenerate and regressive forms. The necrosis is readily explained by the lack of blood-supply, the tumor itself being unusually free from blood-vessels, wherein it, of course, differs from the usual choroidal sarcomata. The inflammatory changes (iridocyclitis) which are so frequently associated with necrosis are lacking, except for a few discrete episcleral collections of leukocytes and the optic neuritis, the external surface of the sclera showing several inflammatory foci and the optic nerve being cupped and inflamed. In the anterior half of the eye there are no inflammatory signs.

This flat and ring-like extension of a tumor distinct from the circumscribed variety has several now well-recognized characteristics. It is a striking example of a tumor growing within the boundaries of its original host—the uveal tract in this instance. In its invasion the suprachoroidal space is obliterated. The tendency to form episcleral nodules at either the site of the perforating vessels or where the sclera is eroded is pronounced, while Bruch's membrane forms a barrier to inward growth. Parsons explains this extension by the growth invading principally the outer layers of the uvea and so gaining access early to the suprachoroidal space.

In the above ring sarcoma the endothelial character of the cells is lacking, a feature which Parsons also speaks of.

Remarks.—The question as to whether the ring is entire or whether the tumor affects only the iris may be of little importance pathologically, for we know that the tendency of these growths, wherever their origin, is to invade the whole uveal tract sooner or later. It may be useful, however, to divide the cases topographically into those in which there is a complete, and those in which there is an incomplete, ring sarcoma, and to designate whether it includes the ciliary body, the iris, or both.

If we confine ourselves to the reported cases in which a diffuse growth was present in the form of a complete ring, involving the ciliary body, apparently originating therein, with or without extension to the adjacent portions of the uveal tract, I have been unable to find but eight examples of this sort. A few cases are on record in which the ciliary body was only affected in part, as, for example, some of the cases described by Ewetsky and Meyerhof, others where the iris was principally involved, as those of Nettleship, Hanke, and recently A. Alt.

A brief description of the cases of complete ring or annular sarcoma of the ciliary body is here given.

Ewetsky's[1] is the first case on record, and was in a woman of thirty, from whose iris a melanosarcoma had been removed eleven years before. There were three pigmented spots under the bulbar conjunctiva and areas of pigment on the iris. A circumscribed tumor was found behind the lens, springing from the ciliary body. The ciliary body and also parts of the iris were infiltrated with sarcoma cells in a complete ring. It was a round- and spindle-celled myxosarcoma.

Von Rechtperg[2] describes a case in a male of twenty. There were brown spots on the iris and ectropion of the pigment layer at the pupillary edge. Nine years later the eye

FIG III
Showing the general topography of the tumor invasion

FIG. IV.
Showing free pigment cells in among spindle cells.

was hard, blind, and painful. The iris and ciliary body were found infiltrated, with a deeply pigmented sarcoma.

Meyerhof[3] saw the case of a woman, aged sixty, in which the ciliary body and iris, as well as the angle of the anterior chamber, were involved in the whole circle. It was a spindle-cell melanosarcoma.

Meyerhof also relates another case, giving neither sex nor age, in which a primary tumor of the iris extended to include the whole ciliary body in a ring. It was composed of pigmented polygonal and spindle cells.

In Parsons'[4] case, a boy of fourteen, who was injured seven years before, there was ciliary staphyloma and a growth 2 mm. thick infiltrating the whole circle of the ciliary body and the iris. There was also involvement of the cornea and sclera. It was a spindle-celled leukosarcoma.

Werner[5] reports the case of a male aged eighteen, with a tumor affecting the whole ciliary region, having abnormal pigmentation of the iris. The ligamentum pectinatum and Schlemm's canal were full of pigmented cells.

Wintersteiner[6] saw an eye from an old woman showing episcleral growths overlapping the cornea. The ciliary body was entirely invaded, but there was no thickening of the iris.

Bergmeister's[7] case was a man aged sixty-one. The entire ciliary ring with the iris was affected. There was pigmentation of the iris and cataract. The growth had in one place broken through the epithelium and was pressing against the equator of the lens.

If we further examine the histories of the cases of ring sarcoma, we find that *glaucoma* was present in every one except that of Bergmeister. The high tension, usually having an early onset, has been generally attributed to the involvement of the iris angle and closure of Fontana's spaces. In the present instance this might suffice for explanation, since the ligamentum pectinatum was everywhere infiltrated. It seems probable that many of these tumors are overlooked,

for the eyes are likely to pass into the condition of absolute glaucoma, and the macroscopic findings are not striking on account of the diffuse character of the lesion.

In only three cases is an *external growth* mentioned, the proportion of episcleral extension being somewhat greater in flat sarcoma of the choroid. The perforation appears to take place by means of the scleral vessels, but may also, as partly in this case, be through erosion of the sclera.

In about half of the cases there was associated with the diffuse growth a definite circumscribed *intraocular tumor*, presenting either into the vitreous or into the anterior chamber at the iris angle, and in all of them this was probably the site of the original growth. In the present case, although there was one area of greater thickening, there was no such well-marked tumor.

Practically all showed spindle cells, and in some cases endothelioid cells are mentioned. This has led some authors to classify the flat sarcoma as an endothelioma, as does Parsons. Most of the cases were pigmented.

BIBLIOGRAPHY.

1. Ewetsky: Arch. f. Ophth., vol. xlv, 3.
2. Von Rechtperg: Arch. f. Ophth., vol. lii, 2.
3. Meyerhof: Klin. Monatsbl. f. Aug., vols. xxxix and xl.
4. Parsons: Arch. of Ophth., 1904.
5. Werner: Trans. Ophth. Soc. Unit. King., vol. xxv.
6. Wintersteiner: Zeitsch. f. Aug., Sept., 1907.
7. Bergmeister: Arch. f. Ophth., vol. lxxv.

DISCUSSION.

DR. ROBERT L. RANDOLPH, Baltimore: I am very glad to have heard this paper. I feel sure now that a case which I saw six weeks ago would come in this category. I did not recognize it as such at the time, but I was struck by the fact that I had never seen such an intraocular condition before, and from its close resemblance to the drawing which Dr. Alling exhibits I have no doubt but that the case is similar to the one just reported. The eye tension was a striking characteristic of the case throughout the clinical

history. There were several of these little dark elevations over the site of the ciliary body, forming almost a circle in this situation. When the eye was opened, these little points looked like glands distinct and separate from one another.

It is rather surprising how seldom we find high tension in an eye which contains a sarcoma. In a total of thirty-six cases of intraocular sarcoma I doubt whether I found an elevation of tension in six, and in most of these cases there was, if anything, perhaps slight minus tension. In connection with this subject of intraocular sarcoma I think that this condition should be searched for in every one of our refraction cases, especially in adults, and no thorough search can be made without a dilated pupil. Three of my cases were in individuals who consulted me about their glasses and who came simply to have them changed, and in every case the vision was normal. The growth was discovered in the regular routine examination with the ophthalmoscope with the help of a mydriatic.

DR. E. FUCHS, Vienna: I should like to say a few words about ring sarcoma, of which I have seen four cases, three of them in my pupils' patients and one in a patient of my own. In all these cases the iris was altered, but not in the way of a circumscribed tumor. It just showed a swollen condition and a changed color. In these cases it is often impossible to make the diagnosis of sarcoma.

The first case was in a young man with a glaucoma in one eye. This was treated, but ten or fifteen years afterward I had to excise the same eye, still taking it for a case of glaucoma, and found that it was a ring sarcoma. The growth in that case was very slow, ten or fifteen years having elapsed between the time the case was first seen and the excision of the eye. Even at the time of the operative procedure there was only a faint ring sarcoma of the ciliary body of the eye present.

DR. F. H. VERHOEFF, Boston: Dr. Alling says that obstruction of the filtration angle by the growth of the tumor was the most probable cause of the glaucoma. Such obstruction can occur either by direct extension of the growth from the uveal tract or by metastases from the aqueous, as in a case I have reported. This would seem to be an

obvious explanation, but the difficulty is that the iris is pushed forward and annular synechiæ are found, just as in primary glaucoma. According to our present ideas, if you have primary obstruction of the filtration angle, the anterior chamber ought to be deepened, as it is in buphthalmos. Therefore it seems probable that in these cases of sarcoma of the ciliary body glaucoma is primarily due to some cause other than obstruction of the filtration angle.

EXHIBITION OF SPECIMENS.

PROFESSOR E. FUCHS,
Vienna, Austria.

NEUROMA OF THE CILIARY NERVES.

I have found small neuromata in two atrophic eyeballs. The *first* case was one of atrophy after iridocyclitis, which had occurred twenty years ago without any known cause. The ciliary nerves, which run under the choroid, are here considerably thicker and form within the ciliary body several neuromata, one large, the others very minute. The large one is enveloped in a sort of capsule formed by the compressed connective tissue. It is not a spindle-shaped thickening of a ciliary nerve, but it hangs on the nerve like a plum on the stem (Fig. 1), and from its anterior pole a small nerve emerges, which runs its course forward between the bundles of the ciliary muscle.

The neuroma is composed of medullated fibers, with scarcely any connective tissue between them. Weigert's stain exhibits a greater variety of the fibers in size as in normal nerves, the small fibers being unusually numerous. The medulla stains less deeply, and the axis-cylinder is not so marked as in normal cases.

The *second* case is one of old iridocyclitis after perforating

Figs. 1, 2, and 3.—Neuroma of the ciliary nerve.



Fig. 4.—Smallest sarcoma of choroid

ulcer. Here a small, knotlike thickening is present on one of the ciliary nerves lying in the detached choroid (Fig. 2). Its structure is similar to the neuroma in the first case.

In both cases the minute tumors are composed nearly exclusively of nerve-fibers, so that they are genuine neuromata, not neurofibromata. Genuine neuroma is very rare; it is chiefly met with at the severed ends of the nerves in amputations.

With reference to the eye, Naito (von Graefe's "Archiv," vol. liii, p. 162) records the presence of numerous new formed medullated ciliary nerves in an atrophic eye, and Vietti (von Graefe's "Archiv," vol. xlix, p. 190) found new formation of nerves after neurotomy of the optic and the ciliary nerves. Most of the new-formed nerves are situated in the cicatricial tissue behind the eyeball, but some nerves also penetrated through the sclerotic into the eye. In my first case there is also a thickening of the ciliary nerves in general; but, besides, there exists in both cases a well-defined small tumor composed of nerve-fibers, a genuine neuroma, which has never been recorded in the eye as yet.

SMALLEST SARCOMA OF THE CHOROID.

I desire to demonstrate three cases, which I believe to be the smallest specimens of choroidal sarcoma hitherto known.

The *first* case was a man of twenty-six, who during life exhibited a choked disc and who died with the symptoms of a tumor of the brain. The postmortem proved a cysticercus in the fourth ventricle to be the cause of death. The small sarcoma (Fig. 4) is seated on the temporal side of the papilla, a little beyond the fovea and a trifle lower. Its diameter in the horizontal as well as in the vertical direction is between 0.7 and 0.8 mm.; its thickness, 0.15 mm. It consists of long spindle cells, which contain a few pigment granules of light brown color, so that the neoplasm on the

whole does not look brown. Most of the tumor is situated between some small branches of the ciliary arteries and the veins in front of the arteries, so that the tumor doubtlessly originated in the layer of gross vessels. It is everywhere separated from the sclera by layers of the suprachoroid membrane, and in front extends only as far as the outer side of the capillary layer; only in one point does it penetrate through it up to the elastic membrane of the choroid, which fact has perhaps to be considered as the very first step to an aggressive growth.

The *second* case was that of a woman of sixty-seven years, whose eye had been excised for glaucoma. The sarcoma is located at the nasal margin of the optic disc; its diameter is 1.25 mm. in the vertical, 1.5 mm. in the horizontal, direction; the thickening of the choroid at the site of the tumor is not more than 0.09 mm. The tumor consists of deeply pigmented fusiform cells, and springs from the layer of gross vessels; it extends in front to the capillary layer and in many places even not as far as that, the intermediate layer of small arteries and veins being preserved.

The *third* case was a man of thirty-seven, whose eye had been excised for suppuration of the cornea after an injury. The sarcoma is seated on the temporal side, in the horizontal meridian, a little behind the equator of the eye. The antero-posterior diameter, which is the greatest, measures 2.25 mm.; the vertical diameter is about 1 mm., and the thickness of the growth only 0.25 mm., so that the choroid attains at the site of the tumor about double its normal thickness. As the pigmented epithelium and the choriocapillaris are normal over the sarcoma, no change whatever would very likely have been visible with the ophthalmoscope.

Where the sarcoma is thickest, it reaches from the suprachoroidea to the choriocapillaris, but toward the border it spreads farther only within the layer of large vessels. It is composed of short spindle cells, generally unpigmented, and

only in the center of the tumor is a focus of pigmented spindle cells.

The question arises, is it fair to consider these small tumors as *sarcomata?* The only positive evidence would be the presence of an aggressive and destructive growth, which, however, could not be expected at such an early stage. So we must base the diagnosis upon the description of the cells composing the tumor. A single accumulation of chromatophores would rightly be termed a *nævus*, and not a sarcoma, and, if I take my cases to be sarcoma, I have to show that the cells are different from chromatophores, as is, indeed, the case. In the first case we find closely packed spindle cells with scarcely any pigment, while the chromatophores of this eye are ramified and richly pigmented. In the second case the pigment cells composing the tumor have partly assumed a polygonal shape, and lay contiguous to one another like epithelial cells. For the third case, what has been said about the first case holds good.

We may learn from these cases that, first, the sarcoma may originate in the layer of large vessels termed Haller's layer; second, it may be composed of spindle cells from the beginning, and, third, deep pigmentation may be present from the very onset.

DISCUSSION.

DR. G. E. DE SCHWEINITZ, Philadelphia: I appreciate highly the beautiful demonstration which Professor Fuchs has made of small sarcomata of the choroid, and I am particularly interested inasmuch as Dr. E. A. Shumway and I exhibited, some years ago, at a meeting of this Society, an exceedingly small sarcoma of the choroid, and reported its clinical history at the same meeting, and, in conjunction with it, a melanoma of the choroid. This sarcoma arose 5 mm. from the center of the optic nerve, and the area measured 4.4 mm. in its antero-posterior diameter and 0.9 mm. in thickness. I quote these measurements because, in Professor Fuchs's reference to this case in his recent paper

on sarcoma of the choroid, doubtless owing to a printer's error these measurements were not accurately recorded. Professor Fuchs, who evidently had not had an opportunity of seeing Dr. Shumway's and my original paper, doubted whether this growth was a sarcoma, and I therefore hope that Professor Fuchs will examine the specimens of this growth which Dr. Shumway and I have again brought to the meeting, when I feel sure that he will be satisfied that the growth in question really is a sarcoma.

DR. E. FUCHS, Vienna: Dr. de Schweinitz has mentioned that one of his and Dr. Shumway's specimens was not recognized by me as being a small sarcoma. In explanation of this I will say that I had not the opportunity to see his original paper, but only a short report of it. This was also the reason that the measurements, as quoted by me, were not exact. Dr. de Schweinitz has shown me his specimen, and I am quite convinced that it is really a sarcoma. I must rectify the statements in my original paper.

THE PATHOLOGY OF SUPERFICIAL PUNCTATE KERATITIS, WITH REMARKS ON NEUROPATHIC KERATITIS IN GENERAL, AND ON A HITHERTO UNDESCRIBED LESION OF THE IRIS.

F. H. VERHOEFF, A.M., M.D.,

Boston, Mass.

(From the Pathologic Laboratory of the Massachusetts Charitable Eye and Ear Infirmary.)

Superficial punctate keratitis was first described as a clinical entity in Vienna, in 1899. In this year, within the space of a few months, descriptions of the condition under different titles were published by Adler,[1] Stellwag v. Carion,[2] v. Reuss,[3] and Fuchs.[4] Of these descriptions, that of Fuchs was undoubtedly the most complete and accurate, being based upon carefully recorded notes of thirty-six cases, and to him is due the name by which the affection is now generally known. He, however, was undoubtedly antedated by Adler, so far as actual time of first publication was concerned. Various other observers have since reported numerous cases of the affection, and it is certainly not rare, although statistics are wanting as to its exact frequency. The more important clinical features of the affection are as follows:

Following, usually, an attack of bronchitis or coryza, there is an acute conjunctivitis without purulent discharge, accompanied by sensation of foreign body irritation. After a few days to a few weeks the keratitis manifests itself, after which the conjunctivitis begins to subside. The keratitis consists at first in the occurrence of extremely minute superficial spots, scattered over the surface of the cornea, numbering from 10 to 100, often arranged in groups or lines. The

periphery of the cornea is least affected. The spots may gradually increase in size, reaching a maximum diameter of 0.5 mm. (Fuchs); 1.5 mm. (Stellwag). The spots are all superficial, and may appear to raise up the epithelium. They almost never undergo ulceration. The cornea may show hypesthesia, and the intraocular tension may be lowered. The attack may last several weeks to a year, during which exacerbations occur. Recurrences after this do not take place (Fuchs). After one to two years the spots are no longer visible. Definite iritis, with posterior synechia, does not occur. The affection is most common among young adults. It is bilateral in about one-third of the cases (Fuchs).

While the clinical aspects of the disease are thus comparatively well known, its pathology and etiology have not been definitely determined. Owing to the fact that under ordinary circumstances the eyes never come to enucleation, a complete histologic examination of an entire eye affected with superficial punctate keratitis has not hitherto been made. The case which I have to report is, therefore, of unusual interest, and is, I believe, the only recorded case of neuropathic keratitis of any kind that has been submitted to such an examination at a sufficiently early stage. This case also shows a hitherto undescribed, but highly significant, condition of the iris blood-vessels.

Clinically, the case did not come under my personal observation, and the clinical record of the case is unfortunately lacking in details. The corneal appearance, however, as seen by me after the enucleated eye was in formalin, was perfectly typical. I have been unable to ascertain definitely upon what grounds the eye was removed, but I infer that the punctate spots were mistaken for exudate in the anterior chamber, which, with the hypermature cataract and the low tension, may have made the condition appear more serious than it really was.

Samuel M., aged seventy-five, visited the out-patient department for the first time June 27, 1910. Twenty-three years ago cataracts had developed in both eyes. The cataract was removed from the left eye, and the resultant vision has continued so good that the patient has not had the right eye operated upon. During the past two years he has had periodic attacks of neuralgia on the right side of the head and about the right eye. Two weeks ago the patient had an extremely severe attack of neuralgia, and a few days later the right eye became inflamed. Diagnosis: Iritis.

One week later the patient returned to the hospital, a diagnosis of iridocyclitis was made, and at his urgent request the eye was at once enucleated. During the nine months since the operation the neuralgia has continued, but has been less severe. The general health of the patient has been otherwise good.

Pathologic Examination.—Macroscopic: Fixation in 10% formalin. The globe is of normal size, indented at the posterior pole, due to low intraocular pressure. The cornea is of normal thickness, and in general appears as clear as a normal cornea after formalin fixation, but shows scattered over it fifteen gray spots. Some of these spots are in the center, none occur closer than 1.5 mm. to the limbus. The smallest are 0.3 mm. in size,* the largest, 1 mm. The average size is probably about $\frac{1}{3}$ mm. None of the spots is exactly round, but their outlines suggest that they are due to fusion of smaller spots (Fig. 1). Some of the smallest are oval in shape, due apparently to the contiguity of two still smaller. Some of the largest spots show one or two discrete smaller spots at their margins, suggesting these would have later fused with the larger spots. All of the spots seem to be situated immediately beneath the surface, and so far as can be determined are not elevated. By carefully removing the excess of moisture with blotting-paper, small defects (artefacts?), evidently due to loss of epithelium, can be made out over the centers of some of the larger spots. Over some of the spots, however, the epithelium is intact.

The anterior chamber is 3.25 mm. deep, and is free from coagulum. The filtration angle is widely open. The pupil,

* As will be noted later, still smaller spots were found in the microscopic examination.

3 mm. in diameter, is free and regular. The lens, *in situ*, has been converted into a Morgagnian cataract, with a free nucleus, 7 mm. by 3 mm. in size. The capsule is covered with white spots, especially marked posteriorly. The ciliary body is normal. The vitreous is clear, normal. The choroid and retina are *in situ*, and normal except for the presence of two small spots of atrophy at the ora serrata. The disc is not swollen or cupped, but its outline is not sharp.

Histologic Examination.—Technic: Fixation in formalin several months, followed by 10% potassium bichromate twenty-four hours. Part of the optic nerve mordanted for myelin sheath stain, and cut in cross-sections. Celloidin embedding. Meridional sections of the cornea, with complete serial sections of some of the punctate spots. Serial plane sections of one of the small spots. One of the spots stained by Levaditi's method for spirochætes. Staining in hematoxylin and eosin, van Gieson's stain, iron hematoxylin, Verhoeff's elastic tissue and myelin sheath stains, Mallory's phosphotungstic acid hematoxylin, Gram-Weigert tubercle bacillus stain, thionin, carbol-fuchsin ½ with differentiation in 70% alcohol.

The subconjunctival tissue of the limbus is congested, and shows a moderate infiltration with chronic inflammatory cells. Except at the sites of the punctate spots the corneal stroma is normal, as are also the epithelium, Bowman's and Descemet's membranes. The anterior half of the corneal stroma shows a slight infiltration with leukocytes, which gradually increases as the spots are approached. The leukocytes are almost all polymorphonuclear; only rarely is a lymphocyte seen. Some portions of the cornea are entirely free from infiltration. No vessels have invaded the cornea. The endothelium is intact, but over the central portion of the cornea it has been invaded by pus-cells. Where this invasion is only slight, the endothelium is still in contact with Descemet's membrane, and the pus-cells seem to lie within the endothelial cells, but where it is marked the leukocytes have accumulated beneath the endothelium, lifting it up (Fig. 9). The invasion is most marked in the lower third of the cornea. In some sections it appears as if it were greater behind the punctate spots, but behind some of the spots it is almost entirely absent.

The punctate spots are found to be sharply defined, disc-shaped foci of necrosis situated immediately beneath Bowman's membrane, which in some cases is intact, in others not (Figs. 2, 3, and 4). Within them the corneal corpuscles are no longer recognizable, and the corneal stroma is infiltrated with granular débris. This débris consists chiefly of broken-down chromatin in irregular coarse and fine granules, but contains also an abundance of granular material which is more or less eosinophilic. There is also a diffuse bluish tinge pervading the entire focus, due evidently to karyolysis. The necrotic material is not confined to pre-existing corneal spaces, but is packed also into new spaces formed by the splitting up of the corneal lamellæ into their constituent fibrillæ. This splitting up of the lamellæ is best seen in sections prepared in such a way that only the stroma is stained (Fig. 10). No actual destruction of the stroma can be made out. At the periphery of the foci can be seen various stages in the necrosis, which takes place relatively abruptly, and it is easily seen that the main mass of necrotic material is formed by leukocytes which have invaded the focus and there undergone destruction. The character of the leukocytes cannot certainly be determined in the meridional sections, although it is suggested by the neutrophile granules they contain, but in the plane sections it is easily made out to be that of polymorphonuclear leukocytes (Fig. 8). In the latter sections, long tubules, evidently Bowman's corneal tubules, are frequently seen marked out by irregular chromatin masses from necrotic pus-cells. At the periphery of the focus the corneal corpuscles are not appreciably increased in number, although in one section one of them is found in mitosis, indicating some proliferation of these cells, however slight. As the margin of the focus is approached the nuclei of the corneal corpuscles show various stages of necrosis, consisting chiefly in karyolysis. Pycnosis and fragmentation of the corneal nuclei are not observed, due possibly in part to the fact that formalin is a poor preservative of chromatin, in which substance corneal corpuscles are not rich normally. In the central portion of the focus no normal corneal corpuscles are to be found, and only occasionally can a normal leukocyte be seen.

The most intensely necrotic portion of the foci is that just

beneath Bowman's membrane. This fact is not always apparent, however, unless the section passes approximately through the middle of the focus. Leukocytes are sometimes seen in the act of passing through the nerve-channels in Bowman's membrane. These stretch themselves out beneath the epithelium, where they undergo necrosis and form irregular, elongated, densely staining bodies. These remain differentiated from the rest of the necrotic material even after Bowman's membrane is no longer recognizable.

The condition of Bowman's membrane varies in the case of different foci, but, generally speaking, does not depend upon the size of the latter. In some, even of the largest ones, Bowman's membrane is intact, while in others, and these may be of the smallest, the membrane may be absent or much reduced in thickness. In no case is there any loss of substance involving the corneal stroma. The destruction of Bowman's membrane always takes place from within, and in one or both of two ways. It may gradually become thinner from the periphery toward the center, the inner surface presenting an eaten-away appearance, or it may be chiefly attacked at one or more discrete points, which, moreover, do not always lie in the center of the focus (Figs. 4 and 5). In certain instances it is easily recognized that these points correspond to the nerve-channels of the membrane. In this way it sometimes happens that the membrane is broken through only at the periphery of the focus, or that it is broken through at several points over the focus (Fig. 3). It also sometimes happens that the membrane is lost a short distance before the focus is reached. This is perhaps due to the fact that after it had broken through here the process had ceased at this point and resolution of the infiltrate had begun (Fig. 7).

The epithelium, where it is intact over the foci, sometimes shows remarkably little change. Over some of them, however, it is distinctly altered, being increased to about double its normal thickness (Figs. 2 and 3). This is due partly to an increase in the size of the individual cells, but chiefly to an increase in the number of layers. The cells sometimes appear swollen, the cytoplasm appearing translucent, while vacuoles sometimes occur around the nuclei. Other supposed evidences of edema, such as clefts between the basal

cells, are but seldom seen (Fig. 5). None of the cells show marked signs of necrosis. Over one focus, where Bowman's membrane has been destroyed, the epithelium forms an uneven layer, thinner than normal, the basal cells of which are flattened out, suggesting that the epithelium here may have been recently reformed (Fig. 7). Leukocytes are only occasionally seen within the epithelium itself. Over the centers of many of the foci the epithelium has been lost (Figs. 3 and 4). The edges of the defect show an irregular, fragmented appearance clearly indicating artefact. This is indicated also by the absence here of any evidences of repair on the part of the epithelium.

In addition to the foci described above, all of which were visible macroscopically, other very much more minute foci are occasionally encountered. Some of these are fortunately included in a set of serial sections. These minute foci, like the larger foci, are due to necrosis of a leukocytic infiltrate between the corneal lamellæ and fibrillæ. In the serial sections it is seen that each is centered about a nerve-channel in Bowman's membrane. Fig. 6 shows such a channel with a leukocyte passing through it. Here also Bowman's membrane is slightly elevated, and the epithelium is separated from it.

The filtration angle is widely open. Below it contains a small collection of cells and fibrin, not sufficient to deserve the name hypopyon (Fig. 11). These cells are chiefly pus-cells with a few epithelioid phagocytes, an occasional lymphocyte, and a few red blood-corpuscles. The ligamentum pectinatum and canal of Schlemm show normal patency. The spaces of Fontana above contain a few red blood-corpuscles, and below, cells similar to those seen free in the angle.

The iris shows almost complete absence of the usual signs of inflammation, and its stroma is entirely free from fibrous change. There are no posterior synechiæ. Within the stroma only an occasional leukocyte is encountered. On the surface, however, and within the crypts, there are small accumulations of cells, chiefly pus-cells with a few epithelioid phagocytes. Lymphocytes are practically absent. The blood-vessels of the iris show a striking and unusual condition. This consists in the occurrence of actively

proliferating blood-vessels and small cavernous blood-spaces. These occur only in certain relatively well-defined areas. Thus, in some sections, they are absent on one side and abundantly present on the other. In others, they form an almost continuous irregular layer, extending immediately beneath the pigment epithelium and then on and within the sphincter muscle (Fig. 11). In still others they occur in small focal areas along this tract (Fig. 12). Where in any one section they are few in number, they are most apt to occur about the sphincter muscle and at the root of the iris. Their origins are best seen in plane sections. In these it is seen that they arise from definite points along the walls of the iris blood-vessels (Fig. 13). When in abundance, they resemble the vessels of an actively growing angioma or those of granulation tissue, except that they are not associated with the inflammatory reaction of the latter (Fig. 14). There is, however, a slight exudation of pus-cells taking place from them, and within their lumens there are often more pus-cells to be seen than occur in normal vessels. Bleached specimens, however, show no infiltration of the pigment epithelium behind them. In the immediate vicinity of the new vessels there are often small collections of discrete red blood-corpuscles, evidently due to diapedesis. The vessels of the iris not involved in the proliferative process are normal.

The other parts of the eye show no noteworthy changes, those found being senile in nature. The lens shows the ordinary appearances of a hypermature cataract. The cortical matter has completely broken down, and the capsular epithelium shows old focal proliferation. The ciliary body is of normal size, but the individual muscle-fibers show senile atrophy. The ciliary processes show hyaline degeneration, and the pars ciliaris retinæ moderate hyperplasia. The retina is normal, except that possibly here and there a multipolar ganglion cell shows evidences of degeneration. The pigment epithelium has formed colloid bodies at the disc margin, but is otherwise normal. The choroid is normal, with the exception of a very slight perivascular infiltration with lymphoid cells in places. The membrane of Bruch shows areas of basophilic granulation commonly seen in senile eyes. The sclera contains

posteriorly an abundance of large basophilic granules, evidently deposits of lime salts. The optic disc is normal, as is also the nerve stem (myelin sheath stain).

The retinal blood-vessels are normal. The central retinal vessels show very slight endovasculitis. The posterior ciliary vessels show moderate endovasculitis, but their lumens are never appreciably reduced. The choroidal vessels and the circulus iridis major are still less affected.

Bacteriologic Examination.—Sections stained by the methods enumerated above, including the method of Levaditi, fail to show micro-organisms of any kind within the lesions.

That this was a case of superficial punctate keratitis (Fuchs) is certain, since the corneal spots were typical in situation, size, and shape, and all other known varieties of punctate keratitis can be excluded. Syphilitic and tuberculous punctate keratitis can be excluded by the superficial situation of the spots and their histology. Leprous keratitis can be excluded by the lack of any other evidences of leprosy, the histology of the spots, and, above all, by the absence of lepra bacilli, which occur in great numbers in this affection. The only features of this case at all unusual are the age of the patient, seventy-five years, and the intense neuralgia. Fuchs[4] gives fifty-two and Reuss[3] sixty as the maximum age, so it is evident that the question of age has no special significance. The fact that the patient had been subject to severe neuralgia for two years previous to the eye trouble would indicate that there was no etiologic relation between the two, the neuralgia simply being aggravated by the irritation due to the eye affection.

The histologic examination of this case shows that primarily the spots were due to necrosis of a leukocytic infiltrate situated immediately beneath Bowman's membrane. The corneal lamellæ and fibrillæ were simply split apart, never actually destroyed. This, no doubt, explains why the lesions may finally disappear without leaving a trace. In their smallest and therefore probably their earliest stage the

spots were extremely minute (0.12 mm. in diameter), and each was centered about a nerve-channel in Bowman's membrane (Fig. 6). Over these minute spots Bowman's membrane was intact, but the epithelium showed slight evidences of edema. The separation of the epithelium from the membrane shown in Fig. 6 was possibly artefact, but since it did not occur anywhere over the normal part of the cornea, it at least showed that the epithelium was more loosely adherent here. These minute foci doubtless correspond to the spots just visible to the naked eye, seen in the earliest stages of this affection. As shown in Fig. 6, Bowman's membrane was slightly bulged forward over them. No doubt this bulging, which probably was still more marked before the action of fixing agents, explains the elevated appearance of the spots seen clinically.

Over the larger spots Bowman's membrane was no longer normal, but to a greater or less degree eroded from within. Careful examination showed that this erosion did not take place uniformly over the spot, but was most intense at discrete points corresponding to certain of the nerve-channels in Bowman's membrane (Figs. 4 and 5). Doubtless these represented the minute scattered points observed clinically by Fuchs by means of a loup. As result of this process Bowman's membrane was broken through in several places over the spot. Fig. 3 shows patches of the membrane still present near the middle of one of the spots. In one instance the membrane was found destroyed at a relatively great distance from the spot (Fig. 7). It is possible in this case that after the membrane had been destroyed at this point the underlying process had ceased and resolution of the exudate had taken place. This is indicated also by the relative thinness of the spot compared to its diameter.

The epithelium over the foci was usually greatly thickened, sometimes to fully twice its normal thickness (Fig. 2). Here it did not show marked evidence of edema, but the cells were

larger and their cytoplasm more translucent than normal. This thickening of the epithelium no doubt explains the slightly elevated appearance noted by Fuchs. Adler, however, states that he could only exceptionally make out such elevation. Over many of the foci the epithelium was absent (Figs. 3 and 4). This, as already explained, was clearly artefact, due no doubt to the sponging during the enucleation. The fact, however, that the epithelium was lost nowhere else, shows that it was not attached with normal firmness over the lesions. The appearance as presented by one of the spots, moreover, indicated that the epithelium at some time may have been lost over it and repaired (Fig. 7). A focus such as this would evidently appear to the clinical observer slightly depressed rather than elevated.

Before discussing the etiology of the corneal affection, it is important, as will be seen, to consider the condition of the iris in this case. There was no actual iritis, unless the very slight cellular exudation from the anterior surface could be termed such. There were no synechiæ, and, at any rate from a clinical standpoint, iritis was absent. The slight leukocytic exudation from the iris was no doubt called forth by the same agents that attracted leukocytes to the posterior surface of the cornea (Fig. 9). The chief alteration in the iris, and this a most striking one, was the active proliferation of the vessels which occurred in certain areas. This was always confined to the vessels just anterior to the dilator pupillæ or in and about the sphincter muscle (Figs. 11 and 12). In some sections the new vessels were abundantly developed, in others they were entirely absent, or occurred only at the root of the iris or about the sphincter. Their occurrence was therefore focal in character. This focal character was also manifested in the areas themselves. Thus, in plane sections, new vessels could often be seen springing from definite points along the course of the original iris vessels (Fig. 13).

For the occurrence of this condition I can conceive of only one explanation, namely, that it was due to abnormal irritation of the vessels through nerves. That it could have been due to toxins from the cornea was excluded, I think, by the fact that the proliferation was focal in character, and that the anterior vessels of the iris were not involved. That it was secondary to an inflammatory condition of the iris was excluded by the fact that the iris showed almost no inflammatory reaction, and that such lesions have never been observed in any other inflammatory conditions of the eye. Whether the proliferation was due to involvement of the nerves of the vessels themselves, or of the nerves of the dilator and sphincter muscles, is not so clear. For it is conceivable that toxins diffused from the nerve terminals in the muscles might have irritated the contiguous vessels. The fact, however, that the proliferation occurred at focal points along the vessels is more suggestive of an involvement of the nerves of the vessels themselves.

The question arises as to the frequency of this condition of the iris in cases of superficial punctate keratitis. According to Fuchs, iritis does not occur, but the iris in early cases shows hyperemia and reacts sluggishly to atropin. It is evident that the pathologic condition of the iris in the present case would in all probability have produced this clinical condition, so that it may be a frequent occurrence. No doubt after the removal of the nerve irritation many of the vessels would finally disappear, as they do in granulation tissue, but even if they persisted no harm would probably result. As I have pointed out elsewhere,[15] in other neuropathic conditions actual iritis with synechiæ may occur. The reason it does not occur more often is perhaps to be explained by the fact that the loose tissue of the iris allows the toxins to be readily diffused away.

The occurrence of this condition of the iris is suggestive in another direction, namely, as to the etiology of angiomata

of the skin. Von Bärensprung first pointed out that congenital vascular nævi follow the distribution of sensory nerves. Recently Cushing[5] has brought forward evidence which lends strong support to the view that these nævi are dependent upon a pathologic condition of the nerves or ganglion supplying the affected regions. This view is thus supported by the findings in my case, which go to show that proliferation of vessels may follow nerve irritation. It is suggestive in this connection also that angiomata of the choroid are most frequently associated with nævi of the face. The findings in the present case also suggest that the capillary nævi occurring later in life, some of them transient in nature, may likewise be due to nerve irritation. A full discussion of this aspect of the question, however, is beyond the scope of this paper.

Turning now to the question of the etiology of the punctate spots in the cornea, it is obvious that if the lesions in the iris were neuropathic in origin, there can be no reasonable doubt that so also were the corneal lesions. Aside from this, however, the histology of the spots themselves furnishes strong evidence of a neuropathic origin. In the first place, it is apparent that the process was most intense immediately beneath Bowman's membrane. This is shown by the fact that this membrane was eroded and even completely destroyed, whereas the underlying corneal lamellæ were simply split apart. Moreover, the process was especially intensified at focal points corresponding to certain of the nerve-channels in Bowman's membrane, which here showed its greatest erosion (Fig. 5), while each of the smallest lesions was centered about a single nerve-channel (Fig. 6). These facts, it seems to me, as I shall point out later, are best explained by assuming that the inflammatory process was due to irritating substances arising at the nerve terminals. It is of course possible that the nerve-channels might be attacked first by any sort of inflammatory process, but it

would be expected if the latter were due to micro-organisms the channels would be attacked more uniformly, not simply here and there. Moreover, if the lesions were due to micro-organisms it would be expected that Bowman's membrane would be affected according to the size of the lesions, whereas this was not the case, it being intact over some of the larger lesions and completely absent over some of the smaller. If infection occurred from without, it would be expected that Bowman's membrane would be absent over all the lesions. If the infection were metastatic, it would be expected that the lesions would be present also at the limbus, and that some of them, at least, would be relatively deeply seated, as in the cases of tuberculosis and leprosy.

Another strong argument against a bacterial origin for the lesions is the small size and character of the lesions relative to their duration. Thus, if infection were due to organisms similar to any known pyogenic bacteria, only a few days, instead of a few weeks, would have been required to produce lesions of such small size. On the other hand, judging from analogy to processes of known bacterial origin, lesions produced so slowly would have had an entirely different character from those in this case. Instead of the infiltration being made up exclusively of pus-cells, the predominating cells would have been lymphoid, plasma, or endothelial cells, and there would have been also marked proliferation of the corneal corpuscles.

It will be observed that the above evidence as to the neuropathic origin of superficial punctate keratitis is based entirely upon histologic findings, and is thus independent of clinical observation. The clinical evidence, however, that may be brought forward in support of such an origin is strong. In the first place, the resemblance of the corneal condition to that of herpes corneæ and dendritic keratitis, typical neuropathic affections, is close, especially as regards the size of the lesions and their arrangement. These conditions are alike,

also, in frequently following catarrhal affections of the respiratory tract. Herpes corneæ and dendritic keratitis, moreover, sometimes show punctate spots identical in appearance with those of superficial punctate keratitis. Secondly, the diminished intraocular tension which not infrequently occurs in this condition is difficult, if not impossible, to explain on other than a neuropathic basis. This was undoubtedly present in my case, as shown by the partial collapse of the globe in the formalin solution, something that I have observed to occur only with soft eyes. Thirdly, the corneal hypesthesia, which with care can usually be made out, to me seems of great significance. Fuchs, on the other hand, attributes it to the general infiltration of the cornea and its nerve-canals. This infiltration is very slight, however, and, according to my experience in other conditions, it must be considerable to cause an appreciable hypesthesia. Fourthly, the fact that the lesions do not typically occur near the limbus suggests a neuropathic origin, since the periphery of the cornea has a different nerve-supply from the center. Finally, the punctate spots give the green staining with fluorescin which I have found occurs in all active neuropathic subepithelial lesions of the cornea.[15] This I regard as highly important, because I have yet to see other corneal lesions, where still covered with epithelium, stain in this way.* The diffuse staining of the cornea, however, which also often occurs in neuropathic keratitis, may occur under other conditions. It is interesting that I was able to obtain elective fluorescin staining of the punctate spots in the present case, after the eye had been in formalin several months.

Fuchs[4] recognized the resemblance of superficial punctate keratitis to herpes corneæ, but laid more stress on points

* I have recently found that all brands of fluorescin are not alike. My observations have been made with that of Gruebler. It is important to allow the fluorescin solution to act one to two minutes before washing it out of the conjunctival sac.

of difference. The points which he emphasized were, the multiplicity of the lesions in this affection, its frequent bilateral character, and the absence of vesicles, erosions, iritis, ulcers, or hypopyon. These differences undoubtedly exist when classic cases are alone considered, but to a certain extent disappear in atypical but equally significant cases. Moreover, they do not necessarily indicate that superficial punctate keratitis is not a neuropathic condition, but more likely, as I shall point out later, only that the nerve lesion has a special character or situation.

As is well known, disciform keratitis characteristically shows outlying punctate spots identical in appearance with superficial punctate keratitis. This impelled Fuchs[6] to believe that both conditions were essentially of the same nature and due to some unknown micro-organism. Peters,[7] however, also on clinical grounds, concluded that disciform keratitis was due to a disturbed innervation leading to edema and necrosis. Meller,[8] after examining histologically an eye from an advanced case of disciform keratitis, concurred in Fuchs's view. He was unable to find any micro-organism present, however, and, as Peters[9] strongly maintained, brought forward no evidence that would justify his conclusions. His description of the disciform opacity agrees in all essential particulars with the histologic structure of the punctate opacities in my case. It is interesting, too, that the organized exudate on the posterior surface of the cornea in his case evidently was but an end-result of the leukocytic infiltration of the endothelium in mine. He found, also, that a punctate spot, which happened to be included in some of his sections, showed histologically the same process as the main opacity, that is, necrosis of a cellular infiltrate lying between the corneal lamellæ. He did not definitely determine the character of the cells making up the infiltrate. If, therefore, superficial punctate keratitis and disciform keratitis are of the same nature, and the former, as I have

just brought forward evidence to show, is a neuropathic affection, it follows that disciform keratitis is also a variety of neuropathic keratitis.

In connection with disciform keratitis, it is interesting to note that the intensified white border to the disc which Fuchs regards as an essential characteristic at some stage, probably also occurs in the case of the punctate spots of superficial punctate keratitis. This was described as a typical feature of the latter affection by Adler,[1] and it could indistinctly be made out in the macroscopic examination of my case. It is, however, not noted by Fuchs.[4] In the case of disciform keratitis Meller thinks it is due chiefly to scar formation at the periphery of the disc, but in the case of the spots of superficial punctate keratitis I should think it due to the zone of living leukocytes around the spots, which in all probability produce a different appearance from the necrotic leukocytes in the center.

Because the disciform keratitis of Fuchs is in all probability neuropathic in origin, it does not follow that there are no cases of keratitis with disc formation due to micro-organisms. As is well known, disc-shaped opacities may occur in congenital syphilis. They may also occur in certain cases of ulcus serpens, where the infection is from without, although here it is probable that in most instances there is a neuropathic basis. Schirmer[10] has observed disc-shaped opacities of the cornea follow infection of the eyelids with vaccine virus, and he has also produced them by vaccinating the cornea of animals. This does not seem sufficient, however, to justify his conclusion that the disciform keratitis of Fuchs is due to infection with vaccine virus.

Nuel[11] and Wehrli[12] have each examined microscopically small bits of corneal tissue from two cases of superficial punctate keratitis. Nuel in his first case found the spots to be composed of a network of filaments twisted into spirals,

situated immediately under Bowman's membrane between the superficial corneal lamellæ. He regarded the spirals as fibrin. In his second case he found Bowman's membrane and the epithelium destroyed and replaced by colonies of micrococci, while the stroma showed the condition previously described. The spirals which he had previously regarded as fibrin he now assumed to be giant bacterial cells. Interpreted in the light of my case, it is evident that the spirals were nothing other than chromatin masses between the corneal lamellæ and fibrillæ, distorted by the traumatism to which the tissue was necessarily subjected during its removal. I have myself observed such spirals in traumatized corneal tissue. The colonies of micrococci no doubt represented infection of a lesion which by chance had become eroded.

Wehrli[12] found the epithelium alone involved, showing minute infiltrations with lymphocytes, while the underlying stroma was normal or almost so. This is contrary to the clinical observations of Fuchs, who after removing the epithelium found the spots unaffected. Wehrli's findings were also at direct variance with those of Nuel,[11] Meller,[8] and myself. The lesions depicted by him were so minute that it seems doubtful that they could have been seen clinically. He speaks of the extreme difficulty with which they were seen, and also states that they did not stain with fluorescin. It seems probable, therefore, that Wehrli was either not dealing with superficial punctate keratitis, or, if so, that his sections failed to pass through the essential lesions.

In a form of superficial punctate keratitis common in Bombay, Herbert[13] describes encapsulated bacilli occurring in epithelial scrapings. It is uncertain whether or not he was dealing with the form of keratitis described by Fuchs. Certainly his description does not agree with typical cases of the latter. Thus he says that the spots sometimes occurred at the limbus, and even on the tarsal conjunctiva,

with nasal catarrh. It was bilateral in only 2 out of 226 cases. He does not state whether or not there was corneal hypesthesia or diminished intraocular tension. In regard to the bacillus, he says it did not stain well enough to be closely described, and that attempts to inoculate a second eye failed. Apparently also he was not able to find it in all cases. Herbert's observations, therefore, are of doubtful significance, so far as the superficial punctate keratitis of Fuchs is concerned.

In leprosy there occurs a form of superficial punctate keratitis that is definitely known to be due to micro-organisms. It is, therefore, of some importance to compare the corneal lesions here with those of Fuchs's affection. Recently I have had the opportunity of examining histologically an eye from a case of leprosy which showed this form of keratitis.* I find that while in both affections the lesion is superficial and punctate, here the resemblance ceases. In leprosy most of the spots, especially the small ones, are simply aggregations of leprosy bacilli, situated in the superficial corneal space or beneath Bowman's membrane, while others consist of lepra cells packed with bacilli. Except where there is ulceration due to secondary infection, there is no infiltration with polymorphonuclear leukocytes and no necrosis. More important still is the fact, which at the same time explains the superficial situation of the lesions, that the infection apparently takes place from the conjunctiva and episclera, as indicated by the increase in size and number of the spots as the latter is approached. This is shown also by the clinical observation that the spots make their first appearance at the limbus and gradually approach the center. In Fuchs's affection, on the contrary, the spots are least abundant at the periphery. The hypesthesia of the cornea in leprous keratitis is probably due to invasion and that the condition was never observed to be associated

* For this eye I am indebted to Dr. Black and Dr. James Bordley.

of the ciliary nerves by lepra bacilli. As a matter of fact, I found these nerves thus invaded in the case I examined.

It may be of some interest now to consider briefly the question of the possible character and situation of the nerve lesion producing superficial punctate keratitis. This consideration must, of course, be largely speculative, because our knowledge in regard to the etiology of neuropathic affections in general is by no means definite. It is safe to conclude, however, with Wilbrand and Saenger,[14] that an irritative lesion is required to produce neuropathic keratitis. Simple withdrawal of nerve impulses is not sufficient. Ample proof of this is furnished by the familiar fact that neuropathic keratitis does not occur after corneal section for cataract, although it has been shown that corneal sensibility is not completely restored for several months. In a previous paper[15] I have brought forward the theory that the irritative lesion gives rise to impulses which pass backward along the sensory nerves to their terminals in the cornea, where they produce chemical changes. The chemical substances thus produced act to a greater or less degree as toxins, and thus give rise to the characteristic lesions.

As I pointed out in the previous paper referred to, it is self-evident that if efferent impulses are constantly passing along a nerve, they must produce some changes at the nerve terminal, however slight. It is true that so far as can be determined the passage of an impulse gives rise to no chemical changes in the nerve itself, but this is all the more reason why the energy it represents should be manifested at the nerve terminal in chemical changes. Moreover, while our ignorance in regard to the nature of nerve impulses is profound, we do know that every impulse is associated with an electric disturbance, negative in character, termed negative variation. It is therefore evident that the nerve terminal would correspond to the negative pole in a galvanic circuit, so that it is possible that the assumed chemical changes

occurring at nerve terminals may be electrolytic in origin. We also know that most living cells are attracted to the negative pole in a galvanic circuit, a phenomenon known as galvanotropism, so that it is conceivable that this may play a part in attracting leukocytes to the corneal lesions. The part played by galvanotropism, however, is probably slight, because it does not explain the marked edema which is often the first change noted in neuropathic keratitis.

The theory just outlined seems to accord well with the character of the lesions in the case here reported. That in the corneal lesions a diffusible toxic substance had been produced was clearly shown by the fact that leukocytes had been stimulated toward the lesions and also to the posterior surface of the cornea. When the leukocytes finally reached close to the source of the toxin, the latter was sufficiently concentrated to destroy them; hence the necrosis of the infiltrate. As previously pointed out, the necrosis was most marked beneath Bowman's membrane, and, more important still, about certain of the nerve-canals therein. The destruction of Bowman's membrane was conceivably due to the direct solvent action of the toxin, but more probably was due to ferments derived from the dead leukocytes. The changes affecting the epithelium also clearly indicate the action of a toxin. While these were not great, they were perfectly definite. Thus, as shown in Fig. 2, the epithelium was increased to twice its normal thickness—a typical response to irritation. Then, too, as already pointed out, the epithelium was not firmly adherent over the lesions, so that it was easily brushed off. That the epithelium did not show greater changes was probably due to the facts that the slowly formed toxin was rapidly diluted by tears, and that, owing to the great reproductive power of the epithelium, injured cells were quickly replaced.

It is clear that the toxins produced in the corneal lesions must have had a special affinity for pus-cells, because the

corneal corpuscles were practically normal except within the lesions themselves.* It is also evident that while the toxic action was relatively intense within the lesions, it rapidly diminished away from them. This was indicated by the small size of the lesions and by the fact that the general infiltration of the cornea was slight, considering the length of time the lesions had been active. The toxin was, therefore, no doubt produced slowly and in small quantities. This was evidently true also in the case of the iris lesions, so that here the toxins did not accumulate in sufficient quantity to produce a leukocytic infiltration, but irritated only the vessel walls. In certain other forms of neuropathic keratitis—as, for instance, herpes corneæ—it is probable that the toxins are more abundantly produced, so that they give rise to localized edema, which in turn leads to vesicles and erosions. In so-called neuroparalytic keratitis the production of toxin is evidently more widespread, so that a diffuse purulent infiltration results. In still other forms of neuropathic keratitis the toxins, no doubt, are less intense in their action.†

An alternative theory to the foregoing is that the lesion in the nerve-trunk or ganglion, by producing local destruction of nerve-tissue or ganglion cells, gives rise to toxins which are disseminated along the nerves to their terminals. If this were true, however, it would be expected that effects of irritation would be manifested along the entire course of the

* The toxins associated with herpetic lesions of the skin are similarly pyogenic, as I have had occasion to observe.

† Among neuropathic conditions I believe should be classed the so-called metastatic gonorrheal keratitis and conjunctivitis. The lesions, as described by Heerfordt,[16] seem to me typically neuropathic. The subconjunctivitis epibulbaris gonorrhoica of Heerfordt corresponds in all essentials to the neuropathic conjunctivitis previously described by me.[15] Heerfordt himself attempts to explain the corneal lesions by assuming that toxins from the periphery follow the nerve-channels into the cornea, but this is, of course, not attributing a neuropathic origin to them. The frequent association of gonorrheal rheumatism suggests that gonorrheal toxins act on the corneal nerves or their ganglia. Another condition that I have regarded as neuropathic, where not due to glaucoma, is the dystrophia epithelialis corneæ recently described by Fuchs.[17]

nerves, or at any rate within the cornea, after they had lost their myelin sheaths, so that the corneal lesions would be diffuse and deeply seated. This theory also does not explain satisfactorily the brief duration, the long duration, or the exacerbations of the process in different cases.

In regard to the possible site of the nerve lesion in superficial punctate keratitis, there are four facts that may be of significance. These are: First, the restriction of the lesions within the distribution of the posterior ciliary nerves. This is shown by the absence of any changes in the skin,* the absence of punctate lesions in the conjunctiva, and especially the infrequency of lesions at the periphery of the cornea, which is supplied chiefly by the conjunctival nerves. The hyperemia of the conjunctiva is no doubt entirely reflex, due either to centripetal impulses arising from the nerve lesion, or to irritation of the unaffected corneal nerves by the corneal lesions. This irritation could occur, of course, in either case, before the lesions are clinically visible, which may explain why the "conjunctivitis" apparently precedes the keratitis. Second, the punctate character of the lesions. Third, the diminution in intraocular tension which sometimes occurs. Fourth, the frequent bilateral character of the affection, the second eye showing the same type of keratitis as the first. These facts, it seems to me, while they do not absolutely exclude the possibility that the causal lesion is in the Gasserian ganglion, are best explained by assuming that the lesion is in the ciliary ganglion. For it is obvious that a lesion in this ganglion would not directly affect the conjunctiva, since the latter is not supplied by the posterior ciliary nerves. The punctate character of the lesions would be explained by the fact that the cornea is only in part supplied by the short ciliary nerves from the ciliary ganglion, being supplied also, and perhaps chiefly,

*Herpes facialis does rarely occur, but when it does it probably has no relation to the eye condition, but is dependent upon the coryza, which would be expected to give rise to it in a certain number of cases.

by the long ciliary nerves. Thus the lesions would occur only within areas in the cornea innervated through the ciliary ganglion. This would account also for the frequent wide distribution of the lesions. The diminution in intraocular tension would obviously be explained by a lesion of the ciliary ganglion, since it is well established that the intraocular tension is markedly influenced by the sympathetic system with which this ganglion, anatomically at least, is in relation. Finally, the fact that the ciliary ganglion is anatomically and functionally a specially differentiated structure explains why it should be electively attacked by certain systemic toxins, and thus explains not only why both eyes are frequently affected, but also why the second eye shows the same type of neuropathic keratitis as the first.*

The fact that the nerve lesion in superficial punctate keratitis is in all probability situated in the ciliary ganglion suggests that neuropathic peripheral lesions in general most often may be due primarily to irritation, not of the nerves themselves, but of their peripheral ganglion cells. It is perfectly conceivable that these cells, being abnormally stimulated, could send impulses toward the periphery, and even continue to do so after the action of the toxin had ceased. Such an origin for neuropathic lesions would explain why certain regions are more apt to be affected than others. For instance, herpes facialis attacks most often the lips and alæ of the nose, which is explained, perhaps, by the fact that the ganglion cells supplying these regions are more sensitive and hence more susceptible to toxins, just as the most susceptible retinal nerve-cells are those of the macula. Similarly may be explained the fact that the cornea is more apt to show neuropathic lesions than the other ocular structures. This theory, moreover, is in accord with the conclusion of Head and Campbell,[18] based on their

* The absence of neuralgic pain in superficial punctate keratitis also suggests the ciliary rather than the Gasserian ganglion as the site of the lesion, but it is possible that this may be dependent only on the character of the lesion.

extensive anatomic investigations, that herpes zoster ophthalmicus is due to intense irritation of the nerve-cells of the Gasserian ganglion by some specific infectious agent.

Another condition which is satisfactorily explained by this theory, and which thus lends strong support to it, is traumatic relapsing keratitis. This, as is well known, clinically closely resembles neuropathic keratitis. The most probable explanation hitherto offered for this condition has been that it is due to direct injury to the nerves within the cornea, but its long duration and relapsing character are against this. If, however, it is assumed that the primary injury to the cornea stimulates the nerve terminals so intensely as to produce a lasting state of irritability in the peripheral ganglion cells with which they are connected, the long duration, the relapsing character, and the neuropathic nature of the lesions are all satisfactorily explained. This would explain also the cases of keratitis disciformis and profunda which result from local trauma.

The conclusion that superficial punctate keratitis is due to a lesion of the ciliary ganglion applies, of course, only to typical cases. It seems possible, in fact, highly probable, that under certain conditions a lesion of the Gasserian ganglion might give rise to similar punctate spots in the cornea. I have myself seen such spots at the periphery of the cornea associated with a conjunctival nodule at the limbus. Here it is evident that the lesion was not in the ciliary ganglion.

CONCLUSIONS.

Superficial punctate keratitis (Fuchs) is a form of neuropathic keratitis.

The corneal lesions in this condition consist of slowly formed necrotic leukocytic infiltrates seated beneath Bowman's membrane, and are due to the action of pyogenic diffusible toxic substances arising at nerve terminals.

Clinical evidence indicates that the causal nerve lesion is

in the ciliary ganglion, and that it is probably due to the elective action of a systemic toxin on certain of the ganglion cells therein.

In this affection there sometimes occurs well-marked focal proliferation of the iris blood-vessels. This observation confirms the view that vascular nævi are neuropathic in origin, and suggests that certain angiomata arising later in life may have a similar origin.

Disciform keratitis (Fuchs) is essentially of the same nature as superficial punctate keratitis, and is likewise neuropathic in origin.

Traumatic relapsing keratitis is due to a state of irritability in the peripheral ganglion cells of the corneal nerves, resulting from intense stimulation of the nerve terminals.

REFERENCES.

1. H. Adler: "Keratitis sub-epithelialis," *Centralb. f. prak. Augenheilk.*, 1889.
2. Stellwag v. Carion: "Ueber eine eigenthümliche Form der Hornhautentzündung," *Wiener klin. Woch.*, 1889, p. 612.
3. A. v. Reuss: "Keratitis maculosa," *Wiener klin. Woch.*, 1889, p. 665.
4. E. Fuchs: "Keratitis punctata superficialis," *Wiener klin. Woch.*, 1889.
5. H. Cushing: "Cases of Spontaneous Intracranial Hemorrhage Associated with Trigeminal Nævi," *Jour. Amer. Med. Assoc.*, 1906, xlvii.
6. E. Fuchs: "Ueber ringförmige und scheibenförmige Keratitis," *Klin. Monatsbl. f. Augenheilk.*, 1901, p. 513.
7. Peters: "Ueber traumat. Hornhauterkrankungen und ihre Beziehungen zum Herpes corneæ," *Arch. f. Ophth.*, 1904, lvii., p. 93.
8. Meller: "Die histologischen Veränderungen des Auges bei der Keratitis disciformis," *Klin. Monatsbl. f. Augenheilk.*, 1905, ii., p. 335.
9. Peters: "Zur Frage der Keratitis disciformis," *Klin. Monatsbl. f. Augenheilk.*, 1905, ii., p. 535.
10. O. Schirmer: "Ueber Keratitis disciformis und Keratitis postvaccinolosa," *Arch. f. Ophth.*, 1904, lix, p. 133.
11. J. P. Nuel: "La Kératite Pontuée Superficielle est une Maladie microbienne typique," *Arch. d'Ophtal.*, 1896, p. 725.
12. Wehrl: "Zur Histologie der Keratitis punctata superficialis," *Klin. Monatsbl. f. Augenheilk.*, 1906, p. 224.
13. Herbert: "Superficial Punctate Keratitis Associated with an Encapsulated Bacillus," *Ophthalmic Review*, 1901, p. 339.
14. Wilbrand und Saenger: "Die Neurologie des Auges," 1901, vol. ii.
15. F. H. Verhoeff: "Neuropathic Keratitis and Some Allied Conditions," *Jour. Amer. Med. Assoc.*, July 17, 1909.
16. Heerfordt: "Ueber endogene gonorrhoische Hornhaut Affectionen," Arch. f. Ophth., 1910, i, p. 145.
17. E. Fuchs: "Dystrophia epithelialis corneæ," *Arch. f. Ophth.*, 1910, iii.
18. Head and Campbell: "The Pathology of Herpes Zoster," *Brain*, 1900.

Fig. 1.—Outer fourth of cornea, after fixation in formalin, showing three punctate spots. Photo. × 2.



Fig. 2.—Punctate infiltrate near its center. The greatest thickening of the epithelium is here not immediately over the center, due to the fact that the proliferation of the epithelium does not follow exactly the contour of the underlying spot. Bowman's membrane is only slightly eroded. The endothelium on the posterior surface of the cornea is infiltrated with leukocytes. The general infiltration of the corneal stroma is slight. Photo. × 50.

Fig. 3.—Two almost contiguous punctate infiltrates Bowman's membrane is destroyed over each and the epithelium is thickened. In the one on the left there are two areas in which portions of Bowman's membrane still remain. The break in the epithelium on the right is no doubt artefact, due to sponging during the enucleation. Photo. × 40.

Fig. 4.—Large punctate infiltrate. Bowman's membrane is almost intact, but shows erosion at site of nerve-channel. The loss of epithelium is artefact—the cells extending from the margins of the break are basal cells, not newly proliferated cells

Fig. 5.—Periphery of punctate infiltrate, showing increased intensity of process at site of nerve-channel, with focal erosion of Bowman's membrane. The epithelium is distinctly altered. Photo. × 375.

Fig. 6.—Minute infiltrate (0.12 mm. in diameter) centered about a nerve-channel in Bowman's membrane, through which a leukocyte is in the act of passing. Serial sections show that this is the middle of the focus. Note the slight bulging of Bowman's membrane. The epithelium is separated from Bowman's membrane, possibly due to edema. This probably corresponds to the smallest spot clinically visible. Photo. × 375.

Fig. 7.—This focus is probably in a healing stage, as indicated by the absence of infiltration on the left, where Bowman's membrane is destroyed for some distance from the focus. The epithelium, apparently recently reformed, is thin and uneven, due to irregularities in the erosion of Bowman's membrane. Photo. × 60.

Fig. 8.—Plane section through margin of infiltrate, showing polymorphonuc leukocytes approaching it and then undergoing necrosis and fragmentation. Pl × 250.

Fig 9.—Showing polymorphonuclear leukocytes collected beneath endothelium on posterior surface of cornea. The corneal stroma above is not infiltrated. Photo × 375

Fig 10.—Periphery of pu showing splitting up of cornea tion bleached and stained in acid hematoxylin. Only an oc fragment is stained. Photo. :

Fig. 11. -Proliferation of the iris vessels along the dilator and sphincter muscles. There is a small collection of leukocytes in the filtration angle below Photo. × 25.

Fig. 12 —Localized proliferation of iris vessels along dilator muscle Note absence of iritis Photo. × 50.

terms parenchymatous, glomerular, and interstitial are used for descriptive purposes largely where the lesions are mainly confined to the secreting cells, the capillary tufts, or the supporting stroma, yet from the pathologic standpoint these terms are not correct, as every acute or subacute nephritis is in a sense diffuse. As far as pathologic investigation has been able to demonstrate, the condition of the kidney occurring during pregnancy is of the acute diffuse or parenchymatous type, with rapid degenerative changes. The etiologic factor is not definitely demonstrable. The most generally accepted theory is that of a severe toxemia, due to a grave disturbance of metabolism and elimination during the course of gestation. Although in this condition it was originally thought that the kidney was the organ to show the greatest disturbance, lately it has been demonstrated that it is often the liver which is chiefly affected, the kidney escaping without signs of any marked injury whatever.

The history of certain cases of retinitis, associated with this condition, seems to substantiate this view; namely, that other organs of the body can be primarily affected by the disease, the kidney showing little or no disturbance of its function. In 1908 Posey and Hirst[2] reported a case manifesting constitutional signs of toxemia with normal urine, in which there was extensive retinitis. In this case an early abortion was followed by complete restitution of vision. There were no clinical signs whatever of an involvement of the kidney. I have had under observation lately a case of like character. The patient (aged twenty-eight) was first seen January 17th, giving the following history: During her first pregnancy, which had occurred four years previously, she had undergone an attack of retinitis which resulted in complete loss of vision of the left eye. Despite the warning of her physician against further conception, the patient had twice gone to full term without retinal complications. But her fourth pregnancy, for which she was admitted to the

hospital, resulted disastrously. As nearly as could be determined, the vision of the right eye had begun to fail during the early part of pregnancy. About a week before the patient was first seen, the vision of this eye became rapidly worse. When examined, there was found to be only moderately good light perception. The retina showed very extensive involvement of the entire central portion. An intense edema, evidently beginning to subside, with large areas of exudation, showing the characteristic white appearance, and fringed by numerous hemorrhages, completely surrounded the disc, extending well beyond the macula.

The retina of the left eye, the one in which the vision had been destroyed four years before, showed large white atrophic spots bordered by heavy pigmentation, in the neighborhood of which areas of active inflammation could be seen. Artificial delivery was immediately performed. The child was apparently at full term. The inflammatory condition of the retina promptly began to subside, but at the end of two months vision still remained reduced to perception of light. When the patient was first admitted to the hospital, urinalysis failed to show the slightest trace of albumin or casts. The only signs of a general toxemia were an excessively high nervous state, occasionally bordering on mania, and a consuming thirst. Repeated urinalyses before and for two months after the delivery of the child failed to show any involvement of the kidney.

From its clinical history, the retinitis of pregnancy would seem to differ from the disease as found in the other forms of Bright's disease. The sudden onset, the tremendous exudation into the retina, the equally sudden cessation on removal of the cause (if done promptly enough), the subsequent and complete restitution of visual acuity, all are in marked contrast to the usual course of the retinitis of other forms of Bright's disease.

A satisfactory explanation for this is to be found in the

virulence of the toxins in the blood which cause the trouble, and the promptness with which the causative agent or agents can be removed. The immediate emptying of the uterus allows the active retinal inflammation to subside, with complete absorption of the accompanying exudate, before there occurs any destruction of retinal tissue with the formation of permanent deposits of hyalin.

As far as the clinical evidence can be relied upon, it seems logical to conclude that the immediate cause of the retinal changes is the same as that acting on the kidney and the liver. In the cases referred to above, the one of Posey and Hirst, the other reported in this paper, there existed without doubt a very active and wide-spread retinitis with no apparent involvement of the kidney—a typical so-called albuminuric retinitis without albuminuria.

The clinical course of the retinitis in chronic Bright's disease does not argue against this view of its method of development, even when appearing in the later stages of the contracted kidney. Here the active cause is of a very mild kind, years often elapsing before the changes in the kidney become a menace to life. As the destruction of the secreting portion of the kidney progresses, interference with proper elimination increases, forming thereby a vicious circle. It is, then, in the late stage when the retina becomes affected, a time when the toxins in the blood have reached the danger-mark. Up to this point in the development of the disease the retinal tissue has been able to offer successful resistance. In the severely acute cases—the most striking example being the toxemia of pregnancy—the offending agent or agents are exceedingly active. The kidney, the liver, or the retina may be attacked simultaneously, or the one before the other, depending on the native powers of resistance of the individual organ.

In 1908 I[3] published a detailed report, both clinical and pathologic, of three cases, one especially showing on post-mortem examination the acute diffuse type of involvement

of the kidney. In all three cases the retinitis had been of short duration, thereby offering an opportunity for pathologic examination of the disease in its early stage. As accurately as could be determined from the clinical history, the retinæ had been affected in one case fifteen days, in one twenty-nine days, and in the third about forty-three days.

The essential details of the important pathologic changes were identical in all three cases. The duration of the disease, as just estimated, is an important point to be remembered in studying these changes. They may be summarized briefly as follows:

Corresponding to the white areas as seen with the ophthalmoscope were found masses of exudate confined chiefly to the outer reticular layer, but occasionally extending into the outer nuclear layer, sometimes as far as the external limiting membrane (Fig. 1). The reaction of these masses to the different stains is quite characteristic, giving a definite picture of fibrin in various stages of metamorphosis into hyaline. These stages, in addition to the appearance of a general widespread edema, may be divided into three: First, a distinct network of fibrin, showing the characteristic reaction to Weigert's anilin-gentian-violet stain. Second, the masses here have lost the fine fibrillar appearance, no longer giving the reaction to the gentian-violet stain. The lines of the former fibrin network begin to coalesce into a more or less solid mass. In the third stage we find the masses have lost all fibrillar appearance, and show distinctly the properties, both chemical and as regards their reaction to the anilin stains, of hyalin (Fig. 2). The hyalin, especially in its reaction to the stains, shows varying degrees of development. In the early part of the process we find masses made up of numerous small round bodies which react more or less strongly to the stain, the intervening substance, being homogeneous, reacting not at all or slightly. In the advanced stage the masses are homogeneous, and react evenly and intensely throughout.

It is to be noticed that the retinal tissue itself is practically intact. In no single instance could fat be demonstrated, nor any signs of a fatty degeneration of the supporting fibers of Mueller. The sections hardened in osmic acid failed to demonstrate the presence of any form of fat cells.

This is in marked contrast to the findings of Leber,[4] who describes masses similar to those shown Figs. 1 and 2, yet who finds these composed chiefly of fat. According to Leber, these extensive deposits of fat represent the masses of white exudate seen with the ophthalmoscope during the course of the disease. He explains the origin of the fat, not as a degeneration of the fixed tissues, but as derived from pigment epithelial cells, which wander into the retina, and which, so to speak, act as carriers of fat. They become massed in both the outer and inner layers, especially in the nerve-fiber and ganglion-cell layers. Another source he finds in a fatty infiltration in which the serofibrinous exudation plays the greater part. This exudation carries the fat cells from the blood-stream into the retina.

Other investigators have failed to discover this extensive deposit of fat. Litten[7] was unable to demonstrate the presence of fat cells in any of his specimens, and Greeff only in small quantities. Krueckmann[6] has found extensive proliferation and fatty degeneration of the glia tissue, to which source he ascribes the origin of the ophthalmoscopic white spots in the retina. This Leber was unable to substantiate.

Lauber and Adamuek[5] also failed to find this wide-spread deposit of fat, but do claim to have demonstrated a derivative of fat—a substance which they style lipoid bodies. These bodies correspond chemically very closely to the derivatives of fat found in the kidney.

A probable explanation of these contradictory findings might be found in the duration of the retinal disease. The longer the disease lasts, the greater are the degenerative changes, with the eventual possible formation of fat as

Fig 1 —Fibrin in outer reticular and granular layers, undergoing hyaline metamorphosis. × 100.

a b

Fig. 2 —(*a*) Hyalin in different stages of development in outer reticular layer. (*b*) Affected ganglion cells, only a few retaining their normal position Notice normal position and character of cells on either side of affected area. × 100.

Fig. 3 —Hyalin in outer reticular layer in various stages of development. × 400.

described by Leber and Krueckmann. As mentioned above, the retinitis of the three cases which I reported had been of short duration, which might explain the complete absence of any fat formation. The lipoid bodies of Lauber and Adamuek could well represent an intermediate stage—a stage of beginning fatty degeneration.

Krueckmann's explanation of the origin of the ophthalmoscopic white spots, based on the proliferative and degenerative changes in the supporting or glia tissue, is not substantiated by my specimens. This proliferation and fatty degeneration of the glia tissue would not account for the reaction of these masses to the various stains. He also finds fibrin only in areas where hemorrhage has occurred. It is rare that I have found extravasated blood in the neighborhood of the fibrin and hyalin formations in the outer reticular layer. The hyalin is evidently derived from the colorless elements of the blood and certain migrating cells, a condition somewhat similar to the formation of hyalin in the pinguecula, as demonstrated by Fuchs, in no way depending on a degeneration of the fixed tissues.

The point I want to lay especial stress upon is that, in the early stage of the process, as represented by the three cases under consideration, the presence of fat cells of any kind was not demonstrable, even when the tissue was stained with osmic acid and examined in the fresh specimen.

Leber also takes occasion to deny certain changes in the ganglion cells of the ganglion-cell layer, which I described as having found in the retinæ of all three of my cases. He affirms the findings of Heinrich Mueller, who originally declared that the masses of ganglion-cell-like bodies discovered in the nerve-fiber layer were not ganglion cells, but were swellings, or, as he termed them, varicosities of the axis-cylinder processes. That these bodies were found chiefly in the nerve-fiber layer seems to be the main argument for this view. They are to be seen in those sections

showing the most extensive involvement of the retina generally. The sections in which they appear also show the large deposits of fibrin and hyalin in the outer reticular layer. That these bodies are actually ganglion cells, displaced into the nerve-fiber layer and undergoing hyaline degeneration, is the only explanation for the condition as illustrated in Figs. 3, 4, and 5.

They are seen in masses, both in the ganglion-cell and nerve-fiber layers (Fig. 3). In the first stage of the process the cells are found more or less in their normal position. They have become somewhat swollen; have lost the characteristic appearance of the normal cell. The Nissl bodies are found near the cell membrane, the cell retaining more or less its normal shape. The cell substance shows sometimes a fine fibrillar, sometimes a homogeneous appearance. In the more advanced stage, where the cells have lost their normal position and are found in the nerve-fiber layer, often as far as the internal limiting membrane (*a*, Fig. 4), they become greatly swollen, losing all characteristics of the normal ganglion cells, yet retaining a very noticeable similarity in shape to these cells. In this stage they react to the various stains in a manner remarkably similar to the masses of hyalin in the outer reticular layer. By hematoxylin and picric acid fuchsin (von Gieson) the central portion stains a dark red, while the cell substance takes a light yellowish-red color. With the combined eosin-hematoxylin, the central body, representing the nucleus, stains an intense red, while the surrounding cell substance is tinged a light red. By the use of the Benda iron-hematoxylin, the picture is that shown in Figs. 3 and 4.

The explanation for their displacement into the nerve-fiber layer is to be found in the method of development of the morbid process. The first stage of the disease is that of an edema. The extravasation takes place from the outer and inner plexuses of the small retinal vessels. From the

Fig. 4.—Ganglion cells displaced into nerve-fiber layer. (*a*) Cell lying against internal limiting membrane, with axis-cylinder process extending outward (*b*) Cells showing distinct limiting membrane with central intensely staining body, resembling a nucleus in appearance. × 400.

Fig. 5.—Displaced ganglion cells swollen to the size of 0.0275 mm. in diameter, yet retaining their characteristic shape. × 400.

former, lying at the outer border of the inner nuclear layer and at the inner border of the outer reticular layer, comes the exudation, which eventually forms the hyaline masses in the outer reticular layer. From the inner larger plexus the first effect of the edema is naturally on the adjacent ganglion-cell layer. By this exudation the cells are pushed into the nerve-fiber layer, become soaked with the albuminous fluid, eventually undergoing the hyaline changes which I have described.

Here I should like to emphasize the fact that I have been unable to demonstrate any signs of a fatty degeneration. The condition as just detailed, and the fact that in no single instance could a varicosity of an axis-cylinder process be demonstrated where the normal nerve-fiber could be followed in both directions from the swelling, as should be seen in serial section, leaves no doubt as to the nature of the bodies. This is especially well shown in Figs. 4 and 5.

The explanation of the formation of these bodies offered by Litten, and originally concurred in by Greeff,[8] that they were formed by the massing together of degenerated leukocytes, is contradicted by their shape and position, by their reaction to staining materials, and by the fact that free leukocytes are never found in the neighborhood of the nests.

Krueckmann's[6] contention that they are varicose nerve-fibers, broken off at one end, and enveloped in a mass of glia-cell protoplasm, also does not explain the condition as found in the sections under consideration. A distinct cell membrane, sharply defining the cell from the surrounding tissue, is invariably clearly demonstrable. In one specimen is beautifully seen an enormously swollen ganglion cell displaced far into the nerve-fiber layer, sharply defined in outline, with its axis-cylinder process extending to a considerable distance (*a*, Fig. 4). Another point of decided importance is that, where the affected ganglion cells have been

pushed into the nerve-fiber layer, the ganglion-cell layer itself is emptied of its normal supply of cells—in fact, in some places it is entirely free of any normal ganglion cells whatever. When one, on the contrary, examines the layer to each side of the affected area, it is found that the cells are normal both in number and in character.

In regard to the question of the dependence of the retinal disease on changes in the retinal vessels, which changes cause interference with the proper nutrition, to which is attributed the morbid process (a view held by Carl Theoreor, von Michel, Weeks, and others, and lately by Krueckmann), I still maintain the position which I advocated some ten years ago, and which has been well demonstrated by the investigations of Schieck[9] and Opin et Rochon-Duvigneaud[10]—namely, that there are cases of marked involvement of the retina in Bright's disease where the retinal and choroidal vessels are practically normal. The most reasonable explanation, then, for the development of the disease in the retina is that the toxins of the blood act as the direct offending agent, and this before affecting the vessels to an extent histologically demonstrable.

REFERENCES.

1. Adami: "Text-Book on General Pathology."
2. Posey and Hirst: Jour. Amer. Med. Assoc., March 14, 1908.
3. Semple: "Pathology of the Retina in Bright's Disease," Amer Jour. of Ophth., March, 1908.
4. Leber: "Ueber d. Entstehungsweise der nephritischen Netzhauterkrankung.," v. Graefe's Arch., lxx, S. 200 ff.
5. Lauber u. Adamük: "Ueber d. vorkommen von doppelbrechendem Lipoid in d. Netzhaut bei Retinitis albuminurica," etc., v. Graefe's Archiv, lxxi, S. 429 ff.
6. Krueckmann: "Ueber Netzhautdegeneration, insbesondere im Anschluss an Arteriosklerose," Bericht über d. 33. Vers. d. Oph. Ges., 66 ff.
7. Litten: "Ueber Veränderungen der Retina bei Nephritis," Münch. med. Wochensch., S. 361, 1903.
8. Greeff: "Pathologisches Anat. d. Auges."
9. Schieck: "Ueber Retinitis albuminurica," v. Bericht über d. 34. Vers. d. Ophth. Ges., 1907, S. 77.
10. Opin et Rochon-Duvigneaud: "Recherches sur les lesions comparées de la rétine et des autres organes chez les malades atteints de rétin te albumenurique," Jour. de Physiol. et de Pathol. gen., v, Nov., 1903, "Sur la pathogenie de la rétinite albumenurique," ibid., vi, Jan., 1904.

PROBABLE CYST OF THE RETINA, WITH A DEMONSTRATION OF THE PATIENT.

GEORGE S. DERBY, M.D.,

Boston, Mass.

The case which I wish to show is, if my diagnosis be correct, interesting because of its comparative rarity. It is well known that cystic spaces in the retina, the result of edema or degeneration of the retina, are often found at the pathologic examination of an eye. Iwanoff's cysts occurring just back of the ora serrata are very frequently seen, especially in old age. The occurrence of cysts in retinal detachments of long standing is also not infrequent. They may be numerous and reach a considerable size. Parsons,[1] in his "Pathology of the Eye," discusses the subject and gives a number of references, while more recently the paper of Fujita has appeared, in which three cases are reported and a bibliography given.

If cyst formation in the retina be of comparatively frequent occurrence pathologically, why is it so seldom observed with the ophthalmoscope? The answer to this question is probably found in the fact that cyst formation of sufficient size to be recognized clinically usually does not develop until after a separation of the retina has taken place, and in such eyes the media are likely to have undergone changes which will make a satisfactory fundus examination difficult, if not impossible. As a matter of fact, however, it may be surmised that a careful examination of our cases of retinal detachment, with the question of cyst in mind, may disclose the fact that this lesion is, after all, not so much of a rarity

as now appears. Leber[2] said, over thirty years ago, in the first edition of Graefe-Saemisch: "It is possible that some cases which, from the ophthalmoscopic examination, are believed to be detachment should more rightly be regarded as cystic degeneration."

The number of instances in which retinal cysts have been observed clinically appears to be comparatively few. In the text-books of the present day one does not find mention of them under disease of the retina, although in the older works, such as Graefe-Saemisch, first edition, de Wecker, Soelberg Wells, etc., allusion is made to cysts of the retina, but from the text it is impossible to ascertain whether the reference is to cysts found in enucleated eyes or in the living.

Parsons makes the statement that cysts have not infrequently been diagnosed clinically from ophthalmoscopic appearances. If so, many of these cases have not been published. "Clinical observations of retinal cysts have been made by Merkel in the dog and by Eversbusch in an old horse and a calf."[3]

The first case the writer has been able to find, and the one which rests on the firmest basis, although it was not a true retinal cyst, is that of Panas and Darier.[4] This was a woman whose left eye had been removed ten years previously for an intraocular tumor. For two years she had noticed in the right eye the same difficulties that had appeared previously in the left.

With the ophthalmoscope was found in the lower external part of the retina a rounded mass the size of the optic disc, of grayish-white color, and with a reddish spot in the center made up of small vessels. This mass protruded into the vitreous. The retina appeared separated from the disc to the tumor. The tumor did not increase in size. The case was watched three to four years, and the vision diminished slowly until, at the time of publication, it was only quantitative perception of light.

The left eye had been removed for probable sarcoma of the choroid. There was a yellowish, globular mass behind the lens, covered with retinal vessels.

The pathologic examination showed a distended cyst filling the eye, formed anteriorly by the retina and posteriorly by the choroid. As the clinical appearance in the second eye resembled that in the first, and as the course of the disease was the same, it seems fair to assume that a cyst formation was taking place in that eye also.

In July, 1890, Marcus Gunn[5] exhibited before the Ophthalmological Society of the United Kingdom a little girl with an eye showing congenital microphthalmos. The lymphatics of the conjunctiva were very much enlarged and tortuous. With the ophthalmoscope a raised pale patch could be seen in the fundus. The condition of the conjunctiva suggested a similar condition in the retina.

In 1893, in an extensive paper on "The Pathology of Intraocular Cysts," Treacher Collins[6] described a case which had been observed clinically by Tweedy. "From the upper and lower borders of the optic disc was a broad white band, like opaque nerve-fibers, which extended circularly around the macula region. The area thus enclosed formed a prominence at the posterior pole of the eye, having a circumference of about five discs' breadth." As a new-growth was believed to exist, the eye was excised. Pathologically, this prominence was formed by a cyst measuring 6 mm. laterally. It had developed between the outer and inner nuclear layers of the retina.

J. Tatham Thompson[7] describes a case of retinal separation following a blow on the eye. The separation was extensive. At one point a cyst was seen projecting forward so as to hide a portion of the disc. It was transparent, and a few small retinal vessels ran over its surface. A colored plate accompanies the article.

The case which I take pleasure in showing here to you for

your opinion came to my office on the second of last March. Two and one-half years ago the sight of the patient's left eye began to fail, and a few months later the right eye followed suit. Two years ago he was in poor health, and was in the Boston City Hospital two months for what he calls "typhoid pneumonia." Since that time he has not felt very well. He is forty years of age, a laborer, is married, has one healthy child; denies venereal infection, but says that at one time he used alcohol to slight excess.

Vision right, $\frac{2}{60}$; vision left, can distinguish hand movements at six feet.

In the right eye the lower and outer parts of the visual field are present. In the left the lower and temporal quadrant of the field remains.

Examination shows normal corneæ and anterior chambers, pupils of equal size, which react sluggishly to light.

The right eye shows clear lens and numerous large and small floating vitreous opacities. There is a transparent separation of the retina in the whole lower half of field, extending up to the disc and well above it on the temporal side. Running forward and downward on the nasal side of the fundus are several whitish bands of tissue. Down low in the separated retina are a number of glistening whitish spots. Running upward and inward from the disc along the vessels is a line of whitish tissue with dark areas of pigmentation which seem to mark a boundary between the separated retina on the temporal side and the normal retina on the nasal side.

The optic disc is whiter than normal, and shows an atrophic excavation. On the temporal side of the disc, and overhanging it, is a rounded prominence of pear-shaped outline, with the neck of the pear overhanging the disc. This ascends steeply from the disc and is sharply outlined, as it is also along its temporal border. The upper and lower borders are not so sharply defined, yet they are distinct from the surrounding separated retina.

Running over the surface of the tumor are a few small, tortuous retinal vessels. The apex of the tumor is best seen with a +6 lens. The vessels leaving the disc can be seen well without a glass. The tumor is of a translucent appearance, and gives a greenish reflex on its outer border. In size it is slightly smaller than the disc.

In the outer part of the fundus can be seen part of a rounded, globular swelling of considerable size, translucent in appearance, with a greenish reflex where it swells forward from the surrounding separated retina, probably also of a cystic nature.

The left eye shows a triangular opacity of the lens below; the reflex is dull gray, except upward and inward, where a fairly good red reflex may be obtained. There is probably almost total separation of the retina here.

The ophthalmoscopic appearance of the case has not changed to any great extent since he was first seen, except for a probable slight increase in the size of the growth and an increase in the amount of separation upward. The growth is now somewhat larger than the optic disc.

A choroidal tumor lying beneath the separated retina cannot, of course, be ruled out, but the separation is present in both eyes, and the localized protrusion in the right eye certainly appears to be in the separated retina itself, and could hardly be produced by a growth pressing forward from behind.

It is interesting to note that in two of the cases I have alluded to, those of Treacher Collins and Tatham Thompson, the situation of the cyst was similar to that in the case reported here. In Thompson's case the cyst projected forward so as to hide a portion of the disc.

REFERENCES.

1. Parsons: The Pathology of the Eye, New York, 1905, pp. 623 to 625.
2. Leber: Graefe-Saemisch Handbuch, first edition, vol. v, p. 702.
3. Parsons: Loc. cit., p. 625.
4. Darier: Archiv d'Ophtalmologie, vol. x, p. 203.
5. Gunn: Trans. Ophthal. Society of the United Kingdom, vol. x, 1890.
6. Collins: Royal London Ophthalmic Hospital Reports, vol. xiii, p. 41.
7. Thompson: Trans. Ophthal. Society of the United Kingdom, 1890, x, 151.

REPORT OF TWO CASES OF PULSATING EXOPHTHALMOS. RELIEF OF ONE BY LIGATION OF THE COMMON CAROTID; RELIEF OF THE OTHER BY LIGATION OF THE COMMON CAROTID, FOLLOWED AFTER RECURRENCE BY LIGATION OF THE INTERNAL CAROTID.

WILLIAM H. WILDER, M.D.,
Chicago, Ill.

Cases of pulsating exophthalmos are so infrequent that I feel warranted in placing on record two cases that I have observed in the last year.

Although in one of them pulsation of the eyeball could not with certainty be demonstrated, it unquestionably belonged to the class of cases designated by this term, inasmuch as it presented all the classic signs except the pulsation, which cannot always be detected.

CASE 1.—Wallace C., aged forty-two, an American, was admitted to the Presbyterian Hospital, October 31, 1910, and gave the following history: Three weeks previously, when returning home from his work late at night, he was waylaid by a thug, who hit him over the right eye, the blow making him unconscious. He was discovered in this state by an officer, who took him home. On recovering consciousness, he found that the lids of the right eye were badly bruised and swollen, and those of the left eye were also much discolored. On separating the lids of the right eye, he noticed that the sight of it was not impaired, but that with both eyes open, objects appeared double.

He experienced severe pain in the right side of the head, but this pain was intermittent in character, lasting from twenty minutes to an hour, after which he would be relieved

of it for a time. After some days the attacks became more severe and more frequent, and he sought relief at a hospital.

With recovery of consciousness after the blow he noticed a roaring in the right ear, which persisted, and sounded to him like a steam-exhaust. The right eyeball began to protrude, and the swelling of the lids did not diminish. The pain in the head became constant, and radiated to the back of the neck, the shoulders, and the spine, and opiates were necessary to give him relief.

After two weeks without obtaining relief, he left the hospital where he had been, and entered my service at the Presbyterian Hospital, October 31, 1910. Examination showed a marked protrusion of the right eye. The conjunctiva was ecchymotic and swollen with edema, so that a fold of it presented between the half-closed eyelids.

The conjunctival veins of the eyeball, as well as those of the eyelids, were engorged, and there was a marked distention of the angular vein at the superior border of the orbit.

The cornea was clear and its surface unbroken.

The pupil was dilated to about 7 mm., and was inactive to light and efforts of accommodation. The mobility of the right eyeball was reduced so that the patient could only slightly abduct it, and the levator palpebræ was also powerless. R. V. $= \frac{20}{60}$; L. V. $= \frac{20}{20}$. The fields seemed normal for form; colors not tested. The media of the right eye were perfectly clear and allowed a good view of the fundus, which was not altered except that the retinal veins were somewhat engorged. The optic disc was slightly redder than normal, but was otherwise unchanged.

The left eye appeared normal in every particular. Examination of the ears showed no change in the ear-drums. The membranes were normal in appearance and showed no sign of a previous rupture. The hearing seemed to be normal, but could not be accurately determined on the right side because of the constant roaring tinnitus, which the patient likened to hissing steam. A marked bruit, most intense with the cardiac systole, could be heard over the right side of the head and over the right eye. It was most pronounced when the stethoscope was placed over the middle of the zygomatic arch. At times it could be faintly heard over the left temple and over the left eye.

The bruit and the subjective noises ceased when the common carotid was firmly compressed. It was doubtful whether there was any pulsation of the orbital contents, even when the patient was made to bend forward, at which time the swelling was increased.

The diagnosis of exophthalmos from aneurism of the intracranial portion of the internal carotid was made, and ligation was advised. The pain in the head, extending down the back of neck and the back, was constant, and at times so excruciating that hypodermics of morphin had to be used to relieve it. Dr. A. D. Bevan, professor of surgery at Rush Medical College, saw the case, and agreed that the right common carotid should be ligated.

Accordingly, this was done by Dr. Bevan, November 10, 1911. The bruit ceased immediately after the ligation, and when the patient recovered from the anesthetic the noises were not heard. The pain in the head persisted for more than a week, requiring anodynes for its relief; however, this gradually diminished, so that at the end of ten days he was very comfortable. The exophthalmos was not immediately relieved, but disappeared slowly. The swollen conjunctiva of the lower fornix protruded in a fold between the lids, and required massage and astringent treatment for two or three weeks to get it back into place. The mobility of the eye slowly returned, the pupil regained its normal size, and the vision of the right eye improved in about five weeks to $\frac{20}{30}$.

At the time of his discharge from the hospital, December 13, 1910, no bruit could be heard, but he suffered occasionally from neuralgic pains in the right side of the head and face.

I am inclined to think that in this case there was an aneurism of the cavernous portion of the internal carotid that did not communicate directly with the sinus.

CASE 2.—C. O., aged thirty-eight, a laborer, entered my service at the Illinois Eye and Ear Infirmary, November 22, 1910, and gave the following history: While in a saloon, five or six months before, he was struck on the back of the head with a beer bottle and was rendered unconscious for some minutes by the blow.

He lost consciousness again while being taken to the hospital on a street-car. At the hospital an operation was done on his head, and he thinks a piece of bone was removed and a silver plate inserted to close the opening in the skull. He regained consciousness after this operation, and recovered within three weeks so that he was able to leave the institution and go to work as a helper in a bowling alley, feeling very well. Some two months later, and about three months before I first saw him, he was waylaid by a ruffian who hit him on the back of the head with an iron bar, knocking him senseless. He was taken in an ambulance to the Michael Reese Hospital of Chicago, where a wound in the scalp was mended, and he left in four days apparently well.

However, two weeks after leaving the latter institution he began to experience headache and to hear noises in his head and right ear. These continued steadily, and five weeks later—that is, seven weeks after receiving the last injury—he noticed that his right eye was becoming very prominent, and some weeks later this had increased considerably, and he began to have pain in the eye and lacrimation. He then appeared at the Infirmary for relief.

Examination showed a man about 5 feet 5 inches in height, physically well developed. His right eye protruded about 10 mm. compared with the left, which was apparently normal, and was directed downward and outward. Mobility of the right eye was limited to abduction and outward rotation. All muscles of that eye supplied by the third nerve (oculomotorius) seemed to be paralyzed; those supplied by the fourth and sixth seemed to be unimpaired, and sensation was retained. There was no facial palsy. The pupil was dilated to 6 mm., and he was unable to raise the right upper lid. There was marked chemosis of the conjunctiva of the eyeball and the fornix, with engorgement of the veins, which was increased when the patient bent forward. The angular vein was not markedly distended.

The refractive media were perfectly clear and the fundus of that eye normal, except for some engorgement of the retinal veins, which were darker and more distended than normal. R. V. $=\frac{20}{40}$; L. V. $=\frac{20}{30}$. Tension of the right, slightly plus. A high-pitched bruit, synchronous with the heart-beat, could be heard on listening over any part of the

patient's head, but it was more intense over the temporal region of the right side and over the right eye.

This was a blowing bruit, the greatest intensity of which was synchronous with the cardiac systole. A very slight pulsation of the orbital contents could be seen and felt, more noticeable if the patient leaned forward.

Pulse, 70; respiration, 18; temperature, 98°; urine normal. The patient complained of deep-seated orbital pain and of roaring noises in the head, like a "waterfall." The ear-drums showed no signs of rupture and were apparently normal. Hearing was normal. The head noises and the bruit ceased when circulation through the common carotid was stopped by compression.

Diagnosis was made of an aneurism of the right internal carotid artery in or near the cavernous sinus, and ligation of the right common carotid was advised. The operation was performed by Dr. A. D. Bevan, at the Presbyterian Hospital, December 12, 1910, and immediately after the ligation the bruit ceased.

The recovery from the operation was uneventful, and the patient was relieved at once of the disquieting noises in the head, and felt no pain.

In two weeks' time the eye had receded into the orbital cavity so that the exophthalmos amounted to only a few millimeters and the chemosis of the inferior portion of the conjunctiva was greatly reduced.

There was partial recovery from the paralysis of the third nerve, but the pupil was still immobile and enlarged. Improvement continued, and in about six weeks the edema of the conjunctiva had disappeared.

The vision of the right eye at this time was $\frac{20}{60}$, and the retinal veins were still considerably enlarged. About this time, January 28, 1911, the patient began to have hissing noises in the head occasionally, especially on arising in the morning, and at such times the eyeball became more prominent, but it would recede after he had been up for some minutes. Repeated examinations at various times failed to reveal any bruit or murmur; but some weeks later Dr. Clifford Smith, interne at the Eye and Ear Infirmary, was certain that he could detect at times a faint bruit when the stethoscope was placed above the right mastoid, and also

in the region of the right temple. This was confirmed by others some time later, but the intensity of the bruit seemed to vary from time to time and was never very pronounced.

Four months after the ligation of the common carotid it was clear that the exophthalmos was returning, although not to the same degree as before, and the bruit could be faintly heard over the temple. The vision of the eye remained about as before, $\frac{20}{60}$, the eyeball was fairly mobile, and there was no pulsation of the contents of the orbit. It was decided to ligate the internal carotid, and the patient was referred again to Dr. Bevan, who operated April 15, 1911.

The incision was made over the proper place for the exposure of this vessel, but when the ligature was placed around it, it was noticed that the bruit did not cease. The wound was then considerably enlarged, and the bifurcation of the carotid was found at least 4 cm. above its normal point. In the course of the operation the facial vein was tied, and finally the internal carotid was ligated with catgut.

The wound healed promptly. About three days after the operation the patient developed complete paralysis of the muscles of the left forearm and hand, and also had difficulty of speech, mumbling his words, although he had no amnesia.

He had no pain in the eye or head, and he was free of the hissing noises that had been present for weeks. Gradually he recovered his power of speech, so that in three weeks it was nearly normal. The muscular power of the left hand and forearm slowly returned, but the recovery was not complete at the time I last saw him, about one month ago. At that time the exophthalmos was very slight, the mobility of the eyeball was good, the right pupil was 1 mm. larger than the left, and responded to light and accommodation. The veins of the right retina were less prominent than formerly, but larger than those of the left eye. R. V. $= \frac{20}{50}$; L. V. $= \frac{20}{20}$.

Probably in both of these cases there was aneurism of the internal carotid in or near its cavernous portion.

The absence of pulsation of the eyeball and orbital contents in the first case, and the faint pulsation in the second case, would seem to indicate that the aneurism was not

arteriovenous in character, or if so, that the communication between the artery and sinus was very small.

In Case 1 the veins at the superior nasal angle of the orbit were distended, but not as much as one would expect if there was a direct communication between artery and sinus.

In Case 2 there was a general engorgement of the veins of the orbit, such as one would expect from a retardation of the venous circulation by pressure upon the sinus, and in such a condition a faint pulsation might be imparted to the venous column.

In considering these points, it was decided to first ligate the common carotid artery.

The combined statistics of Reuchlin and de Schweinitz show that in 150 cases of ligation of the common carotid for this trouble, cure or improvement resulted in 97, or 64.6%; failure resulted in 38, or 25.3%; and death occurred in 15, or 10%.

Ligation of the common carotid is a safer procedure than ligation of the internal, because of the liberal anastomosis between the right and left external carotids through the branches of the occipital, temporal, external maxillary, and thyroid arteries. These allow some blood to flow back around the bifurcation of the common carotid, and hence the brain is not so suddenly exsanguinated as it would be if the internal carotid was tied.

In the second case, even after the lapse of several months after the tying of the common carotid, apparently a long enough time for the establishment of a collateral circulation, ligation of the internal was followed by aphasia and motor paralysis of the arm as described.

However, ligation of the internal carotid on the side of the exophthalmos, after recurrence of the bruit, seemed to us a wiser procedure than ligation of the other common carotid (as has sometimes been done), a course that seemed to be justified by the final result.

DISCUSSION.

DR. SAMUEL D. RISLEY, Philadelphia: I should like to inquire of Dr. Wilder whether, after the ligation of the arteries, there were intraocular hemorrhages in either of the cases reported. Some time ago I reported one instance, which also occurred after a debauch and an injury. This patient came to the Wills Hospital with exophthalmos and a distinct bruit, transmitted to all parts of the head. It was audible to the patient, which he called a "water-fall in the head." He was placed in bed and I sought to establish partial collateral circulation by intermittent pressure made on the carotids, which would invariably stop the bruit while the pressure was maintained. I therefore employed this from time to time, keeping it up as long as the patient could bear it. Then the internal carotid was tied, with the result of complete relief. Forty-eight hours afterward, when I made an ophthalmoscopic examination, extensive hemorrhages were found in the fundus which were not present before the operation.

DR. CARL FISHER, Rochester: A case was operated on about a year ago by Dr. Charles Mayo. The right eye had been lost from a pulsating exophthalmos, and there had been an attempted ligation of the orbital veins and later ligation of the common carotid. Seven years ago the patient developed pulsating exophthalmos of the left eye, with enormously distended veins over the forehead, and the eye almost extruded between the lids. Although the pulsation and bruit were extremely annoying, she continued to teach school. The vision remained fair, but was slowly diminishing. Ligation of the remaining carotid would be attended with too great risk. Encouraged by the results of Dr. Matas, of New Orleans, who found that he could compress the artery seventy hours without getting occlusion, Dr. Charles Mayo, under cocain anesthesia, took a stout spring of tin, which he clamped on the artery until objects got black before the patient's eyes. He then closed the artery as much as was consistent with safety, which stopped the bruit. The object was to develop collateral circulation through the basilar arteries. The latest reports from the patient have been fairly encouraging. Vision has improved,

and the other symptoms are enough better to make the patient much more hopeful.

DR. EMIL GRUENING, New York: I have had two cases of pulsating exophthalmos, both operated on by ligation of the common carotid. There was almost immediate improvement of the sight, and no hemorrhages occurred.

DR. G. E. DE SCHWEINITZ, Philadelphia: I desire to correct a statement in the monograph written by myself and Dr. T. B. Holloway on "Pulsating Exophthalmos." In this monograph we say that at the time of its publication no ultimate unfavorable results had followed the orbital operation, although in some cases temporary alarming brain symptoms had developed. Based upon these data, which were believed to be facts at that time, it was concluded that, if a distended vein could be felt in the orbit, its ligation should be the operation of choice and that, inasmuch as in at least 28 per cent. of the reported cases such a pulsating venous mass was evident, it was possible that in future orbital operations would take precedence, and that such operations should be considered before ligation of the carotid, and certainly should precede ligation of the common carotid, provided that the second operation had failed to produce the desired result. After publication of this monograph the authors learned of one fatal case not reported in literature, in which exactly the condition arose to which Dr. Wilder had referred, namely, after ligation of the vessels at the angle of the orbit venous thrombosis and death occurred. Had we known of this case at the time the monograph was written,—a knowledge we could not have had, inasmuch as it had not been published,—we might have modified the statement which has just been quoted.

DR. W. H. WILDER, Chicago: In answer to Dr. Risley, I might say that there were no retinal hemorrhages in either of the cases. It struck me as rather unusual that in both of them there was not the amount of distention of the retinal veins that one would expect, considering the engorgement of the veins in the vicinity, and nothing like the amount seen in the case that I reported to the Society some years ago. The question comes up whether one should

resort to compression of the artery as a temporary expedient, or should ligate such large vessels as the common or internal carotid; or whether one should practise the procedure mentioned by Dr. de Schweinitz, ligation of the ophthalmic vein. I should hesitate to do the latter operation until I had resorted to other procedures. If there were an arteriovenous aneurism with a rather large connection between artery and vein, there might be considerable risk of a thrombus extending back and filling the sinus, with the attending danger of embolism somewhere in the body, particularly in the brain. In these cases we decided to ligate the common carotid, and, after doing so, we were surprised to find the bruit returning so promptly in the second case; but the results showed the value of doing first a ligation of the common rather than of the internal carotid, because, owing to the collateral circulation, the brain does not become so suddenly exsanguinated when the former artery is ligated.

CONCERNING CERTAIN TUMORS OF THE ORBIT, AND CERTAIN CONDITIONS SIMULATING NEOPLASMS OF THE ORBIT, BEING A CLINICO-PATHOLOGIC CONTRIBUTION, WITH THE REPORT OF SIX CASES.

G. E. DE SCHWEINITZ, M.D.,
Philadelphia.

This paper concerns itself with several case histories bearing upon questions related to the diagnosis and treatment of orbital growths and conditions simulating neoplasms of this region.

CASE 1.—*Spindle-celled Sarcoma of the Orbit Which in Its Earlier Stages Simulated Unilateral Exophthalmic Goiter.**—The patient, a woman aged twenty-two, consulted Dr. H. Maxwell Langdon on the 24th of June, 1907, and gave the following history: Her mother was neurotic and had goiter, but no exophthalmos. A maternal grandmother died of cancer of the throat; other family history has, so far as is known, no bearing on the conditions about to be described.

During 1901, or six years prior to this consultation, the patient noted that the left eye was more prominent than the right. This proptosis appeared suddenly, according to her statement, and apparently followed a severe fright as the result of a "brutal ducking in salt water." The mother of the patient, however, believes that the exophthalmos was of gradual development. For two years she was under the care of an oculist, but I have not been able to ascertain what the symptoms were during this time, or what were the results of treatment. Later she consulted two other ocu-

* This case has been reported in part by Drs. de Schweinitz and Langdon before the Ophthalmic Section of the College of Physicians of Philadelphia, but has not been published except in a brief abstract (Ophthalmic Record, xix, 1910, p. 248).

lists, who, with a neurologist in consultation, came to the conclusion that the condition was best explained by assuming the presence of unilateral exophthalmic goiter. Their notes record that the patient had been nervous, was easily excited, had occasional palpitation of the heart, and was usually warmer than other people, but there was no tremor of the hands, no Graefe's and no Moebius's sign. The neck was enlarged, and this enlargement was at first confined to the left side, but later implicated the right side. The pulse was 82; the patellar reflexes were probably a little exaggerated. The long duration of the process and the escape of the orbital nerves were deemed to be points in favor of the diagnosis of Graves' disease.

During 1905 the patient submitted to a rest-cure for five weeks, took syrup of hydriodic acid for three or four months, iron in various forms for a number of months, and wore a pressure bandage. A trial of thyroid extract was also made. In spite of this treatment, careful measurement by her physician indicated that an increase of about 1 cm. in the size of her neck had taken place during this period of time.

In April, 1906, an examination of the accessory sinuses was made by Dr. Walter Freeman, who, impressed with the fact that the trouble had started after the previously reported ducking in salt water, thought that there might be a mucocele of one or more of the ethmoid cells, probably of those belonging to the posterior group, but was unwilling to make a positive diagnosis without opportunity for further study.

At about this period, namely, on the 12th of December, 1905, or four years after the first appearance of the exophthalmos, I saw the patient in consultation with the physician then in charge, Dr. Swindells, and found visual acuteness normal after the correction of a mixed astigmatism of the right and a compound hyperopic astigmatism of the left eye. Each fundus oculi was normal. Left exophthalmos was present, the eyeball being displaced forward and downward, that is, the apex of the left cornea was 1 cm. lower than the right. None of the ordinary signs of exophthalmic goiter was present. There was loss of the upward movement of the eye, owing to complete paralysis of the left superior rectus; the outward and upward-inward move-

ments of the eyeball were restricted; other rotations were practically unaffected. *X*-ray pictures made by Dr. William M. Sweet at about this time were negative. While no positive growth could be felt by palpation of the orbit, it seemed to Dr. Swindells and to me that a neoplasm was present.

During the following year the patient consulted a number of physicians and reported that they believed the condition was best explained by assuming a unilateral exophthalmos as the result of Graves' disease.

When the patient came under the care of Dr. Langdon, namely, on June 24, 1907, the conditions were as follows: Right eye normal externally and intraocularly, vision $\frac{6}{5}$, full rotations. Left eye proptosed 1 cm. beyond the level of O. D., conjunctiva slightly everted, engorged, and catarrhal, cornea clear; the ocular rotations were somewhat limited in all directions, especially up and in; the fundus was normal, with no engorgement of the veins or alteration in color of the disc. The field of vision was normal. No bruit was audible over the globe, nor could any pulsation be felt. No enlargement of the thyroid was demonstrable; the pulse was 105; there was no tremor.

In view of the continued and increased proptosis, the loss of rotation, the firm resistance to pressure, and the impossibility of reducing the globe to its normal place, it seemed to Dr. Langdon that there must be some force back of it which was pushing it forward.

The patient was again sent to the neurologist who had originally examined her, and who had made a diagnosis of unilateral exophthalmic goiter. While unwilling definitely to abandon that diagnosis, he admitted its improbability, and was inclined to the belief that some local cause for the exophthalmos was present, probably a benign growth, which was forcing the eye forward without involving the orbital nerves.

Dr. Freeman was also at this time unable to arrive at a positive diagnosis, but in view of the fact that there was a slight protrusion of the wall of the sphenoid sinus as compared with that of the right side, and because he was unable to enter the cavity with a probe, and because the signs of ethmoid disease were absent, he believed it possible

that the sphenoid sinus might be the seat of disease. He hesitated to recommend an exploration of the orbit only because of the decided opinion which had been given by various physicians that the case was one of exophthalmic goiter, and that operation was not justifiable; otherwise he would have considered such an exploration of the orbit entirely justified, and in this respect he was in accord with

Fig. 1.—Visual field, left eye, Case 1. Sarcoma of orbit. Beginning contraction of form and colors.

the opinion which had been given by me when I first examined the patient.

In October of that year, or two months after the examinations which have just been described were made, the patient was married, and two months later was again examined by Dr. Langdon and the conditions already recorded were found to be present, but in greater degree. The bulbar conjunctiva was now quite everted and engorged, and the vision $\frac{6}{6}$ partly in each eye. One month later I again saw this

patient in consultation with Dr. Langdon, and found increased exophthalmos and immobility of the globe still present, and beginning pallor of the disc. The visual field was slightly contracted (Fig. 1).

She was admitted to the University Hospital for further study, and in the mean time the surgeon under whose care she had been two years prior to this time was consulted by letter in order that he might state why he had opposed operative interference. He sent the following interesting communication: "I examined Mrs. Y. on November 29, 1906. I found a myopic astigmatism of 1 D., axis 20 degrees in R. E. and 60 degrees in L. E. With the correcting lenses vision was $\frac{15}{15}$ in each eye. There was a marked exophoria for all distances. The media were clear, but in the left eye there was a general retinal edema and engorgement of the veins. The left eye protruded forward, downward, and outward, and the eye showed all the signs of Graves' disease. The left lobe of the thyroid was perceptibly enlarged. Tension and field were normal. The tachycardia was pronounced, the pulse varying from 120 to 145. The iris and pupil were normal in color, size, and reaction. The patient was very nervous, so that I was obliged to interrupt the examination several times. I made a careful rhinoscopic examination, but could detect no growth. I examined the orbit very carefully, but could not detect any growth. I used transillumination exhaustively, but could discover nothing abnormal in the orbit or any of the neighboring sinuses. There was no paralysis of any ocular muscle, and the motility of the eye was unimpaired. At that time she was under the care of a physician who had advised thyroidectomy, but this I advised against. At the time I saw her, therefore, I could not detect the presence of any orbital growth."

This examination was made about one year after the original diagnosis of unilateral exophthalmic goiter had been formulated, and one year before I first examined the patient, when I failed to find any evidence of Graves' disease, but when I felt reasonably sure that a growth was situated in the orbit.

In view of the uncertainty of the diagnosis and the difference of opinion, after consultation with Dr. Edward Martin,

Fig. 2.—Case 1. Sarcoma of orbit, late stage; narked exophthalmos and eversion of conjunc-iva. Front view.

Fig. 3.—Case 1. Sarcoma of orbit, late stage. Side view.



Fig. 4.—Case 2. Sarcoma of orbit simulating ›ulsating exophthalmos. Front view, showing ‹xophthalmos, downward displacement, and pul-ating swelling at inner angle of orbit.

Fig. 5.—Case 2. Sarcoma of orbit simulating pulsating exophthalmos. Side view, showing enlargement of veins in temporal region.

it was decided, before proceeding to operative interference, to try the effect of *x*-ray treatment. The reaction from the exposures was so severe, and the conjunctivitis which they produced so active, that they had to be discontinued.

At this time the patient was called to one of the western States, and was again advised to submit to an exploratory operation, but declined. The exophthalmos continued to increase and the eversion of the conjunctiva to become greater. Severe headache now developed, and reduction of visual acuteness was marked. In June, 1909, the patient returned to Philadelphia, presenting the appearances depicted in Figs. 2 and 3.

Evidently there was a large growth in the orbit, but what its nature was,—that is to say, whether solid, cystic, or intensely vascular,—was uncertain. Exploratory operation was strongly urged, and permission was obtained to eviscerate the entire orbital contents if necessary.

Operation.—Drs. Edward Martin, H. Maxwell Langdon, and the resident physician, Dr. Viehe, assisting, on June 25, 1909, I operated as follows: An incision was made beneath the entire length of the orbital arch and continued slightly downward and outward along the outer margin of the orbit. Immediately a large, bluish-red mass, which occupied the upper and inner, as well as the outer and posterior, portion of the orbit, and which was exterior to the cone of the muscles, was exposed. It was encapsulated so far as its anterior surface was concerned, and was firmly attached to the periosteum of the roof and side of the orbit. Without much difficulty the entire mass was enucleated, and with surprisingly little hemorrhage. As the growth approached the inner and central portion of the orbit, the capsule appeared to be incomplete. Scattered between the muscles in the cone, that is, between the superior rectus and external rectus, as well as still further inward, there were several masses of very suspicious-looking tissue. Moreover, the periosteum was involved, and when it was stripped from the roof and side of the orbit, the bone beneath it was eroded

and implicated. Under these circumstances, and considering the clinical appearances of the growth, which were so strongly suggestive of sarcoma, Dr. Martin urged that the surgical necessities of the occasion demanded complete evisceration of the orbital contents, an operation which was consequently immediately performed. The eroded and involved orbital bones were carefully cureted and subsequently cauterized with the glowing blade of a Paquelin cautery. The lids were not sacrificed, the cavity of the orbit was packed with gauze, and the incision closed with interrupted sutures. The patient's recovery was uninterrupted. Later it was suggested to the patient that the ciliary margin should be removed and the lids closed over the cavity in the manner recommended by Haab and other surgeons. To this operation, however, she was disinclined, and therefore the lids were left in place. The cavity gradually contracted, and the lids ultimately covered the small shallow depression. The patient has last been heard from a few weeks ago, and reports herself in perfect health, having gained in weight and lost her headaches. She is entirely contented with the outcome of the case.

Pathologic Examination of the Growth.—The tumor mass removed is about 24 by 30 mm. in size; shows close attachment of lacrimal gland at one side and loose attachment of muscular tissue on the opposite side. The new-growth proper is imperfectly surrounded by a connective-tissue capsule which sends into the tumor trabeculæ partially lobulating the cell masses into groups. The connective-tissue capsule is between the lacrimal gland and tumor mass, and is shot through with the tumor cells which have invaded the gland adjacent to the tumor. The cells composing the tumor are short spindle-cells; it is therefore a spindle-celled sarcoma. The adjacent muscular tissue shows hyaline degeneration, separation of the fibers with new-cell proliferation (a chronic myositis), with one or two areas sug-

gestive of sarcoma invasion. The sections of the various extraocular muscles show chronic myositis, but, with the exception of the internal rectus, no sarcomatous involvement. In the external rectus undoubted sarcoma-cells are evident between the muscle-fibers.

CASE 2.—*Sarcoma of the Orbit Simulating Pulsating Exophthalmos.*—A man, born in Russia, peddler, came to the University Hospital October 31, 1908.

Family History.—His personal and family history are unimportant in so far as the conditions presently to be described are concerned. Two years prior to his entrance into the hospital prominence of the right eyeball was noticed following an attack of facial neuralgia, and these phenomena were connected with an accident which occurred upon a boat, resulting in a contusion of the head. It was the patient's belief that there had been no increase in the exophthalmos during the past eight months.

Ocular Examination.—Vision of the right eye with the correction of 1.75 of H. was $\frac{6}{30}$. The pupil reactions were normal, the margins of the disc were slightly hazy, but the disc itself was not swollen. The veins were fuller than normal and slightly uneven; there were no arterial changes and no hemorrhages. The eye was proptosed forward and downward. All rotations were good, except that outward and upward they were slightly limited. Hertel's instrument recorded a prominence of 28 mm., of the left eye 15 mm. Palpation of the orbit revealed a soft, seemingly vascular mass in the upper and inner angle of the orbit. There was no objective or subjective bruit, but decided pulsation, the pulsation being synchronous with the pulse-beat. Over the right temple the vessels were enlarged and tortuous. There was no venous engorgement at the inner angle, but on deep pressure the soft mass previously referred to could be felt to pulsate (Figs. 4 and 5). Pressure upon the right carotid checked this pulsation.

The left eye was normal in all respects, vision after the correction of 1.75 D. of hypermetropia being $\frac{6}{6}$.

Operation was advised, but the patient declined, and was not again seen until January 22, 1910, when, because of increase in the exophthalmos and the development of vertex

headache, which had lasted for two days, he returned willing to submit to operation.

Protrusion of the eyeball was now 31 mm., and pulsation, much accentuated by gentle traction on the upper eyelid, especially if this lid was partially everted, was evident. The mass previously described in the inner angle of the orbit, soft and somewhat fluctuating and decidedly pulsating when pressure was made upon it, and particularly if the globe was pushed backward, was conspicuous. Steady pressure reduced the prominence of the globe, but, as before, there was neither subjective nor objective bruit. In addition to the proptosis, the eyeball was displaced downward 5 mm. and outward 2 mm. It could, however, be rotated in all directions, with some limitation of the inward and upward and inward movement. Vision was reduced to $\frac{6}{45}$, but there were no changes in the eyeground other than those which have been described. There was some injection of the ocular conjunctiva, some enlargement of the episcleral vessels, and still greater enlargement of the veins of the temporal region. Two days later slight haziness of the cornea was evident, but ophthalmoscopic examination was quite possible, and it was definitely ascertained that neither neuritis nor papilledema was present.

The patient was admitted to the ophthalmic wards of the University Hospital, and at my request Dr. Charles H. Frazier tied the common carotid on the right side. This was immediately followed by cessation of all pulsation and temporarily by diminution in the proptosis, although the eyeball never resumed its natural position. Two weeks later, owing to the improvement in the condition of the cornea, the vision was $\frac{6}{22}$, and Hertel's exophthalmomometer measured 27 mm.

Against advice, the patient left the hospital, promising to return for frequent inspection. He did not reappear until two months after this date, giving as his excuse that he had been ill with acute rheumatism, and the right hand and wrist showed the effects of this infection, being still swollen, tender, and covered with scaly epithelium. Hertel's instrument registered 26 mm.; there was an erosion of the outer two-thirds of the cornea, capped by a linear, saturated, corneal ulcer; the bulbar conjunctiva was in-

Fig. 8 —Case 2. Result after removal of sarcom
of orbit.

Fig. 7 —Photograph of sarcoma of orbit, Case 2. The roughened end shows the position of attachments to the orbital periosteum.

tensely injected, and the posterior conjunct
much overfilled. Pulsation was not readily
careful palpation at the upper and inner cor
indicated the transmission of a faint pulsatio

The patient was urged to permit explorati
hesitated, but finally gave his consent two
During these two months he came from time
dispensary for the treatment of his cornea
improved somewhat under pressure banda
usual local applications. Vision was reduce
fingers, and the eyeground could not be studie
was insensitive.

Operation.—On the 5th of June, 1910, I exp
part of the orbit by an incision which extend
brow from the inner to the outer angle, and
immediately an encapsulated growth situate
Passing over this, very much as a strap woul
was the tendon of the superior oblique muscle
make a clean removal it was necessary to seve
when, with a blunt dissector, the growth was
was found to be 5 cm. in length and 3 cm. in br
The eyeball immediately fell in place, all
stopped, the wound, 6 cm. in length, was cl
terrupted sutures; no drainage. Healing wa

For about five weeks there was moderate
however, at the end of that period entirely
The cornea rapidly cleared, the ulcer healed
present time, more than a year after the operati
of this eye is $\frac{6}{12}$; of the other eye, $\frac{6}{5}$. Hertel's in
registers 15 mm. in each eye. When the left
right eye stands upward, so that about 3 mm.
is exposed. When the right eye fixes, there is
ing downward movement of the left eye and a
movement. There is some limitation in the ou
ment of the eyeball and a slight limitation of t
movement. Diplopia, at first annoying, has

appeared, and even these limitations of movement are much less marked than they were originally (Fig. 8).

Pathologic Examination.—The growth, 5 cm. in length and 3 cm. in breadth, is composed of large spindle-shaped cells arranged in fasciculi and in whorls, as well as of a number of large endothelial cells and many smaller cells of lymphoid type. The capsule is composed of dense connective tissue, and the blood-vessels of the growth are singularly normal in appearance, suggesting vessels of old formation. The growth, therefore, may be classified as a large spindle-celled sarcoma (Fig. 9).

CASE 3.—*Cyst of the Orbit, Believed to be, on Clinical Examination, a Sarcoma.*—A girl, aged twelve, consulted me on the 30th of September, 1909.

History.—The patient is the only child of healthy parents, and has had no severe illness in her life. In earlier years she suffered from measles and chicken-pox, and four years prior to the time that she came under my care she fell, striking the center of her forehead. This injury was followed by the development of a small area of thickening beneath the arch of the orbit, which was supposed to depend upon a periosteal bruise. Physical examination at this time was practically negative. Cardiovascular and renal systems gave no evidence of disease, the blood-pressure was 100, hemoglobin 95%, R. B. C. 4,000,000, W. B. C. 4000. No evidence of tuberculosis or of lues.

In May, 1907, and therefore about a year after the injury to which reference has been made, the patient's mother noticed a slight proptosis of the left eye, and the child complained of diplopia, which was particularly noticeable in school. On this account she was taken to an oculist, who did not agree with the mother's observation that there was any proptosis of the eye, but who attributed the discomfort to the presence of hypermetropia, 2 D. in the right and 3.25 D. in the left eye. Glasses were prescribed, and the mother's fears were quieted. Somewhat later, when the proptosis was again prominent, the patient returned to this oculist, who, seeking consultation, had the examinations repeated,

and the mother was told that a tumor was
orbit—probably a sarcoma. Drops were pre
ably a solution of iodid of potassium. Prop
have increased rapidly, so that by August of
eye, according to her mother's statement, prot
that the lids did not cover it in sleep, and
bloodshot, but never pained. At about thi
tachycardia developed, the pulse beating fro
times per minute. Under the influence of
ment, instituted by the family physician, thi
gradually disappeared and the pulse becan
normal. There was also marked diminution i
sis, and after a period of time, during wh
were not used and the child did not go to scho
quote her mother's expression, "was so muc
many friends would have to take a second look
one of the eyes had been troubled." In additio
was needed to quiet the cardiac action, iodid
was continued.

In September, 1909, the vision began to fa
I first saw the child in consultation with Dr. F
land, in July, 1909, there were decided propto
changes which will presently be described.

Ocular Examination, September 30, 1909.—
right eye, after the correction of 2 D. of hype
full amplitude of accommodation; entirely no

Left eye about $\frac{6}{60}$. No ordinary type could b
but the field of vision was unlimited and there
tral scotoma. The ophthalmoscope revealed a
the apex of which was 5 D., therefore approxi
above the level of the eyeground. Not onl
marked papilledema, but also marked edema o
which in some portions of the retina was high
swelling of the disc itself—so much so that in
region and to the outer side of the eyeground th
the edematous retina could be studied with +
downward and inward rotation of the eye w
mately normal, the outward rotation limited,

imperfection of the vision of the left eye. The eyeball was proptosed, Hertel's instrument registering 25 mm., and was also displaced downward, so that it was 1.5 cm. below the level of the opposite eye. The child's condition was studied, not only by Dr. Holt and by myself, but also by Dr. Libby and by Dr. Edward Jackson, and later, at my request, by Dr. Edward Martin, professor of surgery in the University of Pennsylvania.

The child was admitted to the University Hospital on the first of October, 1909, for further study, and a careful investigation of the sinuses was made by Dr. Grayson, who reported them healthy in all respects. General examination failed to reveal the presence of any disease. *X*-ray examination by Dr. Pancoast indicated that a growth occupied the upper and outer portion of the orbit, that the orbital walls were very much bulged, but that there was no positive evidence that the sphenoid sinus itself was involved.

All of us were struck with the fact that there had been periods of time when the exophthalmos was neither stationary nor progressively increasing. In other words, the history gave evidence of periods of time during which the proptosis lessened, and if the mother's statement could be credited, for some weeks it practically subsided.

As palpation revealed so distinctly a large growth which did not give the impression of a cystic nature, as the lacrimal gland was tumefied and evidently involved in the morbid process, which seemed to occupy not only the area within but also the area without the muscle cone, it was concluded that an exploratory operation through an incision beneath the arch of the orbit, or by Kronlein's procedure, was not advisable, and that the contents of the orbit should be eviscerated.

Operation.—On the 7th of October, 1909, Dr. Edward Martin kindly assisting, I removed the eyeball with the intention of following this immediately by an evisceration of the contents of the orbit. Before proceeding with this operation I made a digital exploration of the socket, and detected beneath the conjunctival covering a large mass which occupied the upper and outer portion of the orbit,

much in the position that the *x*-ray has inc
slightly fluctuating to the touch on its surfa
palpation appeared to be solid. The overl
therefore dissected backward, exposing almo
a large, bluish-gray mass which unquestiona
While this was being enucleated it unfortur
or, more accurately, I had to rupture it in or
from the surrounding tissues. This procedu
fully concluded, and as far as could be ascert
material was entirely removed in three or
pieces. The solid material which had been
finger was then enucleated, and proved to be
floor and outer side of the orbit, having a sc
shoe-shaped character, and looking exactly
liver. Everything appeared to be cleanly
therefore the evisceration was not performed
in the orbit was closed with sutures, and as
the muscle secured at the edges of the mar
cision, except in so far as the external rectus
which was entirely involved in the mass.
was absolutely uninterrupted, but to my d
ptosis was complete, although I had not conse
the levator during my manipulations. Th
sented an excellent appearance, and except
an artificial eye could have been worn.

The patient returned home, and Dr. Holt
her, and on the 15th of November, or five w
operation, wrote to me that under the influ
phoresis, using petrogen iodin 5%, and forcing
negative pole, the levator resumed its functi
the patient could now open her eye, when the
was in place, as wide as the other. She has co
perfectly well until the present time, wearing
eye with comfort.

Pathologic Examination.—Sections from the

tions of the tissue which was removed briefly show a picture of chronic inflammatory tissue in the solid base upon which the cyst was situated, glandular proliferation, and a cyst wall. More detailed study of seven sections from different portions reveals, first, muscle tissue in its sheath, interposed adipose tissue, and cyst wall, with much engorged blood-vessels ringed about with inflammatory round-cells, and a similar infiltration between the muscle-fibers. In the adipose tissue the perivascular infiltration is more pronounced, and there is some endothelial proliferation in the arteries.

The *cyst wall* is composed of an incomplete, irregular epithelium resting upon a dense connective-tissue base of variable thickness. Beneath the latter there is much free blood, and old and newly formed blood-vessels in a loose connective-tissue matrix. The epithelium varies from a much flattened single cell to a cuboidal shaped cell, and three or four layers in thickness, the innermost approaching in appearance columnar cells.

One portion of the mass consists of a fibrous tissue bearing an epithelial covering with cyst-wall characteristics, similar to those just described, the epithelium being more irregularly arranged, as in a two-layered membrane. The deeper lying connective-tissue mass, a part of which has a resemblance to old organized clot, is infiltrated widely with red blood-corpuscles, and shows relatively large round cells massing around the arteries, with very decided infiltration of the latter, even to obliteration of the lumen.

Other portions of the growth give the characteristics of lacrimal gland tissue and contain massive perivascular and periductal round-celled infiltration. In some portions of the lacrimal gland there are marked indications of gland proliferation, and the foci of these proliferations are mantled by masses of inflammatory cells. An imperfect and irregular epithelium covers a part of this specimen.

Exactly how this specimen should be interpreted it is

difficult to say, partly because of the traun
it was subjected in its enucleation and partl
detached pieces from which it had to be stud
terms, it would seem that the most probabl
that it represents a cyst which had developec
gland, although this does not satisfactorily e
mass of tissue upon which the cyst rested,
sents the appearances of inflammatory tiss
ceivable that the injury to the orbit, describe
history, may have been responsible for this
tissue, which, in turn, was responsible for
a solid growth was present, almost certainl
character.

CASE 4.—*Right Exophthalmos Simulating
Posterior Portion of the Orbit, but Due to
Middle Fossa of the Skull.*—L. W., a marriec
sixty-three, first came under my observatior
delphia General Hospital in December, 1908,
was demonstrated before the Section on Opl
the College of Physicians of Philadelphia Jan
as a case of unilateral exophthalmos with
optic nerve atrophy, and the various possibili
were discussed. Pulsating exophthalmos, a
disease, unilateral intermittent exophthalmc
growth were excluded, and the opinion was
the exophthalmos might be due to a tumor o

The earlier clinical history of this patient, f
indebted to Dr. Wendell Reber, follows:

History.—The patient first came under th
Reber in the out-patient department of the
pital May 18, 1905. The history obtained at
that five years previously she had struck her
heavily against a door. Except for some sl
swelling, which subsided in a few days, there

* Ophthalmic Record, 1909, xviii, p. 197. This case has
by Dr. T. H. Weisenburg in a paper entitled "Exophthalmos

immediate symptoms, and apparently there was no interference with vision. Eight months after this accident the right eye began to protrude, and this protrusion gradually increased. In her earlier years the patient had measles and scarlatina, and described an illness that probably was typhoid fever, which occurred during her twentieth year. Although married for thirty years, she had never had any children. There was, however, no history of miscarriages,

Fig. 10.—Visual field for form and red of Case 4. Right eye. Measured by Dr. Reber May 24, 1905.

nor was there any evidence of syphilitic infection. At that time her general health was good, and she was a woman of plethoric habit.

Ocular Examination.—Dr. Reber's examination of the right eye at that time revealed a proptosis of 8 mm. as compared with the fellow-eye. The ocular movements were complete and smooth in all directions. They were up 35, down 45, to the temporal side 45, to the nasal side 40. No diplopia could be elicited in any portion of the binocular

visual field. Both pupils were 4 mm. in di
acted normally to light and to converger
vision of the right eye was $\frac{6}{6}$ partly; correct
left eye was $\frac{6}{6}$ full, and the left eye was norma
The ophthalmoscopic examination of the rig
two small spicules in the lens, but a perfect
ground, except that the nerve seemed to be a t
on the temporal side than was exactly natura

Fig. 11.—Visual field, Case 4. Concentric contraction for fo
ful central scotoma for red. Measured by Dr. Reber J

pallid apparently than the optic disc of the
visual field is depicted in Fig. 10.

Very careful examination was made of the
uses by the late Dr. Barton Potts; skiagraphs
and the ordinary intranasal and sinus examin
were employed. The results were entirely
months later a very careful examination by D
to reveal conditions other than those which
scribed.

The next examination was made a year and a half later, or in January, 1908, when the patient stated that her memory had been failing for six months, and that between September and October of the fall of 1907 she had on four occasions become unconscious, these unconscious spells having been accompanied with something like a convulsive seizure. The visual acuteness of the right eye was $\frac{5}{12}$, and of the left, $\frac{5}{5}$. Both pupils 4 mm. in diameter, and the right optic disc was pallid and much filled in. There was some slight restriction in the ocular movements as compared with the previous record, these rotations being about 5 degrees less than they had been. The proptosis was 12 mm., but diplopia could not be elicited. The visual field is appended (Fig. 11).

Dr. Reber examined the patient again in March, 1908. The vision of the right eye was now $\frac{1}{200}$, and the nerve decidedly atrophic and filled in. Otherwise there were practically no changes. The left eye continued to be entirely normal.

Soon after this date the patient came to the Philadelphia General Hospital, where I examined her, finding practically the conditions which Dr. Reber has described, except that the optic nerve atrophy was complete, the disc being of a greenish-white hue. The exophthalmos had not increased over and above the measures named, and the ocular rotations were practically normal in all directions. There was no sign of inflammatory disease of the orbit nor loss of sensation in the cornea. The eyeball, which was proptosed straight forward, could not be entirely reduced by pressure, the sensation being that which would be produced by a resisting tissue at the back of the eyeball (Figs. 12 and 13). The exophthalmos was not intermittent. *X*-ray examination was again negative, as was that of the nasal sinuses. The neurologic examination at that time indicated that she had, on a number of occasions, had a general epileptiform convulsion, followed by temporary left hemiplegia. The renal examinations gave evidence of the presence of chronic interstitial nephritis.

Autopsy.—The patient died in the spring of the same year, and the autopsy, in so far as the skull is concerned, demon-

Fig. 12.—Case 4. Exophthalmos from tumor middle fossa of skull which simulated tumor orbit. Front view.



Fig. 13.—Ca of middle fossa of orbit. Side v

Fig. 14.—Case 4. Tumor in middle fossa of skull which produced e of posterior orbital tissues. Photograph by Dr. C

strated a tumor in the middle cranial fossa some pressure upon the orbital bone, the o the temporal and posterior part of the orbit frontal, and the extreme anterior part of the The optic chiasm was somewhat pressed up slightly to the opposite side, and some pr foot of the cerebral peduncle was evident.

I made a rather careful dissection of th showed that the tumor sprang in the mid skull from the periosteum covering the grea sphenoid. It was bounded above and to th the sphenoid fissure, and terminated jus beyond which lie the foramen rotundum a ovale; the bone beneath the periosteum was body of the sphenoid and the sphenoid si the ethmoid sinuses, were free from disease (

There was not the slightest evidence of an cavity of the orbit, the tissue of which was s as it might have been from a long-standin cavernous sinus was unaffected, that is to sa literated, nor was there any macroscopic cranial nerves which pass through the sp Dr. Weisenburg, however, states in his a third, fourth, and sixth nerves were found gives no details of the character of the lesio seen sections of these nerves. The greates base of the tumor was 4½ cm., it was som shaped, and in its greatest height was 2½ c of the growth its appearance was not unlike

Microscopic Examination of the Growth.— that the growth is an endothelioma (sarcom moma formation; cells of endothelial type whorls, at the center of which, in a few pla ances which suggest true sand bodies. In ot resemble the pearly bodies of epithelioma



vessels are abundant, and consist of simple channels formed by endothelial cells (Fig. 15).

CASE 5.—*Left Exophthalmos, Downward Displacement of the Eyeball, Limited Upward and Outward Movement, Clinical Evidences of a Growth in the Sinuses Probably Involving the Orbit; Complete Subsidence of Symptoms Under the Influence of Medicinal Measures.*—A man, aged fifty-two, married, came for examination on the 8th of April, 1910. His family and personal history are unimportant and throw no special

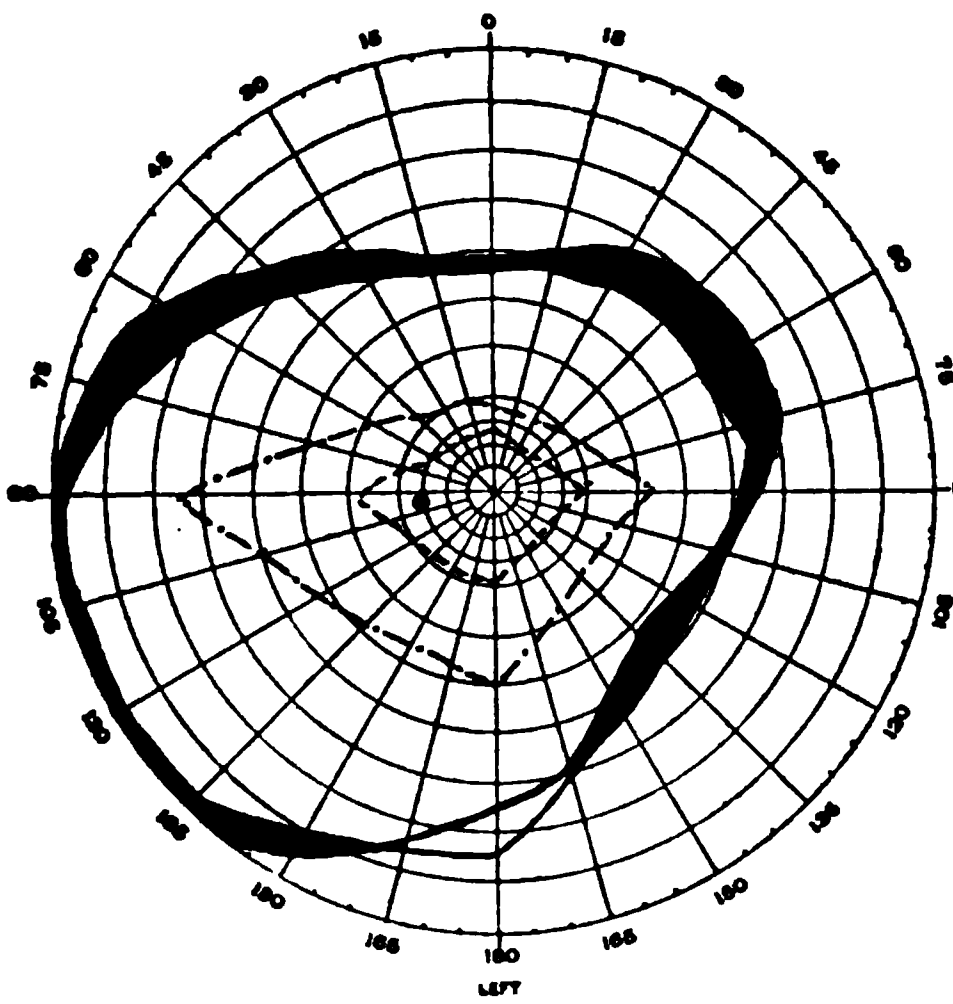

Fig. 16.

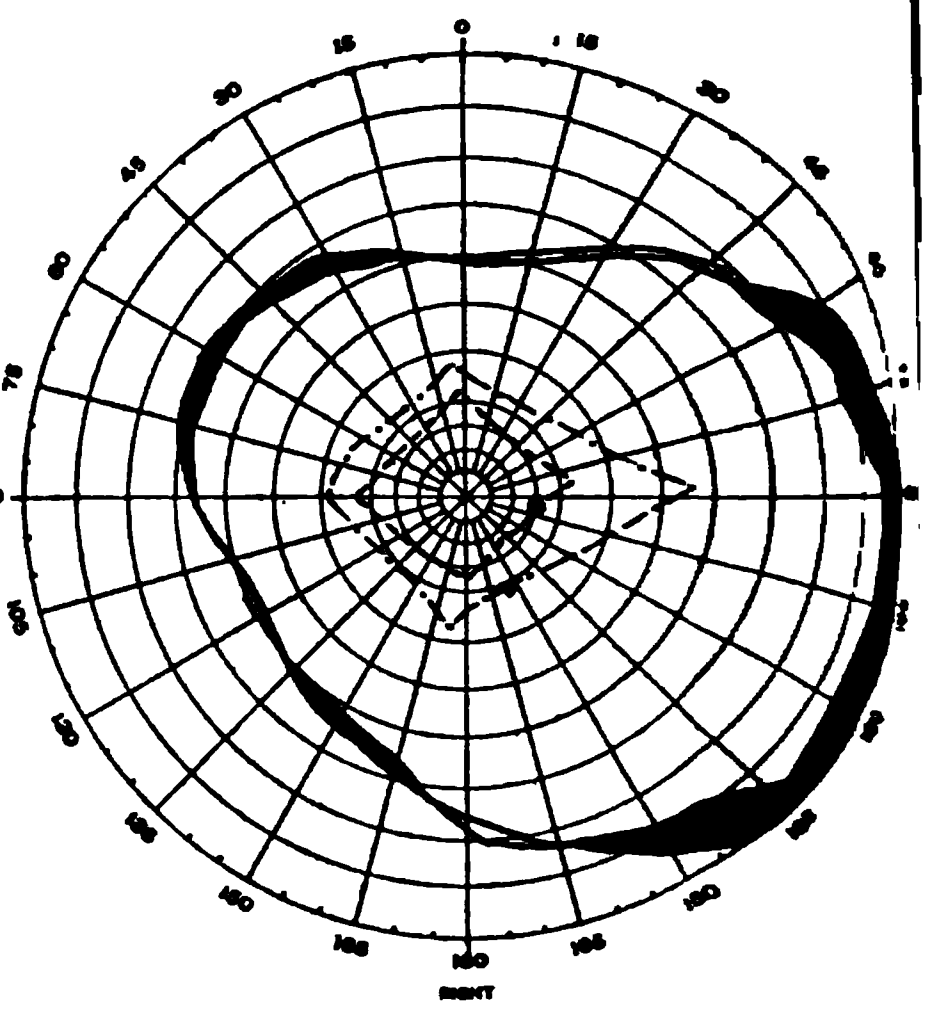

Fig. 17.

Figs. 16, 17.—Case 5. Visual fields for form, red, and green. Very slight contraction.

light on the subsequent symptoms. At times he had suffered from so-called bilious attacks, but was never subject to headache, and there was no family history of morbid growth nor clinical evidences of lues or tuberculosis. A Wassermann test, however, was not made. Occasionally he had been subject to attacks of vertigo, but only when he stooped over, and three months prior to his first examination he had for a period of time dull rheumatic pains in his shoulders and left hip, but at no time an attack of acute rheumatism.

Fig. 15.—Spindle-celled sarcoma of the middle fossa

In February of 1910 he consulted his ph
his left upper lid was red and swollen and int
vision. When examined, a month after t
first became manifest, the symptoms were sw
and partial ptosis of the left lid, but no pain
ness on palpation. Also, there was slight
conjunctival tissue, and the episcleral vessels
There were left hypoexophoria and left pa
but no loss of vision and no history of injury

Later Ocular Examinations, April 8, 191
rected vision $\frac{6}{6}$, and with corresponding p
0.50 at 33 cm. Ophthalmoscopic examinat
negative.

Corrected vision of the left eye, $\frac{6}{7.5}$; pupil
time normal; no demonstrable paresis of a
The nearly round disc exhibited a physiologic
border was distinctly hazy, and the disc gray
layers than that upon the opposite side. Th
superficial redness of the conjunctiva, and t
displaced downward 2 mm. below the level
eye. There was also failure of the lid compl
the downward movement of the eyeball.
limitation inward; the upward movement o
slightly limited, and the eye could not be ro
entirely to the canthus. As measured on the
rotations were as follows: Nasal 45, upward
40, downward 60. The visual fields are ex
accompanying diagrams (Figs. 16 and 17). Ca
tion of the binocular visual field with a small
a slight crossed vertical diplopia in all its porti
separation of the images increasing up and to
greatest vertical separation being down and to
the image of the left eye always below. The
limitation in the outward movement, which
by 5 mm. the outer canthus. There was also
tation in the upward rotation.

The following examinations made by Dr. L
give the results of the tests of blood and urin

Blood Examination:

Pressure: Sys. 105 mm., dias. 90 mm.
Hemoglobin, 95%.

R. B. C., 6,840,000.
Leukocytes, 6880.
Polymorphonuclear, 75%.
Large lymphocytes, 8%.
Small lymphocytes, 12%.
Eosinophiles, 2%.
Transitional, 1%.

Urine Examination:

Medium amber; acid; 1022; albumin negative; sugar negative; phosphates negative; urates positive; indican negative; pus negative; bile-pigment, trace.

Microscopy:

Epithelial cells; a few calcium oxalate crystals; a few small hyaline casts; numerous mucous cylindroids; a few R. B. C.; débris.

The patient was referred to Dr. Francis R. Packard for sinus examination, who reported as follows: "The patient has no intranasal condition indicative of suppuration in any of his sinuses; a spur has evidently been removed from the nasal septum, but contraction of the nasal tissues failed to reveal the presence of polypi or dead bone. On transillumination his left frontal sinus transmitted absolutely no light. His right frontal sinus illuminated very clearly."

The *x*-ray examination made by Dr. Pancoast, and the plates studied by Dr. Packard and myself, indicated the presence of a growth which seemed to extend backward and downward, and which also distorted the orbital roof. The presence of a clear, large right frontal sinus, the complete blocking of the left frontal sinus, and the *x*-ray findings certainly gave every evidence of an extensive neoplasm. Hertel's instrument: right 18, left 20.

Treatment.—In spite of the absence of clinical history of syphilis, I deemed it worth while to try the effects of mercurial treatment, which was carried on from this time until the fall of the same year, and consisted in protiodid of mercury for periods of time, followed by iodid of potassium. Iodid of potassium was never given in doses greater than 30 grains three times a day; of the protiodid of mercury,

a quarter of a grain was administered thr
except for a period between the 27th of
16th of May, when the iodid of potassium t
referred to was tried, but soon stopped on ac
distress.

After two months of this treatment the vi
was normal—that is, $\frac{6}{6}$; there was still a slig
the prominence of the two eyes, the exoph
left eye being about a millimeter and a half,
tions in movement previously described wer

Four months later the record of Hertel's i
exactly the same in each eye, namely, 18 mm
were now precisely upon the same level. T
lutely no diplopia in any portion of the fiel
no limitation in movement. There was sti
December, 1910, or six months after treat
very slight difference in the level of the tw
eye being nearly a millimeter lower than the

Reëxamination by Dr. Packard and reëxan
x-ray failed to reveal any of the conditions
scribed. In Dr. Packard's letter occur these
do not think I have ever seen quite so remar
in a patient's appearance and condition. H
gave a perfectly clear reflection on transillun
is no pus coming from or in any of the sinuse
cation of the former state of affairs." The r
eye at this time were outward 45, up and ou
ward 45, downward 60, downward and outwar
apparently entirely normal.

CASE 6.—*Left Exophthalmos; Complete F*
with Slight Divergence and Downward Displ
plete Loss of Vision of Left Eye; Recovery afte
tion.—A woman, aged nineteen, unmarried, c
nation at the request of her physician on th
uary, 1911. The patient's father and mothe

apparently healthy, but the father gives a distinct history of luetic infection in earlier life. The patient, in general terms, has been in good health. In childhood she had pneumonia, and one year ago an attack of appendicitis, but no operation was performed.

The general physical examination was practically negative. Urine: specific gravity 1024, acid reaction, no albumin, no sugar, a trace of indican, abundant triple phosphates, no casts. The blood examination was as follows:

Hemoglobin: Talquist, 80%; Gower, 85%.
Red blood-corpuscles, 4,400,000.
White blood-corpuscles, 12,000.
Differential count (500 cells):
Small lymphocytes, 28%.
Large lymphocytes, 6%.
Polymorphonuclears, 65%.
Basophiles, 0.5%.
Eosinophiles, 0.2%.
Coagulation time, medium rapid.
Wassermann reaction was negative.

One year ago the patient is said to have had partial ptosis of the left eyelid, which lasted about two months. About the first of January, 1911, she consulted her physician, who reports that he found at that time marked exophthalmos, the eye protruding from the socket and having a fixed, glassy stare. Palpation seemed to indicate increased intraocular tension. Vision is not recorded, but the statement is made that there was very little vision in the affected eye. Both pupils at that time were moderately dilated and reacted to light. She was examined by an oculist, whose detailed report is not available, but who wrote to her physician that "he was compelled to make a provisional diagnosis of sarcoma of the orbit." *X*-ray examination was negative. The plates, according to the report which was sent to me, did not show any destruction of bone, new bone formation, or pus in the sinuses of the skull.

The following additional details were given by the patient at the examination made in my office: Ten weeks prior to her visit, not following illness, trauma, or inflammation, there was a sudden onset of blurred vision of the left eye, but no pain. This seems gradually to have disappeared, and four

weeks later, after a sharp, toothache-like p
the right eye was suddenly practically extin
panied by exophthalmos, and all motions of
lost, so that the condition was that whicl
viously described in the report furnished b
The knee-jerks were normal; the station
no thyroid enlargement, but there was a
lymphatic cervical swelling in her earlier life

Examination of the Eyes.—O. D., vision n
in diameter and entirely irresponsive to dir
lus; the indirect light stimulus was prompt
nearly round, with a slight crescent on the
while the nasal edges were somewhat over
moderately veiled. There was a small phys
macula was redder than is usual, and the rel
The veins were also larger than those of th

When the left or seeing eye fixed, the right
position slightly downward and outward a
lower than the left eye. The rotations as n
perimeter were: Outward 30, upward 30, in
ward 60. The greatest limitation in moveme
up, where it was not more than 15 degrees,
tion upward and inward was 55 degrees;
limitation in the downward and outward mc
was 15 degrees. There were no pulsation an

Vision of the left eye $\frac{6}{5}$, 0.50 p.p. 12.5 cm
mm. in diameter, reacted promptly to direct
and to efforts at convergence and accommo
direct light stimulus was absent. The form
mal; there was slight concentric contractic
fields; there was no scotoma. There were n
fundus demonstrable with the ophthalmoscop
strument recorded right 22 mm., left 16 mm

Dr. Howard F. Hansell was called in consu
that the ophthalmodiaphanoscope might l
instrument showed that the orbital cavities
new formation. The accessory cavities of tl
no obstruction to the passage of light. I
there was nothing to indicate that a morb
present either in the orbit or in the adjacen
skull.

Treatment.—In spite of the negative Wassermann test, I suggested the thorough trial of mercurials. Prior to her visit to my office the patient had taken for ten days 5 grains of iodid of potassium and $\frac{1}{48}$ of bichlorid of mercury four times a day. As the result of this treatment her physician reported in the letter which he sent with her that the protrusion of the eyeball which he had first noticed had diminished, and that there was some improvement in the rotations of the eyeball, which at her first visit had been entirely lacking, and which at the visit she made to the oculist first consulted had been present in moderate degree only downward, the other motions having been lost.

The treatment now consisted in a daily inunction of 1 dram of ointment of mercury, preceded by a vapor bath, while the iodid of potassium was continued internally.

At the expiration of a week the patient showed remarkable improvement, and her physician reported the disappearance of the peculiar stare which the exophthalmos had given her, and that the eyeball was now freely movable. After two weeks of the mercurial treatment the patient was able to distinguish large objects, although they were still hazy, and it was noted by her physician that such objects were better seen 30 degrees to the left of the center of the eyeball than elsewhere. Pupil reaction had also begun to return. Mercury was continued until its full physiologic effect was produced, and at my last examination, namely, on the 22d of March, 1911, the vision of the right eye was $\frac{6}{9}$, the near point 13.5 cm., there was no diplopia in any portion of the field of fixation, and the Maddox rod showed exophoria of 4 degrees and a left hyperphoria of 1½ degrees. The optic disc was pale, especially on the temporal side, and there was a slight venous pulse. Pupil reactions were prompt to all tests—the right pupil 3.5 mm., the left pupil 3 mm. The patient's general condition was perfectly good, and has continued so until the present time.

Remarks.—In this communication we deal with:

1. A spindle-celled sarcoma of the orbit simulating in its earliest stages an exophthalmic goiter, which was without difficulty removed by opening the orbit through an incision beneath the orbital arch, followed, because the ocular muscles and periosteum were evidently involved, by an evisceration of the contents of the orbit; no return of the growth at the expiration of two years, the duration of this growth from the time of the first symptoms of exophthalmos to its extirpation being eight years.

2. A sarcoma of the orbit exactly simulating pulsating exophthalmos, save only that subjective and objective bruits were wanting. Pulsation was temporarily checked by ligation of the common carotid, followed by a return of pulsation, and, owing to the patient's neglect of advice, by exposure-keratitis—so much so that the vision was reduced to hand movements. Four months later an exploration of the orbit was made through an incision beneath the orbital arch, and a spindle-celled encapsulated sarcoma was removed which was 5 cm. in length and 3 cm. in breadth. Complete recovery with restoration of the functions of the eyeball took place, with a vision of $\frac{6}{12}$. No return more than a year after operation.

3. A cyst of the orbit that began apparently two years and a half before it was submitted to operation, that in the character of its growth gave the impression of a malignant neoplasm, that was accompanied by choked disc and blindness, and that could have been removed, in all probability, without sacrifice of the eyeball, but because clinical examination so strongly indicated malignancy, the eyeball was sacrificed prior to what was intended to be an evisceration of the orbit, not performed, however, when the partly cystic and partly solid growth was discovered and removed without material difficulty. It consisted of a mass of granulating fibrous tissue with portions of the lacrimal gland in a state

of active proliferation, together with a large epithelium-lined cyst. Perfect recovery with excellent prosthesis.

4. A right exophthalmos which had existed for nearly ten years, and which was accompanied with optic nerve atrophy without neuritis. The exophthalmos was irreducible and gave the impression of resting upon a solid growth, although all examinations failed to prove the presence of a neoplasm either in the orbit or in the accessory sinuses. Death from Bright's disease, the autopsy revealing a large psammoma-sarcoma in the middle fossa of the skull, the orbit and sinuses being free from disease in the sense of neoplasm, but the orbital tissue solid from a pronounced edema.

5. A left exophthalmos, palsy of the superior rectus muscle, and ophthalmoscopic examination negative, but *x*-ray examination indicating extensive involvement of the frontal and probably sphenoid sinuses, all symptoms rapidly disappearing after free mercurialization, so much so that sinus as well as *x*-ray examinations at the expiration of treatment, namely, six months, were negative.

6. A left exophthalmos and primary fixity of the globe, together with downward displacement and divergence, with complete loss of light perception, coming on suddenly, preceded, however, two years before by one attack of ptosis of the opposite eyelid, and a short time before by a brief period of blurred vision of the opposite eye. Gradual but only partial restoration of the movements of the globe, with continued blindness. Negative examination with the ophthalmodiaphanoscope; complete restoration of all functions of the eyeball, vision, accommodation, and movements, after free mercurialization. Negative Wassermann test, but luetic family history.

Certain interesting facts in these cases may further be pointed out, as follows:

1. In four of the cases—viz., the spindle-celled sarcoma of the orbit simulating unilateral exophthalmic goiter, the

spindle-celled sarcoma of the orbit simula
exophthalmos, the cyst of the orbit simulati
and the exophthalmos with optic nerve atro
growth in the orbit or sinuses, but due to a
middle fossa of the skull—there is a distinct hi
to the orbit or surrounding tissues.

2. Two sarcomata of the orbit were re
through an incision beneath the orbital arch wi
of the eyeball, in the one case with perfect res
functions of the eye, and in the other follow
ceration of the orbital contents for surgical
have been already detailed. The cyst of th
doubtless have been removed in the same way
onstrated by the ease with which it was en
the eyeball was removed, but because an evisc
contents of the orbit had been contemplated,
the ocular globe was sacrificed owing to the
sarcoma was present when really the process
non-malignant character.

I dwell upon this portion of the paper for
cause it has been my experience in this serie
well as in others, that a growth in the orbit in m
can be reached just as well through an incisio
orbital arch as by Krönlein's method, and in m
a few large orbital growths excepted, is a muc
factory procedure than the resection of the t
of the orbit.

3. The important fact that tumors of the
contents are occasionally associated with exo
its turn accompanied by a solid edema of the
tion of the orbital contents, so much so that or
inations suggest a tumor of the orbit. In the
of the various causes of exophthalmos this caus
must not be forgotten.

4. The astonishing rapidity with which a mo

of what nature is not clear, but probably gummatous, disappeared after mercurialization, when every clinical evidence was present that a growth of magnitude occupied the frontal sinus, the upper and inner portion of the orbit, and probably the sphenoid, restoration of all functions being secured in less than six months by means of the treatment named.

5. The equally astonishing rapidity with which a morbid process, almost unquestionably syphilitic, disappeared in the case of the young woman with complete blindness and fixity of the eyeball. Where the lesion was is a matter of speculation, and in my speculations on this point I have had the advantage of Dr. Spiller's advice, who, while he did not see the patient, has heard me discuss the clinical history, and he permits me to quote his views. The lesion could hardly have been in the region of the corpora quadrigemina, for if confined to this part of the cranial contents, it would not be possible for it to have paralyzed all of the ocular nerves, including the optic. To be sure, the sixth nerve could be paralyzed from a cutting off of the posterior longitudinal bundle between the nuclei of the third and sixth nerves, but this would have caused paralysis of the sixth on the opposite side of the paralysis of the third, and would *exist* in associated lateral movements. A lesion in the region named could implicate the nucleus of the fourth nerve, as this nucleus is directly posterior to that of the third. Dr. Spiller doubts whether a lesion confined to the corpora quadrigemina could affect vision seriously. In lower types of animals this structure, or what corresponds to it, has much to do with vision, but he points out that we have not sufficient evidence that the corpora quadrigemina are concerned with the visual act in man, and bases his conclusions chiefly on a case that he reported some years ago, in which all those parts belonging to the visual system which are recognized without dispute were congenitally absent, and yet the cor-

pora quadrigemina were well developed. A
region would have to exist far enough forwar
optic radiations or the external geniculate bo
cause blindness. If such a lesion had occurre
be associated with the symptoms of involv
sensory tract and the superior cerebellar pedu
involvement of the latter a cerebellar ataxia
expected. Evidently the lesion that most
explains the condition is one where the opt
fourth, and sixth nerves are close together, a
only be near their exit from the cranium. It
that syphilis selects especially the regions of
peduncles for its manifestations, and therefor
palsy is so common in cerebral syphilis, but a le
to this region could not explain the symptoms o
It would be possible, and even probable, for a
tend from this region and implicate the adjoinir
the optic foramen and the sphenoid fissure.
tory lesion, which is the common one in syphili
vous system, might easily implicate the optic n
third, fourth, and sixth nerves at this part.
fissures are close together, and the third, four
nerves pass through the sphenoid fissure. No
no anesthesia of the cornea and skin, and yet
to have been, because the ophthalmic division
would, in case the lesion is placed here, be affe
of course, perfectly possible that a limited area
was overlooked, but there is another point to b
consideration, as Dr. Spiller suggests, namel
sensory fibers are often more resistant to pressur
fibers, and that sensation may return in a nerve
while motor palsy persists. The temporary p

of the periosteum of the orbit. In a case periosteum is involved and strips readily, le in a fairly good condition so far as appearan reasonable evidence that the tumor is limit osteum and has not involved the bone itself. it would be just as well not to continue, as I de Schweinitz to say that he did, the operation tion of the denuded bone with the orbits made the report of six or seven cases of orbit meeting of the Pan-American Medical Congr ago. Among these there was a tumor of the all the appearances of a pulsating exophtha malignant. It had come on very suddenl spontaneous hematoma of the orbit and rapidly after the removal of a hypodermic dark semifluid blood. I think that it is imp sider the matter of operation very carefully, at a conclusion as rapidly as possible, and to in the course of the disease, as the chances of much less when the surrounding tissues hav come involved, and the operation itself may extensive.

Dr. George F. Libby, Denver: In rega of those enumerated by Dr. de Schweinitz, the patient was a member of my cousin's fam say that I was in intimate touch with the c spondence, for two years before Dr. de Schw patient. It might be of interest to you to kno good general surgeon diagnosed the conditio at the beginning of this two-year period. It interesting to state that under treatment v potash and general hygienic measures the pati physically for a year and a half, with undoub of the growth; and that the family physician f ful. Dr. de Schweinitz has related the case f that he saw it in consultation with me, the d my first examination of the patient; and I further to add to his complete history of this The diagnosis of sarcoma at the beginning, and ment under iodid of potash, add, I think, son the picture that he has given.

amination was first made there began to be
malar bone. Probably there is an osteos
started in the sphenoid, and now extends ou
the orbit, which is showing extensive ab
patient suffers from neuralgic pain, but is m
fairly comfortable. The progress during t
or so has been rather slow. I shall be glad t
history of this case at a future meeting.

Dr. E. A. Shumway, Philadelphia: In c
the series of cases that Dr. de Schweinitz
and in corroboration of the readiness with w
of the orbit may be reached through the lid,
report the case of a boy, sixteen years of
ophthalmos, which, according to his father,
three weeks before I first saw him. The sinus
as well as the general medical examinations,
The *x*-ray showed the probability of a growt
eye, and in this position a mass could be felt v
An operation was performed, and the growth r
through an incision in the lower lid. We hac
it would prove to be a cyst, on account of
growth, but we found a solid tumor. In consi
excellent result obtained by Dr. de Schweinitz
case, we thought it safe to close the wound, w
rating the orbit, until a microscopic examina
made. The wound healed kindly, a drainag
outer end being removed in a few days. Wi
however, the patient returned with extensiv
and, as the microscopic examination in the r
shown spindle-cell sarcoma, the orbit was at
rated. The periosteum was apparently not
the last report, five weeks after operation, s
been no recurrence. The case therefore illust
that many of these growths can be removed w
tion of the temporal wall of the orbit, and al
great rapidity with which sarcomata grow in you
a fact which, of course, has been well known.

Dr. G. E. de Schweinitz, Philadelphia: Ow
time I have been unable to read the clinical hi
cases reported. Referring to the growth con

Dr. Johnson has inquired, namely, the sarcoma which simulated exophthalmic goiter, I desire to point out that it would have been perfectly possible to have restored the eyeball to its normal position after the enucleation of the tumor, but complete evisceration was practised because of the probable malignant nature of the neoplasm, and, as subsequent examination showed that the sarcoma cells had infiltrated the ocular muscles, it evidently had been a wise surgical procedure.

From the patient to whom Dr. Libby referred there is no doubt that the cystic tumor could have been removed without sacrificing the eyeball. The diagnosis of sarcoma seemed to be so plain, and was apparently confirmed by so many examinations, that at the operation those present believed evisceration was indicated, and the eyeball was removed as the first step of this procedure, when it was found that the growth could have been removed without an exenteration of the orbit. Fortunately, the child is able to wear an artificial eye with comfort and is in good condition. Microscopic examination has shown that the neoplasm was not malignant in structure.

I refer again to the interesting features associated with the exophthalmos produced by an intracranial tumor, although the clinical symptoms were strongly indicative of orbital growth, and urge that cases of this character should be taken into consideration in the examination of various forms of otherwise unexplained proptosis.

SUBSEQUENT HISTORY OF A CASE OF EXOSTOSIS OF THE ORBIT REPORTED TO THE SOCIETY IN 1897.

WILLIAM M. SWEET, M.D.,
Philadelphia

The following case, reported to this Society in 1897, is of interest as showing the results of operation for a large ivory exostosis of the orbit with no recurrence after nine years, and also the value of the Roentgen rays in demonstrating the possible situation of the disease in suppurating sinusitis.

The patient first came to the hospital of the University of Pennsylvania in 1896, and an examination made at that time by Dr. Wm. F. Norris showed a hard lump which was growing from the inner wall of the right orbit. The tumor had existed for six years, but the latter two years it had rapidly increased in size. The growth could be traced with the finger for a considerable distance back into the orbit. There was a constant epiphora, and a probe could be passed through the canaliculus and into the entrance of the sac as far as the tumor, but could not be introduced any further into the lacrimal passage.

The tumor upon removal by Dr. Norris was found to be an ivory exostosis growing from the plate of the ethmoid bone, involving it almost in its entire extent, and invading the lacrimal bone. The mass measured 41 mm. in its long diameter and 25 mm. in transverse diameter.* The patient left the hospital in three weeks, and the parts were dressed by his family physician for six weeks afterward. During the time some necrosed spicules of bone were removed.

*Trans. Amer. Ophthal Soc., 1897.

For several years following the operation the man states that he suffered no serious discomfort, although the epiphora continued and there was an occasional discharge of purulent material at the inner canthus. In October, 1904, he had an attack of marked edema of the right side of the face, the swelling closing both eyelids and extending to the angle of the jaw. This subsided under local measures. The following month there was a second attack of edema of the side of the face, at which time he opened a swelling near the internal canthus from which considerable pus was discharged.

Fig. 1.—Ivory exostosis of the orbit (natural size).

The purulent material continued to appear until the date of my first examination, in March, 1905.

He was given ether, a large probe was passed through the fistulous opening into the nasal cavity, and the lacrimal sac was washed out for several days. The purulent discharge lessened for a time, but in a few days would reappear. Believing that the seat of the trouble was in the ethmoid cells, an incision was made above the internal canthus, and a probe passed in the direction of the anterior ethmoid cells was followed by about three ounces of pus. The region was cureted and washed out, and a drainage-tube inserted, through which the cavity was irrigated daily, and a 20%

solution of argyrol injected. The discharg amount and became mucilaginous in ch direction taken by the drainage-tube was upw ward, presumably leading into the region o ethmoid cells, and it was the opinion that t trouble was at this point, until I had Dr. Wil of the Jefferson Medical College Hospital, make a radiograph of the tube in position, with a piece of lead wire in its lumen. This radiograph (Fig. 2) shows that the tube, after passing backward for about 1½ inches, curved forward and passed into the frontal sinus. This was probably one of the earliest uses of the Roentgen rays in locating the seat of sinus disease.

As there was no chance of recovery without operation on the frontal sinus, I

There is considerable bulging of the outer nasal wall at the agger nasi, evidently due to dilated first and second frontal cells. Externally a rubber drainage-tube leads from above the inner canthus upward and forward, through which the frontal sinus can readily be explored in all directions. The external opening being closed by the nozle of a syringe, no fluid can be forced into the nose through the frontal sinus.

The patient was advised to have the frontal sinus opened externally, so that drainage could be re-established into the nose. He consented, and, at the Philadelphia Polyclinic, Dr. Freeman made an incision directly through the eyebrow from the supraorbital notch to the inner limit of the eyebrow, elevated the periosteum, and drilled an opening $\frac{3}{16}$ of an inch in diameter into the frontal sinus through the anterior wall. Abundant granulations and thick mucopus filled the sinus, but no bony floor was found, this evidently having been removed with the osteoma by Dr. Norris. A counteropening over ½ inch in diameter was made through the floor of the sinus, and a drainage-tube of large diameter passed through the sinus into the nose and out through the nostril. The fistulous tract, which led from the inner canthus far back along the orbito-nasal wall, was then cureted.

One week later the external wound was entirely healed, and the patient returned to his home in the country. Examination three months later showed no discharge whatever from the frontal sinus, and the opening from the nose admitted a probe 4 mm. in diameter. The external fistula had closed and the patient was able to follow his occupation. Up to the present time the patient has remained well.

PHANTOM INTRAOCULAR TUM

ARNOLD KNAPP, M.D.,
New York.

In describing the conditions which may sir roidal sarcoma, Haab, in his book on "Opht third edition, page 82, speaks of the so-ca tumors, which, arising probably from the retin rior part of the eyeball, produce one or more rc nences. They are presumably cysts resulting f generation of the retina, and may disappear wit

Through the courtesy of Dr. A. N. Alling, of I had the opportunity of seeing a case where diagnosis of sarcoma of the ciliary body was enucleation no tumor was found, but cysts ciliaris retinæ were present.

Mrs. C. N. I., aged seventy-three, was seen 1, 1910. She stated that the left eye became re for the last six weeks had protruded. The e straight forward; some of the conjunctival v usually congested. Palpation of the margin c negative; except at the upper and inner ang nodular mass to be felt which pulsated. V = $\frac{2}{7}$ nerve was normal. The fundus revealed dis sclerotic changes in the retinal vessels, a few rhages, and below, in the periphery, a shallow After dilating the pupil, a round brownish easily seen by oblique illumination back of th temporal side. Tension normal. The diagn ocular tumor with an orbital extension seeme Alling enucleated the eyeball; there was no orbit, but an aneurism of the ophthalmic eyeball was opened and again no tumor was fc terior seemed normal to the naked eye. The

placed in formol and sent to me for examination. After hardening in alcohol and celloidin-embedding, antero-posterior sections were cut and stained in hematoxylin-eosin. Microscopic examination showed typical senile changes in the retina, choroid, and ciliary processes. In addition to pronounced cystic degeneration of the retina (so-called Iwanoff's edema), there are distinct changes in the epithelium in the pars ciliaris retinæ. The inner or non-pigmented epithelium shows degenerative and proliferating changes. The cells are distended, some with vacuoles; some contain a bluish, homogeneous mass. Large cysts are formed, which are lined with cells and contain a substance stained faintly blue, with many fine interlacing lines (mucin). In other sections the entire non-pigmented layer is separated from the underlying pigment epithelium by a collection of mucin. The tumor recognized clinically was presumably a large cyst or detachment just described, which ruptured on opening the eye immediately after removal.

Pagenstecher, in an article on "Multiple Cysts on the Posterior Surface of Iris and on the Ciliary Body" (von Graefe's Archiv, vol. lxxiv), describes a case where a cyst of the posterior surface of the iris pushed the iris forward. A diagnosis of malignant tumor was made. After enucleation a separation of the two pigment layers at the posterior surface of the iris was found corresponding to the site of the tumor. Other smaller cysts were present. No glaucoma was present, though in Wintersteiner's case, quoted in this article, symptoms of increased tension were present.

DISCUSSION.

DR. E. FUCHS, Vienna: I mentioned to Dr. Knapp a similar case of tumor springing from the ciliary body. It was brown in color, and seemed perfectly solid, but, by means of transillumination, it was found to be so transparent that it seemed possible that it might be a non-pigmented tumor. I penetrated it with a needle. It collapsed, and remained much smaller than before. It was seen after this that it was only a big cyst springing from the ciliary portion of the eye.

THE POSITION OF THE EYE THE EI
SAFETY IN THE EAST INDIAN EY

far to substantiate the fact that when the eye looks up during the operation no loss of vitreous is to be expected. Since then I have had an opportunity to try this method in two cases.

The first was a man forty-two years of age who had been struck on the right eye by a piece of wood on November 26, 1910. The lens was dislocated upward, outward, and backward, so that only a crescent of its edge remained in the dilated pupil. An incision was made with one sweep of the knife, as described by Colonel Smith. There was an immediate escape of some fluid of watery consistency, which probably came from a pocket of degeneration in the vitreous immediately about the dislocated lens. The patient was told to look up, which he did strongly. Counterpressure was made above the wound with the spatula and pressure applied with the point of the strabismus hook at the junction of the middle and lower third of the cornea. This was made directly backward toward the center of the eye. The lens moved forward to the middle of the wound, the bottom edge turned upward, and the lens emerged from the wound without any loss of its contour. It was not in its capsule. Vitreous did not present in the lips of the wound during the operation. As the lens was opaque, the capsule may have been ruptured by the original injury, or it may have been ruptured at the time of the operation. The capsule retracted toward the position in which the lens was before it was removed. The wound healed without incident, and the pupil and the area of the coloboma of the iris were subsequently entirely free of lens capsule. The movement of the lens in this instance was similar to that described by Dr. Smith, and to which lenses he has given the term "tumbler."

The second case was that of a man thirty-three years of age, who was struck in the right eye on January 11, 1911, by a piece of wood. He appeared at the Massachusetts Charitable Eye and Ear Infirmary three weeks after the

accident, referred by Dr. Carleton, of Hanov
that time there was a slight amount of conj
tion. No corneal scar was visible, and with
dilated pupil the edge of an opaque lens was s
downward and outward.

On January 26th, under cocain, an incision

INTRACAPSULAR EXTRACTION OF THE CATARACTOUS LENS.

ROBERT SATTLER, M.D.,
Cincinnati, Ohio.

The von Graefe method of modified linear extraction in its present perfected form has given general satisfaction and has deservedly become an almost universal practice. It assumes that the most opportune time for the delivery of the cataractous lens is at or during a relatively advanced or mature stage of its progress. The opening incision and iridectomy are its cardinal features, and have the unqualified approval of common experience; but the means for delivery of the lens by opening the capsule and expressing its contents, leaving a more or less torn and not always empty capsule in the eye, have remained its weak and objectionable points.

What may be said hereafter must not be construed as an expression of disappointment either with the visual results obtained or with the technical execution of the operative sequence of the modern method of linear extraction of senile cataract.

A larger series of consecutive extractions made after this method only, during the last ten years, would conclusively refute this, and would rather emphatically confirm what is generally admitted—that for the average ophthalmic surgeon, and certainly so far as my own personal experience bears out, it has been eminently satisfactory, and for this reason is justly preferred on its own merits of safety and facility of technic. This experience supports the commonly accepted statement that total failures have been reduced to 2%, but adds an additional 2% loss, and in one series of

spoon. The latter is the plan I have followe extraction is not always possible by this mea ing and retention of the capsule, as the zon is firm and offers greater resistance to the at best difficult to manage if lens and caps moved jointly.

Concerning the most important point o final restoration of useful vision after the d tive interference are safely over, and abili resume occupation or professional work has l the modified linear method has yielded me n and numerous excellent results, as well as i indifferent ones and failures. From a surgic I have never been able to overlook the obj sequence of capsular thickening and visi opacity of the pupillary area found even in cessful cases. Each cyclus of new cases, in minor post-operative interference with th thickened capsule is necessary, is undertake understanding of its uncertainty and dange

This shortcoming from a surgical point of the consequences which follow the technic lens delivery as part of the modified linear met the most ingenious surgical skill and inventi sought in vain to overcome, forces us irresisti our search for a possible means to avert these one of which alone adds 1% or even 2% to t the first or major surgical interference of ext method.

It was with this purpose in mind, and to dis whether delivery in capsule along wholly di before used surgical lines, such as proposed Smith, was practicable for our cases, that a s gations was begun. The earlier results were this led to others on a larger scale, of which th

synopsis, and leads to the conclusion that it is safe and practicable for a large share of our cases from choice, and for a smaller one most certainly advisable.

A successful method which would include extraction in capsule has until recently not been known nor ever been made a possible or lasting part of the von Graefe method or any other.

For the reason that the Smith method directs a new and different technical execution for lens delivery in capsule, it deserves an impartial consideration and a fair trial.

The credit of having revived in us the hope of a possible safe extraction in capsule belongs to Colonel H. Smith, now of Amritsar, India.

The operation is now known, and justly so, as the Smith or Smith Indian method, for until Colonel Smith proposed the method all similar suggestions, even the one in question, practised for a much longer period by the Pagenstechers and their followers, for the delivery of the lens in capsule, were found wanting in safety and facility of technic, and were speedily and silently abandoned. The glamour which surrounded the first almost fabulous numerical accounts, together with the imperfect evolution of its technic, the vague and varied directions for the execution of its distinctively new feature, combined at first to deprive the Smith method of the recognition and consideration to which it was entitled for the following reason: The lens delivery of the Smith Indian method is radically different from all former ones. It disposes of lens and capsule in one movement. If successful, it eliminates permanently the dread and danger of post-operative surgery, which is necessary in more than one-half of the successful extractions after the linear method. This alone should afford it an impartial trial. It points out also a long-sought technical deftness and new instrument, with instructions which can be safely followed by any trained and calm ophthalmic surgeon, as well as by those of larger experience and specially acquired skill. It cannot be

considered a rival method, for it claims only in a safer way the same purpose of lens deliv of a different technic. The visual results further surgery is unnecessary, and it is a fi cess.

Against it are admitted objections, some tive, as to what becomes of the posterior cap for the iris, and the tangible ones of immin loss of vitreous, an ovoid, drawn-up pupil, o punctation of the hyaloid envelop; but neitl are any more certain consequences than tha the capsule or retained corticalis, its opacifica ing, must happen in every case after capsule expression with the modified linear method.

As a new method, that of Colonel Smith attract me. To again transfer the opening clear cornea, and without a flap of bulba upset all my cherished and confirmed convict security for my patient, and for me facility extraction.

The iridectomy also had from the first m It was unsurgical in its execution and incom concerned the making it a clean excision with divergent limbs reaching to the periphery of t peared to me at that time, and does so at presen practical experience, that the iridectomy is a tionable feature of the new method. Much of t urged against it, that an ovoid, drawn-up pu common an attendant, even of a successful ext method, is a necessary sequence of too small an excision of the iris, often embracing onl border, or a triangular slit with its base towar border. It is claimed by Colonel Smith that introduction of the iris forceps into the eye, be made to prolapse by gentle pressure with

ceps against the outer wound margin, and with light pressure only a small knuckle of iris made to prolapse, which is quickly abscised." With the exception of doing this in a few first cases, I have not followed this suggestion since, or in the larger number of cases which followed.

For the reason that the distinctive feature of the Smith method, *i. e.*, lens delivery in its intact capsule, was not for a long time fully understood by me, even after a thorough study of Colonel Smith's published accounts of his visit to New York and his personal demonstrations there, and other sources of information as well, I was nevertheless convinced, even with inadequate appreciation of its technical execution and with limited trials, that it merited more careful investigation. Now that experience has added a larger number of cases, Colonel Smith in his book has more specifically explained it, and more recently, my associate, Dr. Clarence King, has given additional and more exact information, a brief description of the technical execution of the cardinal feature of lens delivery in capsule by the Smith method, as now interpreted and practised, may convey a fuller meaning.

Let us assume that incision and iridectomy have satisfactorily preceded it. After a brief interval, the upper lid is securely held with a blunt hook in the right hand, and the lower lid with the fingers of the left one of an assistant whose manual dexterity, good judgment, and knowledge of every possible happening during and after its execution enable him to control even the voluntary or other contractions of the lid muscles. This should afford an unobstructed though deep view of the field of operation, with unrestricted freedom to begin the pressure movements which, if successfully carried out, effect the expulsion of the lens in its intact capsule. This pressure is exerted through the medium of a large blunt or rounded strabismus hook, over a limited area of the cornea not much larger than its point, and near the lower border or even slightly beyond or below it.

It is sufficiently firm from the first; it m
continuous in force or definite in direction
tain that the equatorial ridge of the lens c
felt through the indented groove of the corn
It is this indentation of the cornea and the
around the equatorial ridge of the lens w
operator, through pressure carefully and fir
the point mentioned, to rupture the zonu
above or below. That this has happened w
dent at once. If it is ruptured above, the
pressure directly backward will tilt the u
zone of the lens into the wound, which it fill
ator must hold there until he is convinced t
detachment is complete. At the finish, its
be assisted by gentle tapping or by scoopi
truded lens with the hollow or concave porti
now used for this purpose. If the zonula r
either accidentally or because the lens is
because it is the intention of the operator
rotate or tumble, and will even more com
wound, and must be held there by the ope
zonular attachment is fully torn above. T

th
tic

m
in

de
pl
in
to

vi
te
m
vi

wi
ce
su

to
re
ca

de
ol
be
ex
ne
ur
in
ru
m
fa
tu

and expression. Thirteen of the twenty-fiv recoveries. Eight of these could be classed a perfect in so far as vision for distance and cerned, as well as a speedy, painless, and healing.

Five of the remaining twelve had drawn not sufficiently so as to interfere with visio subsequent surgery. The rest made incon but satisfactory visual recoveries. The lowe ing was 0.3. There was no casualty.

For the remaining twenty-five I had ad method. I confess to having taken some li iridectomy; whenever possible, a preliminary and, this impossible, the iris excision was not triangular rent of the pupillary border, but free limbs to its periphery. This series inc exceptional responsibility. Two cases wer subjects, aged forty-four and forty-nine. I one eye, the result of a former injury. Both consequence of slowly increasing loss of visi insistent that something should be done. In was swollen, the opacity not striated, but blo mistakable capsular thickening and patholog

Of the later cases, one was a man aged seventy-eight, in feeble general health, with a hard sclerosed lens, great capsular thickening, and concretional deposits. The other eye was hopeless. Intracapsular delivery was done without difficulty, but with slight loss of vitreous and an adherent zonula. Even the equatorial regions of this lens were found studded with the concretional, colloid, or calcareous deposits. Total loss followed this attempt.

There was an almost hopeless outlook in another case—a man upon whom seventeen years previously double iridectomy for acute glaucoma had been done, but in which functional tests still justified, or rather commanded, interference. One eye was hopeless; the other had a central darker opacity, but the entire lens was sclerosed and dark amber in color, and the capsule, under high magnification, was full of punctated thickened areas. The lens was removed in capsule and was huge in proportion and thickness. Capsule opening and expression in this case would not have been justifiable. It is true that much vision was not recovered, but an absolutely uncomplicated, painless recovery followed.

The series includes, further, one additional total failure, but this is not to be attributed to the attempt at intracapsular delivery, for the eye was lost before this was accomplished. The patient, who was a neuropathic subject seventy-six years old, with pronounced arteriosclerosis, became uncontrollable when the incision for a preliminary iridectomy had hardly been completed, squeezed the speculum, and extruded the contents of the globe. A general anesthetic and removal of the eye, the only safeguard against a tedious recovery, was promptly advised and carried out.

Another uncommon experience was afforded by a woman aged sixty-eight who had great apprehension that the operation would not prove successful. The eye had a sclerosed, centrally opaque lens, but she was able to go about without

assistance in her own home. There was little or no progress in the lenticular opacity after a preliminary iridectomy fourteen months previous. *I was loath to advise the operation and she was eager to defer it, but finally became intolerant of her helplessness and submitted. The other eye had cataracta accreta, firm iris synechiæ; vision, 0. The eye for operation had a thickened capsule, which the iridectomy had uncovered and enabled us to make out most satisfactorily. The case was certainly one for which intracapsular removal afforded the best and only chance for success. It was done without loss of vitreous. The lens was very large, with capsular deposits on both surfaces, but in particular on the posterior. There was no reaction of any kind. On the third day a visual test was made. She was found totally blind, not even able to distinguish movements of the hand, and had only an uncertain light perception. As already stated, there was nothing to indicate infection or other complication. The ophthalmoscope disclosed absolutely clear media, and the fundus presented an appearance so startling that at first we thought an unsuspected intraocular neoplasm had been uncovered by the operation. More careful observation established that it was an extensive detachment of the choroid. For six days this truly wonderful ophthalmoscopic picture lasted, then slowly receded under no treatment, and the patient was dismissed three weeks afterward with vision 0.1, which during the interval of one year has increased to 0.5, with ability to read ordinary print. No trace of the former extensive detachment of the choroid can be discovered.

I mention these cases only to prove that a fair test was accorded the Smith method, after the manner we practised it, with the best information which could at that time be obtained for its technical execution. Let me add that in most of these cases the pressure movements to deliver the lens were not confined, as at present advocated and prac-

tised by me, to a limited area, but with the sa
get the point of the hook under the lens bord
follow it up with strokings until the lens was
over a larger area of the cornea.

The practical information furnished by th
of cases was conclusive on one point—that
delivery after Smith's execution cannot be m
safe part or substitute of the older method
practised. If with the old method it is impos
after capsule opening and expression, the vec
spoon is the best and safest expedient to effe
All other means, including Smith's, are inferi
tain.

If the indications are plain for removal in ca
selected as the most rational, the safest techn
to effect it is the method proposed and pract
sively by Colonel Henry Smith—the opening i
in the cornea; the knife entered at an angle of
more or less, to the equatorial plane. If succe
out, it is a more brilliant achievement from a

outside of the globe is possible, is a new fact and an important disclosure of the Smith method.

Intracapsular extraction is selected by me from choice in those cases in which I can distinctly make out the presence of a swollen or rounded lens, with additional objective proof that the equatorial regions are not too angular. The depth of the anterior chamber, retraction of the periphery of the iris, and preliminary iridectomy are the principal means to determine this.

If capsular thickening is present, it is an additional reason for its choice. The age-period which I found most favorable for delivery in capsule, with the conditions just mentioned present, was between fifty and sixty. For Morgagnian cataract with capsular thickening, I have also found that it affords a safer and readier means to extract in capsule.

For certain cases I would use the older method from choice and experience, and select them accordingly. These cases include in particular those of slowly advancing lenticular sclerosis or desiccation in older subjects or those past sixty-five, but even under this age-period, if the same advanced lenticular senile changes are present; but I must be able to prove the absence of capsular thickening or opacity. If, in addition, it can be assumed that the lens is shrunken and hard throughout, dark yellowish or brownish-black in color, semi-translucent, flat on its surfaces and angular at its periphery or equator, capsule opening and expression accomplish the purpose of lens delivery with lesser risk and greater ease.

I also believe that it is the safer method for extraction in younger subjects around the age of forty-five, who, with other evidence of pre-senility, develop cataract which advances more rapidly to complete opacity, with waxy texture, and flat and inelastic lens, often with capsular thickening and adhesion. The same changes occur as in older subjects, only more rapidly enacted and attended by greater

shrinkage of lens and wrinkling of capsule. I have also found it best not to attempt aga removal, but to rely on the old method, wit an expedient for final delivery.

In general, the cases most favorable fo removal are those with lenses that have not

Linear Extraction.	Extraction in Capsule.
Case I.—Woman aged fifty-nine. Operation six years ago. V=0.7. Two capsulotomies. Has thickened and opaque capsule but clear central area.	Complete operation, uncomplicated delivery. Leakage of the wound for seven days. No iris incarceration. V=0.9. Visual and surgical results incomparably more favorable than fellow-eye.
Case II.—Woman aged sixty-two. Operation two and a half years ago. Eye diverged, lens hypermature: capsule thick. Uneventful recovery. V=0.4. Dense capsular opacity and thickening.	Preliminary iridectomy. Extraction in capsule without accident. V=0.7. Reads finest print with corrective lenses. Healing uneventful, no iritis and at no time indication for treatment. Surgically and visually greater success than fellow-eye.
Case III.—Man aged sixty-seven. Operation three years ago. This eye had iridodialysis from blow, but functionally sound otherwise. Lens hypermature: capsule not thickened. V=0.8+ for distance and full normal for reading with corrective lenses. Uneventful recovery, but two capsulotomies necessary to restore present vision.	Preliminary iridectomy. Extraction in capsule: rupture and retention of capsule. Large loss of vitreous. Final recovery with drawn-up pupil; cystoid scar of incision. From surgical point of view, complete failure. Final recovery of 0.3 vision, but which, owing to the perfect state of the other eye, is impracticable. Incomparably in favor of the first eye.
Case IV.—Man aged seventy-one. Operation eleven years ago. Until two years ago was able to read satisfactorily with lenses, and distance vision was equally perfect. V=0.3, but had dense capsule and needs discission operation.	Preliminary iridectomy. Extraction in capsule without accident. Absolutely painless and rapid healing. V=0.8. Incomparably more favorable from both a visual and surgical point of view.
Case V.—Woman aged seventy-nine. Operation thirteen years ago. Has V=0.4 in spite of iris adhesion, dense and opaque capsule. Two capsulotomies.	Complete operation. Delivery of lens in capsule without accident, but extremely tedious, as lens was flat and hard. Uneventful healing, except hazy cornea from pressure, but pupil drawn up and eye invaded by a low grade of uveitis. Final recovery. V=0.1. Refused iridectomy on account of her age. Visually a failure without an iridectomy, surgically equally so.

In two cases an extraction in capsule was performed on the first eye and a subsequent linear extraction on the other. In the first one it was unsuccessful, even though a subsequent iridectomy restored 0.3 vision. The lens of the eye was extracted by the linear method, preceded by preliminary iridectomy, with restoration of 0.5 vision, but will require subsequent surgery, as capsular thickening is in progress. In the second case intracapsular removal of the first eye was attended by bursting of the capsule and its retention, but after a tedious recovery and excessively bad surgical result the patient had 0.3 vision.

The lens of the other eye was extracted by the linear method, followed by tedious recovery owing to retention of corticalis, dense capsular thickening, secondary glaucoma. An iridectomy controlled, but could not avert, what can only be considered a failure surgically and visually.

I now advise and practise preliminary iridectomy, and insist upon it in every case in which I decide upon an intracapsular operation.

It must be added that in the selection of suitable cases for extraction in capsule of the last fifty cases, sixteen were intracapsular. The rest were linear extractions, and many of the latter were very disappointing, owing to the necessity of post-operative surgery. My excess of caution must be attributed to the experience gained from the first fifty and an equal desire fairly to match and test the linear method. The total loss of the one hundred cases was 1%, with additional 1% equivalent to a loss, but with preservation of the globe, and vision less than 0.1. The perfect intracapsular recoveries compared more favorably with the perfect ones of the linear method because of their absolutely clear pupillary area and the absence of the necessity of additional surgery. The partial successes of the intracapsular compared as favorably with the similar ones of the older method.

Again let me add that he who attempts to extract in can-

sule after the Smith method must keep well in mind that the pressure movements against the cornea must make of the vitreous and its elastic envelop a cushion, of the upper overhanging wound of the cornea a support or buttress against which, if the elasticity of the globe and the resistance of the hyaloid can be counted upon, rupture of the zonula will take place, followed speedily by the delivery of the lens in its unbroken capsule.

The series of fifty additional cases has been reduced through the fairest exercise of selection of one intracapsular extraction to three of the modified linear one. This is neither for nor against one or the other, but is rather a confirmation of the fact that both are entitled to equal recognition and trial, and that for some cases, as those which have been mentioned, the older method offers the safest and most facile means, and for others, the intracapsular method, after Smith, is not only the best, but the only justifiable one.

THE IRIS IN THE INTRACAPSULAR OPERATION FOR CATARACT.

ANDREW TIMBERMAN, M.D.,
Columbus, Ohio.

For a number of years, now, there have been numerous contributions to the literature on the subject of the intracapsular extraction of the cataractous lens. These contributions have been valuable in focusing the attention and interest of the profession on the subject, and in enlightening the members as to the technic of the operation, the results obtained by different operators, the general difficulties connected with the operation, a description of the instruments used, and a narration of the experiences of those who have

made the pilgrimage to the Mecca of present-day cataract work. It is saying not too much, I take it, to assert that no operation in general or special surgery has elicited more interest or occasioned a more animated discussion than has the one devised for the intracapsular extraction of cataract. On all sides there is the note of accord that it is the ideal operation, provided it can be done successfully—as successfully as the capsulotomy operation is done. On the other hand, there is almost a unanimity of opinion that the difficulties are so great, the technic so complex, the impending dangers so monumental, that the stamp of approval of the ophthalmic profession has not yet been given. I regard this position of the profession as a beneficent one, because, as a profession, we are no more capable of doing this operation than the ordinary laryngologist is of doing the work of Chevalier Jackson, even with a set of Jackson's instruments in his hands. But discussion of the subject is valuable. The more discussion of it we have, the more familiar with it we will become, and the more familiar with it we are, the better we will understand it, and the more likely we are to use it intelligently and skilfully when we do use it.

The importance of the rôle which the iris plays in any method of cataract extraction has been recognized as long as the operation has been done. Its chief physiologic func-

tion is to regulate the amount of light to be admitted to the

says—and he practises what he says—that it is safer and better in the intracapsular operation to do an iridectomy. During my visit to his clinic last autumn I had occasion to question some parts of the technic of his method of operating, only to find, on further experience, that he was always right. An experience with almost or quite 25,000 cases will give any bright, keen man, with good surgical judgment, a right to speak as one having authority. When, therefore, Smith says that the intracapsular operation is best done with an iridectomy, I shall always so do it, believing, as he asserts, that I shall have fewer prolapses. I shall not do an iridectomy because of any fear that the bruising of this membrane, on delivery of the lens, may cause an iritis. Observation of not a few cases leads me to believe that little is to be feared on this line, and, besides, Colonel Smith never gave that as a reason for doing an iridectomy.

But why do we have prolapse of the iris in cataract extraction, and where is the prolapse most likely to occur? Apart from those cases in which it is due to an injury, in which the position of the prolapse is somewhat determined by the direction from which the force of injury comes, we can say that it will occupy that portion of the wound having the least support, or at least be most pronounced at that point. This means exactly midway between the two angles of the incision. Here is where, in any cataract extraction, the iris has the least support; and if at that point a portion is excised, we are diminishing to just that extent the liability to prolapse. If this will hold good in the capsulotomy method, it certainly will in the intracapsular method, where the iris does not have the support of the unruptured posterior capsule. However well the two edges of the incision may be coaptated, the healing process is furthest advanced, at the end of any given period, at the angles of the incision; and midway between them it is least advanced. If we make our iridectomy, then, at this midway point, we lessen by

just so much our chances to have this membrane swept into an opening by the escaping aqueous, should there for any reason be a gaping of the wound. Atropin is used after extraction of the lens by some operators because they believe less of the iris is liable to be thus forced into the wound. There is no doubt but that the farther away from the scleral tissue we end our incision, the more protection we afford the iris. With small lenses this may well be half-way between the upper pupillary edge and the sclera. And these might well be thought to be the best cases in which to do the simple operation by any method of extraction. But by far the greater number of all cases do not have small lenses, and for the present an iridectomy seems the wisest thing to do in the intracapsular method of operating.

The usual procedure in doing an iridectomy is for an assistant to fix the eyeball with a pair of forceps and gently pull it downward; the operator himself grasps the iris, pulls it out, and excises a portion of it. There are thus three things to do in making an iridectomy—fix the eyeball, grasp the iris, and do the excision. From the time the incision is made, our dangers increase, and any false move or untoward manipulation of the instruments may cost the sight of an eye. To me the fixation of an eyeball in making an iridectomy is an act requiring skill and judgment. Just enough pressure must be made with the fixation forceps in grasping the conjunctiva and subjacent tissue to afford a firm hold and no more. An assistant may not know just where to put the forceps, and if he be a tyro at the work, certainly will not know how much pressure is necessary to give him a firm hold. He is, therefore, very likely to make excessive pressure upon the globe and rupture the zonula, as once happened in one of my cases. Should the operator himself fix the globe by means of fixation forceps with a catch, and then attempt to transfer the forceps, *in situ*, to an assistant, the same bungling may occur, with like disastrous results

even more likely to supervene. How much just the requisite amount of pressure upon the globe aids one in grasping the iris only those know who have tried the procedure. An assistant can hardly do any damage in handling the scissors. He can be instructed to straddle the protruding iris with the blades of the scissors at right angles to the wound, letting them lie gently upon the eyeball as he makes the excision. There is nothing else he can cut off, there is nothing he can run into, and there is no danger of him making undue pressure upon the globe. It seems to me, therefore, that fixing the eyeball and grasping and pulling out the iris are the two main and correlated steps in this operation, and should be done by the operator, leaving the act of excision of the iris to an assistant, as being less dangerous.

This is in no way offered as a criticism or as a modification of Colonel Smith's method of doing an iridectomy. It is not always possible for us to have such assistants as he has, for when working alone he has his trained man, and his pupils likewise are all trained in the use of ophthalmic instruments. His method is as follows: His assistant fixes the eyeball and gently pulls it downward, at the same time making just such pressure upon the globe as facilitates Smith's grasping the iris, as noted a moment before. The iris forceps are grasped between the thumb and the index and middle fingers of the left hand; with the ring and little fingers of this hand he pulls upward on the brow and adjacent skin, thus overcoming any tendency of the corrugator supercilii to squeeze. The forceps being held directly vertical to the incision at a point midway between the two angles, and the points toward the right temple, the posterior blade is dropped into the wound and permitted to rest against the scleral edge of the incision. The forceps are now permitted to swing open until the anterior blade on the outside of the cornea reaches to, or a little below, the upper edge of the pupil. Pressure is now made by this anterior blade upon

the cornea, denting it, and as it closes toward the posterior blade, causing the incision to gape and the iris to bulge, which is then grasped, pulled out, and excised. Colonel Smith is careful to deal gently when grasping the iris, claiming that a tight squeeze of it causes more pain than the act of cutting it off. This method cannot always be made to succeed, but is always tried in Smith's clinic. It has the advantages of less instrumentation within the aqueous chamber, less liability to rupture the anterior capsule, and less rough or irritative handling of the sensitive iris.

The ideal post-operative pupil, as has been noted above, is the one where no iridectomy is done—round, with full, free, unimpaired action of the sphincter pupillæ. The ideal post-operative coloboma of the iris will have sides or edges which stand in relation to each other, much like the marks of parenthesis. This gives the necessary protection against prolapse, and at the same time is not cosmetically unsightly. Another form often seen after intracapsular extraction is the U-shaped coloboma, in which no coloboma angles are seen, the pupil forming the bowl of the U, and the edges of the coloboma being straight and parallel. This also is not cosmetically objectionable. Departures from these two desirable types are numerous and are occasioned by loss of vitreous, inclusion of the iris in the angles of the incision, too large or too small iridectomy, and folding or tucking of the iris upon itself. As in all operations, and especially in this, where the technic is so complex, the experience of operators will soon guide them to the use of those procedures best calculated to give the more desirable results.

In discussing the question whether or not an iridectomy should be done, the writer noted the prophylactic features of that procedure as to prolapse of the iris. Now, many worse things than prolapse can happen to an eye. But it disturbs the normal function of the iris, causes the patient some pain, distorts the pupil, induces another operation, and

is disquieting to surgeon and patient. Judged on purely mechanical considerations, it ought to occur more frequently in the intracapsular operation than in the standard capsulotomy method. Practically, however, I doubt if it does, as I feel quite certain that the various contingencies that arise as the result of retained cortex and capsule outnumber the disadvantages of loss of posterior capsule as a supporting membrane. My own percentage of prolapse of iris was about 3%. I did 207 extractions in Smith's clinic, but was not able, on account of sickness, to take notes on my first 75 cases; nor does it include my last cases, so that my records are made up from what might be considered neither my worst nor my best work, but just an average record. I have no doubt but that a correctly made and correctly placed incision will do much to prevent prolapse. We will occasionally have prolapses and be able to give no satisfactory explanation for them. Large ones should be excised, small ones let alone, as they will usually settle down without operative interference. In excising a prolapsed iris, the lids should be held by an assistant, exactly as Smith says they should be held, while extracting the lens. Thus only two instruments, the lid hook and a pair of curved scissors, are used. A pressure bandage should be avoided.

On one point of the intracapsular extraction of the lens all observers are agreed, viz., that there is almost no tendency to iritis. In view of what this operation has shown, we must conclude that iritis after cataract extraction must be mainly due to retained cortex or capsule. When Captain W. E. J. Lister could do 579 operations for cataract and not have a single case of iritis, it speaks volumes which no amount of hypothetic reasoning can budge. Further argument does not seem necessary. Even when it does occur, it is robbed of many of its terrors, for it is usually very mild in form. This does not seem difficult to comprehend when we remember that there is no occasion for an unholy and en-

tangling alliance between the iridic exudate and some firm structure like the posterior capsule. But the exudate coming in contact only with the aqueous and vitreous humors, it is not difficult to understand that the reparative processes are accelerated and the exudate easily and quickly carried away.

On the other hand, replacement of the iris when displaced during the operation is more easily effected when the posterior capsule is left *in situ.* The iris itself is a sticky membrane and the viscid vitreous no less so. The interposition of the smooth, non-adherent, and rather firm posterior capsule of the lens permits of many manipulations of the iris impossible when no such membrane is present. In nervous, restless, sensitive patients, therefore, it may be difficult or impossible to make such replacement in a satisfactory manner. But it must be remembered that it is equally so by the old method, when there is rupture of the zonula and threatened escape of vitreous. The intracapsular method has the obvious advantage of absence of all lenticular substance, and any faulty position of the iris is not anywhere near so apt to occasion trouble. For it is a common observation in Smith's clinic, where literally hundreds of cases may be seen at one time, that the troublesome cases are usually due to retained capsule and lens matter.

There are many important phases of technic as done and recommended by Colonel Smith. There must be a trained assistant, the incision must be larger than usual, it must be correctly placed, the iridectomy properly done, the lids must be controlled during the extraction of the lens, and the delivery of the lens itself requires delicacy of touch, skill, judgment, and courage. I know of no single act requiring a more splendid exhibition of courage in the face of an impending danger than the bold use of the spoon for the prevention of escape of vitreous and the delivery of the lens. And yet I

nated, and Beer, who perfected, cataract e
has been none greater than Graefe, who ad
cedure because he became convinced, throug
of knowledge and a vast experience, that it h
Up to this date the majority of the statist
there was no error in his judgment. Persona
cide with the opinion of Professor Voelckers,
sity at Kiel, one of the most careful and mos
tors of his time, when he remarked regarding
"it has always served me well, giving me th
percentage of success, and I am entirely sati
While we may laud the efforts of those who
find something better, we realize at the same
infrequently these efforts are at the cost of ma
might have been saved had the "modified line
prevailed.

With each individual eye the problem is th
of the operation with the least possible loca
the least general trauma to the globe, in ac

from the lower conjunctival cul-de-sac, and the whole conjunctiva is then gently irrigated with a normal saline solution. Twenty-four hours later this is repeated. If all of the four cultures are found to be negative after another twenty-four hours, the operation is proceeded with, preliminary attention having been exercised in the cleansing of the intestinal tract. Atropin is instilled provided no glaucomatous symptoms are present and there has been no previous atropin irritation. This latter may be tested by placing a drop of an atropin solution, $\frac{1}{120}$, in the eye immediately after the first irrigation. Should no irritation develop, this is repeated twelve hours previous to, and again just before, the operation. This will keep the pupil more or less dilated during the succeeding four days, in which the eye had best not be disturbed.

The turning of the eyelids and otherwise manipulating the eye, even to placing the speculum and removing it several times before taking the second cultures, are of great value in acquainting the patient with one's touch, and also in training the patient to refrain from gripping the lids during the progress of the operation.

Although the operation may very safely be undertaken in a private residence or in a hotel, this is not to be encouraged. For the performance of an operation of such profound importance to the patient there is no place so safe as a clean, properly lighted operating room. As a rule, the modern white-tile operating room, with its glaring, eye-straining, optically unscientific walls, is as unfit for the fine, delicate work of the general surgeon as it is for the fine work of the ophthalmic surgeon. In such rooms the glare may be partly overcome by means of dark-green screens, 6 or 7 feet high, properly placed about the operating bed. The ideal operating room should have a gray floor, dark gray-green walls, a light cream ceiling, and a large, high north window fitted with clear glass. Also, ideally, the patient

should not be disturbed when the operation has
Lack of attention to this important point is
the cause of many preventable hemorrhages.
For this reason a bed with comfortable, easily
head-rest, and low head- or foot-piece should

For lid retractors the fingers of an expert assistant are perhaps the most reliable. Otherwise any readily adjustable lid speculum will serve. It should be one that can be removed instantly without pressure on the globe.

Fixation is another important matter to which little attention is ordinarily given, the prevailing idea seeming to be that skill will overcome any obstacle. However true this may be, the globe will frequently rotate in the most skilful hands and under the most clever manipulation, often with the result of a faulty counterpuncture, which is invariably irritating to the operator. In my own work this is avoided by the employment of a two-pronged fixation forceps, such as is shown in the accompanying diagram (Fig. 1), with

Fig. 1.—Two-pronged or double fixation forceps.

which the fixation is made in the conjunctiva on either side of the cornea just below the horizontal meridian. In a first trial the instrument may seem to be clumsy because of one having to guide the two prongs at once, but this is readily overcome with a little practice.

The corneal incision may be executed with a broad lance-shaped keratome, or with any of the counterpuncture knives in common use. Whichever is chosen, it should be thin, perfectly keen-edged, free from stains, and without a perceptible flaw. Among those last mentioned I prefer a broad, thin Graefe knife as a protection against engaging the iris. It is entered 0.25 to 0.5 mm. beyond the clear cornea in the sclerocorneal margin, and 2 to 3 mm. above the horizontal meridian; the counterpuncture is made in the same

horizontal line, and the incision is maintained in the same plane until the upper corneal margin is reached, where it had best finish with a small conjunctival flap. If a keratome is employed, my own choice is one with a rectangular point, the lateral angles 12.5 mm. apart, the angle of the blades to the handle 155 degrees, and the heel of the blade a curve corresponding to the curve of the sclerocorneal margin, such as is shown in the accompanying illustration (Fig. 2). With this knife the incision is begun in the sclerocorneal margin, 0.25 to 0.5 mm. above the clear cornea, and should be maintained in this plane, or nearly so. There is, however, no harm in passing the point of the blade back of the iris at the lower pupillary margin, in such a way as to enter the lens capsule. Several cases in which I have accomplished this have resulted most favorably. With either knife great care should be exercised to avoid injuring the clear cornea, and also to avoid injury to the region of the canal of Schlemm, for interference with the latter will interfere with the circulation of the anterior chamber, and injury to the cornea anterior to the vascular support may mean a breaking-down of the adjoining epithelium and tardy healing, as well as delayed closure of the wound. By fixation with the two-pronged forceps the globe may be held very firmly in position for an exact incision with any form of knife without injurious pressure on the globe.

Fig. 2.—Lance-shaped knife or keratome in which the heel of the blade has the curve of the sclerocorneal margin.

For incisions of equal size externally the larger incision on the posterior surface of the cornea will be made by the keratome, as is demonstrated in the diagram (Fig. 3). Also in case the corneal margin flattens in using this knife and the lateral angles of the knife pass somewhat further backward than was intended, better protection is afforded the conjunctiva than is possible with a linear knife when an

;

about the upper margin of the natural small pu similar snip should be made in the capsule to firs and then the other, in each snip one blade bei behind and the other in front of the capsule. movement is then repeated and the scissors are closed. This procedure thoroughly removes th without tugging at the zonule or dislocating the frequently happens with capsule needles or wit forceps.

Following the central bite with the scissors the cisions may be made with the sickle needle or oth

Fig. 4*b*.—Toothed scissors for the abscission of the lens capsu extraction; blades greatly enlarged to show more accurately th tion.

cystotome instead of with the scissors. My clean have been with the scissors. In the toothed s shown in the above-mentioned illustration, the po long tooth of the right blade is set a little backwa structed in this way, the blade readily engages th and the tooth does not interfere in the least with th edge of the blades. At the base of each tooth nick (Fig. 4*b*), the purpose of which is to hang th portion of the capsule and bring it away in the w of the scissors from the wound.

It is possible that scissors of the sheep-shear typ

the whole central portion of the capsule at o
an opening sufficiently wide in the capsule

case the sickle needle was employed to further divide the capsule in its upper portion to either side.

Should the excised portion of the capsule not cling to the scissors, it will come away with the lens, the removal of which is accomplished in the usual way by a very mild support of the posterior lip of the wound above with the back of a Daviel spoon, and direct pressure backward with the back of a cataract spoon or of a Daviel spoon at the lower sclerocorneal margin, and after the margin of the lens is well engaged in the wound, by slowly stroking the cornea backward and upward at the center and to either side so as to have all the cortex follow the nucleus. After the lens is away the iris is again replaced with the silver spatula, the lips of the corneal wound are carefully approximated, also the edges of the conjunctival flap, and all shreds of blood or coagulum are removed with forceps from about the wound and from the conjunctival sac. The whole conjunctival sac is then gently irrigated with normal saline solution, the upper lid being lifted a little from the globe and the solution permitted to flow over the wound from the nasal side and drain toward the temporal side into a sterilized towel or basin. This will frequently clear the anterior chamber of any remaining cortex and assist in approximating the lips of the corneal wound and in adjusting the conjunctival flap.

A thin pledget of sterilized cotton moistened in mercury bichlorid (1 : 5000) is then placed over the closed lids of each eye, and over this a light pad of dry, sterilized, absorbent cotton, just sufficient to round out the orbit from the eyebrow to the cheek, and the whole dressing is held firmly in place by a single layer of gauze fastened about the margins of the orbit with collodion. The moistened bichlorid pledget acts as a ready absorbent while an absorbent is needed; it then becomes dry, and being molded to the contour of the lids, it acts as a splint to keep the lids approximated. The dressing is further protected against light and injury by a

to the fellow-eye in the matter of properly cleansing it with a borax or a boric-acid solution. Returning to the operated eye, after resterilizing the hands, the lower conjunctival sac is gently irrigated with a normal saline solution and the atropin and cocain solution is repeated. A temporary covering is applied with adhesive for half an hour. The atropin and cocain solution is again repeated, and the eye dressed as at first, except that a pledget of dry gauze takes the place of the moistened bichlorid pledget. After twenty-four hours this is repeated, and again after another twenty-four hours, when the wound may be inspected. If the cornea is clear on the first removal of the bandage and there is a good anterior chamber, which may be determined by gently depressing the lower lid, and very little conjunctival injection exists, inspection of the wound is unnecessary. Its non-inspection avoids the liability to infection and to irritation. As a guard against irritation, the lids are not everted, and no pressure is made in the region of the wound for a number of weeks after the healing is completed.

While many surgeons remove the bandage permanently on the seventh or eighth day, a disagreeable experience in my first extraction taught me that there is far less liability to cyclitic or iritic hyperemia if it is worn for ten days or two weeks, and if the choice is left to the patient to assume or not assume the responsibility after the reason has been explained, I find there is never any trouble in having it worn cheerfully till all circumcorneal irritation has subsided in the region of the wound. With the Ring mask adjusted as above described, I have never met with the necessity of forcible control of the patient in the matter of binding the hands. Careful instructions are given regarding the blowing of the nose, this being forbidden, also straining at stool, or making any movement which would cause a sudden increase in the blood-pressure to the head. The value of these precautions was demonstrated to me early in my ophthalmic

career by an uncomfortable disaster which is
mentioned here, as it bears directly on this
days after an extraction the weather began

The value of removing the capsule by abscission, which prompted the writing of this paper, is demonstrated in the following examples, in which the appearance presented by the membranes which remained in the pupils, as seen with the ophthalmoscope, is illustrated by accurate drawings of as many of them as could be obtained.

CASE 1.—Male, aged fifty-seven, incision with Graefe knife, abscission of capsule with De Wecker scissors, apparently no result, division with sickle needle, nucleus 3×8.5 mm., pupil much clearer than ordinarily obtained with cystotome or with sickle needle, floating shreds in vitreous. As. 2 D., cyl. rejected, V = $\frac{20}{38}$+, reads 5-point type readily.

CASE 2.—Female, aged fifty-five, Graefe knife incision, capsule abscission with De Wecker scissors, single snip, nucleus 3×6 mm., chalky, clear central pupil with dense capsule to either side (Fig. 5).* As. 1.5 D., cyl. rejected, V = $\frac{20}{75}$+, reads 10-point type readily, large central retinochoroidal atrophic spot, central vision in fellow-eye lost by similar trouble.

CASE 3.—Female, aged fifty, incision with keratome, capsule abscission with De Wecker scissors and lateral incisions with sickle needle, nucleus 4×8 mm., As. 2.5 D., cyl. rejected, V = $\frac{20}{24}$+, reads 5-point type readily, clear pupil.

CASE 4.—Female, aged seventy-three, preliminary iridectomy, keratome incision, capsule abscission with De Wecker scissors and lateral incisions with sickle needle, nucleus 3.5 ×7 mm., considerable sticky cortex, after its absorption a clear pupil (Fig. 6).* V = $\frac{20}{20}$, As. 7 D., reads 3½-point type readily.

CASE 5.—Male, aged fifty-nine, fixation with two-pronged forceps, keratome incision and puncture of capsule at lower pupillary margin, capsule abscission with toothed scissors, De Wecker mechanism, nucleus 3.5×7.5 mm., clear pupil (Fig. 7). As. 2 D., V = $\frac{20}{15}$, reads 3½-point type readily.

CASE 6.—Female, aged forty-five, double fixation forceps, keratome, capsule abscission with toothed scissors, De Wecker mechanism, nucleus not measured, clear openings in pupil (Fig. 8), seven days after the operation bleeding from

*The diagrams of the pupils in Case 2 and Case 4 are also included, being obtained after the reading of the paper.

Fig. 5.

Fig. 6.

Fig. 8.

Fig. 9.

Fig. 11.

Fig. 12



the nose and moderate hemorrhage in ante
As. 1 D., cyl. rejected, V = $\frac{20}{24}$+, reads 5-poin
Patient ill for eighteen months previous to
with double valvular cardiac lesion.

CASE 7.—Male, aged sixty-three, double fi
keratome, puncture of capsule at lower pu
abscission with toothed scissors, De Wecke
nucleus 3.5×7 mm. As. 3.5 D., V = $\frac{20}{15}$, reads
readily, clear pupil (Fig. 9).

CASE 8.—Female, aged seventy-seven, d
forceps, keratome, puncture of capsule at lo
margin, capsule abscission with toothed scisso
mechanism, nucleus 3.5×7.5 mm., clear pu
As. 1.75 D., V = $\frac{20}{15}$+, reads 5-point type readi

CASE 9.—Male, aged seventy-seven, very
litic, old choroiditis observed in both eyes th
vious, pupil 5 mm. in diameter and eccentri
outward, black cataract, double fixation force
puncture of capsule at lower margin of pupi

Every precaution should be exercised in the matter of asepsis.

Prolonged holocain and short cocain anesthesia; atropin unless contraindicated.

Fixation with double fixation forceps.

Incision with a counterpuncture knife or a broad lance-shaped keratome.

Small iridectomy opposite center of the corneal incision.

Abscission of the anterior capsule with toothed scissors.

Replacing of the iris by the aid of a thin silver spatula.

Gentle irrigation of the wound and the conjunctival sac with a normal saline solution, not intraocular.

Bandage fixed with collodion about the orbit.

Ring mask attached by means of gauze to temples and forehead with collodion.

First redressing ninety-six hours after the operation unless it should be demanded earlier by unfavorable symptoms.

Use of eye in near work only after all inflammatory indications have entirely disappeared.

DISCUSSION ON THE PAPERS OF DRS. STANDISH, SATTLER, TIMBERMAN AND EWING.

DR. MYLES STANDISH, Boston: I do not want to discuss my own paper, but I should like to say a few words in connection with the general subject of the extraction of the lens in capsule *à la* Smith. I have always been interested in this method of extraction. I have done a number of operations by this method, though not a large number, and I have done them in the class of cases that I understand now Dr. Smith says are the easiest ones. That is, I have done it in those cases in which there was a central opacity in a lens, which remained nearly stationary for an indefinite length of time. These are cases that are troublesome both to the operator and to the patient, and that, with our previous methods, we always approached with some trepidation. I have operated, for seven or eight years at least, every such case that has come into my hands, both in private practice and in the hospital, by what I supposed to be Smith's operation. It is true that my early ones were not operated upon so nearly

in Smith's method as I had supposed. In the last year or two, however, I believe that I have approximated his method. So far, I have had no accident, and have obtained most excellent results. I have never gotten my courage up to operating on all cases of senile cataract by that method, and since the reading of Dr. Sattler's paper, which we have heard here, I am glad that I was wise enough to go carefully in selecting the class of cases upon which I should operate by this method. I am sure that the method has come to stay, and that eventually it will be the operation of preference in certain cases. That being so, I am always sorry when I hear eminent colleagues turn the question down and say that they are not interested in it. I am sure that if they had seen the operation properly performed in properly selected cases, they would be interested; and I speak now only to say that I hope that the gentlemen present will not allow their prejudices to prevent their perfecting themselves in this operation, when they have satisfied themselves in what variety of cases it should be performed.

times,
amazing
days pr
time, a
patient
his eyes
Anotl
sized is
not ase
ments,
thoroug
cocain i
waits ei
He puts
no more
the iris
another
outside;
has larg
judge, h
cate tou
that it h

Dr.
iridecto
required
with the
to cut t
formed
the iris
an assis

Dr. A
remark
tions: I
ever hac
Smith's
what wi
continue
For inst
using th
during t

be compared to it or that is safer to the eye. If you have a fractious patient, with more or less vitreous humor presenting and the lens free, you cannot pull the eye down, but must let it alone, when using the old method. By the use of Dr. Smith's spoon, however, dropping it back into the vitreous and making an inclined plane, it is possible to slide the lens out of the ocular cavity.

There are one or two other things that I should like to mention regarding Dr. Smith's work. Dr. Wilson has visited Smith's clinic, and has borne out what I shall say. The majority of his operations are done with a one-cent stogie in his mouth. I have seen the ashes so thick that you would think that they would drop directly into the patient's eye. I was there a week before I saw a towel used upon a patient. He had two or three towels in the laboratory, which we all used promiscuously all morning. But the last thing that he does before operating is to douche the eyes of the patients thoroughly, not with a 1 : 10,000, but with a 1 : 2000, bichlorid solution; likewise the hands. After the speculum is inserted, he pulls up on the speculum, which exposes the cul-de-sac, and a half-inch stream of the solution is permitted to flow into the eye from an elevation of three to four feet, so that every particle of detritus is washed out of the sac. "Rivers of bichlorid" is a phrase that pretty accurately describes the method that he employs. It is remarkable. So far as I was able to determine, nothing ever happened from this free use of bichlorid in his clinic. These patients may be more tolerant to irritants, dirt, and dust, but I cannot see that this is the explanation of the results obtained. I know what a strong antipathy there is in this country to the use of bichlorid of mercury, but I have gone back to the use of it in my own practice after seeing it employed by Dr. Smith. If you visit his clinic, he will give you "the glad hand." He is the apostle of the new method, and is anxious to teach the profession the new creed, in which he thoroughly believes; and I am sure that you will be most happy in making even a short visit. You may not get to do any operating, for he takes only two men each season and lets them do the work; but you will see sights.

DR. GRUENING: Can you give any information with regard to the results of operation?

DR. TIMBERMAN: It is difficult to give you a correct idea regarding the results in these cases. When I went into Dr. Smith's clinic, there were about three hundred and fifty cases in the hospital, mostly cataract cases. One had to step over the patients in going from one ward to another. They were lying on the floor, one patient between each two beds; and on the verandas on both sides of the house there were beds. Dr. Smith is placed under many disadvantages. It is a question of getting through the greatest amount of work with the least amount of fuss and time. He has been criticized because of the lack of a definite and critical report on his work. One morning, in a bunch of seventy-five patients seen for the first time, he admitted sixty to his operating-room, which is not a very large one. In one corner of it he set them all on the floor, where they remained quietly until their turn came to be operated on. Of these sixty, we operated on forty-one. I did thirty-one of these operations, and he did ten. He had never seen a single one of these patients before. They had not had one particle of preparation. They were put on the table, their cheeks wiped with carbolic solution, their eyes douched with bichlorid, and their eyes operated on. The patients are not seen by Smith subsequently unless a report is made to him by the nurse or the attendants that something has gone wrong. With this amount of material on hand, it is impossible for him to do what we do with our private patients. He cannot examine them with the ophthalmoscope or prescribe glasses for them. He lets them go home on the tenth day, unless there is prolapse, iritis, or something else wrong with their eyes.

Now, what proportion of these cases show complications it would be impossible to say; but the vast majority look good. I do not know whether Dr. Wilson had an opportunity to go through the wards or not; but a good many of us came home with impressions that it would be impossible to get elsewhere.

I wish to emphasize what Dr. Standish has said regarding the question of meeting this thing with an open mind and the willingness to know the truth. When we have that attitude toward the proposition, we shall be better off.

DR. G. O. RING, Philadelphia: It would be interesting to have Dr. Timberman tell us in how many cases he has

seen the final results of his operative work at

DR. B. ALEX. RANDALL, Philadelphia: I have always used the double-fixation forceps for the last twenty-five years.

DR. A. E. EWING, St. Louis: A central snip is made which opens the capsule over its center. This is followed by two other snips, one to either side of the first, which divide the capsule laterally. In order to be more certain of securing the abscised portion of the capsule with the scissors as they are withdrawn, the first movement had best be repeated. By snipping away the capsule with the scissors over the pupillary area this portion of the capsule is entirely gotten rid of, and its entire removal in this manner will probably mean a reduction in the percentage of secondary cataract.

In my first cataract operation I opened the eye on the second day, with the final result of a closed pupil, which I had to correct by iridotomy. Since then I have let the eyes alone for four full days, unless there were urgent reasons for doing otherwise, and I have never had a repetition of the closed pupil.

THE MECHANICS OF CHOKED DISC.

MYLES STANDISH, M.D.,
Boston, Mass.

The discussion concerning the cause of choked disc has extended over many years without reaching a definite conclusion. Even the question as to whether all cases of choked disc are produced in the same manner is still *sub judice*.

It is unnecessary before this Society to enter into any extended discussion of the various theories. The principal theories which have had earnest advocates are that choked disc is due:

1. To pressure from fluids in the sheath of the optic nerve.
2. Toxemias.
3. Intracranial pressure due to fluids or growths.



ances indicated a retardation of the venous outflow. An operation was done under ether by Dr. George L. Tobey, Jr. Small cells of the mastoid were found filled with granulations, and the sinus exposed from bulb to upper limits within the mastoid about 2 inches. The emissary veins were also exposed. The lateral sinus was covered with a thin white exudate. The incised wall was very thick. A parietal thrombus was demonstrated. Hemorrhage followed the incision of the sinus, which was subsequently packed with iodoform gauze, and the left internal jugular vein ligated. Following the operation there was considerable rise of temperature and pulse, and the patient, although very ill over several weeks, subsequently entirely recovered.

Ophthalmoscopic examination three days after the operation showed the edge of the disc entirely blurred and all the veins markedly tortuous. In the other eye there was some tortuosity of the larger veins, and the appearance of the smaller twigs was identical with the condition seen in the left eye at the first examination.

On the 7th of April another ophthalmoscopic examination showed in the left eye the edge of the disc still blurred on the nasal side, and the principal veins and twigs less tortuous, although still much convoluted. In the right eye the veins were much straighter, and the edge of the disc was everywhere sharp.

In another ophthalmic examination, on May 16th, there was hyperemia of the disc in each eye. In the left eye the veins were rather tortuous, although they might be considered within physiologic limits. In the right eye the veins were apparently normal.

June 10th the boy was up and about, going out, and ophthalmoscopic examination revealed an absolutely normal fundus in each eye. Vision was $\frac{20}{30} + 4$ or 5, without correction of a refraction.

The boy was too ill throughout the whole period in which

the ophthalmoscopic appearance was present to permit formal fields to be taken, but a rough estimate was made on one occasion, in which the only definite fact established was that the field for red was larger than the field for blue.

It will be seen that the first examination of the fundus of the left eye presented the initial appearances of a choked disc. That after the plugging of the lateral sinus and the tying of the jugular vein a well-marked, though not excessive, condition of a choked disc supervened, and the early appearances of a choked disc appeared in the second eye.

From the condition found at operation it would appear to be fair to assume that the retardation of the venous outflow through the diminution of the caliber of the lateral sinus was the direct cause of the tortuosity of the retinal veins as observed by the ophthalmoscope, although the permeability of the sinus was not to any very great extent diminished by the parietal thrombosis. When, however, the outlet for the venous flow was entirely obstructed, the typical appearances of choked disc supervened within three days, and apparently these conditions stood in relation to one another as cause and effect.

When a large amount of blood is thrown into new channels, a certain amount of time is necessary to reëstablish normal flow, and during this period it is interesting to note that not only was typical choked disc produced in the eye on the side of the operation, but the retardation of the outflow from the cranial cavity expressed itself in the tortuosity of the retinal veins in the other eye. This case seems singularly adapted to substantiate von Graefe's theory that an obstruction to the outflow of the venous blood may be the ultimate cause in the production of choked disc.

T

N
se

A
ex

to
cl
co
p
ti
5
sl
sl

to
L
n
su
co
ex

sy

on the head by a baseball. There were no lo
toms. Slight labyrinthine irritability; othe
sinuses negative. Wassermann negative.
115 mm. V. = O. D. $\frac{6}{9}$; O. S. $\frac{6}{12}$. The edema
in the right nerve, which showed a swelling of
5 D. Tension, O. D. 15 mm.; O. S. 19 mm.
ture showed increased pressure. Field showe
traction of form fields, with interlacing of the

CASE 4.—Male, aged sixty years. History

TABLE

No.	Amount of Swelling	Tension	Lumbar Puncture	Remarks
1.....	O. D. 5 D.	18	Increased	....
	O. S. 5 D.	17	....	....
2.....	O. D. 2 D.	19	Increased	....
	O. S. 2 D.	17	....	....
3.....	O. D. 6 D.	15	Increased	Swelling appeared first in right eye.
	O. S. 5 D.	19	....	
4.....	O. D. N.	25	Not taken	....
	O. S. 2 D.	15	....	....
5.....	O. D. 5 D.	25	Increased	Swelling appeared first in left eye.
	O. S. 5 D.	12	....	
6.....	O. D. 4 D.	21	Increased	....
	O. S. 3 D.	16	....	....

In Cases 1 and 2 swelling in the nerve in each case was the same in both eyes, it being 5 D. in the first and 2 D. in the second. The tension in both eyes, in each case, was approximately the same; in the first, 18 and 17 mm., and in the second, 19 and 17 mm.

In Cases 3 and 4 the swelling in the nerve is of a different amount in each case. In each instance the nerve in the eye showing the least amount of tension is swollen most.

In Case 5 the discs are each swollen 5 D., while the tension of the two eyes shows a difference of 13 mm. The swelling, however, appeared first in the left eye, which had the least tension, and in which, at the time of examination, there was a beginning atrophic process, while in the right eye the process was still active.

In Case 6 the swelling of the right nerve was 4 D., and in the left 3 D., while the tension was 5 mm. less in the eye the nerve of which showed the most swelling. This case was the only exception to the rule that the swelling is most in the eye that shows the least tension. As this patient was under observation but a short time, it was impossible to ascertain in which eye the swelling first appeared, the ophthalmoscopic examination showing no marked difference in the appearance of the two nerves.

The use of the tonometer has demonstrated: first, our inability to determine accurately the tension of the globe by the use of the fingers; and, secondly, that there is a marked variation in the normal tension, the exact amount being still undetermined. This variation is not only present in different individuals, but may exist in the same individual.

If for any reason whatsoever the intracranial pressure is increased, the fluids in the craniospinal cavities and canals will follow the hydrostatic law and exert pressure equally in all directions. Such increased pressure will manifest itself first at the point of least resistance, consequently when the intracranial pressure overcomes the resistance at the papilla, edema will appear. One element in the resistance offered at the papilla is the tension of the globe as shown by the

never seen in the literature any reference to
producing rise in tension, I thought it possible
use of the Schiötz tonometer such a condit
demonstrated. While I realize that certain ot
that their fingers are as skilful as this instrumer

tend to a rigid system, and if severe enough or prolonged over a sufficient length of time, it ought to produce a rise in the tension in Schlemm's canal, through the increase of tension in the posterior uveal system being taken up by the anterior uveal system and eventually by this channel. This is the explanation given by Henderson for the production of a rise in intraocular tension in cases of intraocular growth, although in illustrating this he refers to a growth of the choroid which directly involves a different vascular system from that implicated in cases of choked disc. Nevertheless, it seems to me that if this holds true in reference to a growth in the choroid, it ought to hold true in case of a growth of the retina, and here also we might expect a rise in tension if Schlemm's canal be influenced, for, according to Henderson, the intraocular pressure will remain normal no matter how large the growth may be if this canal remains uninfluenced. Unfortunately, in the past few months there has been a dearth of available cases to carry out studies with the Schiötz tonometer. I can report on but one case in which an unsatisfactory estimation was made, and here only on the left eye, inasmuch as the patient would invariably shrink whenever the instrument approached the right eye. For reasons not necessary to mention, the examination could not be made prior to the operation, but was made after a secondary rise of intracranial tension, following a decompression for an extensive infiltrating growth of the right side of the brain. Tension was estimated on two different occasions, and the lowest was 30. I submit the fields of this case because they illustrate a marked widening of the color fields after decompression, the hemianopsia being probably due to an involvement of the internal capsule. I may add that in this case everything was ipso-lateral to the growth—the vision, the height of the disc, the late development of hemorrhages in the left eye, and the fields.

DR. B. ALEX. RANDALL, Philadelphia: In any mechanical theory, which seems to me very plausible in both these papers, we must be cautious, I think, as to our reasoning, and not mix matters of hydrostatics with what are often matters of hydraulics. Those who see many cases of obstruction of the large venous channels of the head know how

exceedingly variable are the signs of intracranial involvement, and that the choked disc and other symptoms cannot be counted upon as positive or negative evidence in any considerable proportion of the cases after one examination, or even a considerable series of examinations. Also that the pressure symptoms present may be quite local, and that the law of hydrostatics may not apply. The rule probably is that it does, but we must expect exceptions. I think that we must bear in mind, regarding these studies, not only the tonometric pressure of the eyeball itself, but also the exceedingly interesting question of pressure within the lumbar spinal canal; but the question of the general arterial and venous pressure, as shown by instruments, is frequently surpassed in value by that exceedingly simple test, without apparatus, of the relation of the pulse to temperature and respiration. The common rule, I think, in these cases of intracranial pressure, is that the pulse is slow relatively to the other symptoms of the case; and it is a ready and frequently valuable test, when we have not the opportunity to make these more exact measurements. In all such cases we can note the degree of rapidity of the pulse, and learn much from it. We must accept many of the readings of would-be exact measurements with a great deal of reserve, whether it be that of the blood-vessel pressure, which is frequently unequally decided in the two eyes, and is dependent a good deal on the attitude of the patient, or something else. Taken alternately, first in one eye and then in the other, the blood-pressure will frequently give different results, which might not be found if the pressure in both eyes were taken simultaneously. I am sure, however, as to spinal pressure, that this must be largely dependent on hydraulic questions of the freedom of the channels of communication; and that we may have no recognizable pressure in the lumbar spine, when there is high pressure in the cranial cavity. I do not want to say too much regarding offhand and rule-of-thumb measurements, but I believe that many tests of the tension in the spinal column by means of lumbar pressure are fallacious. If we count the speed of the fall of drops from the cannula, we shall get a truer measurement of the pressure in the spinal column than by any tonometer yet devised. I think that very often, in the use of elaborate apparatus, we lose sight of the patient.

it may be a question whether the collateral circulation would care for it or not.

Regarding Dr. Risley's point, it seems to me that the terms neuroretinitis, etc., are entirely artificial. We have drawn attention to this continuous process; and, by definition, have placed the process in the first stage under one title, and in the second stage, under another. If the term neuroretinitis means inflammation, it does not apply to this case. My opinion is that the term choked disc applies to a mechanical process purely, and that the various stages are not entitled to a separate definition and entity. In that sense of the word, I reported the case as one of choked disc.

DR. WALTER R. PARKER, Detroit: Regarding Dr. Risley's question about the variation in the intraocular tension of normal eyes, I would say that I think Mr. Marple's conclusions have practically been confirmed by all who have used the tonometer. The tension of normal eyes will vary from 15 to 25 mm., the average being about 19 mm. In my own cases the average was 18.4 mm.

Dr. Brown, I think, has in mind the determination of the absolute tension of the eyeball rather than the relative tension which I have considered in my paper. If the tonometer is always used in the same manner, the error, if there be one, will remain constant and the results obtained will be comparable. It matters not whether the decreased tension be due to a uveitis or is a normal variation, so long as there is a difference in the tension of the two eyes when the increased intracranial pressure occurs, when, if my conclusion can be proved to be true, the choked disc will appear first in the eye showing the least tension.

Cases of choked disc occur so infrequently it will take the combined results of a large number of observers to establish the truth or falsity of my conclusions, which are based solely on the six cases I have reported.

these discoveries to further research for other specific infections, it must be admitted that in the vast majority of patients suffering from cardiovascular disease with ocular affections as a part of the general malady, neither syphilis, tuberculosis, nor other known specific infections or intoxicating agent has been demonstrated. Gout and rheumatism, whatever these may be proved to be, are unquestionably regarded as the most commonly present, as an etiologic factor. The association of the gouty or rheumatic diathesis and other allied states of general ill health with faulty digestion and assimilation of foods has for many years claimed the attention of physicians. Experience in the treatment of disease had taught our immediate predecessors and the generation from which they sprang the importance of freeing the alimentary canal of noxious accumulations. Hence their first step in the treatment of practically all forms of disease was the administration of purgatives, which were the sheet-anchors by which they sought to have their patients weather the storm. Laboratory study has given to us in some measure the scientific explanation for the therapeutic experience of former generations. Careful study by many observers has made it reasonably certain that many unclassified forms of ill health are due to the fact, so tersely stated by Metchnikoff, that "the accumulation of waste matter retained in the large intestines, for considerable periods, becomes a nidus for microbes which produce fermentations and putrefaction harmful to the organism. Although our knowledge of the subject is far from complete, it is certain that the intestinal flora contain some microbes which damage health, either by multiplying in the organism or by poisoning it by their secretions." A former generation of doctors swept the house: the modern doctor seeks to disinfect.

While the products of the intestinal flora are toxic and are the cause of some of the so-called autointoxications of

air-passages, the ears, and the sinuses in the anterior segment of the skull are involved; certain forms of iritis and muscular rheumatism may be cited as examples. Such a condition may be produced by sudden chilling of the surface of the body, the abnormally reduced temperature having arrested the physiologic chemico-vital changes in the fluids and tissues which are necessary to normal metabolism and health. In their stead the blood- and lymph-streams are loaded with faulty end-products which cause more or less serious impairment of health. It is equally true that a more or less nearly similar chain of events may be produced by the ingestion of improper foods for the individual, or proper food taken in too great abundance or taken under unsuitable conditions, so that the digestive act is incomplete and the organism is gorged with material not suited for the normal purposes of nutrition. The so-called uric-acid diathesis, and the resultant disease of the heart and the general vascular tree, with the multitudinous local manifestations, as in nephritis, ocular disease, affections of the ears, gout, and rheumatism, are doubtless the result of repeated occurrences of the conditions caused by their chronic persistence.

In addition to these commonly recognized etiologic factors, clinical study suggests that not only does cardiovascular disease result from the uric-acid diathesis, but that in a considerable group of patients it may be caused either by specific infection, microbic in origin, entering the blood- and lymph-streams from the large intestines, or by the absorption of the noxious products of an abundant intestinal flora in persons of a constipated habit.

Reasoning *a priori*, we are led to anticipate that the blood-vessels, the lymphoid and highly vascular structures of the body, would be the first to manifest the presence of a poison or of infecting agents in the blood or lymph-stream. Clinical observation confirms such reasoning. In a common cold and in many infections, as in measles, for

small with gray borders. None of the palpable arteries were atheromatous, but she had what her physician pronounced "an anemic heart murmur." The pulse was soft, with occasional intermission. She had constant abdominal pain with tenderness to palpation.

She had for years been constipated, but for the last month this had been interrupted by attacks of diarrhea. Palpation of the abdomen revealed an enormous impacted colon. After many days, with the administration of castor oil, high enemas, and mechanical aid, the colon was finally emptied of the most surprising quantity of offensive, hard, dark masses of contents, the retained accumulation of, possibly, months, probably adherent to the walls of the colon or detained in sacculated distentions of the gut. Under subsequent treatment, by abdominal massage, a discriminating diet, and medication, her general health was restored. I saw her again several years later. She was then apparently in perfect general health, but ophthalmoscopically the atrophy of both optic nerves seemed complete. She had retained only sufficient vision to go about in familiar surroundings without aid. There was nothing in her own or her family history other than the impacted colon and long history of constipation to explain her ocular disease, which was doubtless a toxic neuroretinitis.

Case 2.—While this paper was in the course of preparation, Mrs. B., aged sixty-eight, the wife of a country physician, came because of rapidly failing vision. She suffered very little pain, but had spells of general weakness and vertigo. O. D., V = $\frac{6}{30}$, with eccentric fixation; O. S., no letters on the chart at any distance. She was unable to count fingers, but recognized movement of the hand, eccentrically placed, the center of the field being apparently completely blind. The field in the right eye was concentrically contracted, and there was a small absolute central scotoma.

The ophthalmoscopic picture was that of a neuroretinitis rapidly advancing to atrophy on the left side. In O. D. the veins were full, dark, and tortuous to the limit of the ophthalmoscopic field, but the lower temporal vein was much larger than the others. The arteries were apparently normal in size, without gray borders. All details were slightly veiled.

The papilla was not swollen, but was gray-red, opaque, and the margins obscured. The same changes were present in the left eye, but at a more advanced stage. There were no hemorrhages in either eye and no evidence of their earlier presence.

The blood-pressure was 172 systolic and 145 diastolic. She was sent to Dr. David Riesman for study, who confirmed my record of blood-pressure and reported his findings as follows: "The urine is free from albumin and sugar, has a sp. gr. of 1026, and is moderately acid. There is a congested hemorrhoidal polyp. She has been suffering from chronic constipation, interrupted by attacks of diarrhea. This diarrhea seemed to be accompanied by absorption of toxic material. The diagnosis might be written as follows: Hypertrophy and dilatation of the heart, hypertension, chronic constipation, autointoxication, hemorrhoids. Regarding treatment, it seems to me that attention to the bowels is of the greatest importance."

The most careful study could elicit no other plausible origin for her neuroretinitis than that of an autointoxication.

CASE 3.—C. S., aged fifty-one, came June 1, 1911, complaining of impaired vision, attacks of general faintness, with tachycardia, vertigo, extreme nervousness, and hallucinations. He had a quite constant headache, with a sense of painful pressure at the vertex. He said that for many years he had been a dyspeptic, with recurrence of intestinal trouble and flatulence. He had found it necessary to always be taking digestive tablets, had always been constipated, and had acquired the cathartic habit, finding the greatest relief from calomel and soda followed by salines. He was a large man, with an average weight of 176 pounds. In his youth he had acquired gonorrhea, but there was no evidence of syphilitic infection; that is to say, he had never had recognized secondaries, but, owing to the inquiry and study of various physicians, was in constant dread of the disease. His wife had always been in good health. They had a son twenty-seven years of age, a stalwart, healthy man. There had been no miscarriages. He said he had never tasted whisky in his life, but occasionally took a glass of beer, but for many years had smoked to excess, often as many as fifteen or twenty cigars in twenty-four hours, but had

stopped his cigars two years ago. He had always eaten large quantities of food, habitually taking, for breakfast, oatmeal with cream and sugar, three boiled eggs, fried potatoes, and two or three cups of coffee.

O. D., V = $\frac{6}{40}$, with eccentric fixation; O. S., V = $\frac{6}{20}$, slowly, slightly eccentric fixation. There was an absolute paracentral scotoma in the right eye and a relative scotoma in the left. There was also some concentric contraction of fields for form in both eyes, which appeared to be due rather to a partial failure or uncertainty of perception in the peripheral field. He had a pulse-rate of 80 to the minute, which on the slightest exertion would rise to 90 or higher.

His blood-pressure was 200 mm. in systole. In August, 1906, he had discovered a blur before his right eye on awakening in the morning, which his physician told him was due to a hemorrhage in the eye, and administered large doses of potassium iodid and protiodid of mercury, but without notable relief.

In January of the present year a blur came before the left eye, which he was again told was due to a hemorrhage, and was once more placed upon ascending doses of iodid of potassium with protiodid of mercury, which he took steadily until the first of April, during which time he lost 20 pounds in weight and the symptoms of which he complained on June 1st came on; that is to say, his general nervousness, headache with pressure at the vertex, vertigo, and tachycardia, with increase of his syphilophobia. He then abandoned both his medicine and his physician until June 1st, so that he had been without treatment from April 1st to June 1st.

The ophthalmoscope on June 1st revealed, in the right eye, a large area of retinochoroiditis with extensive absorption patches in the macular region. The details were obscured by fine, web-like opacities of the vitreous. The entire fundus was dark red and fluffy. No swelling of the papilla could be made out, but the margins faded insensibly into the surrounding eyeground. The arteries appeared of normal size, but the veins were large, dark, and wavy to the limit of the ophthalmoscopic field. There were no hemorrhages. In the left eye the same general conditions were present, but the changes at the macula consisted of a maroon-colored, woolly area and a granular nest at the fovea. The

vitreous was transparent, but a faint haze in the retina slightly veiled every detail. His urine was free from sugar, but there was a trace of albumin, a decided amount of indican with hyaline and granular casts,—the latter 5 or more in every minim voided,—and a specific gravity of 1.016.

He was sent to Dr. R. G. Curtin for examination, who reported no irregularity of the heart or murmur, notwithstanding the fact that he was seen during one of his "queer spells," which occurred while under physical examination in Dr. Curtin's office. Dr. Curtin suggested that his circulatory symptoms were probably those of Grave's disease, which suggestion was rendered plausible by the fact that a sister was afflicted with that disease in a mild form.

The man was placed on skimmed milk and stale bread diet exclusively, and was directed to take a sufficient dose of sulphate of magnesia daily to secure free purgation, and 5 grains of chlorid of calcium, four times daily. In a week he reported feeling much better. He was then allowed a more generous diet, and received $\frac{1}{100}$ gr. of bichlorid of mercury after each meal, with a nux vomica tonic, and was sent to the seashore. On July 7th he reported that he no longer suffered from headache or pressure, that his "queer spells" had disappeared. There was no vertigo and there were no hallucinations. Blood-pressure, 145 mm. O.D. V = $\frac{6}{12.5}$ and O. S. V = $\frac{6}{7.5}$. There can be but little doubt that both his general condition and the ocular disease were produced by his intestinal toxemia. It is interesting at least to inquire how far his excessive use of tobacco set up his intestinal state primarily.

To this group of cases might be added a considerable number of patients affected with diseases of the uveal tract; as, for example, recurrent iritis, the so-called cases of serous iritis with turbid aqueous and vitreous opacities and deposits upon the membrane of Descemet, which are often a more advanced stage of milder but equally persistent affections of the fundus, characterized by a flannel-red, fluffy eye-ground, with undue sensibility to light, rebellious asthenopia, lowered acuity of vision, uncertain fields, impaired light sense, and general ill health. The same may be said of

another important group usually occurring after middle life in patients with retinochoroidal disease, characterized by edema of the retina, tortuous and full veins, high vascular tension, headache, impaired vision, contracted fields, acid urine of high specific gravity, with or without traces of albumin; with or without demonstrable arteriosclerosis, but which, if neglected, unquestionably result in permanent cardiovascular disease.

It is not my intention to rehearse the extensive literature which has grown up during the last decade, in which such untiring industry and serious endeavor have been made to fix definitely our knowledge of the autotoxemias and their relationship to disease of the eye and other organs of the body. Our knowledge of this complex subject remains as stated by de Schweinitz in his admirable paper presented to the Ophthalmic Section of the American Medical Association in 1906. Quoting and emphasizing the conclusions of Elschnig and Taylor, he said: "We do not know the entity of a single autointoxication except the acidosis of diabetic coma, and we know that no known autointoxication is to be attributed to any known end-product of any known metabolism, but we do know, from clinical analogy, that autointoxications exist, even if their true nature is as yet a secret."

It has been my intention to show, by illustrative examples of ocular disease, the apparent relationship of cause and

CILIORETINAL AND OTHER ANOMALOUS RETINAL VESSELS.

EDWARD JACKSON, M.D.,
Denver, Colo.

The ophthalmoscopic examination of 500 patients (1000 eyes) presenting consecutively in private practice has yielded the facts herewith presented. The notes and diagrams were made at the time of examination, and the latter usually verified by looking again into the eye.

To determine whether a particular vessel were an artery or a vein, I have relied upon observing whether it crossed venous or arterial branches. Arteries cross veins, and veins cross arteries. But in the retina I have never observed two arteries crossing each other, or two veins crossing each other, except as they may wind over each other at the optic disc before passing to their areas of distribution. Certainly the test is practically reliable in this connection. Some such test is necessary because many of the cilioretinal vessels are so small that we cannot tell by color whether they are arteries or veins.

The vessels are spoken of as small, medium, or large. By large, I mean a vessel of the average size of the superior or inferior nasal branch of the central retinal artery, somewhat smaller than the temporal branches. A medium vessel is one the size of the average primary branch of a superior or inferior nasal or temporal artery. All visible vessels less than this in size have been called small.

Cilioretinal veins are quite rare as compared with ar-

teries. But perhaps systematic search mig
less rare than we have supposed. This serie
cases. In one a vein of medium size seemed t

artery. If these are added, we have 23% of eyes showing cilioretinal arteries. I have, however, confined this term to the 191 eyes in which the choroidal origin seemed unmistakable.

Such branches occur with equal frequency in the two eyes. In 43 patients both eyes presented them. They were in the right eye alone in 53; and in the left eye alone in 52. In regard to size these arterial branches were classed as: large, 43; medium, 54; and small, 94. The small branches are quite as surely recognizable as the large, but are easily overlooked in the ordinary ophthalmoscopic examination. Twelve eyes presented each two cilioretinal arteries of quite

Fig. 3.

Fig. 4.

Fig. 5.

independent origin. Three distinct cilioretinal arteries were seen in each of two eyes. In 6 of these 14 cases the fellow-eye presented one cilioretinal vessel. In 23 eyes the cilioretinal artery divided or gave off one or more visible branches before leaving the disc.

In what is regarded as the typical form of cilioretinal artery the vessel comes into view within the area of the disc, as shown in Fig. 3. It was a matter of surprise, however, to find that the majority of cases could be traced from the extreme disc margin, as in Fig. 4; or could be seen starting in the choroid, sometimes branching from a large choroidal vessel, entirely beyond the margin of the disc, as in Fig. 5. Thus the branch appeared as a hook on the disc in 85 eyes;

but it could be traced from the edge of the disc in 74, and seen to start in the choroid in 32. In three eyes the artery originating in the choroid did not pass onto the disc at all, but turned before reaching the disc margin. Two of these were the right and left eyes of the same patient, the vessels being symmetrically placed. Often the deeper origin of the vessel is seen indistinctly, or is brought out only by using a concave lens, sometimes 5 or 6 D. more concave than the lens required to render the vessel distinct in the retina. Sometimes the deep origin is hidden directly behind the more



Fig. 6. Fig. 7. Fig. 8.

superficial part of the vessel. In the above statistics, however, the origin has been noted as at the disc margin, or beyond it in the choroid, only when this was rendered unmistakable.

After appearing on the disc the vessel may turn so as to pass off nearer the top or bottom of the disc, as in Fig. 3, or near the horizontal diameter, as in Fig. 4. My diagrams show no preponderance of one plan over the other. The former shape shows some resemblance to the distribution of branches of the central retinal artery; the latter is rather a reversal of that form. Often the cilioretinal vessel arises near the horizontal diameter of the disc, and crosses it going either upward or downward before passing off the disc, as in Fig. 5. Sometimes when two cilioretinal branches are present their curves are symmetric with regard to the hori-

zontal diameter, as in Fig. 6; in other cases they are asymmetric, as in Fig. 7.

Any of the above plans of distribution would be in harmony with the view that these cilioretinal arteries are survivals of, or reversions to, the system of retinal arterial supply prevalent in the lower vertebrates, as described by Lindsay Johnson* and E. Nettleship.† But there is one point in their distribution that seems to indicate a different significance. Of these 191 eyes, the vessels in 188 passed from the temporal side of the disc to be distributed toward or to the region of the macula. This preponderance of macular distribution is so great that it cannot be accidental. Whether it means anything beyond provision against certain dangers that attach to a supply through the central retinal artery need not be taken up at present.

A general impression previously obtained, that in normal conditions *visible pulsation* is more frequent in cilioretinal vessels of equal size than in the branches of the central retinal artery, has been confirmed by this statistical study. Thus, in the 1000 eyes only one is noted as showing a pulsation in branches of the central retinal artery; but among the 43 large cilioretinal arteries, 3 showed a visible pulsation. It is desirable that other observers should direct attention to this point, and confirm or correct this impression, the number of cases mentioned being quite inadequate to settle the question and the personal equation large. Arterial pulsation is shown in normal eyes by change in the form of the artery, and not as pulsation is shown in the retinal veins, by visible narrowing or collapse of the vessel. The looped curve of the cilioretinal vessel is often particularly favorable for exhibiting slight changes of form produced by the ar-

*Comparative Anatomy of the Mammalian Eye, Trans. Royal Society, 1901, p. 1.

†Transactions of the Ophthalmological Society of the United Kingdom, vol. xxv, p. 338.

terial pulse-wave. But it seems likely that some additional factor contributes to this difference.

The passage of an artery through a rigid ring tends to diminish the pulsation in the distal portion of the artery, while it increases the excursion of the arterial walls on the proximal side of the obstruction. The relatively prolonged passage of the central retinal artery in the trunk of the optic nerve, although here surrounded by a lymph-channel, may tend to diminish pulsation, as compared with the ciliary arteries passing through the sclera.

two eyes large isolated arteries, placed as shown in Fig. 10 and Fig. 11, were seen. The latter carried fully one-third the total blood-supply of the retina. These vessels, although noted simply as "isolated," probably arose as cilio-retinal arteries.

DISCUSSION.

DR. B. ALEX. RANDALL, Philadelphia: I have always been very much interested in this matter; and, while I have never made the skilful study that Dr. Jackson has, I have records and sketches of several hundreds of these conditions in my portfolio, as well as many previously published. It seems certain that while aberrant veins are far less frequently seen than the arteries, they constitute a larger proportion in my experience than is indicated by Dr. Jackson. The point of vessels never crossing like vessels, vein over vein or artery over artery, while almost invariable, is not always true. I have published one exception to this rule, and here present sketches of several more. It has been so very infrequently mentioned as to make it a very rare anomaly, yet one that ought to be taken into consideration as sometimes occurring.

EXHIBITION OF A BJERRUM STICK.

T. B. HOLLOWAY, M.D.,
Philadelphia.

In submitting this novelty I realize that it is probable that a number of observers have used a stick similar to the one I am about to show. Those ordinarily employed are without a joint, which makes them more inconvenient for transportation. In using the stick the small discs of paper are moistened and stuck to the cross or cylinder on the end of the wire. Most of us have at times had difficulty in satisfactorily charting certain central scotomata with the

ordinary perimeter, and I believe it would have
impossible to accurately chart the scotomata s
meeting by Prof. Fuchs without the aid of Bjerr
In the center of this stick there is a fish-pole jo
the proximal and a concave surface for the t

A DOUBLE COLOBOMA (NASAL AND TEMPORAL) OF THE OPTIC NERVE AND SHEATH: EXHIBITION OF DRAWING.

B. ALEX. RANDALL, M.D.,
Philadelphia.

It has been the habit of the writer for the past thirty years to sketch, and at times to publish, the various anomalous appearances which he has met with in the eye-ground, in the belief that their recognition and discrimination from pathologic lesions are important. Among these have been various less usual forms of coloboma, especially of the optic nerve or its sheath; one note published in these "Transactions" in 1887 citing three or four forms of this condition, or of pseudo-coloboma, that should be considered in connection with it. Few other ophthalmoscopists have recorded the anomaly to which attention is again drawn,—perhaps not regarding it as noteworthy,—where a small marginal depression of the disc, into which vessels can generally be traced, presents a dark, "bottomless" appearance instead of revealing the glistening white of the scleral sheath. This may be seen as a mere coloration, with no surface defect of the nerve-head; yet darker in its greenish color than any atrophic fibers look, unaccompanied by a defect of the visual field, but accompanying other anomalies unquestionably colobomatous. In the instance which is now brought forward the condition is presented at both inner and outer margins, instead of being confined to the lower or external, where its etiology would be more explicable.

Coloboma to the nasal side, of which an instance was

published by Dr. de Schweinitz and the writer,* may require for its elucidation a reversal of that outward rotation of the fetal cleft which is assumed as explaining colobomata to the

Upper illustration: Double coloboma of the optic nerve and sheath. Lower illustration: Coloboma of choroid and of nerve sheath at lower margin.

temporal side; yet it certainly can occur in iris, choroid, or other structures, such as nerve and sheath. The simultaneous appearance of an anomaly which purports to

*Arch. of Ophth., xvii, No. 4, 1888.

have any such meaning at both lateral margins of the nerve-head certainly raises a somewhat new question.

My brief notes of the case are as follows:

Dorothy ——, aged fifteen, was brought because of choreic and other nervous manifestations since her involvement in a trolley crash. Headaches and other discomforts, especially at school, seemed due to near-work, and her eyes were suspected of responsibility. Her mother has H.=1.5 with slight As.; her father the same on the right, with +1.5 cy. left; his brother +1.75, and the paternal grandmother +1.75. Examination showed slightly subnormal vision and accommodation with H.=1.5, with clear media and fair fundus alike in the two eyes, except for the anomaly of the disc in the left. The nerve-head is here large, horizontally oval, with a pigment-bounded absorbing crescent to both outer and inner side. Close to this, at each lateral margin, is a greenish, dark fleck, which study shows to be a deep excavation, overhanging at the border, but shelving inward. The upper nasal vein and artery disappear under the overhang of the depression at the nasal side, but can be followed only about the 2 D. that the other vessels can be followed into the rather sharp-cut physiologic cup which occupies all the center of the disc. No notable vessels emerge from or enter the outer depression. In each there is the characteristic previously noted, that the shelving pit seems *bottomless*, offering no sign of white sclera or lamina cribrosa as limiting its depth.

The choroid, as in the other eye, presents no suggestion of coloboma, and the crescents at the inner and outer nerve-margins differ so little from those in the other eye as to seem probably acquired lesions. The central porus and its vessels offer nothing unusual; but we have here, at each margin of the distorted nerve-head, a depression due to lacking fibers, beneath which the white fibers of the sheath seem alike lacking. The vision is $\frac{6}{6}$, as in the fellow-eye, the accommodation and muscle-balance normal, and the field entire.

The discrimination of these antenatal conditions (doubtless of inflammatory causation) from the choroiditic lesions

of later life is often difficult, and at times in

RETINITIS PIGMENTOSA ASSOCIATED WITH ALBUMINURIC NEURORETINITIS.

T. B. HOLLOWAY, M.D.,
Philadelphia.

Owing to the most interesting and unique fundus picture produced by the coexistence of two affections, either one of which may produce a more or less characteristic ophthalmoscopic picture, the following case-history is reported:

J. A., aged thirty-four, was referred to me by Dr. Isaac Brown, of Philadelphia, on February 16, 1911, and to him I am indebted for the accompanying medical notes:

During infancy the patient had marasmus, and at the age of ten months an abscess developed on the right side of the neck. From two and a half to eight years of age he was subject to attacks of unconsciousness that lasted but a few seconds. He had scarlet fever at the age of six years, followed three years later by measles, during which illness he states he was blind for three days, and he dates his present ocular trouble from this illness. In November, 1910, he had a severe attack of pneumonia. He smokes, but for some time has not used alcohol, although in the past he has done so to excess. He denies syphilis. When first seen by Dr. Brown a few days before my examination he complained of weakness, shortness of breath (asthmatic), and poor vision, which he thought had become worse during the past few months. The skin was dry and sallow, the conjunctivæ pale, and the temporal arteries distinctly tortuous and prominent. Examination of the lungs revealed signs indicative of an asthmatic condition. There were a distinct precordial pulsation and a marked accentuation of the aortic second sound. The result of the examination of the urine was as follows: Sp. gr. 1006, distinct amount of albumin, but no sugar; numerous granular and hyaline casts, epithelial

cells, no crystals. The total amount passed in the twenty-four hours was 80 ounces. The blood showed 70% of hemoglobin, 3,830,000 red cells, and 13,120 white cells. The systolic blood-pressure was 225.

His chief ocular complaint was his inability to read. During his illness in October, 1910, he had been told that he had

Fig. 1.—Retinitis pigmentosa associated with albuminuric neuroretinitis.

had a hemorrhage in each eye. There was no dizziness or vertigo, but there existed a more or less constant buzzing in the ears. While he did not recall ever having had a discharge from either ear, he stated that the hearing of the left ear has been defective for years.

An ocular examination revealed the following interesting condition: The pupils were equal, and reacted to direct and indirect light, accommodation, and convergence; the extra-ocular muscles were intact.

Right eye: In the lens could be noted a small posterior linear opacity with several dots up and out. The vitreous was slightly hazy and contained a number of string-like opacities. The disc was vertically oval, the margins hazy but not distinctly blurred; the color was a dirty gray and there was no physiologic cup. Both sets of vessels were much reduced in caliber, the arteries being accompanied by white lines that extended along some of the branches for one to two disc diameters from the disc. The superior nasal branch could be traced only as a white line on the papilla, while the inferior temporal branch became invisible at two points just beyond the disc. Over the posterior pole of the eye there was a slightly grayish haze, while directly in the macular region there was a series of exudates arranged in the form of a typical stellate figure. There were no other exudates and no associated hemorrhages. Beginning just beyond the macula there was a heavy reticulated retinal pigmentation of typical bone-corpuscle type. Over the pigmented area there was a distinct absorption of the retinal pigment, but no sclerosis of the choroidal vessels could be noted ophthalmoscopically. The vision was $\frac{5}{40}$.

Left eye: The lens showed a posterior cortical opacity with several striæ extending upward. The disc was vertically oval, with distinct blurring and slight striation of the temporal margin. The temporal half was distinctly pinkish in color; there was no physiologic cup. In other respects the intraocular changes were similar to those found in the right eye, except that the stellate figure was not as complete, being partially deficient down and out, while down and in from the macular region several small isolated exudates could be noted. The vision equaled $\frac{5}{30}$.

Owing to the day being dark and cloudy, the fields were taken under electric illumination. There was a concentric contraction of the form fields to about 15 degrees, with some flattening below and to the nasal side in the right field, and below and to the temporal side in the left field. In each field a small central scotoma could be determined with

a 5- and 10-mm. square, while no color could with a 2-mm. square.

With these details at hand the following f

minous literature on this subject, and in recent years by the elaborate studies of Nettleship, Shoemaker, Herrlinger, and others, several points in the above case-history may be referred to:

Embolism of the right central artery.

CONGENITAL DEVIATIONS OF THE EYES.

ALEXANDER DUANE, M.D.,
New York.

General Characters.

In considering congenital motor anomalies of the eyes, the term congenital deviation is preferred to either congenital squint or congenital paralysis. For in many such deviations, particularly when of the slighter sort, there is no actual squint, at least in the ordinary directions of the gaze; and in many also there is probably no paralysis in the usual sense of the term,—*i. e.*, there is no impairment of nerve-power,—but simply a restriction of movement due to faults of insertion or structure in the muscles themselves.

Congenital deviations have not been regarded as very common. I think they will be found to be common if account is taken of the slight deviations, discoverable only on careful examination. Such slight deviations are of particular importance, first, because they may give rise to troublesome symptoms; second, because, as stated below, they may become the starting-point of a progressively increasing squint. Indeed, I am persuaded that many of the squints, particularly divergent squints, that develop at a very early age have their origin in a congenital vertical deviation, and most often in a congenital insufficiency of the superior rectus. To this point I will return later.

It is often hard to say whether a given deviation is congenital or not. In a marked squint the statement of the parents that it has dated from infancy is a fair but not conclusive evidence of a congenital origin. To be sure, we must exclude faulty observation and the presence of possible

2. The absence of secondary deviation. My own experience, however, is that in many cases, at least, secondary deviation develops as promptly and as fully in congenital as in acquired paralysis. Indeed, it is precisely by such a secondary deviation that some of the characteristic clinical features of congenital paralysis are produced.

3. Absence of secondary contracture of the opponents. This is a very important point of distinction, but we cannot agree that it is absolutely reliable. I believe that the most we can say is that in congenital cases secondary contracture is uncommon, while in acquired cases it is rarely absent.

4. Absence of involvement of the pupil and the accommodation. The interior muscles are rarely affected in congenital cases. I can recall but one case, and that not certainly congenital, of ophthalmoplegia interior.

5. The stationary character of the deviation. This is a valuable sign. When repeated examinations, made years apart, show a deviation essentially the same in amount and kind, we may feel pretty sure that it is congenital. This constancy is doubtless due, first, to the absence of secondary contracture; second, to the fact that the conditions causing the motor defect consist of factors which do not alter—consist, that is, of structural and insertional anomalies of the muscles. While, however, congenital deviations usually remain stationary, this is by no means always the case; and even when stationary themselves, they are often the cause of progressive acquired squint, so that they have an apparently variable character.

6. Other signs are given by Kunn which are helpful, but which either do not occur often enough to be absolutely distinctive, or which at times occur in acquired paralysis as well. They are the retention of convergence when the ability to make lateral movements is abolished, the presence of nystagmus, the presence of facial paralysis or other abnormalities of the facial muscles, and the presence of other

congenital defects in the eyes or elsewhere. As Kunn remarks, congenital deviations are not especially apt to be associated with defective vision or anomalies of the fundus.

Kunn's distinctive signs often fail us, particularly when the deviation is slight, and we are then dependent on the history or on some signs other than those he has given.

In the series of cases on which this paper is based I have included those in which—

(*a*) I personally observed the deviation early in life or in which there was reliable evidence that it was noticed very soon after birth.

(*b*) There was evidence that head-tilting or shutting of one eye in order to see better had existed since earliest infancy.

(*c*) The case fell into one of those categories which we know to be distinctly congenital (*e. g.*, Group I (*a*) or Group VIII below).

(*d*) The conditions remained constant for a number of years together.

(*e*) There was a characteristic diplopia which could readily be elicited by the tests, but of which the patient was either totally unaware or which, at least, had never been obtrusive or annoying. (This is not a sure sign, being also found in cases of comitant squint, especially in children.)

(*f*) There was a lateral deviation which had evidently developed very early in life, and neither had the customary causal factors nor followed the usual course of an ordinary comitant squint, and which, as a rule, was associated with a vertical deviation.

Diagnosis.

In diagnosticating the deviation present I have used all the ordinary tests, but in the case of young children have relied particularly upon—

(*a*) The screen test for distance and near, with the eyes in the primary position.

(*b*) The screen test with the object at 10 inches, to determine the kind and amount of deviation in the six cardinal directions of the gaze (right, left, up and right, up and left, down and right, down and left).

(*c*) The observation of the movements of each eye, both when fixing and when following, in the six cardinal directions of the gaze. In order to effect this, a large card is placed in such a way that one eye can and the other eye cannot see the object of fixation when carried in the given directions, and yet the physician can observe how the non-seeing follows the seeing eye in its movements. The test being made first with the left eye covered, and the behavior of both eyes in all the six cardinal directions of the gaze being noted, the card is shifted so as to cover the right eye, and a similar observation is thus taken. The record of such an observation might read as follows:

Eyes Directed.	R. Fixing.	L. Fixing.
Up and right	R. up imperfectly; L. flies far up.	R. drops; L. rises normally.
Up and left	R. normal; L. normal.	R. normal; L. normal.
Right	R. out well; L. in and shoots up.	R. drops somewhat; L. normal.
Left	R. normal; L. rises somewhat.	R. goes lower; L. out normal.
Down and right..	R. normal; L. normal.	R. normal; L. normal.
Down and left ...	R. normal; L. lags up.	R. shoots below; L. down imperfectly.

A finding which would indicate paralysis of the right superior and paresis or insufficiency of the left inferior rectus.

(*d*) Diplopia in the six cardinal directions of the gaze plotted on the tangent plane.

(*e*) The field of monocular fixation taken with the perimeter or tropometer. Repeated experience has led me to regard this as not only the least valuable of the means of diagnosis, but often as quite misleading.

Varieties Found.

The cases that have come under my observation have fallen into the following groups:

I. *Insufficiency of the Superior Rectus.*—This is common. It comprises the following subvarieties:

(*a*) Insufficiency of the superior rectus; fixation with the paretic eye and secondary deviation (upshoot) of the other. This is quite a characteristic condition. In the primary position there is often no obvious squint, or there may be a spasmodic and often intermittent up-turning of one eye. When the fixing eye moves outward, the other shoots spasmodically up and in (spasmodic action of inferior oblique). This is a very striking feature of these cases, and often is the first thing that calls the parents' attention to the defect. The movement of the fixing eye is found to be restricted upward, and especially up and out; in extreme cases it cannot go up at all when abducted. The head is often tilted to one shoulder, and the patient, especially in a strong light, may shut up one eye and avoids turning the eyes to the side of the paretic eye. In some cases the head-tilting amounts to actual torticollis. I have seen 14* well-marked cases of this condition, uncomplicated by ptosis.

It may be argued that the upshoot of the in-turning eye in these cases is not due to secondary deviation, but to some peculiar insertion of the internus which pulls the eye up as it goes in. That the former is the case, however, is proved (*a*) because if the out-turning eye is screened and the in-turning eye made to fix, the in-turning eye moves inward on a level, while the out-turning eye drops—both behaving just as they do in acquired paralysis of the superior rectus; (*b*) if the eyes are made to converge, the in-turning eye does not rise, which of course it would do if the upshoot were caused by an

*If we include four cases in which both superior recti were affected and there was alternate fixation—cases, that is, in which fixation was always transferred to the out-turning eye, and the in-turning eye always shot up and in.

insertional anomaly of the internal rectus instead of being the result of a secondary deviation due to paresis of the other eye; (*c*) the upshoot, as was shown in one of my cases, can be abolished by an operation done on the other eye; of course, this could not be so if it were due to faulty insertion of the internal rectus; (*d*) in some cases, at least, as the in-turning eye goes up it makes a wheel-rotation (*i. e.*, a movement of extorsion), as it should do if it were being pulled up by the inferior oblique.

Quite a similar picture to this is produced by some cases of acquired, especially traumatic, paralysis.

In four of these cases the vertical deviation was combined with an esotropia; in three with an exotropia, which in one case developed under our very eyes. In the other cases there was little lateral deviation.

In one of the cases the spasm of the inferior oblique producing the sharp upshoot was particularly marked in near vision. That is, the hyperphoria, being little or nothing for distance, suddenly increased to 16 degrees when the object of fixation was brought up to the eyes. In this case probably the tendency to spasmodic action had become so habitual with the inferior oblique that it occurred whenever the non-fixing eye turned in, whether in making an associated parallel movement or in converging.* The same is probably true of another case in which the degree of spasmodic upshoot in one eye was out of all proportion to the very moderate restriction of upward movement in the other.

(*b*) Paralysis of the superior rectus; fixation with non-paretic eye. Of this type of deviation I have seen no less than 32 cases which I regard as congenital. In some of these, however, fixation was at times alternating, so that they then resembled cases of Group I (*a*). It may seem surprising that I have seen so many, as the anomaly is not

* It is possible, too, but on other grounds not likely, that there was an insertional anomaly here.

ordinarily regarded as a common one. It is, however, often overlooked, not only by the parents, but even by the examining ophthalmologist, since the deviation itself is commonly slight, so as not to produce an obvious squint even in upward directions of the gaze, and, of course, the conspicuous secondary deviation (upshoot) of the non-paretic eye, which is so marked in cases of Group I (*a*), is absent. As in the former group, head-tilting and a tendency to shut one eye are frequent.

In six of the cases both superior recti were affected, but in no case equally so. In seven of the cases there was esotropia, in five a permanent exotropia, and in two a transient exotropia (in one case reproducible at will). In one of the cases the esotropia combined with an insufficiency of both superior recti to cause an anotropia.

In three of the cases there was a slight ptosis, but not of a kind to indicate that the levator was involved. See below, Group XII.

(*c*) Insufficiency of superior rectus in one eye and inferior rectus in the other. I have seen 8 cases of this sort. The hyperphoria produced by this condition is more comitant than in Groups (*a*) and (*b*). For example, a combined insufficiency of the right superior and the left inferior rectus will produce a left hyperphoria marked in looking both to the right and to the left. The vertical deviation is often considerable, and is frequently associated with a lateral deviation, evidently secondary. In all but one of my cases there was exotropia. Head-tilting was noted in only one case, but may have been present in others.

II. *Insufficiency of the Inferior Rectus.*—This again is quite common. It comprises two subvarieties:

(*a*) Slight insufficiency of the inferior rectus. In this the deviation is often very slight indeed, being then recognizable only by very careful plotting of the field of double vision at its extreme lower limits. Sometimes the charac-

teristic diplopia occupying one corner of the field (insuperable right hyperphoria in looking down and to the right, or left hyperphoria in looking down and left) is not made out until the eyes have been carried to 50 degrees below the horizontal plane. In the primary position there may be no hyperphoria at all. In cases with such slight insufficiency there is rarely, if ever, any limitation of movement of the affected eye that we can detect. We are thus practically dependent on a single test (determination of the field of double vision). This we must not rely on too implicitly. There are many neurasthenic cases in which such a diplopia in the outlying portions of the field may occur at times, only to disappear again. Hence we should make the diagnosis of a true insufficiency of the inferior rectus only when repeated observations at rather long intervals give a consistent finding. Nor should we even then regard the condition as necessarily congenital, unless it is evident that the subjective troubles to which the condition gives rise have been lifelong.

I have seen many cases of the sort, and of these I have thought that twenty were congenital.

Slight as the deviation is, it often seems to cause considerable and persistent trouble, especially marked asthenopia. The patients state that from early childhood, in spite of the most accurate correction with glasses and in spite of physical well-being in other regards, they have not been able to read for any time at all without discomfort and a feeling of drowsiness which prevents attention. In other cases, vertigo is complained of. In some cases at least the symptoms have been pronounced enough to serve as a serious bar to professional work and advancement.

The deviation itself in these cases is too slight to serve as the starting-point for a lateral squint. In none of my cases was there either exotropia or esotropia.

(*b*) Marked insufficiency of the inferior rectus. I have seen six certain cases. In two of them the paralysis of the

inferior rectus was complete. In three cases there was well-marked constant exotropia, and in one other there was a high exophoria with marked convergence insufficiency (*i. e.*, the patient was on the verge of an exotropia). In all cases in which binocular vision was not maintained fixation was performed with the non-paretic eye. Head-tilting was marked in at least two cases (in one producing an actual torticollis).

III. *Insufficiency of the Inferior Oblique.*—Paralysis of the inferior oblique passes for the rarest of muscular anomalies, some alleging that it never occurs except as a result of traumatism. I have seen five cases in which there was no evidence of traumatism, and in which it seemed reasonably sure that the deviation was congenital. In one case, the congenital origin of which was undoubted, the deviation was very marked, and was associated with a peculiar form of false ptosis in the paretic eye—*i. e.*, a contraction of the palpebral fissure occurring when the eye was abducted, and a widening of the fissure when the eye was adducted. This, it will be noted, is a phenomenon just the reverse of that which occurs in the retraction syndrome (see Group VIII). No more than in the latter case is the contraction of the palpebral fissure a true ptosis. Unlike the syndrome cases, there was no retraction of the eyeball and no impairment of either outward or inward movement.

In one case, likewise quite surely congenital, there was a paresis of both inferior obliques, associated with an alternating exotropia. As each eye deviated outward and the in-turning eye fixed, the out-turning eye shot spasmodically upward (secondary deviation due to spastic contraction of the superior rectus). The result was an anotropia.

In one case, owing to poor vision in the non-paretic eye, fixation was performed with the paretic eye, causing a very disfiguring upshoot of the other when it was abducted. Two of the cases were complicated with exotropia.

IV. *Insufficiency of Superior Oblique.*—This comprises:

(*a*) Insufficiency of the superior oblique uncomplicated with other insufficiencies. This apparently is not very common. I have seen only six cases, and of these one (a very marked and typical case) was not certainly congenital, while in three others the diagnosis, owing to complications produced by operation or by other causes, was not perfectly sure.

In one case the nature of the deflection was such as to produce an anotropia. In another the condition seemed to be complicated by varying spasm of the inferior rectus and inferior oblique of the same eye. In two of the uncertain cases there was also considerable spasm of the inferior oblique in the affected eye, making the conditions resemble a good deal those in Group I (*a*).

(*b*) Insufficiency of the superior oblique and superior rectus in the same eye. One very marked case, probably congenital. The diagnosis, owing to complications produced by operations, was not absolutely certain, although quite fairly so.

V. *Combined Insufficiencies of Vertical and Lateral Muscles.*—This group comprises:

1. L. J. (male), aged fourteen. Complete paralysis of

structural insufficiency of the external recti. Case probably congenital. Tendon of left externus very thin and friable, so that it was advanced with great difficulty.

VI. *Marked Vertical Squint not Certainly Referable to Paralysis or Spasm of Any Definite Muscle.*—Of this type eight cases are recorded. They present many peculiarities. In two cases, while the conditions seemed to indicate a paresis of the elevators and depressors, the relations of the primary and secondary deviation were such as to be quite inexplicable on the theory of either paresis or spasm. It is probable that some peculiar insertional conditions obtained in these cases.

In two cases there was slight apparent ptosis, but not of a kind that would indicate any real insufficiency of the levator.

VII. *Uncomplicated Insufficiency of External Rectus.*—I have had five cases, in three of which both external recti were affected. In one of the unilateral and in one of the bilateral cases there was complete inaction of the affected muscle. In one case of incomplete paralysis the defect was found at operation to consist in adhesions of the tendon to the conjunctiva and sclera, hampering the action of the muscle. In this and another case there was incongruous diplopia, with what Graefe calls "antipathy to single vision." One unilateral case was associated with nystagmus. The condition, especially in the bilateral cases, simulated an ordinary alternating esotropia, which in one case, owing to simultaneous contracture of the interni, was of extreme degree. In another case, on the other hand, in which there was complete paralysis of both externi, there was binocular fixation, at least for near-points.

VIII. *Peculiar Syndrome Associated (Generally) With Retraction Movements.*—This interesting and undoubtedly congenital condition is marked by the following peculiarities:*

*Archives of Ophth., 1905, xxxiv, p. 133.

1. Restriction or usually complete abolition of outward movement in one or both eyes.

2. Restriction of inward movement in the eye in which abduction was absent.

3. Spasmodic upshoot (or sometimes downshoot) of the affected eye when adducted.

4. Closure of the palpebral fissure (not true ptosis) when the affected eye is adducted.

5. Retraction (often considerable) of the affected eye when adducted.

This affection occurs oftener in females than in males, and when unilateral usually affects the left eye.

I have seen seven well-marked cases (five females and two males), one patient being only two years old. Diplopia is commonly present; head-tilting is more or less frequent.

IX. *Insufficiency of the Internal Rectus.*—This, if we except the cases grouped under the syndrome just mentioned (Group VIII) and the complex cases of Group V, seems extremely rare as a congenital affection. I have seen but one case which I thought congenital, and in this the insufficiency was but slight.

X. *Esotropia (Non-paretic).*—I have noted five cases in which an esotropia was apparent since early infancy, and in which there was no evidence of a paresis of the externi. In three of the cases the conditions were those of a convergence excess, which, in distinction from the ordinary esotropia that develops later, was not accommodative in origin. These at least were probably congenital. In the other two cases the conditions may have had an accommodative element, but the diagnosis here was obscured by operations that had been done early in life, and it is difficult to say whether the squint was actually a congenital one or not. If congenital, the original deviation had probably been increased after birth by the effort of excessive accommodative tension, just as occurs in the case of ordinary acquired squint.

XI. *Exotropia (Non-paretic).*—I have noted three cases which were quite surely congenital. The conditions had the characters of a divergence excess, were associated with a diplopia (in two cases incongruous), and in one case with head-tilting and the tendency to shut one eye.

XII. *Lid Affections.*—Of the ordinary type of congenital ptosis I happen to have seen but one case. In this the defect was bilateral. The other types of lid affections that I have seen comprise two classes, viz.:

1. Slight drooping of the lid associated with insufficiency of the superior rectus in the same or the opposite eye (four cases); or with complex insufficiencies of the vertical and lateral muscles (one case cited under Group V); or with a hypertropia not certainly paretic (Group VI, two cases are cited).

2. Contraction of the palpebral fissure occurring when the eye is moved inward (in five of the seven cases of the retraction syndrome cited under Group VII) or outward (in one case affected with complete congenital paralysis of the inferior oblique, cited under Group III).

In neither of these two classes of cases is the contraction a true ptosis, *i. e.*, due to a paralysis of the levator. Rather is it the result of a contraction of the orbicularis muscle (spastic pseudoptosis), due to some peculiar associated nerve-action.

The peculiar condition known as "jaw-winking," which is usually associated with ptosis and with more or less paresis of the superior rectus or other muscles, and in which the lids open widely whenever the jaws are opened or are moved, I have never happened to see.

XIII. *Affections of the Interior Muscles.*—These seem to be very rare as a congenital anomaly. I have seen one case of partial ophthalmoplegia interior in a girl of sixteen which may have been congenital, although it is possible that it developed in the third year of life. The paralysis affected

both eyes, although unequally. The right pupil was 4, the left 5, mm. wide; light reaction was absent in both, and in the left the convergence reaction was also absent, or at all events minimal. The accommodation in the right eye was 4.75 D., in the left, 2.50. The mother was tabetic and had spinal miosis.

RECAPITULATION.

Recapitulating the above data, we find:

	No. of Cases.
I. Insufficiency of superior rectus:	
(*a*) Fixation with paretic eye	14
(*b*) Fixation with non-paretic eye	32
(*c*) Combined with insufficiency of inferior rectus	8
II. Insufficiency of inferior rectus:	
Slight	20
Marked	6
III. Insufficiency of inferior oblique	5
IV. Insufficiency of superior oblique:	
(*a*) Alone	6
(*b*) Combined with insufficiency of superior rectus	1
V. Combined vertical and lateral insufficiencies	4
VI. Vertical squint apparently non-paretic	8
VII. Insufficiency of external rectus (simple)	5
VIII. Retraction syndrome (insufficiency of externus and internus, combined with oblique and retraction movements and closure of lids in adduction)	7
IX. Insufficiency of internal rectus	1
X. Esotropia, non-paretic	5
XI. Exotropia, non-paretic	3
XII. Involvement of lid muscles:	
True ptosis	1
False ptosis comprising cases already included under various of the above heads	13
XIII. Ophthalmoplegia interior (perhaps not congenital)	1
Total	140
Entered twice	13
Net total	127

PREDOMINANCE OF VERTICAL DEVIATIONS.

A review of the cases here collected reveals two or three interesting facts. The first is the predominance of vertical deviations, due to involvement of the elevators and depressors. If we consider only the separate muscles involved, we find the following:

Superior rectus defective in	58	cases
Inferior rectus defective in	36	"
Superior oblique defective in	7	"
Inferior oblique defective in	6	"
External rectus defective in	16	"
Internal rectus defective in	7	"
Levator defective in	1	case
Interior muscles defective in	1	"

Or classing the deviations into vertical and lateral, we find:

Solely vertical	64
Solely lateral	16
Mixed vertical and lateral	45
	125

PREDOMINANT TYPE FORMS.

Again, certain type forms stand out as particularly common and characteristic. Such special forms are:

1. Group I: Isolated insufficiency of superior rectus. Especially characteristic is the form in which the paretic eye is used habitually for fixation.
2. Group II: Insufficiency of the inferior rectus, usually slight. Often attended with considerable subjective difficulties. Sometimes combined with (1).
3. Group VIII: The retraction syndrome with its highly characteristic features.
4. Group XII: The various lid symptoms, most of which coexist with paresis of the bulbar muscles. These are not to be confounded with true ptosis, which is comparatively uncommon.

Groups I, II, and VIII, it will be noted, comprise 69% of all the congenital anomalies of the exterior muscles contained in this series.

IMPORTANCE OF THE MIXED CASES. DEVELOPMENT OF AN ACQUIRED LATERAL SQUINT IN CONDITIONS OF CONGENITAL VERTICAL DEVIATIONS.

Particularly important is the frequency of the mixed cases —cases, that is, of vertical combined with lateral deviation.

Apart from the rather rare cases in which a true insufficiency of the lateral rotators is combined with an insufficiency of the elevators or depressors (Group V), a vertical deviation, and particularly any well-marked paresis of the elevators or depressors, is apt to be combined with a non-paretic esotropia or exotropia. Of 46 cases of isolated insufficiency of the superior rectus, 10 were complicated with exotropia and 11 with esotropia; of 14 cases in which the inferior rectus (either alone or in conjunction with the superior rectus) was involved so as to produce anything more than a minimum amount of diplopia, 11 showed exotropia; and the same was true of 2 out of 5 cases of insufficiency of the inferior oblique.* It is a striking fact that in these congenital cases exotropia is twice as common as esotropia, and that the exotropia so often assumes the characters of a divergence excess, *i. e.*, of a condition in which there is an active divergence of the externi, rather than a passive relaxation and weakening of the interni. These facts seem to me very significant, and strengthen the view that I have been led to by other considerations, namely, that the lateral deviation in these cases is set up by a more or less voluntary attempt to get the double images away from each other, and so make them less confusing. At the beginning a patient with vertical diplopia can obviate the confusion it causes, either by shutting one eye or by tilting the head, and one or both of these expedients are commonly adopted. Sometimes these are kept up throughout life, as in one case in which the effect of a congenital complete paralysis of the inferior rectus producing a vertical diplopia of 34$^{\Delta}$ was offset by a head-tilting that amounted to an actual torticollis.† In other cases the head-tilting is given up, and the patient then either converges or more often diverges the eyes, so as to place the

* It is rather strange that, while over 50% of the insufficiencies of the other elevators and depressors were complicated with lateral squint, none of the six cases of insufficiency of the superior oblique was so complicated.

† Both torticollis and diplopia were relieved by operation on the eye muscles.

double images as far apart as possible. This we saw take place in one of our patients with an insufficiency of the superior rectus, in whom the marked head-tilting that she showed at the age of one was replaced at the age of five by a divergent squint (pure divergence excess) which developed within a few months. The development of squint in these cases resembles the development that we have traced for squint in general,* and has its origin in the same principle, *i. e.*, the instinctive attempt to avoid diplopia.

Considering the comparative frequency with which this occurs, it seems not unlikely that a fair number of cases of what we have regarded as ordinary comitant squint are really due to unnoticed congenital vertical deviations which, some time after birth, have given rise in this way to a progressive lateral deflection of the eyes.

Apart from this very frequent post-natal development of lateral squint in a complication of a congenital vertical deviation, we sometimes see the latter increase by the same processes that increase an acquired paretic deviation, *i. e.*, by the development of spasm and contracture in the antagonists. In congenital deviations this is rare, but I noted it in two or three cases—in one, in particular, in which the vertical deviations, undoubtedly congenital, increased considerably under our observation.

SYMPTOMS.

The symptoms of congenital deviations are by no means insignificant. Apart from the obvious deformities—squint, ptosis, disfiguring upshoot in conditions like those given in Group I (*a*)—there are found head-tilting, sometimes amounting to torticollis, diplopia (not often spontaneous), confusion evidently due to diplopia, vertigo, asthenopia, aprosexia, and other evidences of discomfort and strain.

* Duane: "Motor Anomalies of Eye," chaps. vii, viii; "Evolution of Squint," Xe Congrès d'ophtalmologie.

As would be supposed, insufficiencies of the depressors, particularly the inferior rectus, cause more trouble in this regard than do insufficiencies of the elevators, and in the case of the inferior rectus it is the very slight and hardly discoverable insufficiencies that often cause persistent and considerable trouble.

TREATMENT.

Treatment of these cases is required when the symptoms are sufficiently important. It is best to initiate it early, as some of the more troublesome developments may thus be forestalled. For example, by the removal in early childhood of a vertical deviation the subsequent development of a lateral squint may be prevented. For cases in which the deviation is of any amount operation is the only resource. This must be selected according to the needs of the individual case after a careful diagnosis has been made. In cases of Group I, and especially Group I (*a*), tenotomy of the overacting inferior oblique acts very well, particularly in relieving the symptoms. This may be supplemented by advancement of the superior rectus. Advancements of other insufficient muscles—especially the inferior rectus or the externus—may be made as required. Advancement, however, should be avoided in the retraction cases like those of Group VIII, for here the eyeball, being already bound down tightly and thereby hampered in its movements, would be hampered still more by the tightening effect of an advancement. Sometimes in these and in other cases, too, the preferable operation is a tenotomy of the associate muscle in the other eye. Every case, however, must be judged by itself.

In the case of small deviations, particularly the very slight ones often caused by insufficiency of the inferior rectus, material relief may be had by prisms of 1^{Δ} or 2^{Δ}, base up or down. These may be added to the glasses for constant wear, or, if the deviation occurs only in the lower

I passed them over on
ainly in congenital devia-
on the screen test; and
getting the field of double
either method, it is easy
he time, and by means of
ays fixes to the exclusion
can answer this question
I have seen, the patients

-

OF CORNEAL ASTIG-
LAR ANOMALIES.

M.D.,

ided from consideration
r frequency is underesti-
xis can be measured only

on, corneal astigmatism
curvature of that mem-
ed with the curvature in
make clear the object of
rst a statement in figures
form of astigmatism; for
sm of, say, one diopter.
rnea has been measured
slightly different results.
o assume that the normal
v, to find the radius of
that radius is too short,

assuming nothing else except that radius changes, let us suppose that a lens of D. diopters is—

d = millimeters in front of the eye.

r = radius of the cornea.

n = index of refraction of the eye.

Then, for myopic astigmatism, for example:

$$r = \frac{\frac{7830}{D} + (d)\ 7.83}{\frac{1000}{D} + \frac{7.83}{n-1}}$$

For a myopic of 1 diopter r = 7.70, or the astig. = 0.13 mm.

For a myopic of 2 diopters r = 7.57, or the astig. = 0.26 mm.

For a myopic of 3 diopters r = 7.44, or the astig. = 0.39 mm.

The radius of curvature in hypermetropic astigmatism is expressed by the same equation, of course, only the sign is changed.

The main object of this note is to call attention to the fact that this astigmatism is not infrequently hereditary. This means that the eye of a child sometimes resembles that of a parent or other ancestor, not only in the kind of astigmatism, but approximately in degree, and occasionally even in the meridian of the abnormal corneal curvature.

Examples of the first class are very frequent. Simple hypermetropic astigmatism with the rule is so common that it may be counted almost as normal, and should be excluded from consideration here, because it may be due to other causes, or even produced artificially by pressure of the lids.

A better illustration of the heredity referred to is presented by those families in which there was an astigmatism against the rule. Without going over many records it was easy to find six families in which an astigmatism against the rule

or within ten degrees of that point existed. The resemblance was:

In two families between father and son.
In one family between mother and two daughters.
In one family between four sisters.
In one family between father, two sons, and one daughter.
In one family between father, one son, and three daughters.

Such examples have probably been observed by most clinicians. But the best examples of the heredity of astigmatism are those in which the astigmatism with oblique axis occurs in one or more persons of the same family, the degree being approximately the same, and the axis also approximately the same; for example, varying not more than ten degrees. I have seen only one real example of this, at least since my attention was called to the subject. A mother had:

$$\text{R.} + 1.25 \text{ c } 135^\circ \text{ V} = \frac{6}{9}$$

$$\text{L.} + 1.00 \text{ c } 140^\circ \text{ V} = \frac{6}{6}$$

One daughter had:

$$\text{R.} + 1.00 \text{ c } 145^\circ \text{ V} = \frac{6}{6}$$

$$\text{L.} + 1.00 \text{ c } 90^\circ \text{ V} = \frac{6}{6}$$

Another daughter had:

$$\text{R.} + 1.25 \text{ c } 90^\circ \text{ V} = \frac{6}{6}$$

$$\text{L.} + 0.75 \text{ c } 130^\circ \text{ V} = \frac{6}{9}$$

It is true these are not really perfect examples. It would be too much to expect the resemblance to be exact, though perhaps better examples have been observed by others. But these facts lead to the conclusion that a difference in the corneal curvature, which is represented by even 0.13 of a millimeter, is transmitted from parent to offspring.

In spite of the far-reaching effect of heredity in ophthalmology, as in all other branches of medicine, there is perhaps no more striking example than this, in which a variation from the normal type to so small a fraction of a millimeter is transmitted from one generation to another.

Finally, a word may be added concerning the relation of heredity of conditions of the ocular muscles. It would be far beyond the limits of this note to attempt any discussion of all of the abnormal conditions of the ocular muscles which we have long known to be hereditary, such as esotropia, exotropia, and similar abnormalities. Every clinician of experience has seen cases of esotropia, for example, or of exotropia, in the same family. These are so frequent as hardly to arrest attention. But these family resemblances exist not only in the evident malpositions of the visual axis which we call heterotropia, but also when the malposition is not apparent, that is, in heterophoria.

Before my attention was called to the heredity especially of exophoria or hyperphoria, I had but little idea as to its frequency. Without any difficulty, however, I have been able to turn to records of four families in which a marked exophoria was a most prominent and annoying symptom. Other examples of this kind are not cited, but I am sure they can be duplicated by the records kept by any practitioner.

If it seems to us a marvel that a radius of curvature of the cornea which is expressed in decimals of a millimeter can be transmitted from parent to child, it is no less a marvel that the anatomic or functional peculiarities of the ocular muscles which produce a heterophoria of a given kind, and of a given degree, are also hereditary. Indeed, in the whole range of medicine probably no better examples of heredity can be found than those which show themselves in the eye, especially in the curvature of the cornea, and in the form and action of the ocular muscles.

APPENDIX.

REPORT OF THE COMMITTEE ON OPHTHALMIA NEONATORUM.

I. Explanatory.

In explanation of the present report mention should be made of the two which preceded it. In 1887 this Society appointed a committee on ophthalmia neonatorum—that being apparently one of the first official recognitions of the importance of that disease by any such society in any country. The startling facts and figures which it was easy to collect then, are now well known and have been frequently verified.

In 1907 this Society appointed a similar committee—two members being the same as served on the first. A comparison of the conditions existing at that time and twenty years before was interesting, not only in showing how any gain had been made in lessening that disease, but, after all, how slight that gain was.

At the last meeting of this Society a resolution was passed instructing the Committee on Ophthalmia Neonatorum to communicate with ophthalmologists and others in order to compare different views and methods, and by associated effort to bring about better results, if possible, in the prevention and treatment of this disease.

We are already familiar with the efforts which have been made and which are still being made constantly for the prevention of blindness from ophthalmia of infancy. We know that many States have laws which require midwives to re-

port these cases to some qualified physician as soon as they are recognized. We know that the committee of the American Medical Association for the prevention of blindness has organized the profession in nearly all of the States, to make an admirable effort to lessen the number of cases which result in blindness.

We know also of the earnest efforts made by various philanthropic societies to second these efforts of the physicians.

But when we take into account all of these agencies and consider the results, we must admit to ourselves that the total gain is by no means what it might be. The progress made in one direction often has meant a loss of energy in another.

The object is now to find out, if possible, why it is that these sad cases are still met with—forming nearly a fourth of the blind in our asylums; and why each year hundreds of recruits are added to that army of over eight thousand people in the United States who, from this disease alone, are made a burden to themselves, to their friends, and to the community.

Thus far the average ophthalmologist has laid the blame of this condition on the midwife or the obstetrician, or on both, and has contented himself with cleansing the conjunctiva and applying solutions of silver nitrate, or of the proprietary silver compounds, most of which are unknown as to their composition or their exact effects.

The result is that although there has been some slight decrease in the number of these cases, they still occur with all of their sad and costly results, a calamity to themselves, and a shame to the medical profession, especially to the ophthalmologists.

Apparently, therefore, there is some fault with our method, or, to state the problem in other words, the physician is gradually learning that the mere diagnosing of this disease,

and the treatment of it, form a comparatively small part of his duties.

II. Duties of the Committee.

Therefore, the evident duty of a committee like ours is:

First, to ascertain what are the weak points in our line of attack, and,

Second, to call attention to them, indicating, if possible, also, a method by which those points can be strengthened.

Now if we make even a cursory examination of the field before us, we find that it contains several divisions which should be clearly separated from each other. These are:

(*A*) The prevention of gonorrhea itself.

(*B*) Prenatal prophylaxis.

(*C*) The recognition of the gonococcus after infection, and its possible destruction, either by local antigonococcic treat-

the sources of information are available to every physician. As long as this condition exists it is practically useless to expect any great reduction in the number of cases of ophthalmia neonatorum. In spite of all laws which require midwives to report cases of ophthalmia, in spite of all organized efforts among physicians for the prevention or cure of that disease, in spite of the earnest efforts of large-hearted men and women outside of the profession who are seeking the same object—in spite of these and all other efforts, requiring a vast amount of energy and time and cost, all these innocent children will be infected and be subjected to suffering and blindness, just so long as a large number of any community continues to be infected with gonorrhea. In other words, unless we stop this flood at its source our combined efforts amount to nothing more than the sweeping back of the ocean with a broom.

(*B*) *The Spread of Gonorrhea Can be Restricted or Perhaps Prevented.*—A second point which becomes evident in any such study is that the spread of gonorrhea can be restricted or perhaps prevented. As we have gradually learned that with proper precautions we can restrict or even prevent the spread of smallpox or other contagious diseases, as we have learned during the last quarter of a century that even tuberculosis comes in this same category, so is it now dawning upon the leaders of the medical profession and even upon the laity that the time has arrived to join in a crusade against gonorrhea, a disease which has properly been called "the black plague." This movement has been started so recently and has grown so rapidly, that its extent and strength are surprising to any one whose attention has not been called to them. As recently as 1905 the American Society of Sanitary and Moral Prophylaxis, whose headquarters is in New York, issued its first publications. Now there are societies directly allied with that Society, or with practically the same objects in view, existing in Baltimore, Buffalo, Chicago,

Denver, Indianapolis, Jacksonville, Milwaukee, Philadelphia, Portland, St. Louis, Spokane, and in other cities, besides some State societies, like those of California and West Virginia. This rapidly increasing number shows that the public is gradually awakening to the importance of the subject.

It is far beyond the scope of a report like this to indicate what are the best methods to follow, but it suffices to say that by educating the public as to the gravity of this disease, by municipal regulations of prostitution, and by conservative and simple legislation, a great deal of good has already been accomplished.

(*C*) *Ophthalmologists Should be Leaders in this Crusade Against the Black Plague.*—The majority of us can easily place ourselves in communication with the societies for pro-

much to emphasize the importance of this movement by calling attention to the fact—brought out by all recent statistical studies of this disease—that, while many cases of ophthalmia in the new-born arise from other causes, the cases which result in blindness are due, almost without exception, to gonococcal infection.

IV. Other Factors in the Problem of the Prevention of Ophthalmia Neonatorum.

Although this Committee thought it best to devote the greater part of this report to the prevention of gonorrhea, they would call attention also to studies bearing on other factors in this problem. Early in the year we were fortunate enough to enlist the coöperation of Dr. John C. Torrey, of the Loomis Laboratory, and we take this occasion to express our hearty thanks for the care and attention he has given to the subject. He prepared a polyvalent serum for these cases, which has thus far been used by Dr. Edgar S. Thomson in a few cases only, and with results not particularly satisfactory, but it is hoped that this part of the study can be taken up again, and later a more definite report can be made concerning it. One or two other aspects of the subject deserve attention, but it is impossible to dwell upon them now.

V. Conclusion.

In view of the foregoing, the Committee asks for more time, and this year respectfully recommends that each member of the Society join in some organized effort for the restriction of the spread of gonorrhea, thus helping to lessen also the ravages of ophthalmia neonatorum.

Lucien Howe
Edward Jackson
Peter A. Callan

LIST OF SOME OF THE AMERICAN SOCIETIES REFERRED TO IN THE REPORT.

California State Association for the Study and Prevention of Syphilis and Gonorrhea. (R. A. Archibald, Oakland, Cal.)

Connecticut Society of Social Hygiene. (Dr. Thomas N. Hepburn, 42 High St., Hartford, Conn.)

Colorado Society for Social Health. (Dr. Ethel V. Fraser, 1434 Glenarm Street, Denver, Colo.)

Chicago Society of Social Hygiene. (Wirt W. Hallam, Esq., 79 Dearborn Street, Chicago, Ill.)

The Indiana Society of Social Hygiene. (Dr. H. G. Hamer, Newton Claypole Building, Indianapolis, Ind.)

Detroit Society for Sex Hygiene. (Raymond E. Van Syckle, 33 High Street, East, Detroit, Mich.)

St. Louis Society of Sanitary and Moral Prophylaxis. (E. A. Hildenbrandt.

-

INDEX TO AUTHORS, VOL. XII.

PAGE

Alling, A. N.:
A Case of Ring Sarcoma of the Ciliary Body 778

Bruns, Henry Dickson:
A Case of Spasm of the Retinal Arteries 535
Bull, Charles Stedman:
The Adverse Influence of Diabetes in Certain Operations on the Eye 62
Memoir of Dr. Samuel Benedict St. John 351
The Post-operative History of Eighteen Cases of Magnetic Foreign Bodies Removed from the Eye by the Haab or Giant Magnet 365
Byers, W. Gordon M.:
Conjunctival Flaps in Ophthalmic Surgery 398
Colored Toric Glass for Use in Examining Cases of Ocular Paralysis 677

Callan, Peter A.:
Memoir of Dr. Charles John Kipp 700
Carmalt, William H.:
Memoir of Dr. Charles Stedman Bull 694
Claiborne, J. Herbert:
Cylndroma of the Orbit 441
The Operation of Excision of Tarsus and Conjunctiva (Heisrath) in Old Trachoma, Together with Demonstration of a New Instrument, and a Description of a New Method of Performing It 767
Clark, C. F.:
The Possible Influence of Racial and Other Characteristics in Accounting for the Success of the Smith-Indian Operation 385

Davis, A. Edward:
The Treatment of the Eye when the Globe is Infected, with the Object of Preventing Panophthalmitis 103
Derby, George S.:
Vaccine and Serum Therapy in Ocular Tuberculosis 614
The Use of Serum in Sympathetic Ophthalmia 748
Probable Cyst of the Retina, with a Demonstration of the Patient . . 827
Duane, Alexander:
A Classification of Eye Diseases 31
Congenital Deviations of the Eyes 981

Emerson, J. B.:
Memoir of Dr. Daniel Bennett St. John Roosa 14
Ewing, Arthur E.:
Cataract Extraction with the Least Trauma, Excellent Visual Results 914

Fisher, Carl:
The Differentiatio
phologically S
Fridenberg, Percy:
The Nerve-head
Fuchs, E.:
The Field of Visi
Neuroma of the
Smallest Sarcom

Goldberg, Harold G.
Pathologic Rep
Gruening, E.:
Memoir of Dr.
Embolism of t
Years...

Hansell, Howard I
A Case of Bil
Ocular Signs
Harlan, George C
Memoir of D
Holden, Ward A.
A Report of
bulbar
Holloway, T. B.
Congenital
Exhibition
Retinitis P
Holt, Erastus F
Physical E
Howe, Lucien:
Tropomet
On the Di
Arra
Note on
Ano

Ingalls, Jame
Spontan

Jack, Edwin
New-gr
Jackson, Ed
Standa
Memoi
Ciliore

Kipp, Cha
Hemo
Knapp, A
Glauc
Dyst
A Ca
Phan

PAGE

Koller, Carl:
Recurrent Tubercular Choroiditis 586

Lambert, Walter E.:
Memoir of Dr. Richard Henry Derby 19
Libby, George F.:
A Case of Complete Albinism: Observations on the Changes in the Diameters of the Lens as Seen Through the Iris 246

Marple, W. B.:
Some Observations on the Use of the Schiötz Tonometer. ... 552
Minor, James L.:
Some Impressions of Certain Eye Affections in the Negro as Compared with the White Race 459

PAGE

Sattler, Robert:
Intracapsular Extraction of the Cataractous Lens 889
de Schweinitz, G. E.:
Concerning a Form of Retinal Disease, with Extensive Exudation; Being a Clinical Contribution, with the Report of Two Cases 273
Some Observations of the Ocular Manifestations of Sinus Disease . . 477
Concerning Certain Tumors of the Orbit, and Certain Conditions Simulating Neoplasms of the Orbit, Being a Clinico-pathologic Contribution, with the Report of Six Cases 842
Semple, N. M.:
Some Questions Concerning the Method of Development and the Pathology of the Retinitis of Bright's Disease 817
Sherman, Harris G.:
Illuminated Box Eye-testing Chart 658
Shoemaker, William T.:
Adenocarcinoma of the Pituitary Body. Report of a Case under Observation for Four and a Half Years. Pathologic Examination 173
Shumway, Edward A.:
Metastatic Carcinoma of the Orbit, with the Report of a Case 191
Slocum, George:
Report of Two Cases of Chronic Cyanosis with Polycythemia, Including Ophthalmoscopic Examination 505
Snell, Albert C.:
Episcleritis Periodica Fugax 736
Standish, Myles:
The Position of the Eye the Element of Safety in the East Indian Extraction in Capsule 885
The Mechanics of Choked Disc 936
Stevens, George T.:
Suggestions Regarding the Nature of Visual Sensations 644
A Brief Note Concerning the Tropometer 667
Sweet, William M.:
Third Series of Cases of Injuries from Foreign Bodies Examined by the Roentgen Rays, with Results of Operation 117
Improved Apparatus for Localizing Foreign Bodies in the Eyeball by the Roentgen Rays 320
Implantation of a Metal Ball in Tenon's Capsule (The Frost-Lang Operation), with Report of 48 Cases 492
Subsequent History of a Case of Exostosis of the Orbit Reported to the Society in 1897 879

Theobald, Samuel:
Summary of Results Obtained, and Features of Interest, in Two Hundred and Fifteen Consecutive Cataract Extractions 76
A Protest Against the Indiscriminate Use of the Organic Compounds of Silver in Ophthalmic Practice 763
Thomson, Edgar S.:
Memoir of Dr. Frank Newell Lewis 704
Thorington, James:
Report of a Case of Leukosarcoma of the Iris Successfully Removed by Iridectomy and Useful Vision Retained 409
Timberman, Andrew:
The Iris in the Intracapsular Operation for Cataract 906

	PAGE
Veasey, C. A.:	
Large Piece of Wood Embedded Deeply in Orbit of Child Twenty-five Months. Removed, with Preservation of Vision	395
Report of a Case of Epibulbar Sarcoma	436
Verhoeff, F. H.:	
New-growths of the Lacrimal Gland—a Case. Death	414
Tumor of the Adrenal Gland with Metastasis in the Orbit	451
The Histologic Findings in a Case of Tuberculous Cyclitis, and a Theory as to the Origin of Tuberculous Scleritis and Keratitis.	566
The Pathology of Superficial Punctate Keratitis, with Remarks on Neuropathic Keratitis in General, and on a Hitherto Undescribed Lesion of the Iris	791
Weeks, John E.:	
Vaccine and Serum Therapy in Ophthalmology	598
West, J. M.:	
A Window Resection of the Nasal Duct in Cases of Stenosis	654
Wilder, William H.:	
Report of Two Cases of Pulsating Exophthalmos. Relief of One by Ligation of the Common Carotid; Relief of the Other by Ligation of the Common Carotid, Followed after Recurrence by Ligation of the Internal Carotid	832
Williams, Chas. H.:	
Memoir of Dr. Gustavus Hay	11
Improved Lantern for Testing the Color-perception. Model of 1909	330
Zentmayer, William:	
Angioid Streaks in the Retina, with the Report of a Case	267
Ziegler, S. Lewis:	
Symmetrical Lymphomata of the Lacrimal and Salivary Glands (Mikulicz's Disease)	222
Memoir of Dr. Charles Augustus Oliver	701

[redacted]

INDEX TO SUBJECTS, VOL. XII.

ADENOCARCINOMA of Pituitary Body, 173
Adrenal Gland, Tumor of, with Metastasis of Orbit, 451
Albinism, Case of Complete, 246
Albuminuric Neuroretinitis in Retinitis Pigmentosa, 972
Amaurosis, Wood Alcohol, 513
Angioid Streaks in Retina, 267
Arcs of Rotation, Measurements of, 312
Argyrol, Use of, 763
Arthritis in Gonorrheal Conjunctivitis, 759
Atrophic Eye, Sarcoma and Bone Formation in, 188

BJERRUM Stick, 966
Bright's Disease, Retinitis of, 817
Bull, Charles Stedman, Memoir of, 694

CARCINOMA, Metastatic, of the Orbit, 191
Cardiovascular Disease from Intestinal Sepsis, 950
Cataract Extraction in Capsule, 385, 885, 889, 906
Extraction with Least Trauma, 914
Influence of Diabetes in Operation, 62
Results in 215 Extractions, 76
Smith-Indian Operation, 385, 885, 889, 906
Chart, Illuminated Box Eye-testing, 658
Chlorosis, Neuroretinitis in, 284
Choked Disc, Mechanics of, 936
Relation to Intraocular Tension, 940
Chorioretinitis, Central Hemorrhagic, in Non-myopic Eyes, 250
Choroid, Smallest Sarcoma of, 787
Choroiditis, Recurrent Tubercular, 586
Ciliary Body, Ring Sarcoma of, 778
Nerves, Neuroma of, 786
Cilioretinal Vessels, 960
Classification of Eye Diseases, 31
Coloboma, Bilateral Macular, 249
Double, of Optic Nerve and Sheath, 968
Color Perception, Lantern for Testing, 330
Congenital Deviations of the Eyes, 981
Pigmentation of Cornea, 423
Conjunctival Flaps, 398
Conjunctivitis, Gonorrheal, with Arthritis, 759
Cornea, Congenital Pigmentation of, 423
Corneæ, Dystrophia Epithelialis, 745
Corneal Astigmatism, Heredity of, 1001
Cyanosis with Polycythemia, 505
Cyclitis, Tuberculous, 566
Cylindroma of Orbit, 441
Cyst of Retina, 827

DERBY, Richard Henry, Memoir of, 19
Diabetes, Adverse Influence in Certain Operations, 62
Diphtheria Bacillus, Differentiation of, 297
Dystrophia Epithelialis Corneæ, 745

ECONOMICS, Physical, 141
Embolism of Right Central Artery, 978
Enucleation, with Implantation of Gold Ball, 492
Epibulbar Sarcoma, 436
Episcleritis Periodica Fugax, 736
Exophthalmos, Pulsating, 832

Exostosis of Orbit, 879
Eye Affections in Negroes, 459
Diseases, Classification of, 31
Eyeball, Localizing Foreign Bodies in, 320
Spontaneous Rupture of, 169

Fibroma, Orbital, 205
Field of Vision in Tabetic Atrophy, 718
Flaps, Conjunctival, 398
Foreign Body Injuries, 117, 365
in Orbit for Twenty-five Months, 395
Bodies, Localizing by Roentgen Rays, 320
Bodies, Results of Magnet Extraction, 117, 365
Formosan Savage, Ocular Asymmetry of, 455
Frost-Lang Operation, 492

Glaucoma from Adhesion of Lens Capsule to Cornea, 472
Spontaneous Rupture of Globe, 169
Gonorrheal Conjunctivitis with Arthritis, 759

Harlan, George Cuvier, Memoir of, 347
Hay, Gustavus, Memoir of, 11
Heisrath Operation in Trachoma, 767
Hemorrhagic Central Chorioretinitis, 250
Heredity of Corneal Astigmatism, 1001

Injuries, Ascertaining Damages after, 141
by Foreign Bodies, Results of Operation, 117
Intestinal Sepsis in Cardiovascular Disease, 950
Intraocular Infections, Treatment of, 103
Tumor, 883
Iridotomy, Choice of Operation, 89
Iris in Intracapsular Extraction, 906
Leukosarcoma of, 409

Keratitis, Neuropathic, 791
Superficial Punctate, 791
Kipp, Charles John, Memoir of, 700
Knapp, Herman, Memoir of, 687

Lacrimal and Salivary Glands, Symmetrical Lymphomata of, 222
Gland, New-growths of, 414
Lantern for Testing Color Perception, 330
Lens Capsule, Adhesion to Cornea Causing Glaucoma, 472
Changes in Complete Albinism, 246
Leukosarcoma of Iris, 409
Lewis, Frank Newell, Memoir of, 704
List of Members, 5, 341, 681
Lymphomata of Lacrimal and Salivary Glands, 222

Macular Coloboma, Bilateral, 249
Magnet, Results of Operations by, 117, 365
Massive Exudation in Retina, 273
Metastatic Carcinoma of the Orbit, 191
Mikulicz's Disease, 222
Minutes of Proceedings, 21, 355, 708
Muscular Anomalies, Heredity of, 1001
Anomalies, Congenital, 981
Myelitis, Retrobulbar Neuritis in, 728

Nasal Duct, Window Resection of, 654
Necrology, 11, 347, 687
Negroes, Eye Affections in, 459
Neuritis in Myelitis, 728
Neuroretinitis in Chlorosis, 284
in Retinitis Pigmentosa, 972

Ocular Asymmetry of Formosan Savage, 455
Manifestations of Sinus Disease, 477
Signs of Vasomotor Disturbances, 526
Oliver, Charles Augustus, Memoir of, 701
Optic Nerve, Atrophy in Tabes, 718
Double Coloboma of, 968
Retrobulbar Neuritis in Myelitis, 728
in Wood-alcohol Amaurosis, 513

Ophthalmia Neonatorum, Report of Committee on, 357, 1005
Optometry Bills, Resolutions Relating to, 359
Orbit, Cylindroma of, 441
Exostosis of, 879
Large Piece of Wood in, 395
Metastasis of, from Adrenal Tumor, 451
Metastatic Carcinoma of, 191
Tumors of, 842
Orbital Fibroma, 205

Panophthalmitis, Prevention of, 103
Papillitis, Mechanics of, 936
Relation to Intraocular Tension, 940
Paralysis, Ocular, Toric Glass for Examination of, 677
Pathology of Retinitis, 817
Physical Economics, 141
Pituitary Body, Adenocarcinoma of, 173
Polycythemia, Ophthalmoscopic Examination of, 505
Prism Tests, 669
Protargol, Use of, 763
Pulsating Exophthalmos, 832
Punctate Keratitis, Pathology of, 791

Retina, Angioid Streaks in, 267
Cilioretinal Vessels, 960
Cyst of, 827
Diagnosis of Subretinal Mass, 466
Embolism of Central Artery, [illegible]
Extensive Exudation in, 273
Retinal Arteries, Spasm of, 535
Retinitis, Pathology of, in Bright's Disease, 817
Pigmentosa with Albuminuric Neuroretinitis, 972
Roentgen Rays, Localizing Foreign Bodies, 117, 320
Roosa, Daniel Bennett St. John, Memoir of, 14
Rupture of Eyeball, Spontaneous, 169

Schiötz Tonomo
Serum in Symp
748
and Vacci
Silver, Organic
Sinus Disease, C
of, 477
Smith-Indian C
889, 906
Smith-Indian O
Racial Charac
Spasm of Retina
St. John, Samu
of, 351
Stevens, Edmun
Sympathetic O
Serum in, 748

Tarsus, Excisio
[illegible]
Tenon's Capsul
Metal Ball in,
Tension, Intra
Choked Disc
Test Chart, Illu
Test-types, Stan
Thomson, Willia
Tonomotor, Use
Trachoma, Exci
Conjunctiva i
Tropometer, Bri
667
Tropometers an
Arcs of Rotati
Tubercular Ch
[illegible]
Tuberculosis, V
Therapy in, 6
Tuberculous Cy
ings in, 566
Tumor, Phanton
Tumors of Orbit

Vaccine and Ser
Vasomotor Di
Signs of, 526
Visual Acuity,
types a
Field, Ne
Sensation